


RCP TIPS TH

Dominique Thabut, Marika Rudler, Filomena Conti
Charles Roux
Eric Savier

Mardi 7 juin 2022



La Transplantation hépatique est le traitement des hépatopathies au stade terminal ou décompensées mais

- Pénurie de greffon accès difficile pour les MELD bas

Le TIPS améliore la survie par rapport au traitement standard

- Dans l'hémorragie digestive chez les patients à haut risque de récurrence
- En cas d'ascite réfractaire
- En cas d'ascite récidivante

La problématique

TIPS

- 3 risques principaux
 - Insuffisance hépatique et décès
 - Encéphalopathie hépatique (35%, réfractaire 5%); mise sous RFX systématique
 - Insuffisance cardiaque (20%)
- Efficacité dans l'ascite réfractaire
 - 70%

TH

- Difficulté d'accès à la TH
- Composante expert seulement si TIPS inefficace ou CI
- TH si complication du TIPS



Discussion TIPS et TH dans le même temps en cas d'effet indésirable grave ou d'inefficacités

Outils de sélection

- Plq bili
- Fips
- Impression clinique
- MELD
- Composante expert

Patient ayant une indication de TIPS



Présentation en réunion multidisciplinaire
(hépatologues + chirurgiens+ anesthésistes + radiologues + addictologues + infirmières)

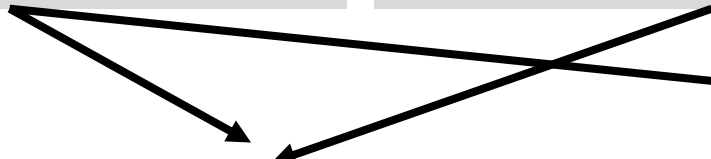


OK TIPS et TH
Dans les indications TIPS et TH
Pas de contre-indication

OK TIPS mais pas TH
Dans les indications TIPS et TH
Contre-indication à la TH

OK TH mais pas TIPS
Dans les indications de la TH
Contre-indication au TIPS

TIPS et TH non
retenus



Bilan pré-TIPS
(Evalutation risque EH, risque cardiaque)



Bilan pré-TH

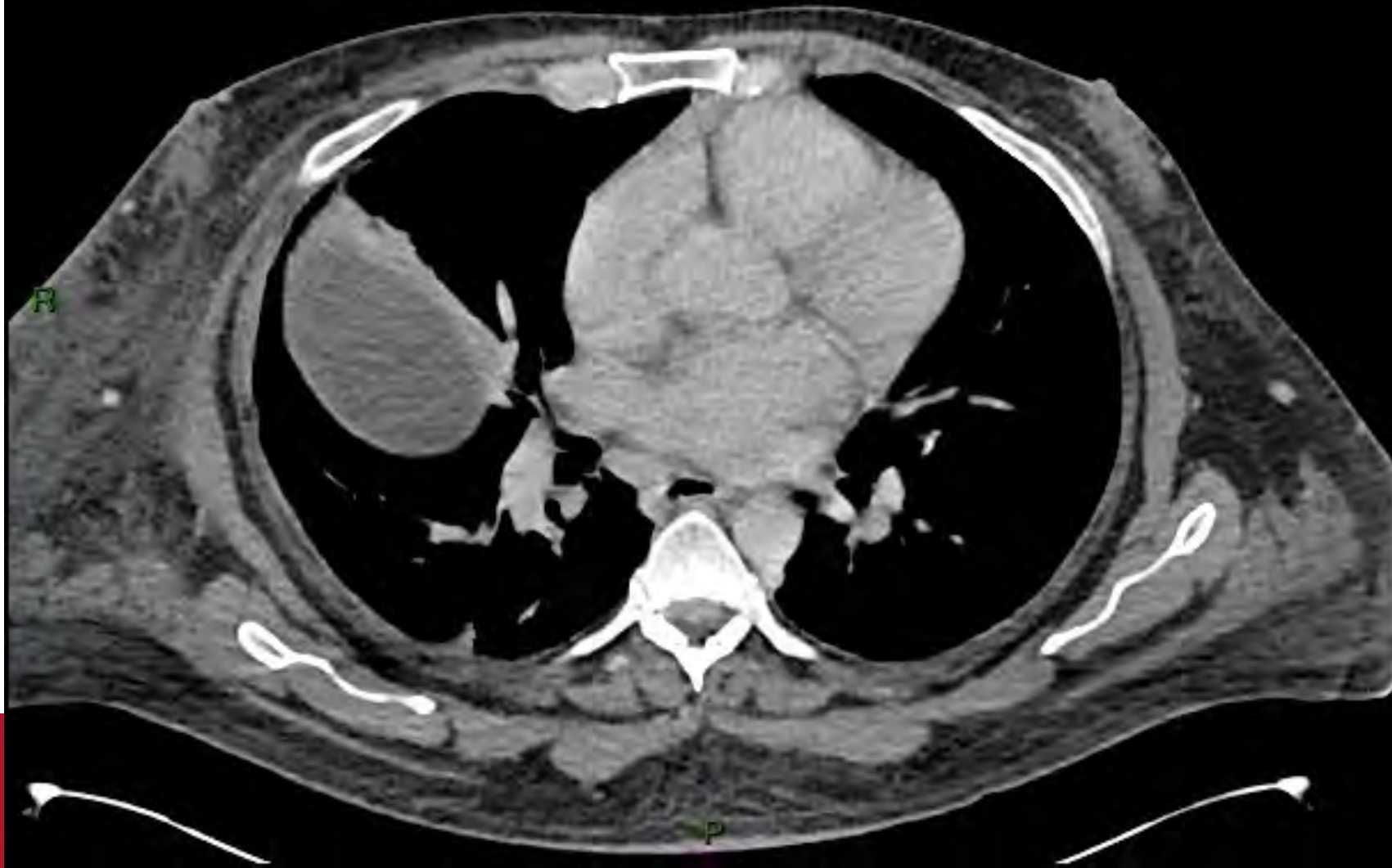Cas n°1

- Homme 44 ans, groupe 0
- Cirrhose liée à une conso OH et un syndrome métabolique, sevrage OK
- Ascite R (IR sous diurétiques), VO grade I, jamais EH, pas de CHC ni de thrombose porte
- Bio: Hb 7,3 g/dL, Plaq 49.000/mm³, Bili 74/51 micromol/L , Albumine 20g/L, créat 111 micromol/L, TP 30%, FV 22%
- Bilan cardiaque bio et morphologique N
- Child C13, MELD 25
- **BMI 55 au moment de la discussion (mais anasarque)**
- **Bili 74, plq 49000**
- **Fragilité: 4,81**
- **(FIPS score: 0,88 (âge, créat, bili, INR, albu))**

Actuel

[18/02/2022 16:28:00]

<15-1>



Cas n°1

TIPS

- Le pour
 - Indication de TIPS
 - Anasarque rendant ce patient très jeune grabataire
 - Aucun accès à la TH
- Le contre
 - IHC sévère (MELD 25, C13)
 - Bili > 50 $\mu\text{mol/L}$, plaq < 75.000/mm³

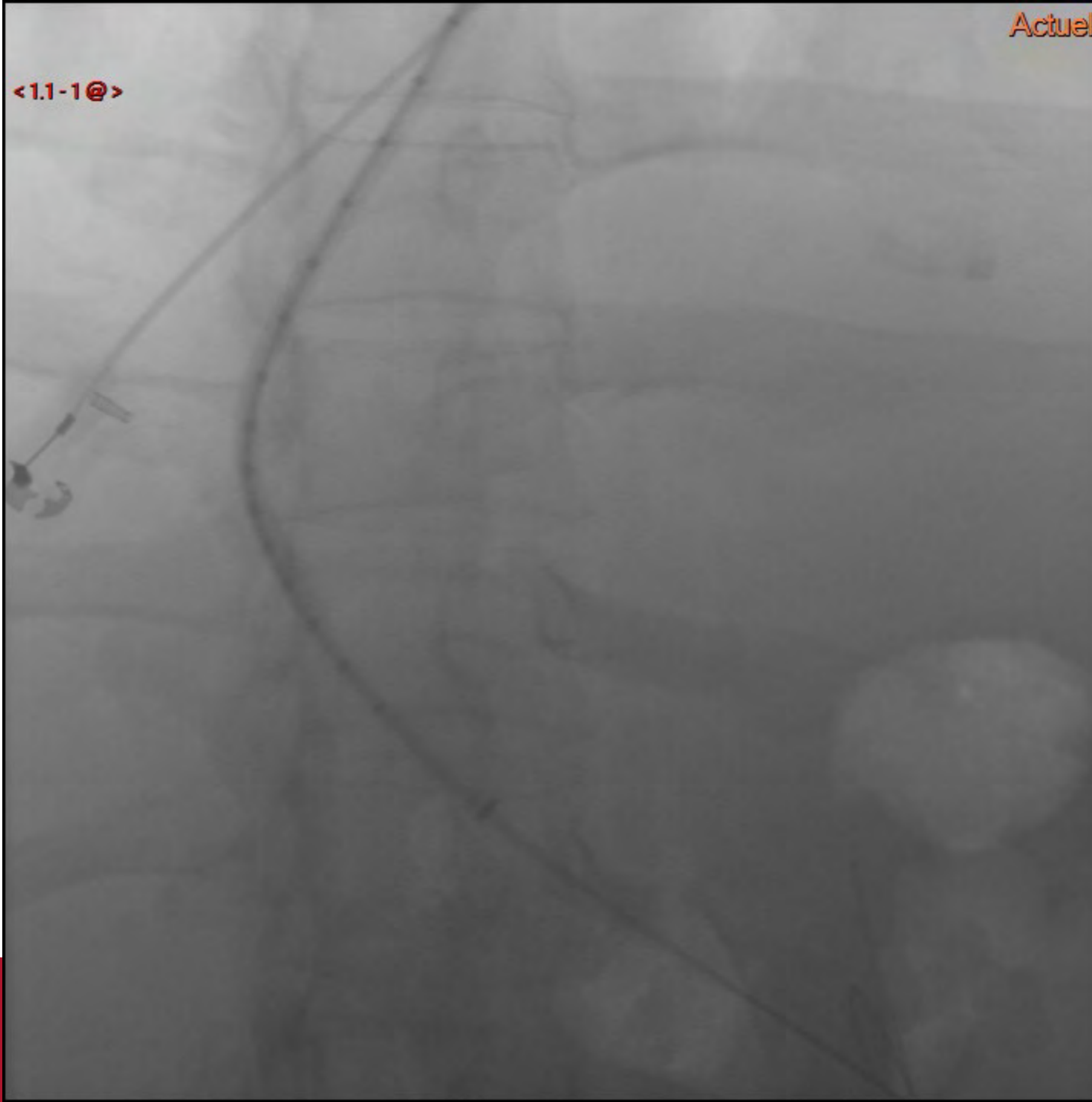TH

- Le pour
 - Indication de TH
 - IHC sévère (MELD 25, C13)
 - Sevrage complet
- Le contre
 - BMI 55
 - Pas d'accès rapide à la TH
 - Pas de composante expert MELD > 15!

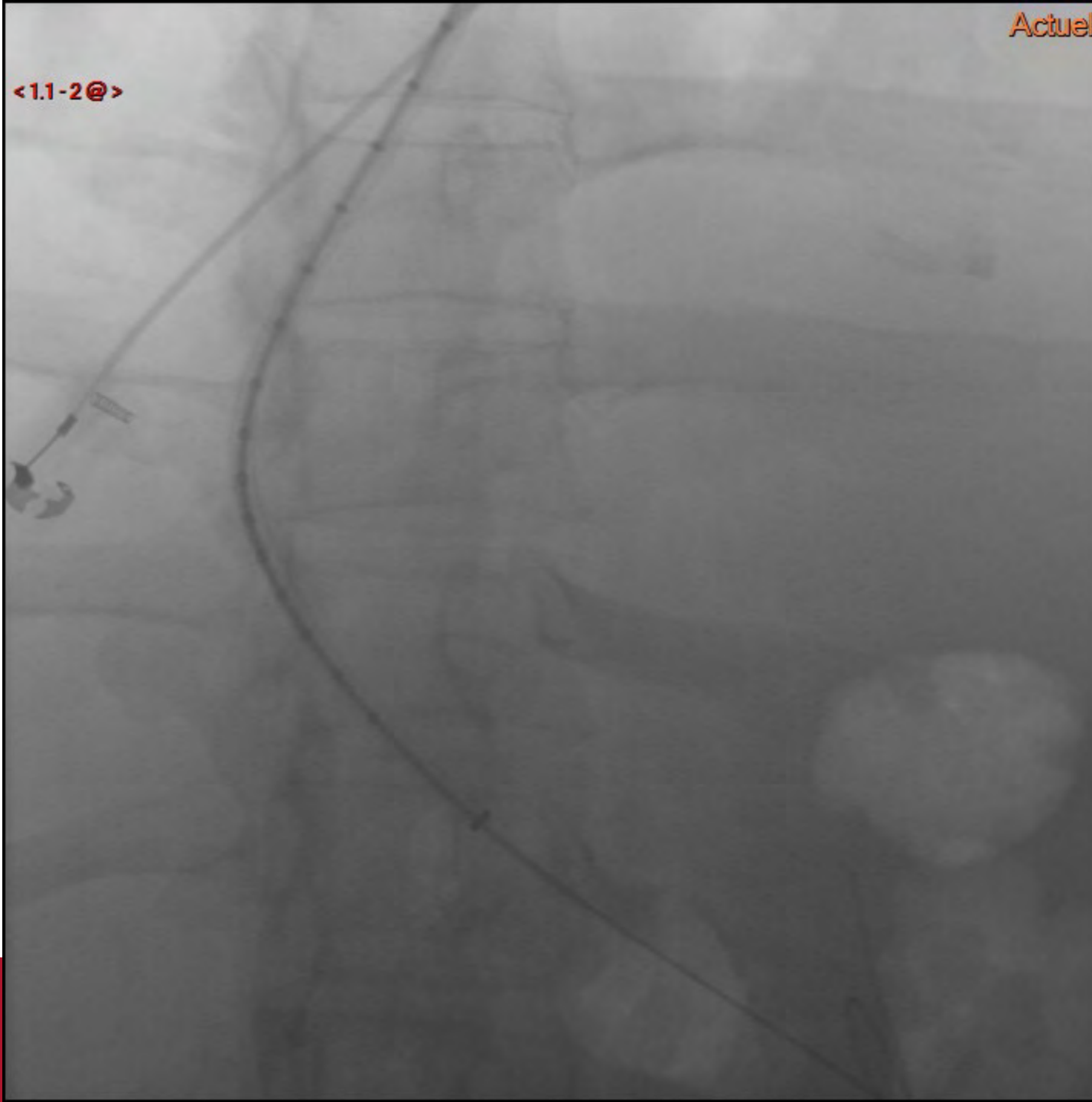
Décision RCP

- TIPS puis TH si besoin

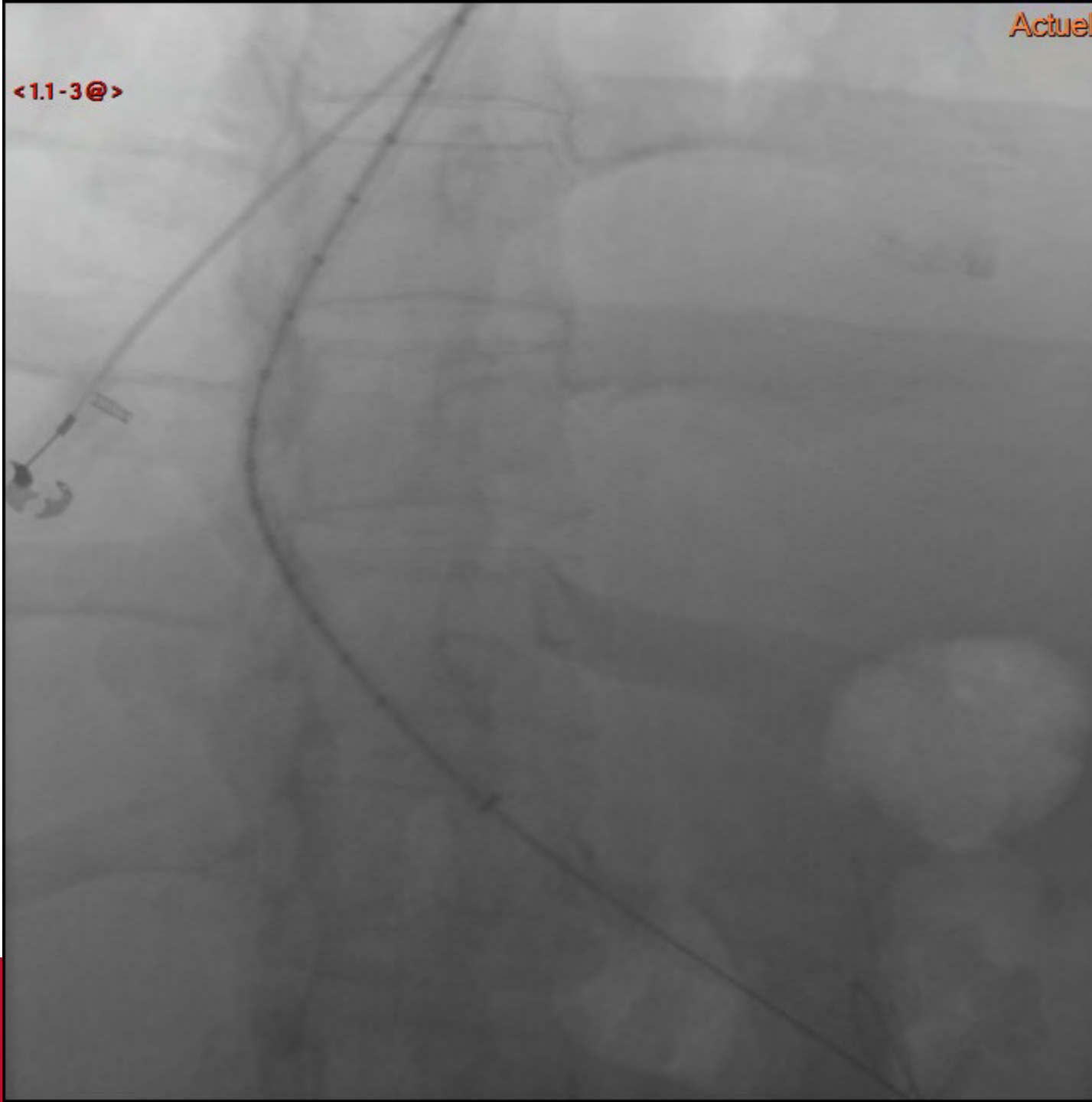<1.1-1@>



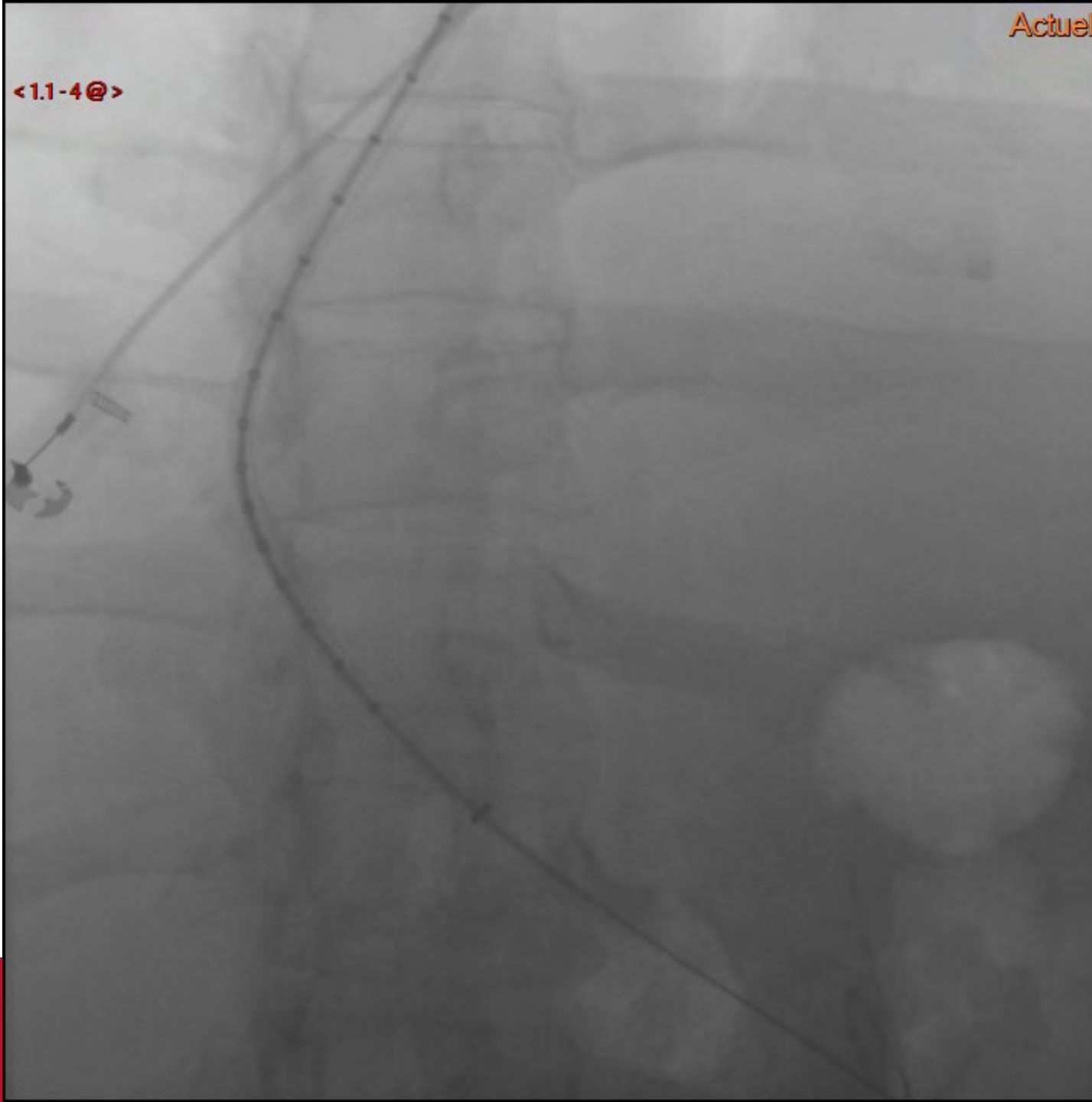
<1.1-2@>



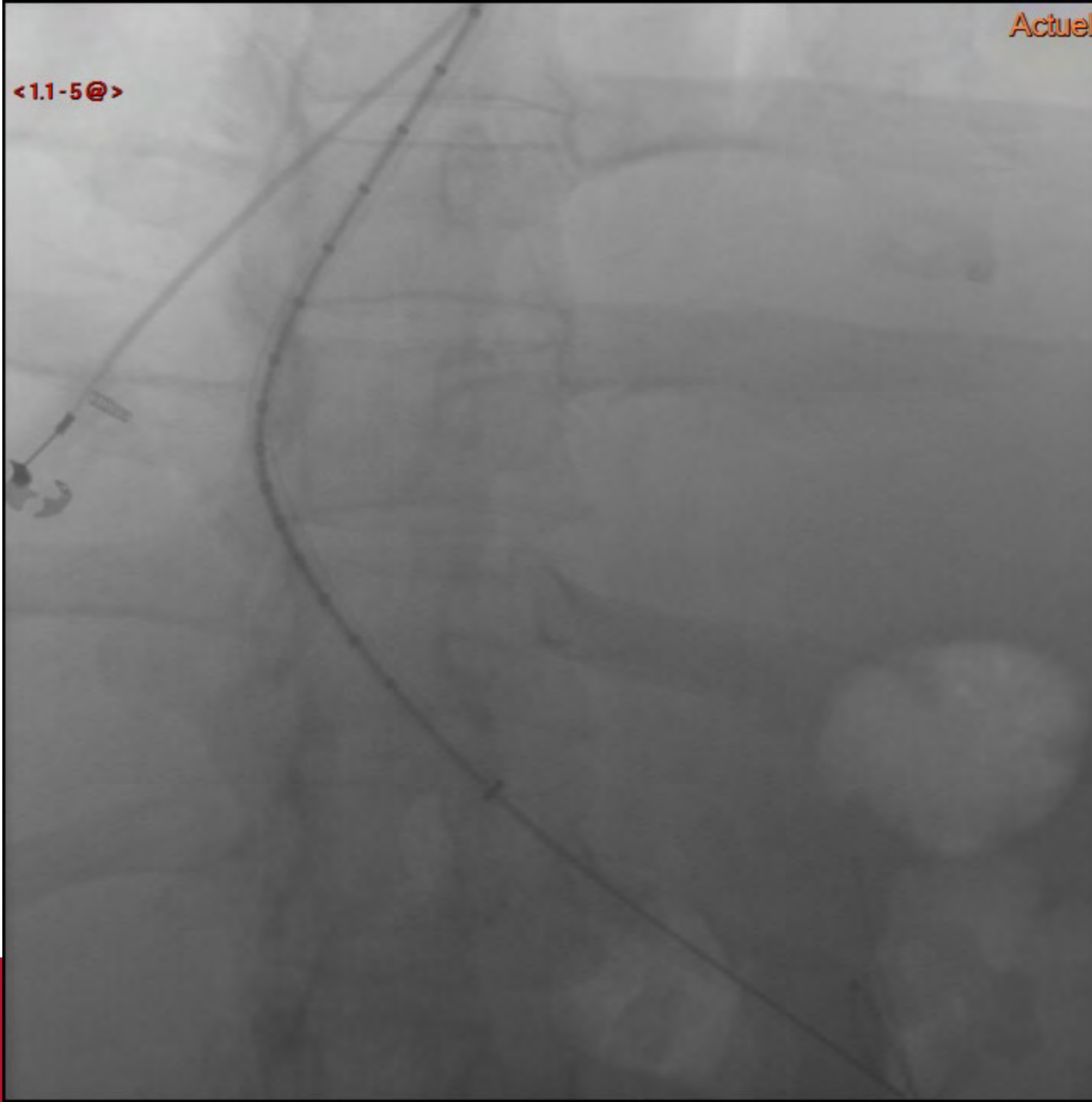
<1.1-3@>



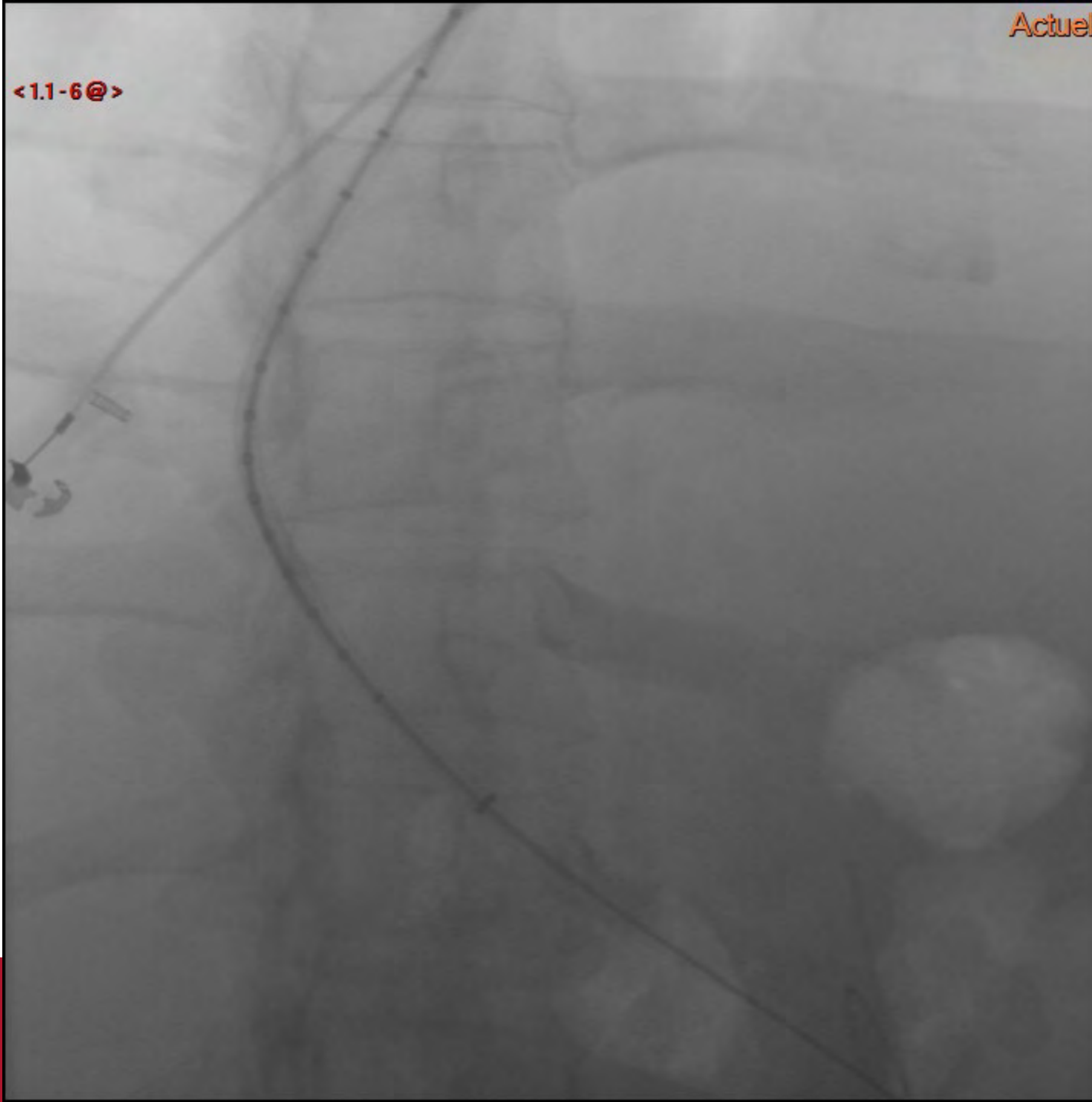<1.1-4@>



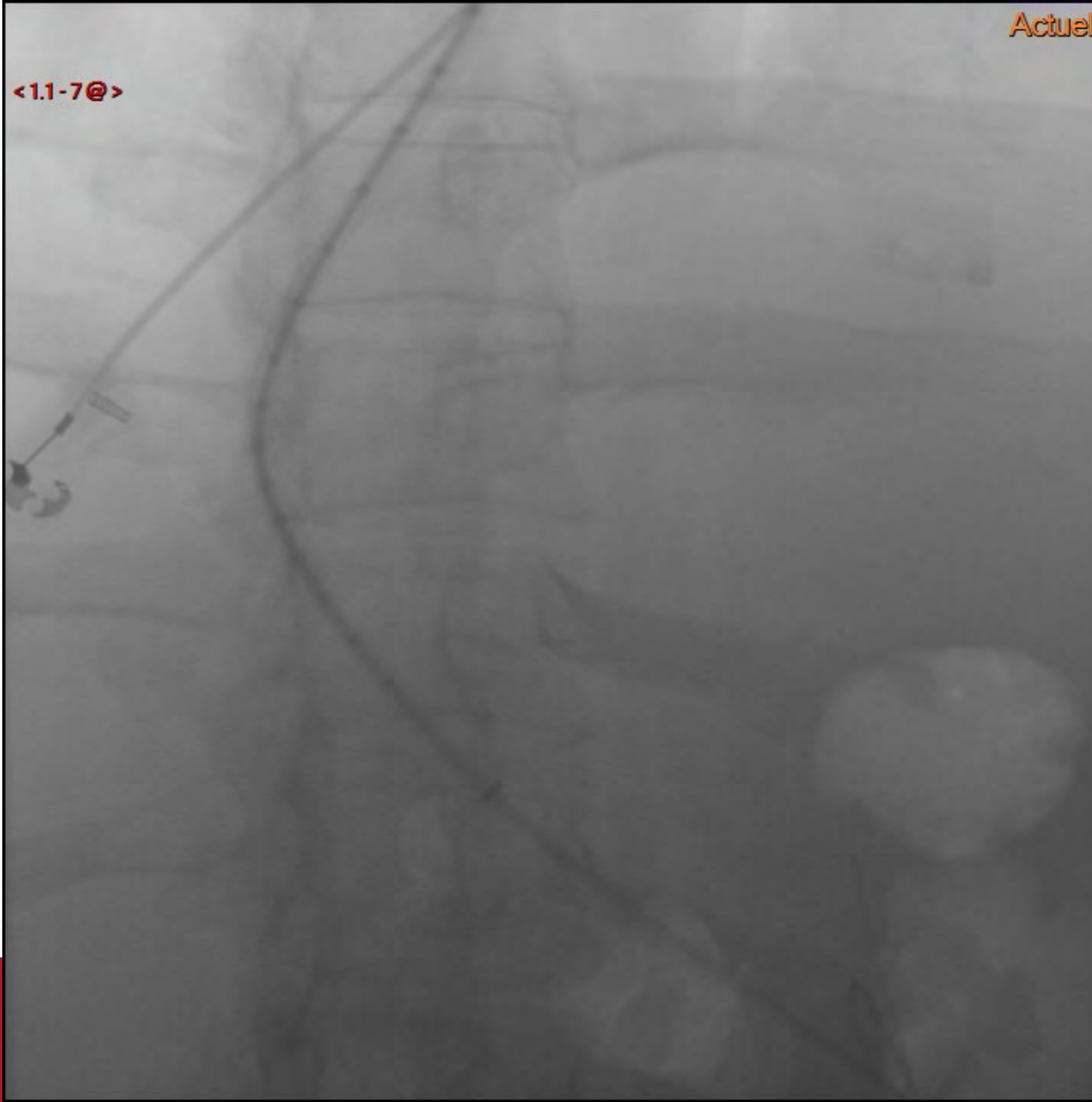
<1.1-5@>



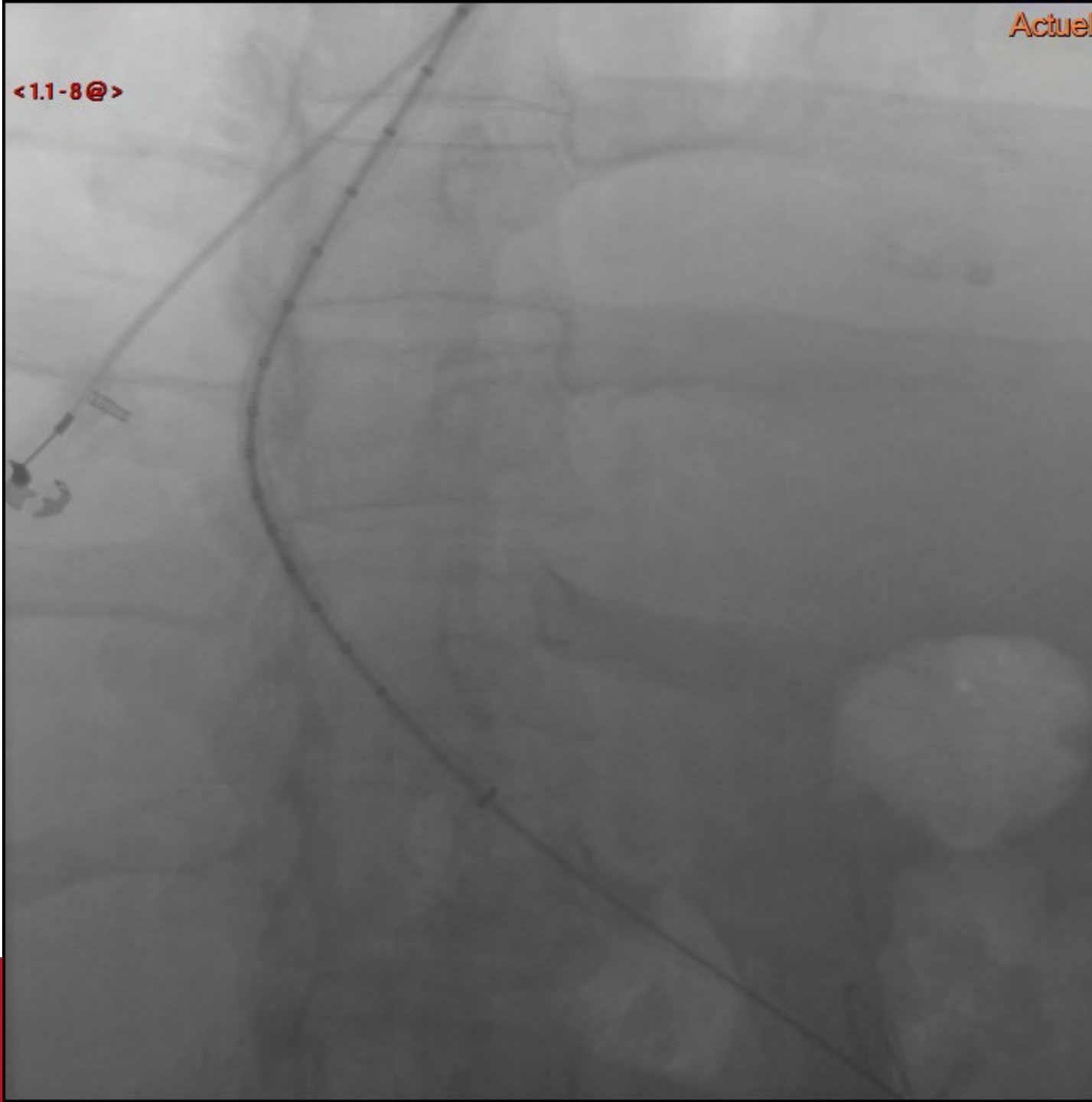<1.1-6@>



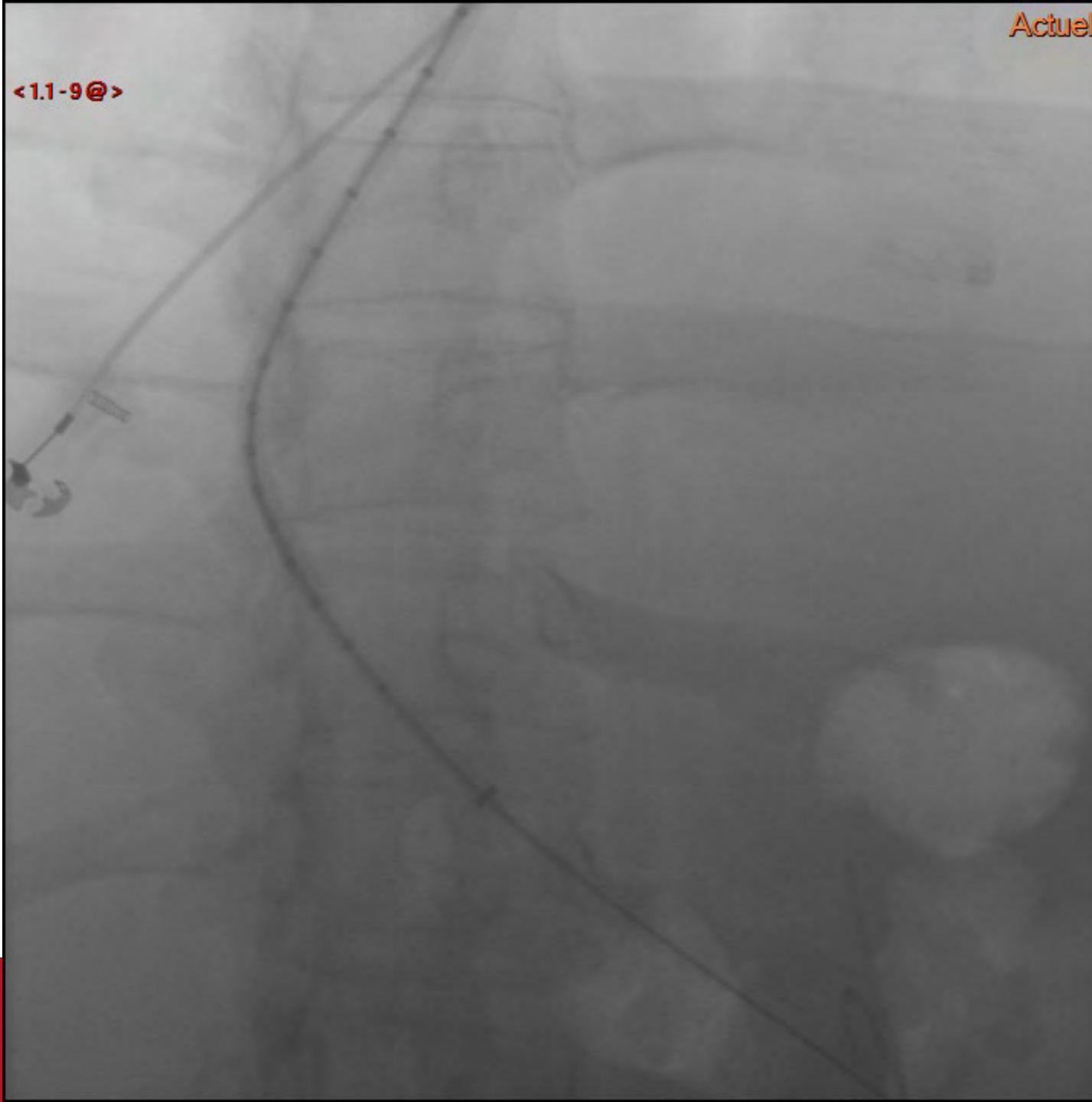
<1.1-7@>



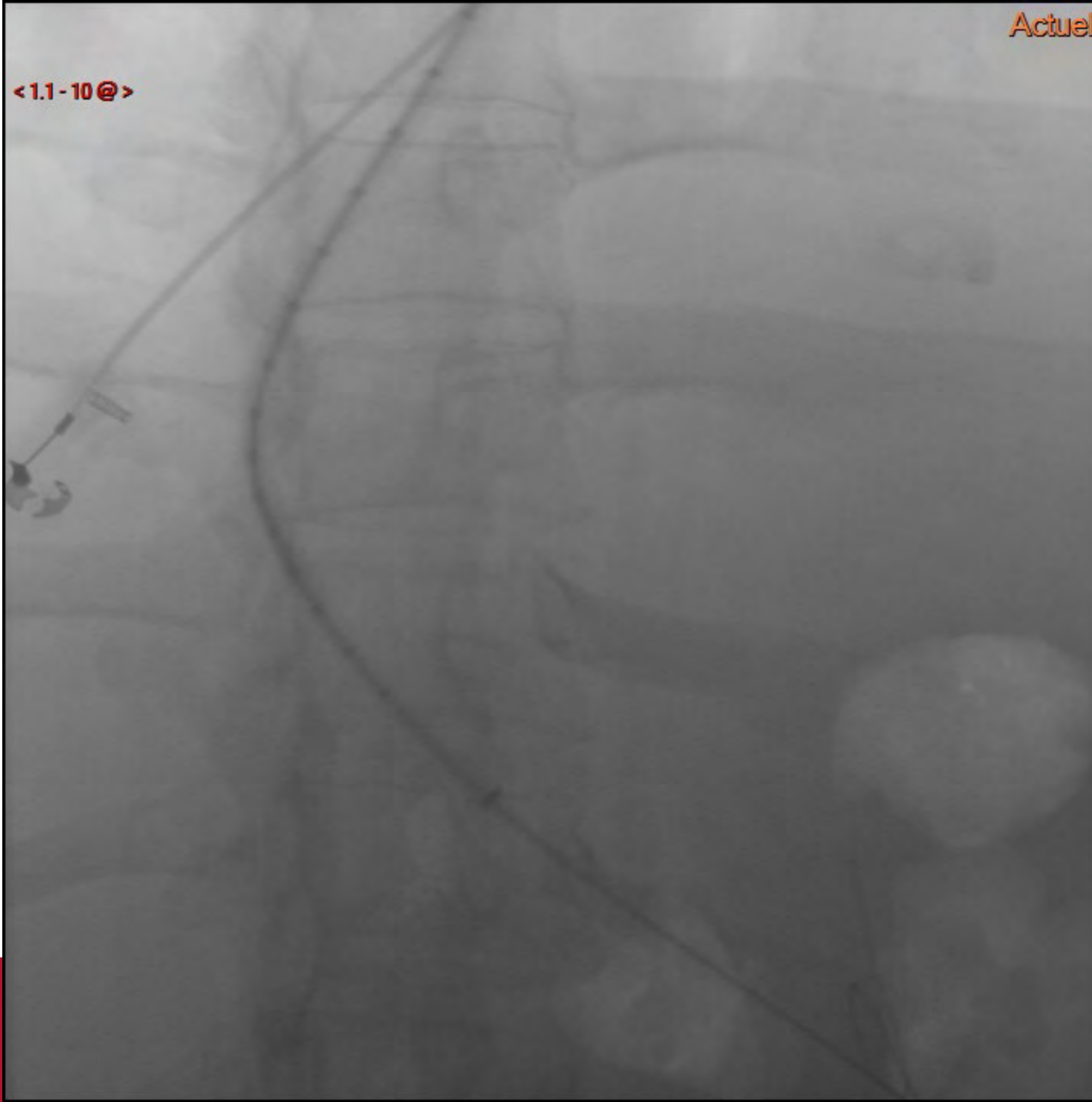
<1.1-8@>



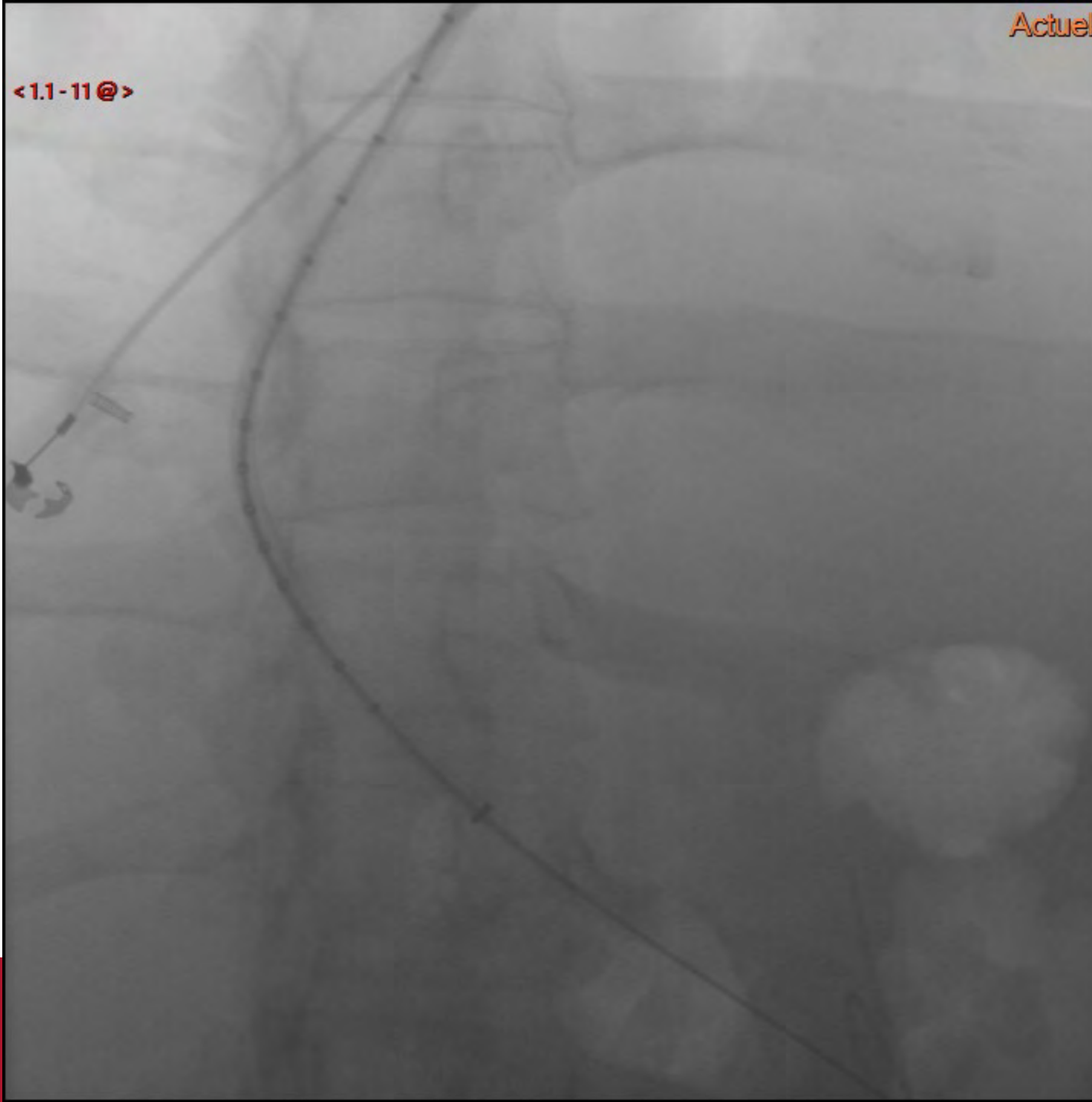
<1.1-9@>



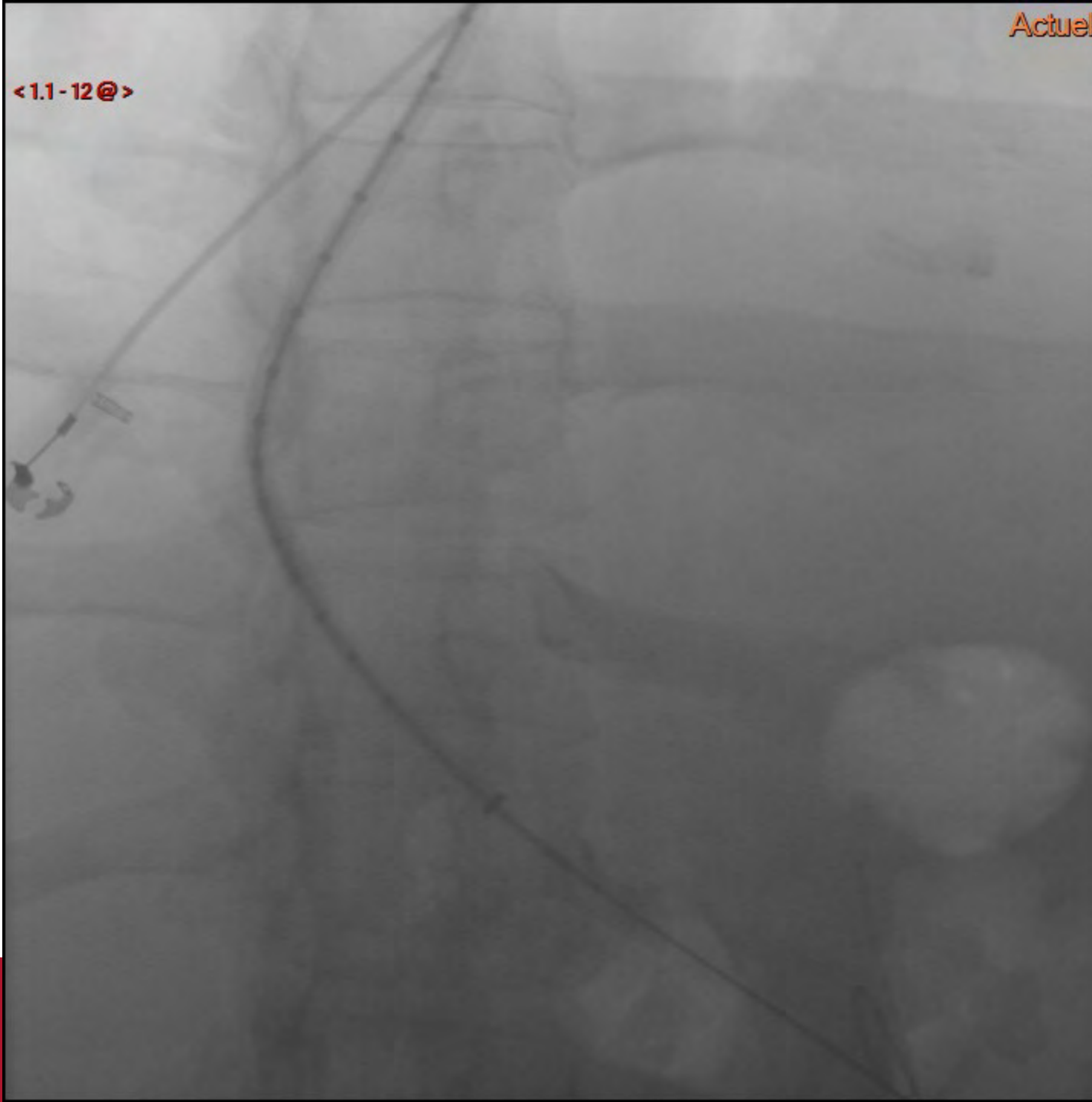
<1.1-10@>



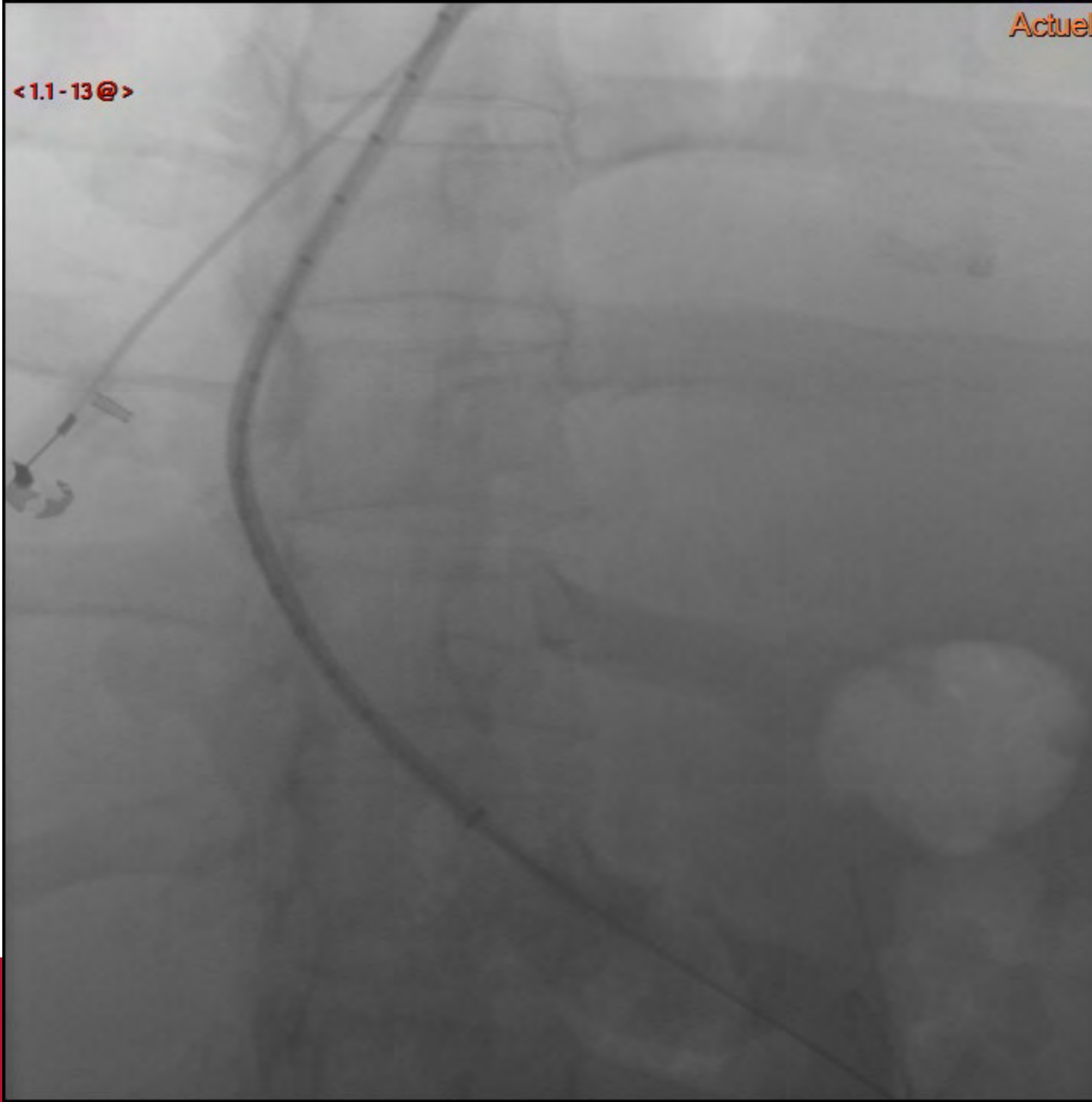
<1.1-11@>



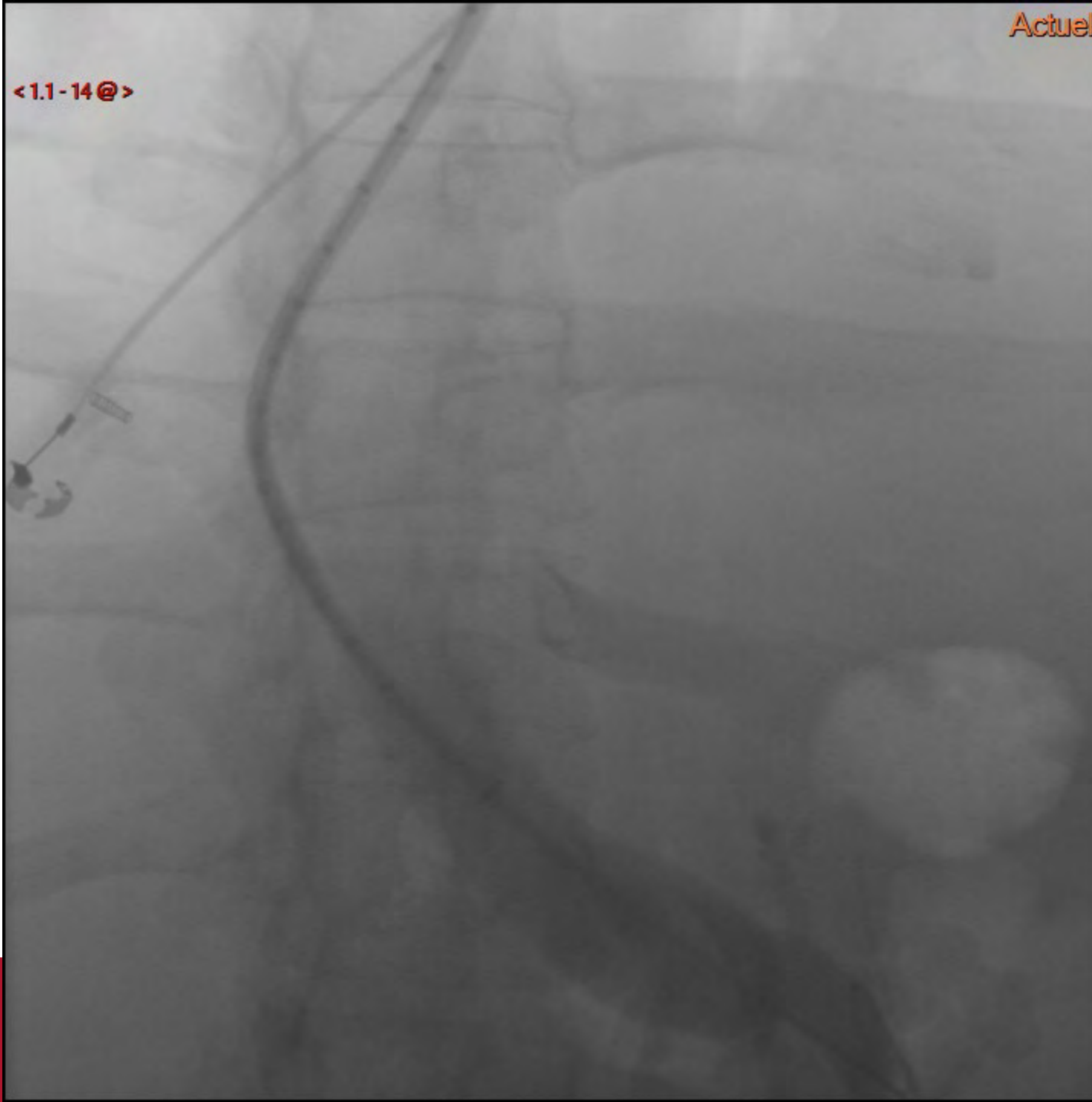
<1.1-12@>



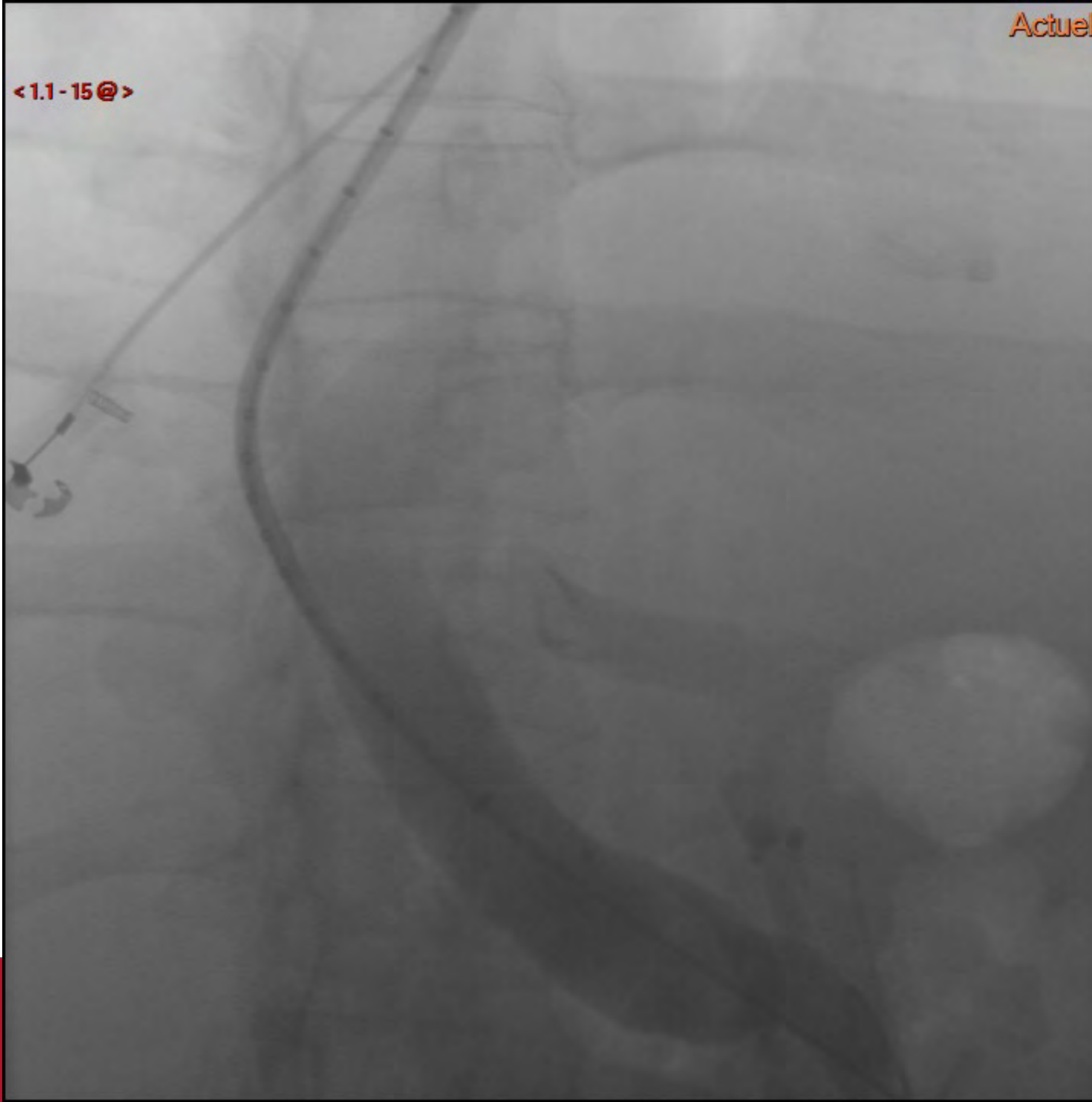<1.1-13@>



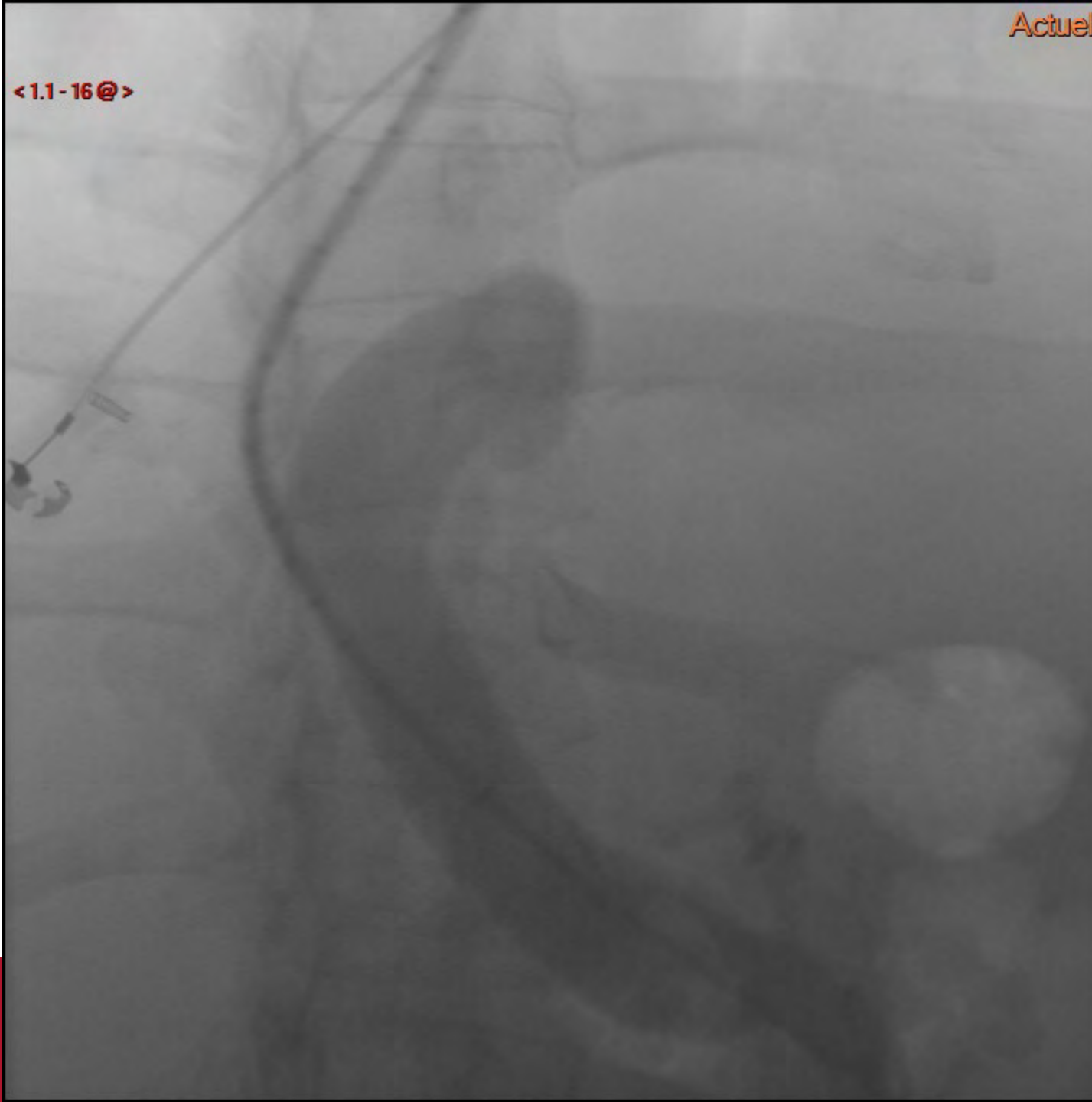
<1.1-14@>



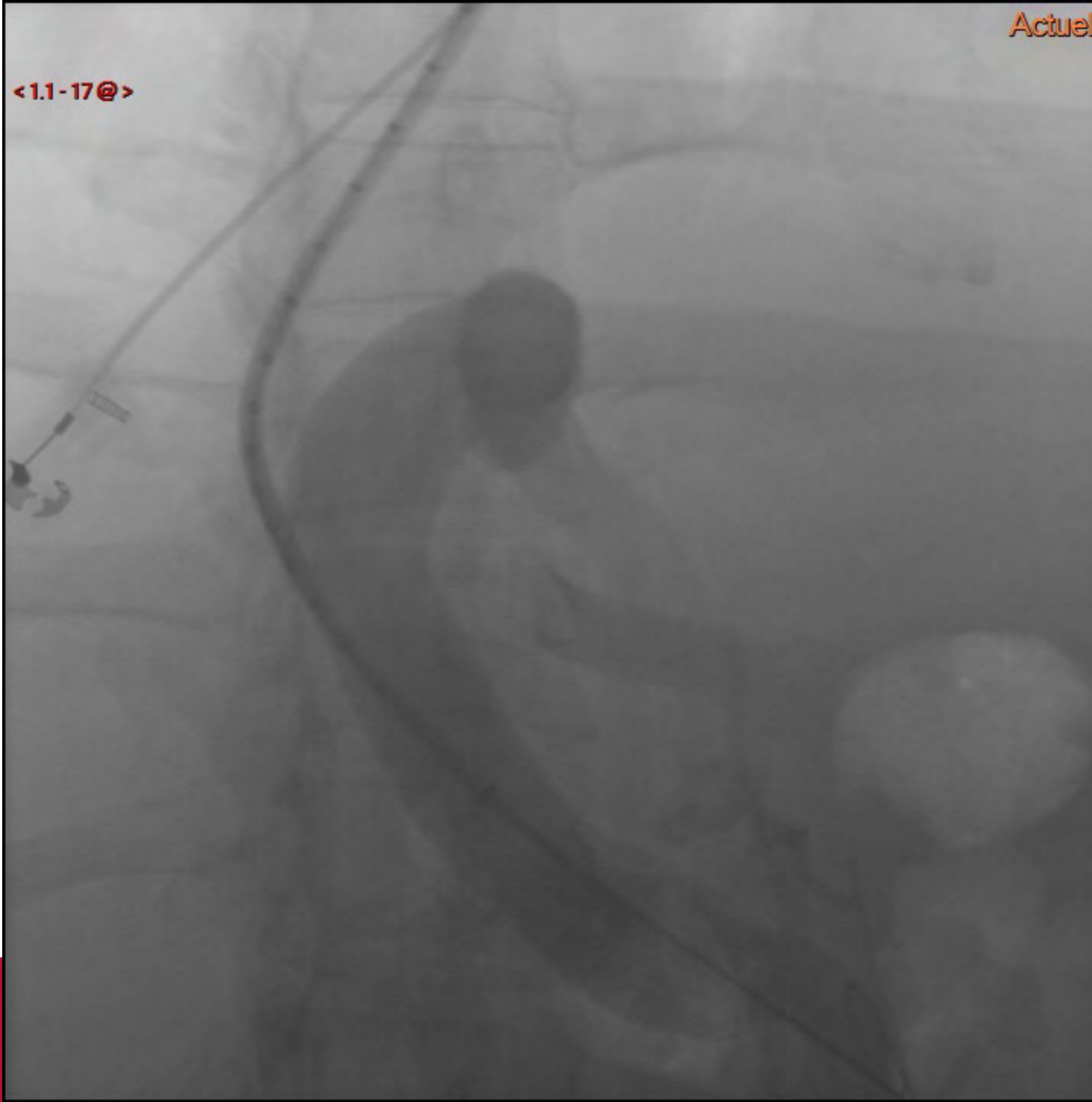
<1.1-15@>



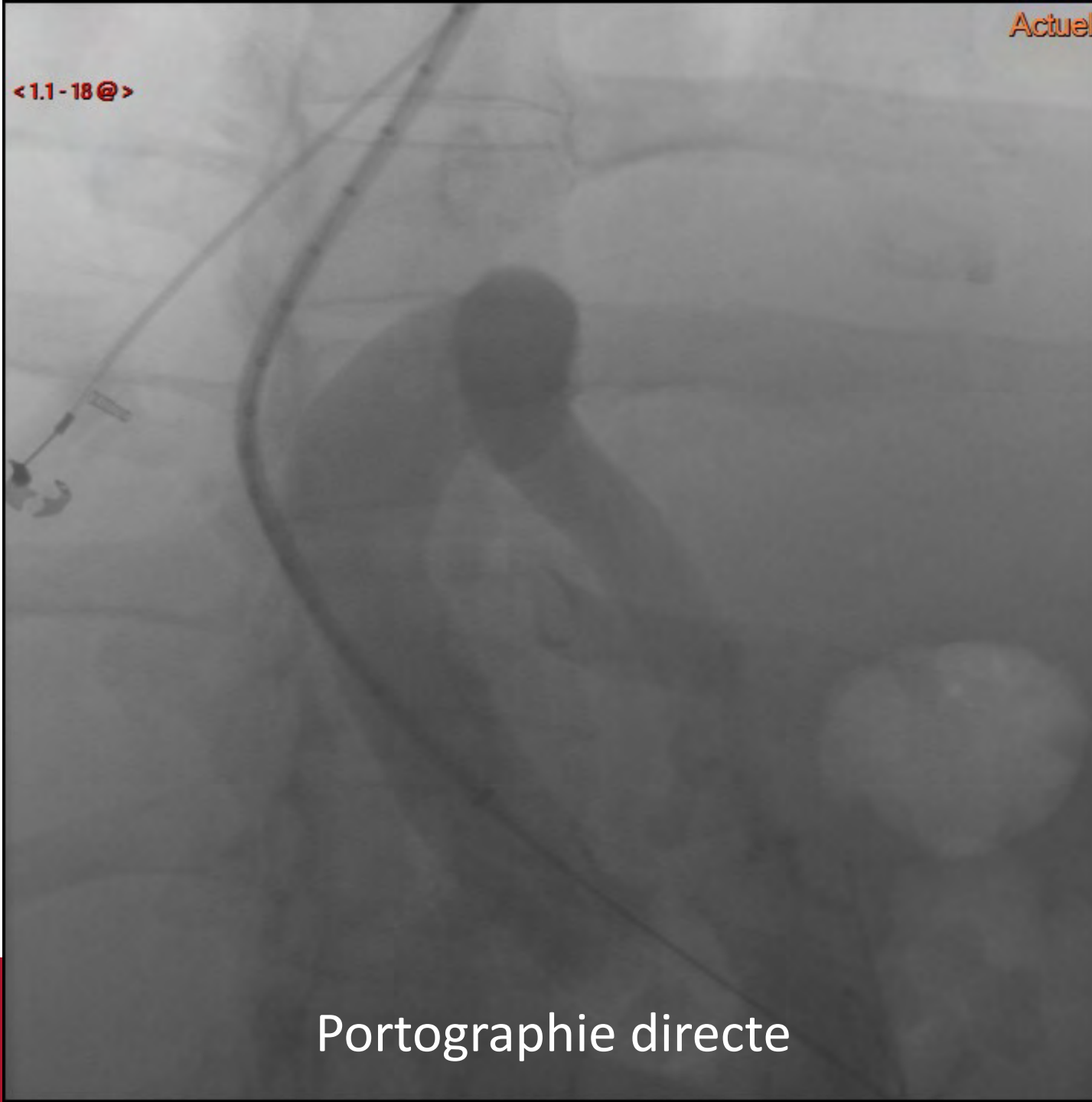<1.1-16@>



<1.1-17@>

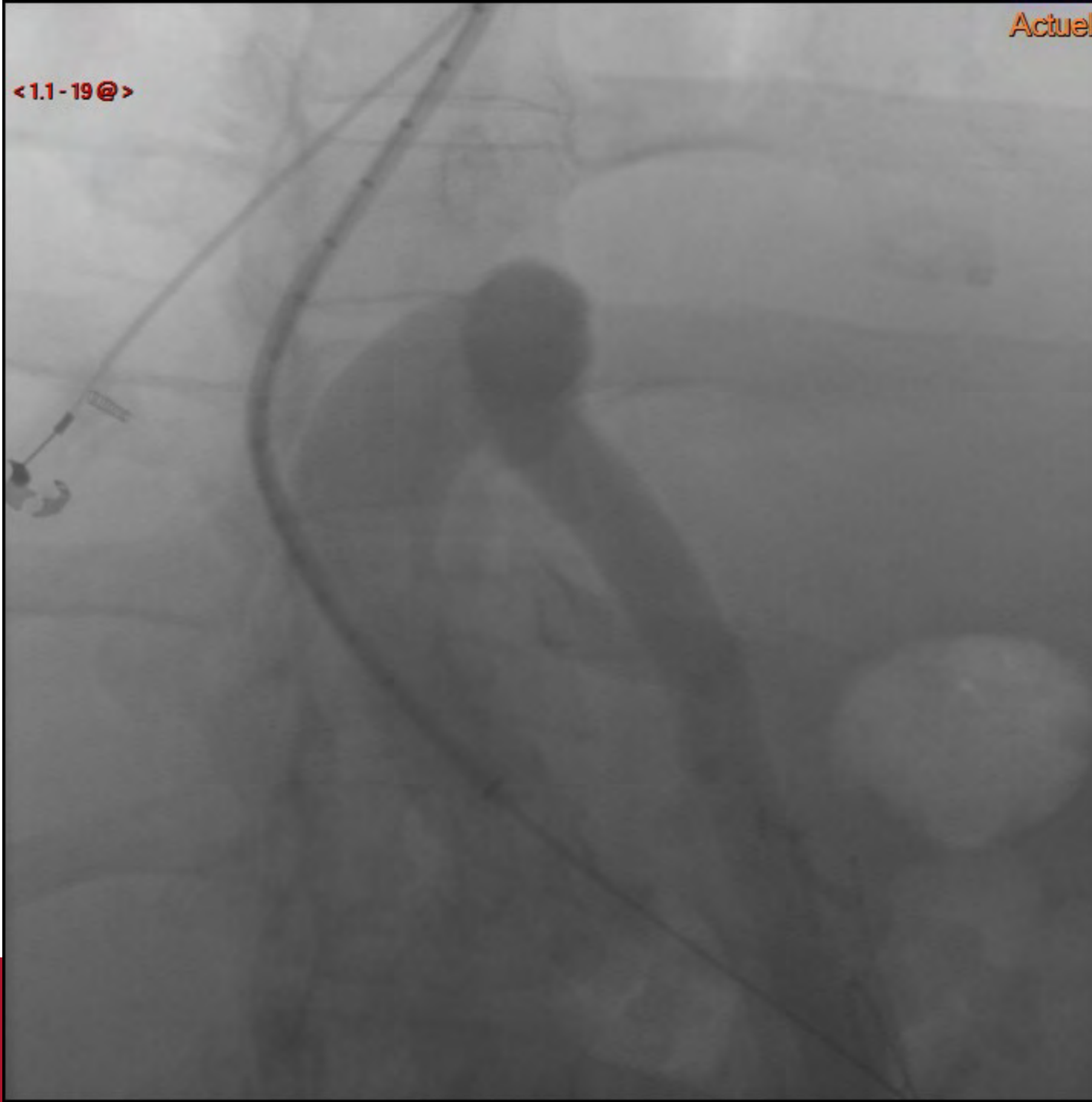


<1.1-18@>

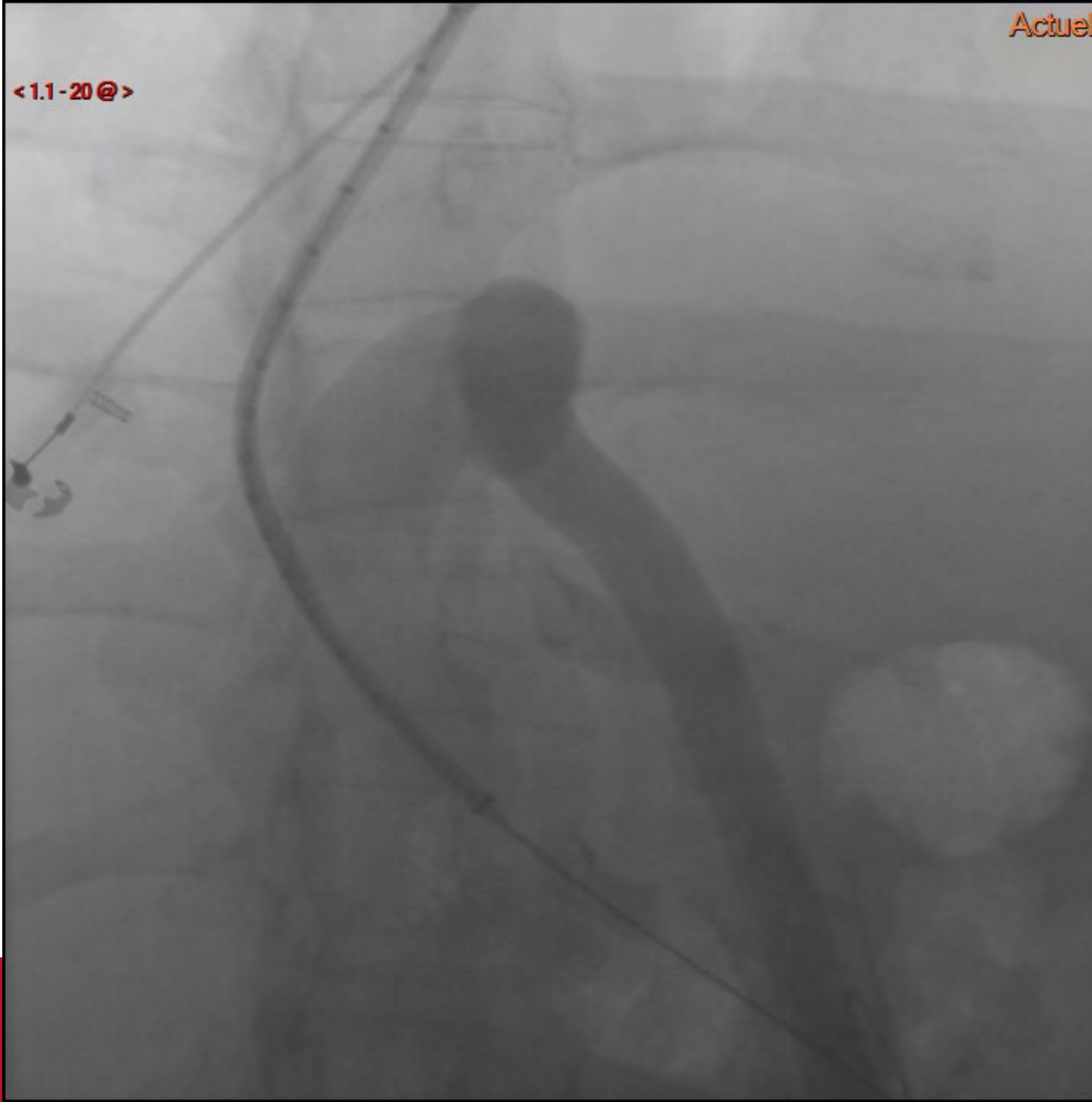


Portographie directe

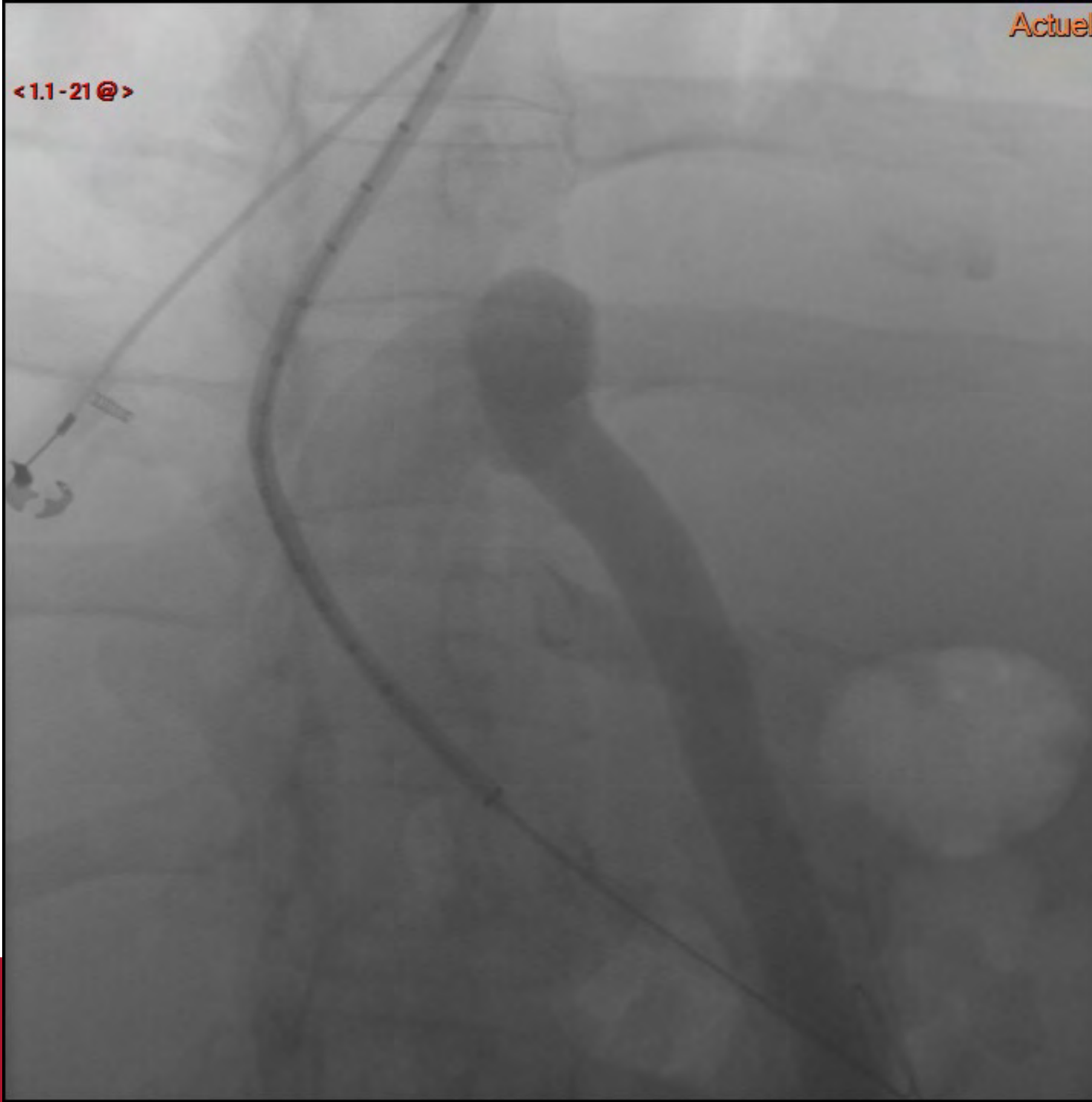
<1.1-19@>



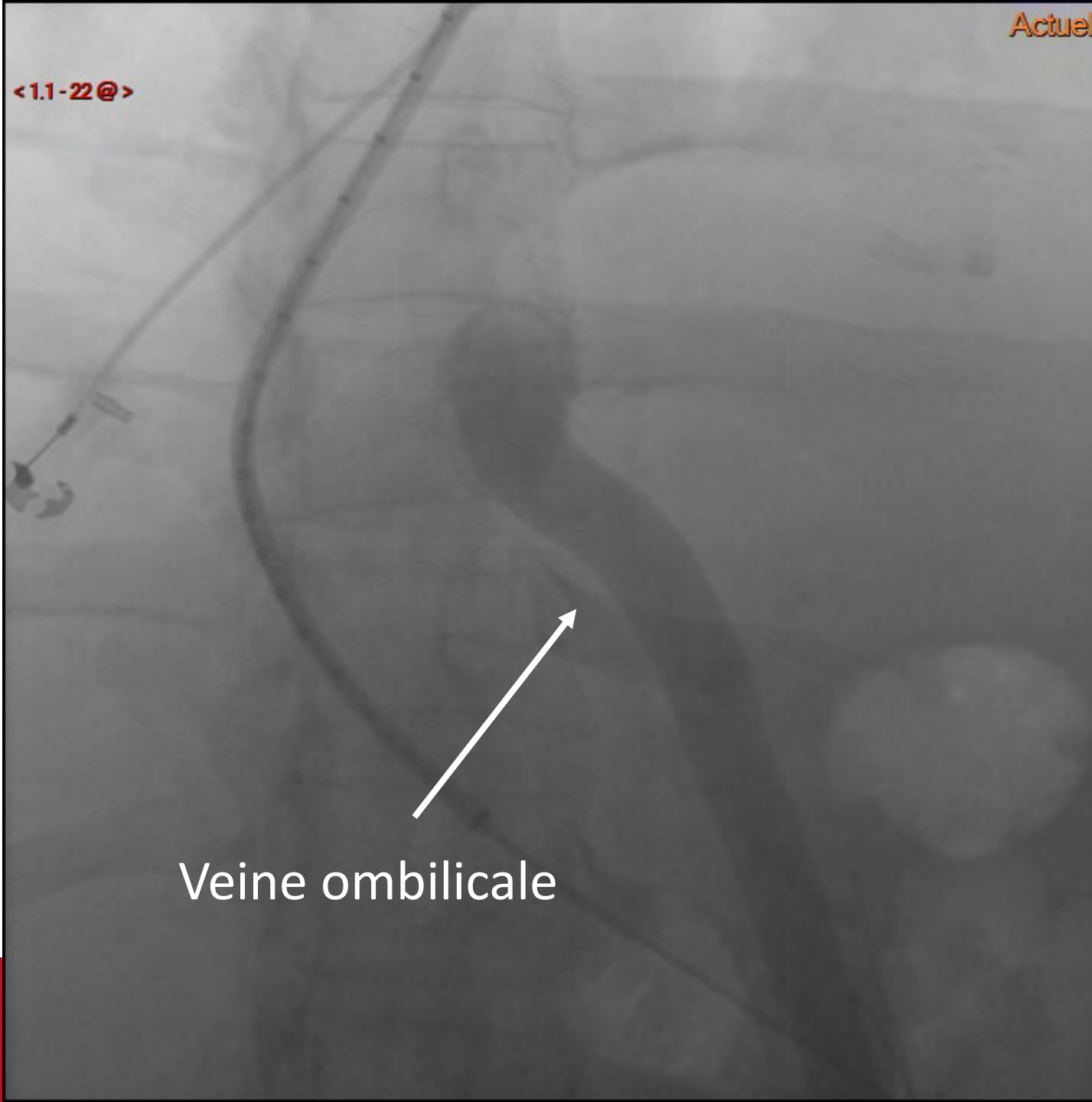
<1.1-20@>



<1.1-21@>

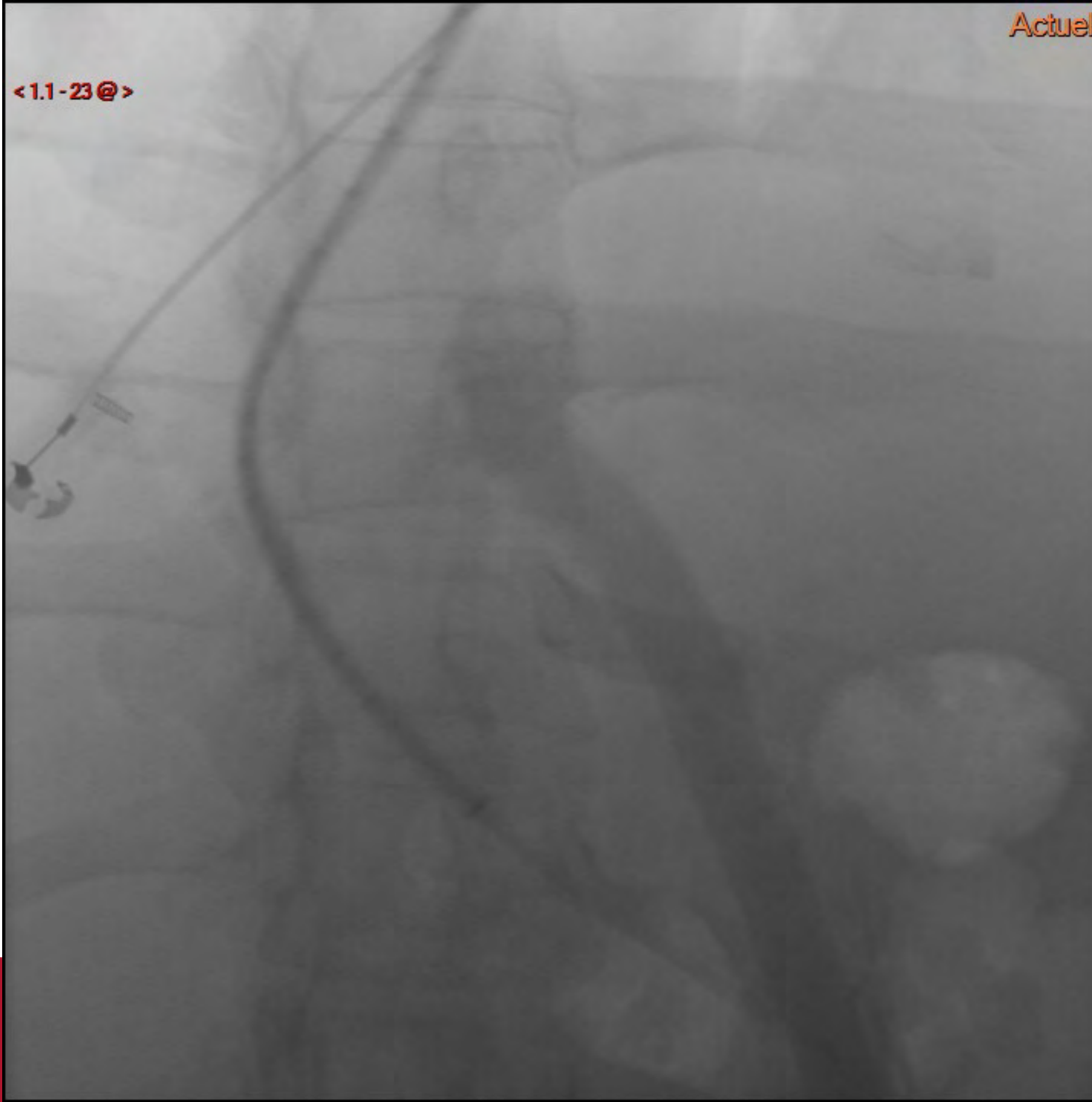


<1.1-22@>

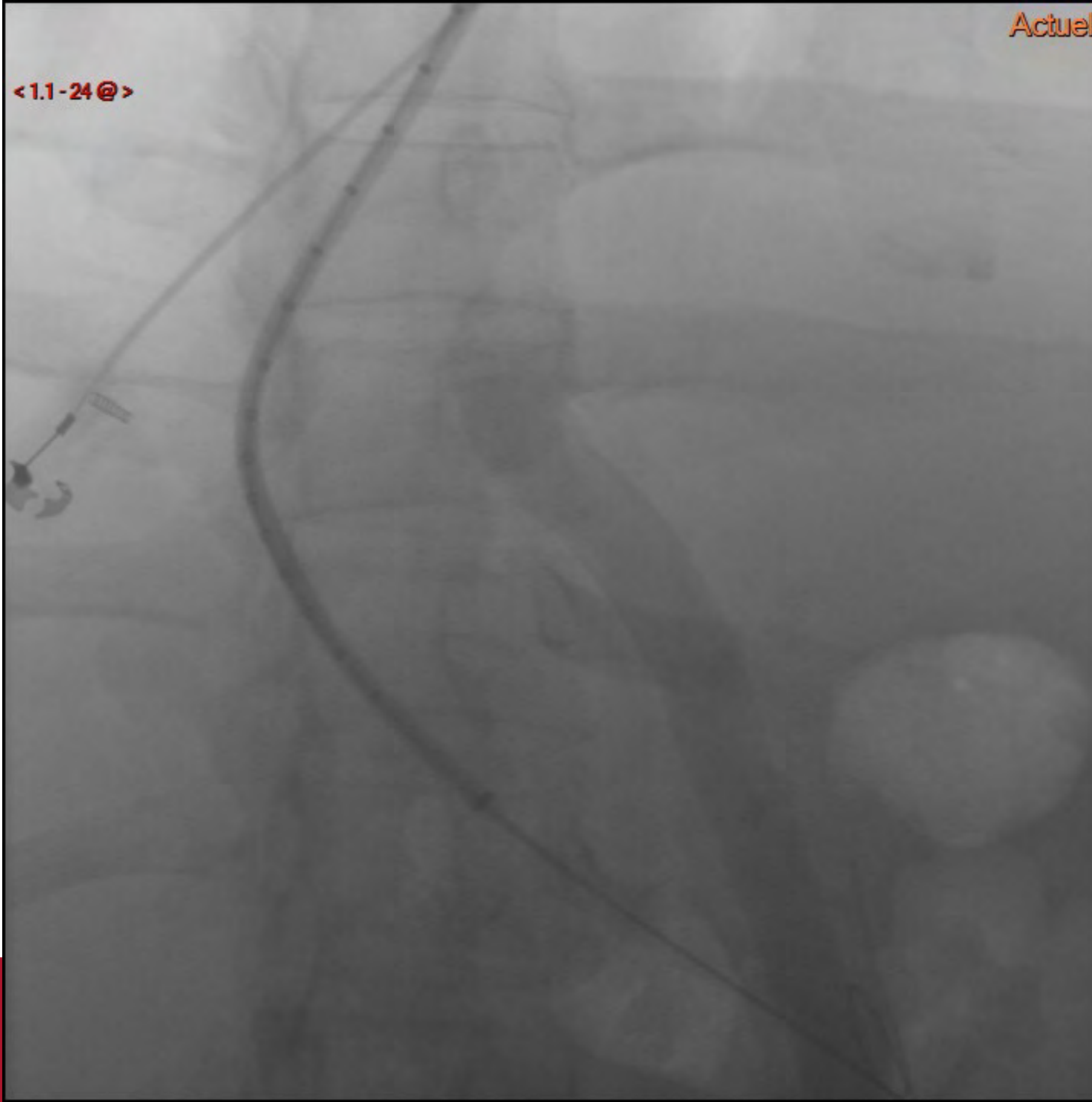


Veine ombilicale

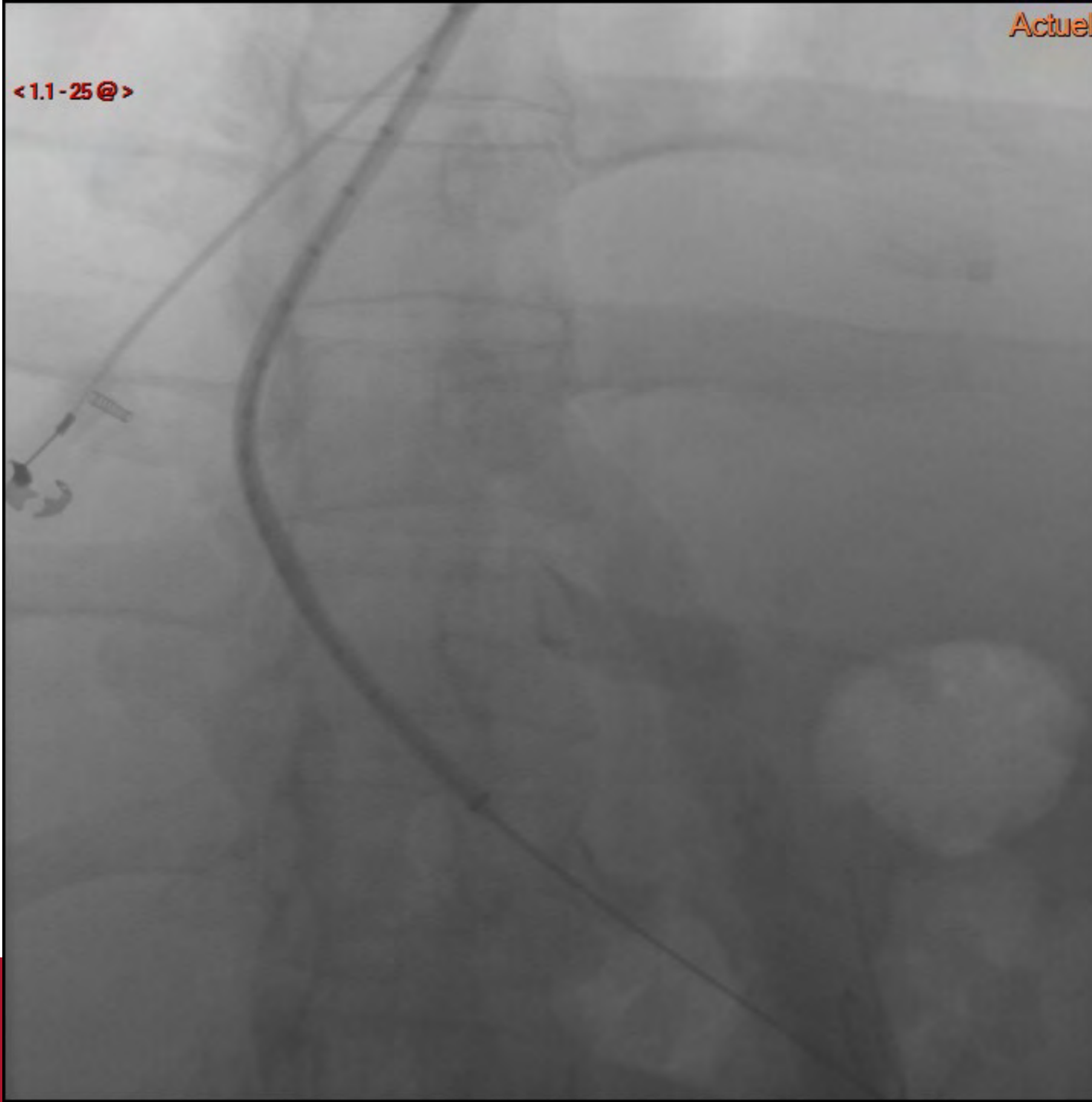
<1.1-23@>



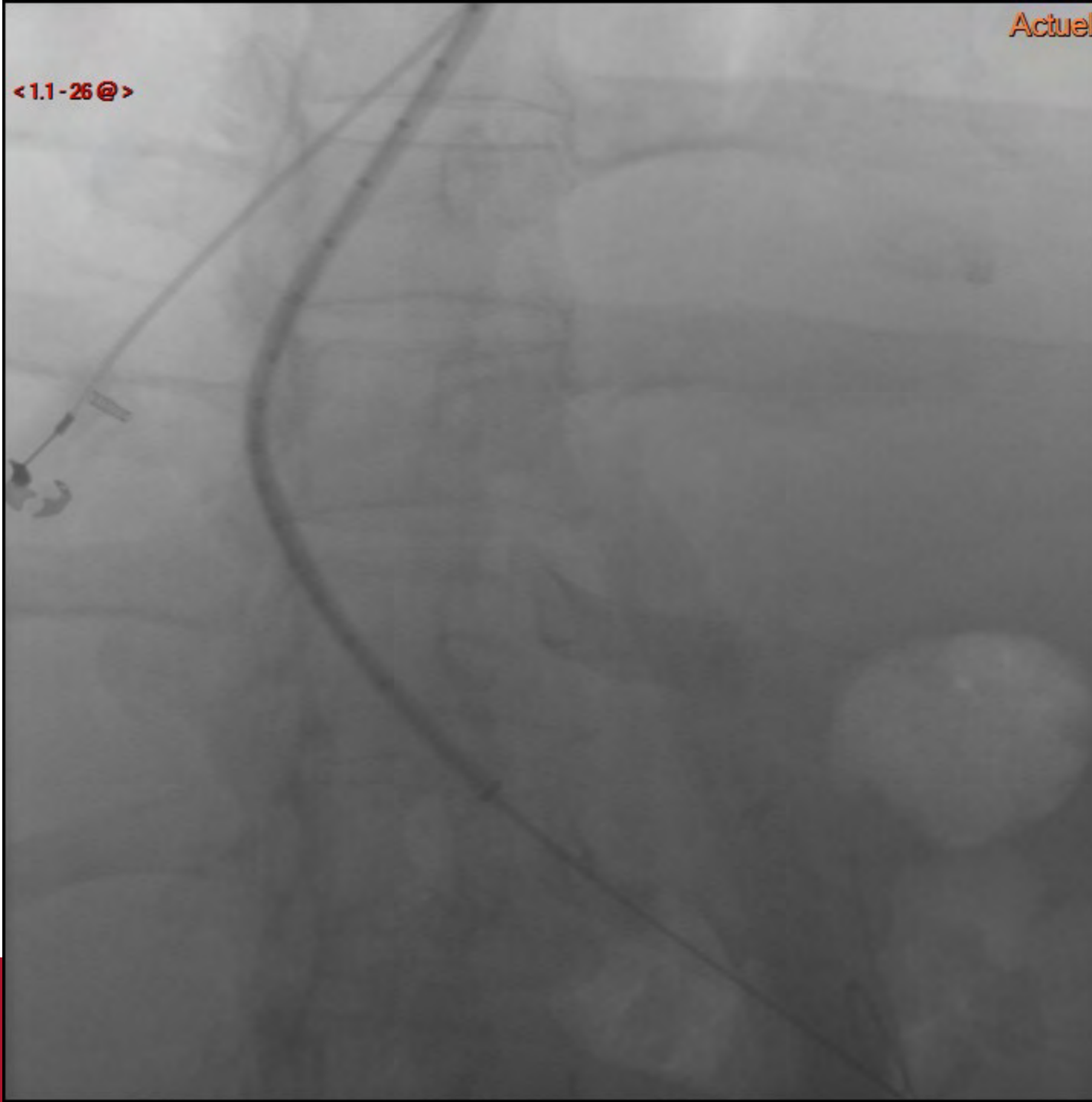
<1.1-24@>



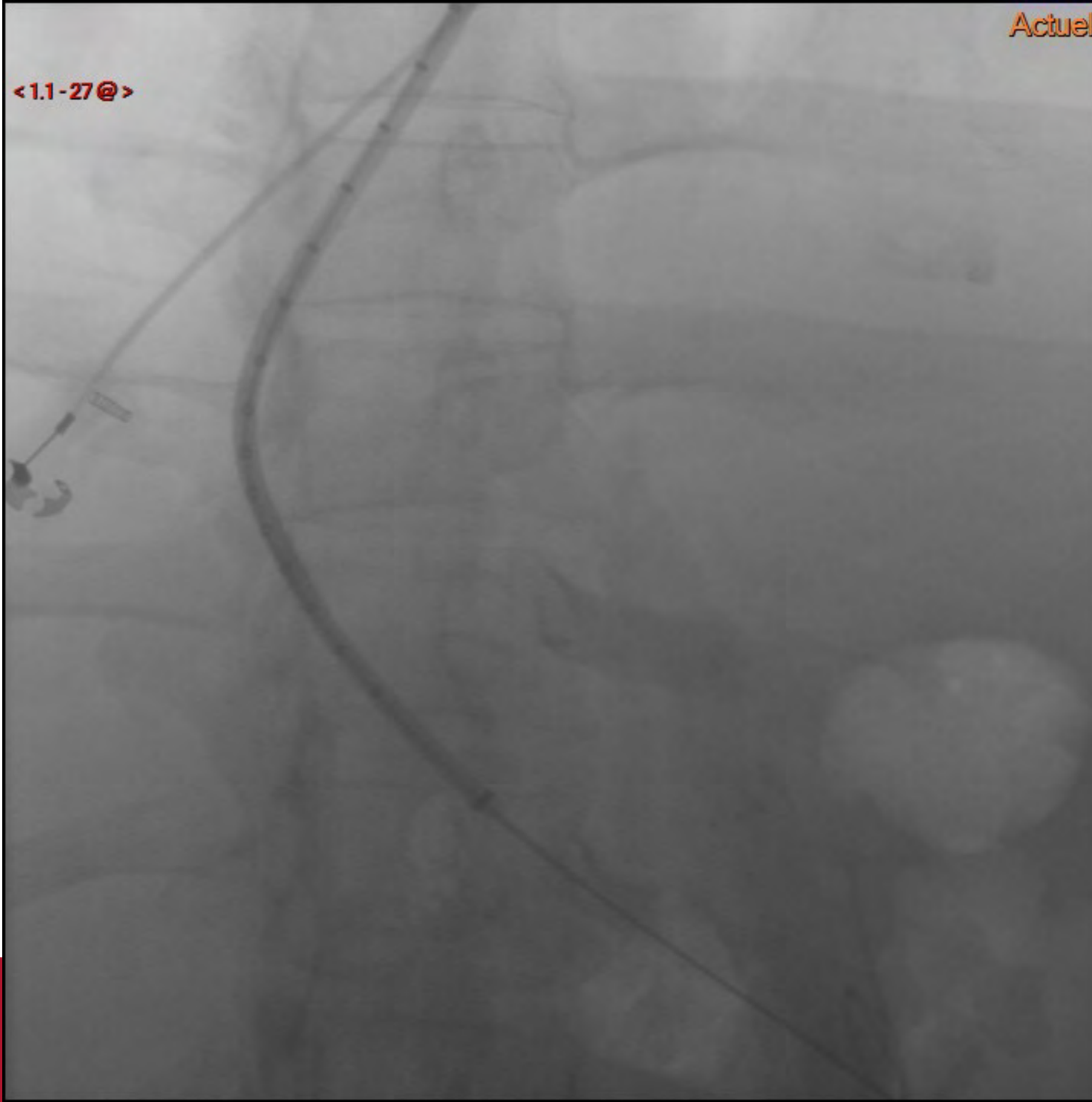
<1.1-25@>



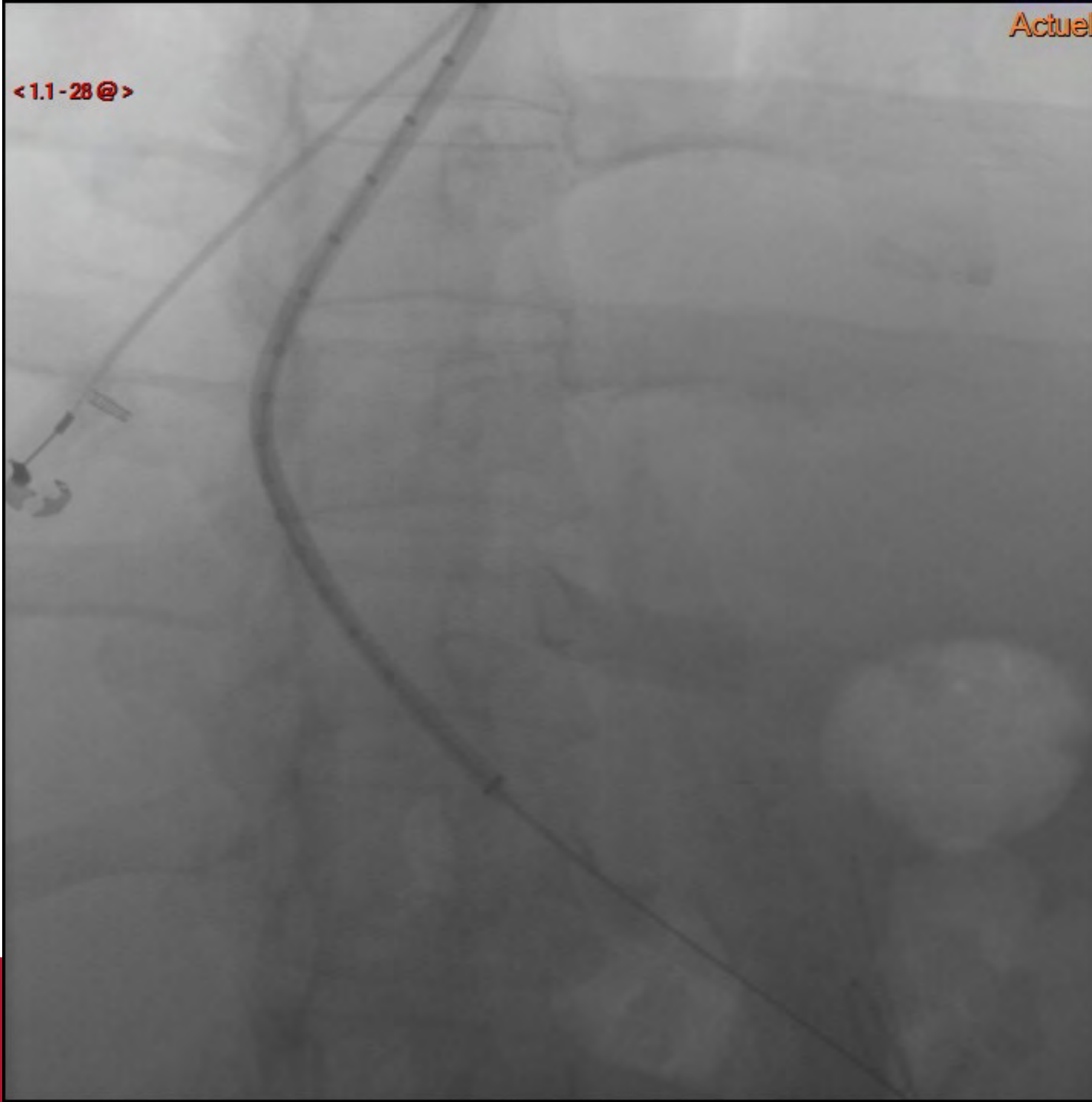
<1.1-26@>



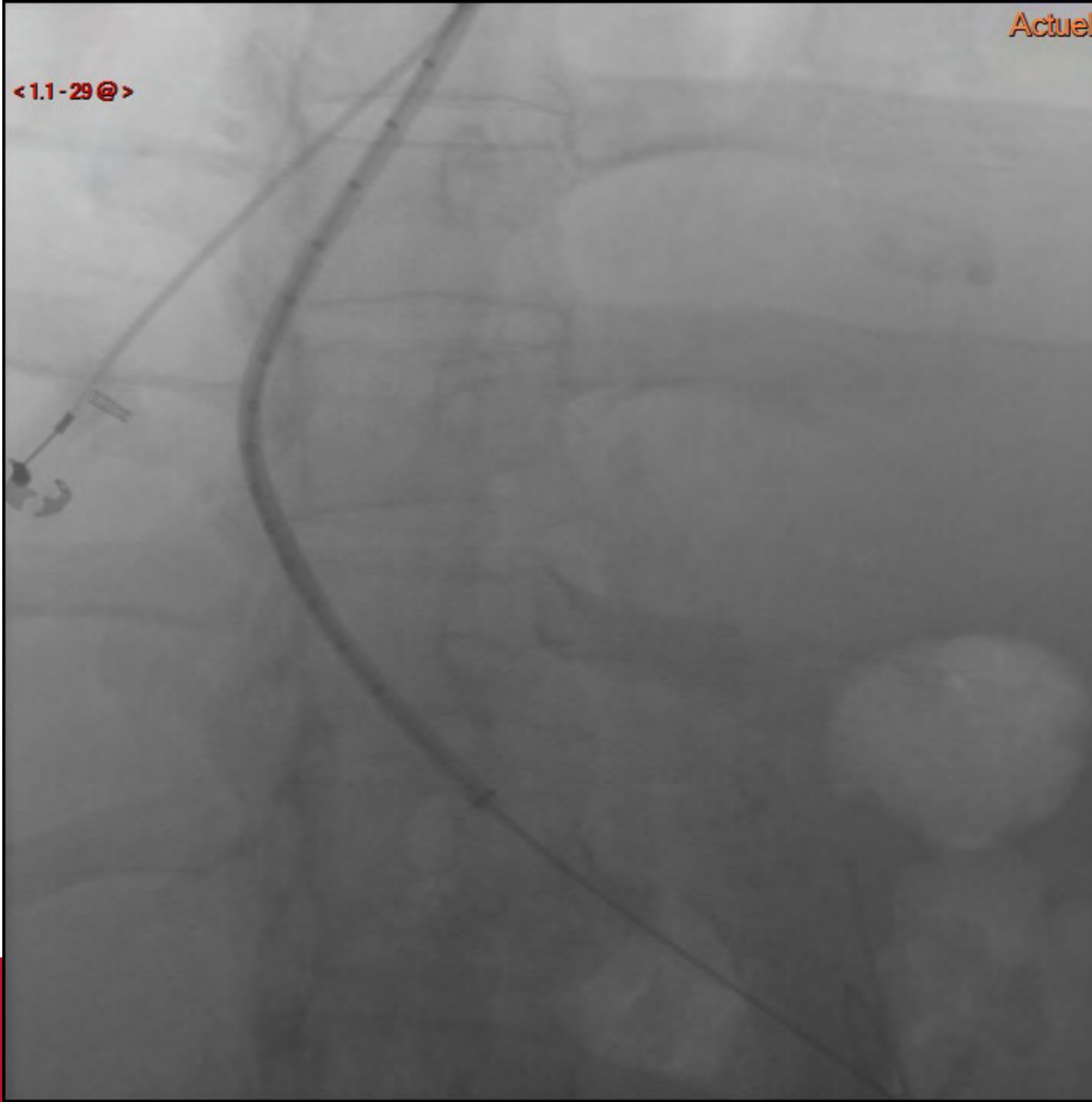
<1.1-27@>



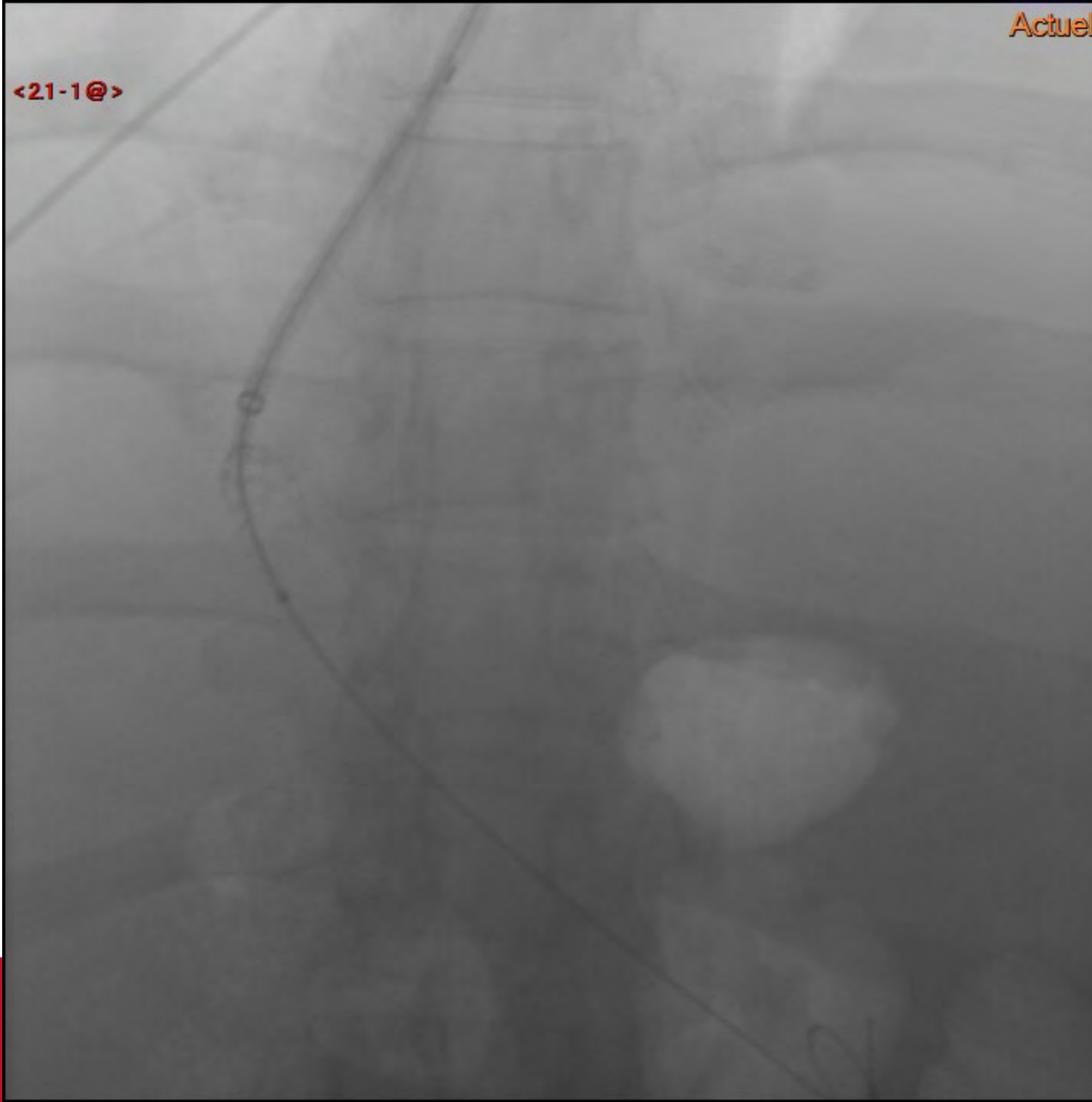<1.1-28@>



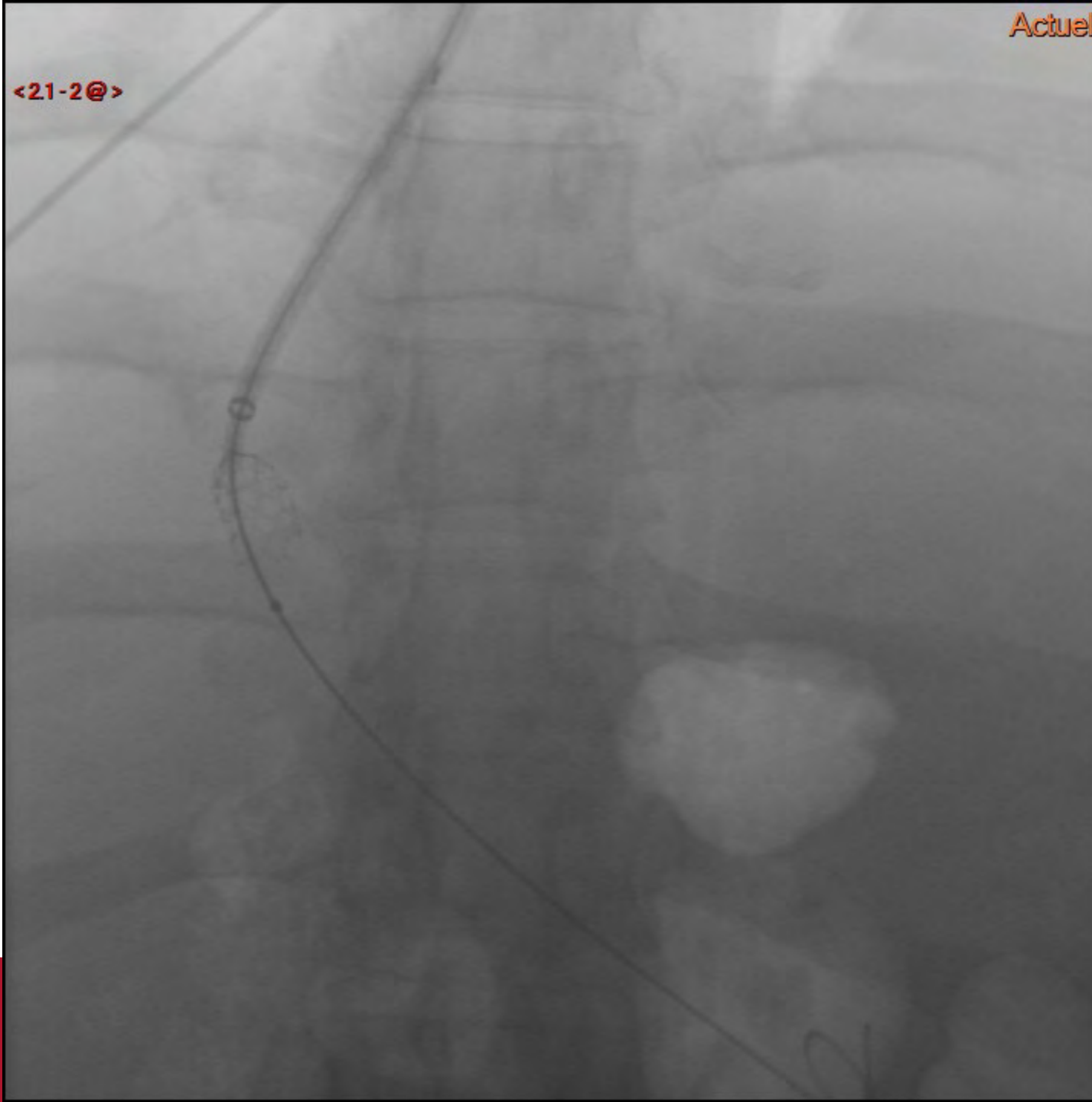
<1.1-29@>



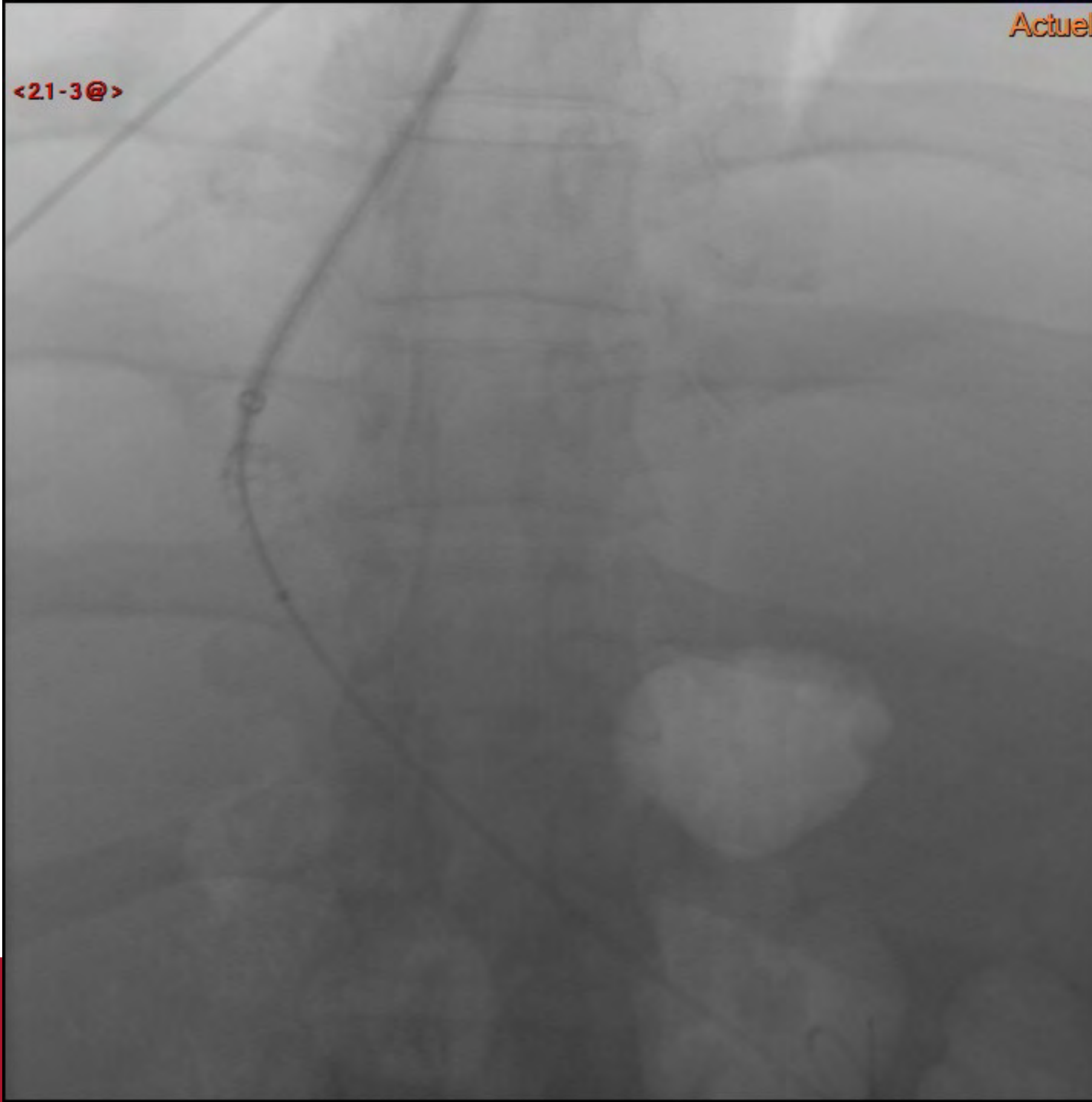
<21-1@>



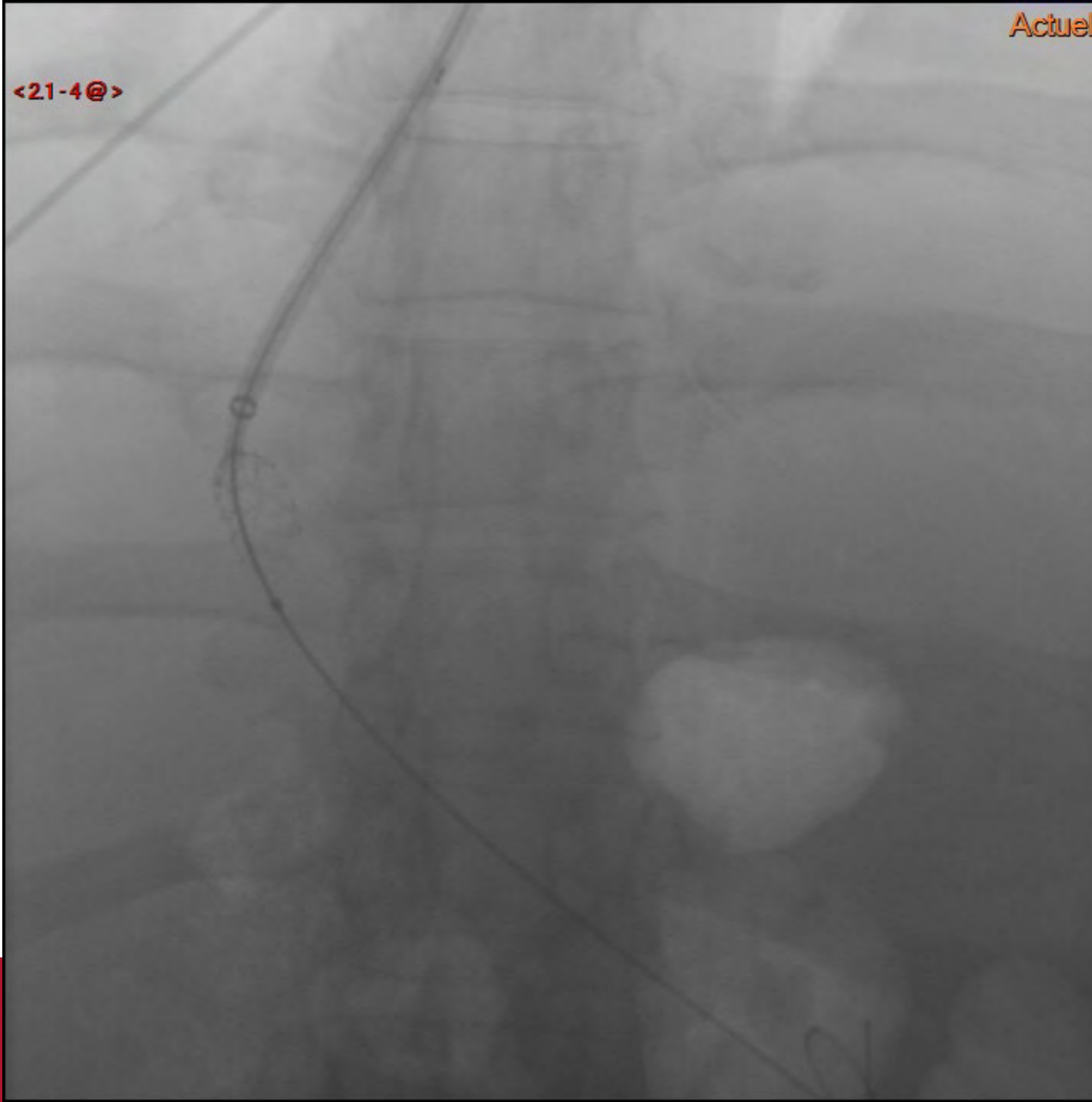
<21-2@>



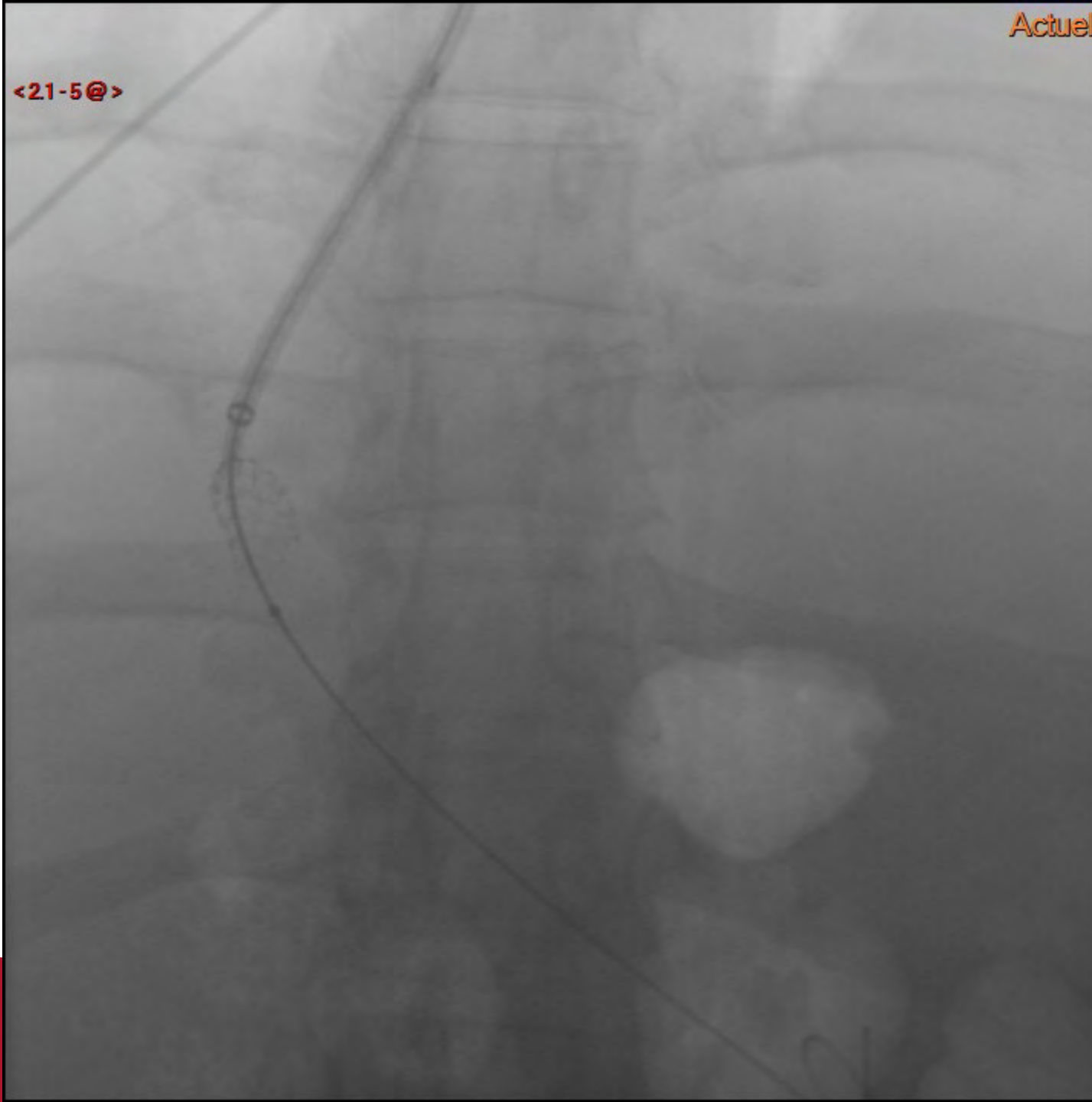
<21-3@>



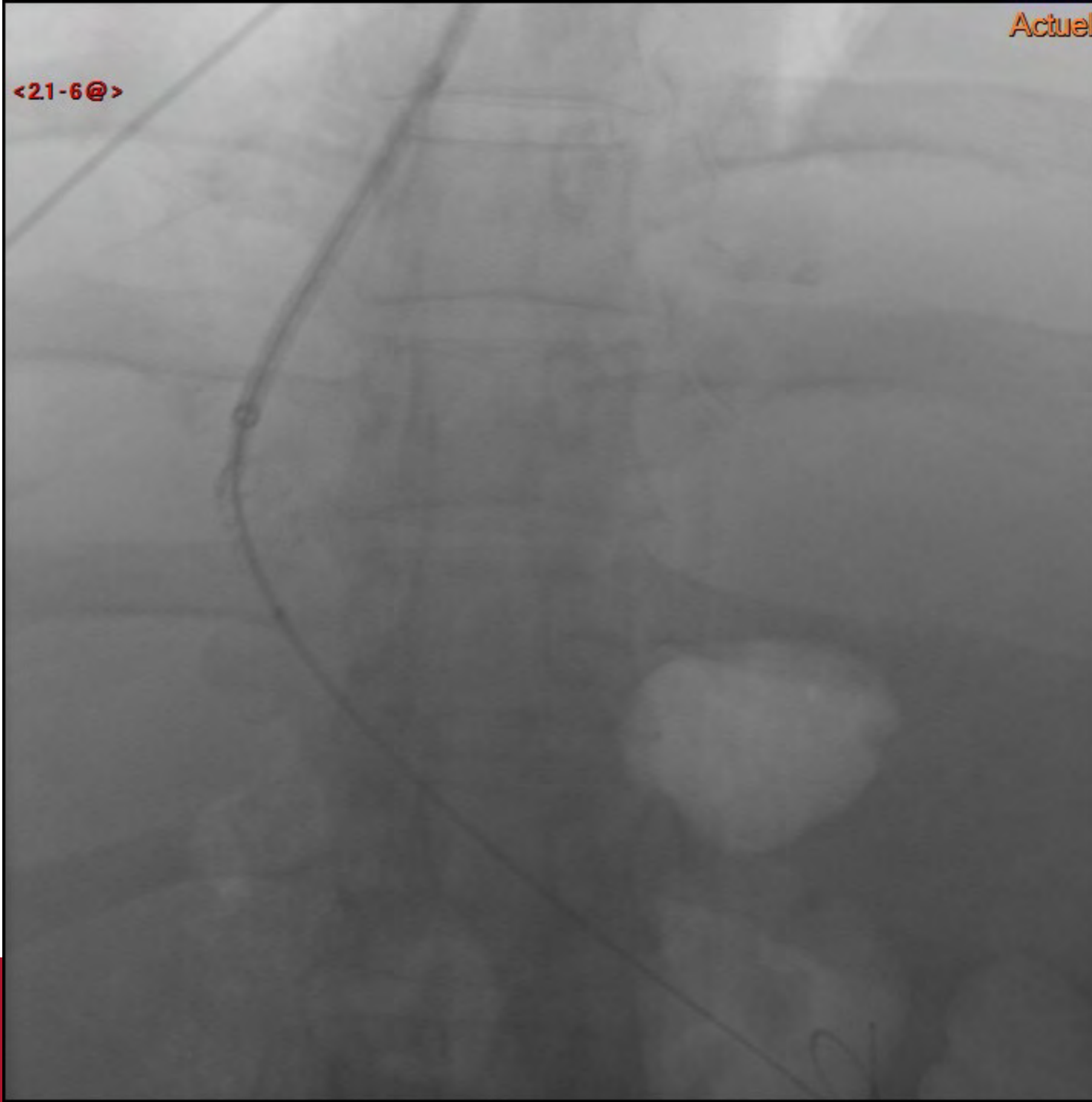<21-4@>



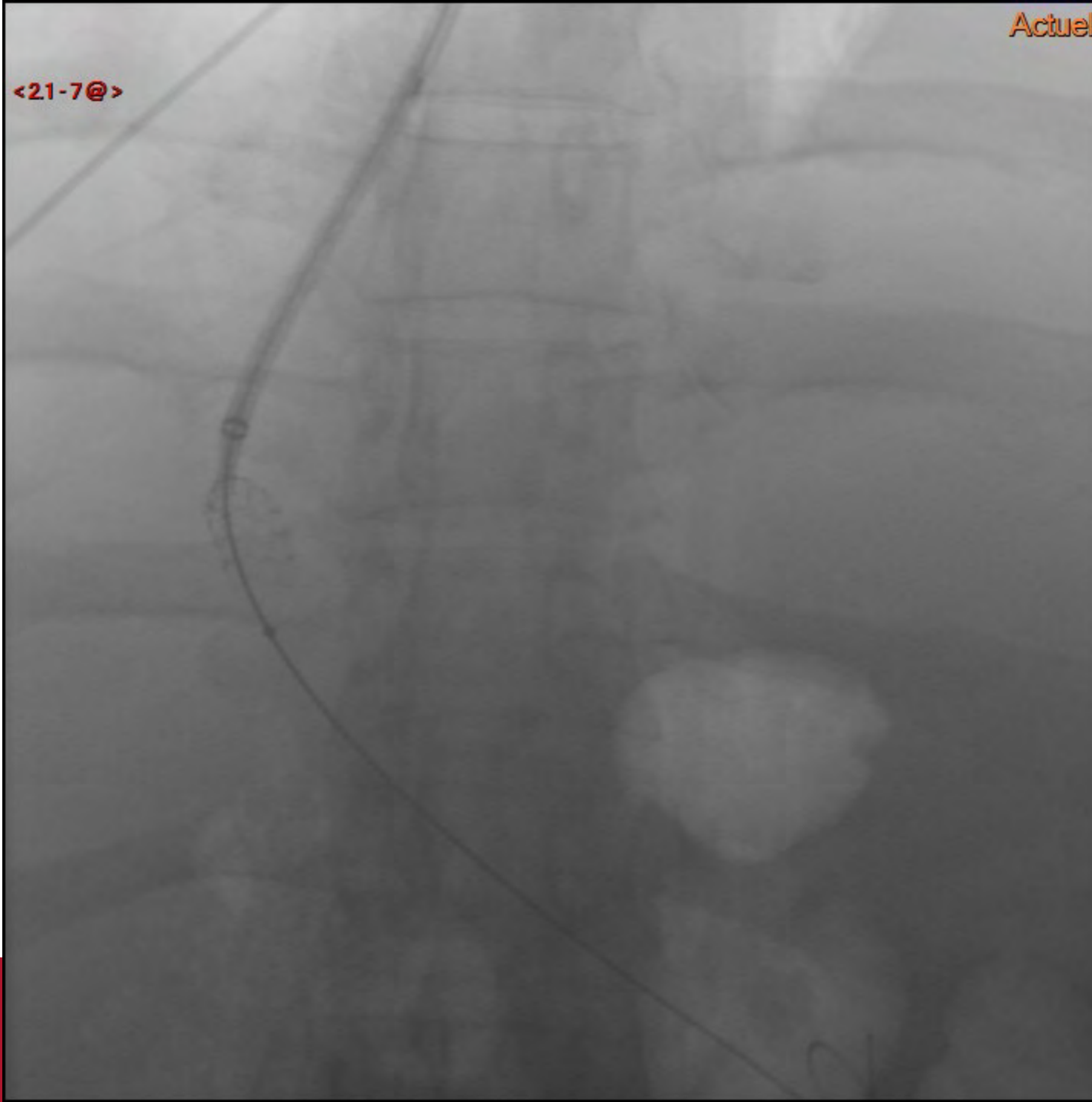<21-5@>



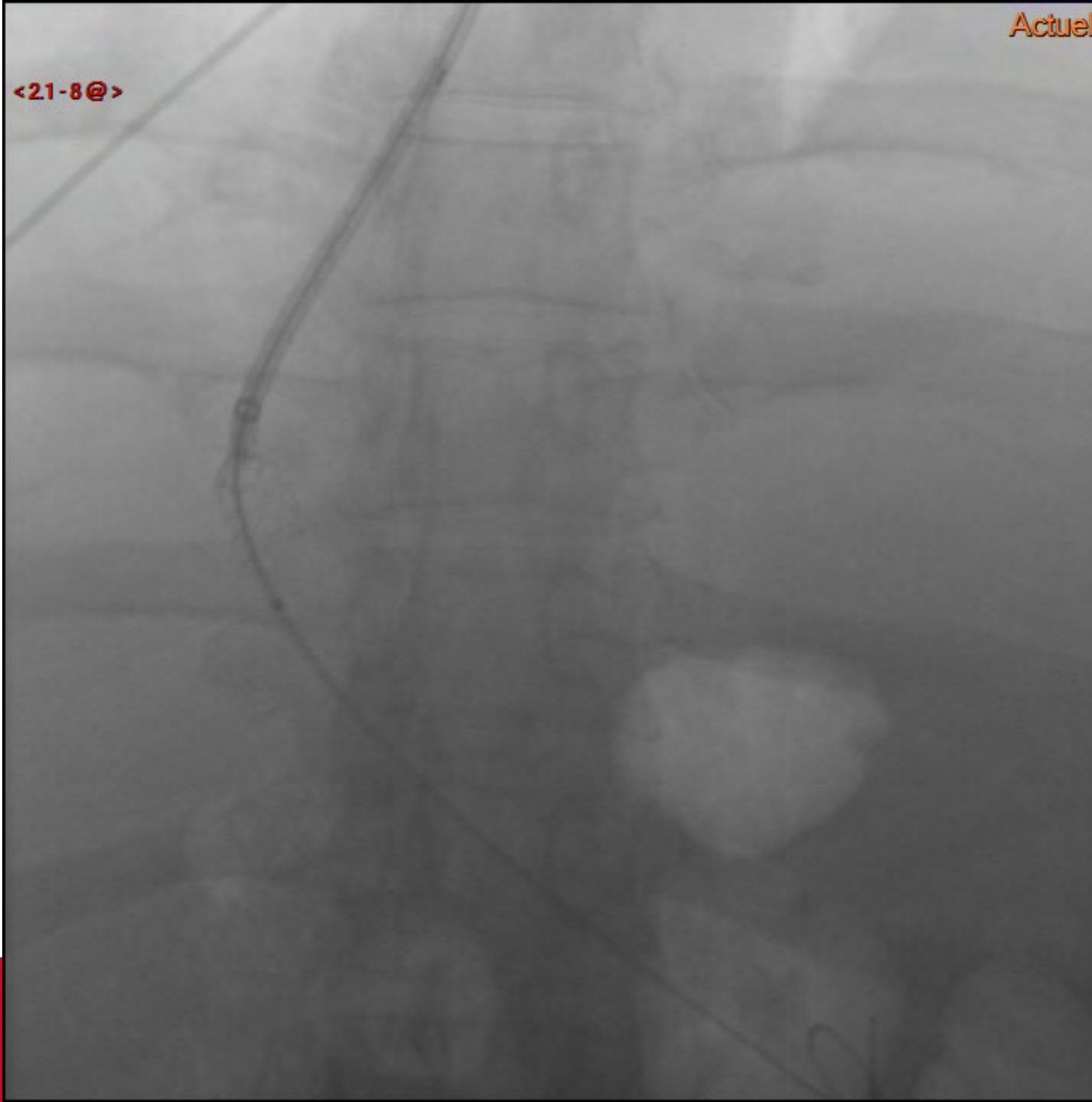<21-6@>



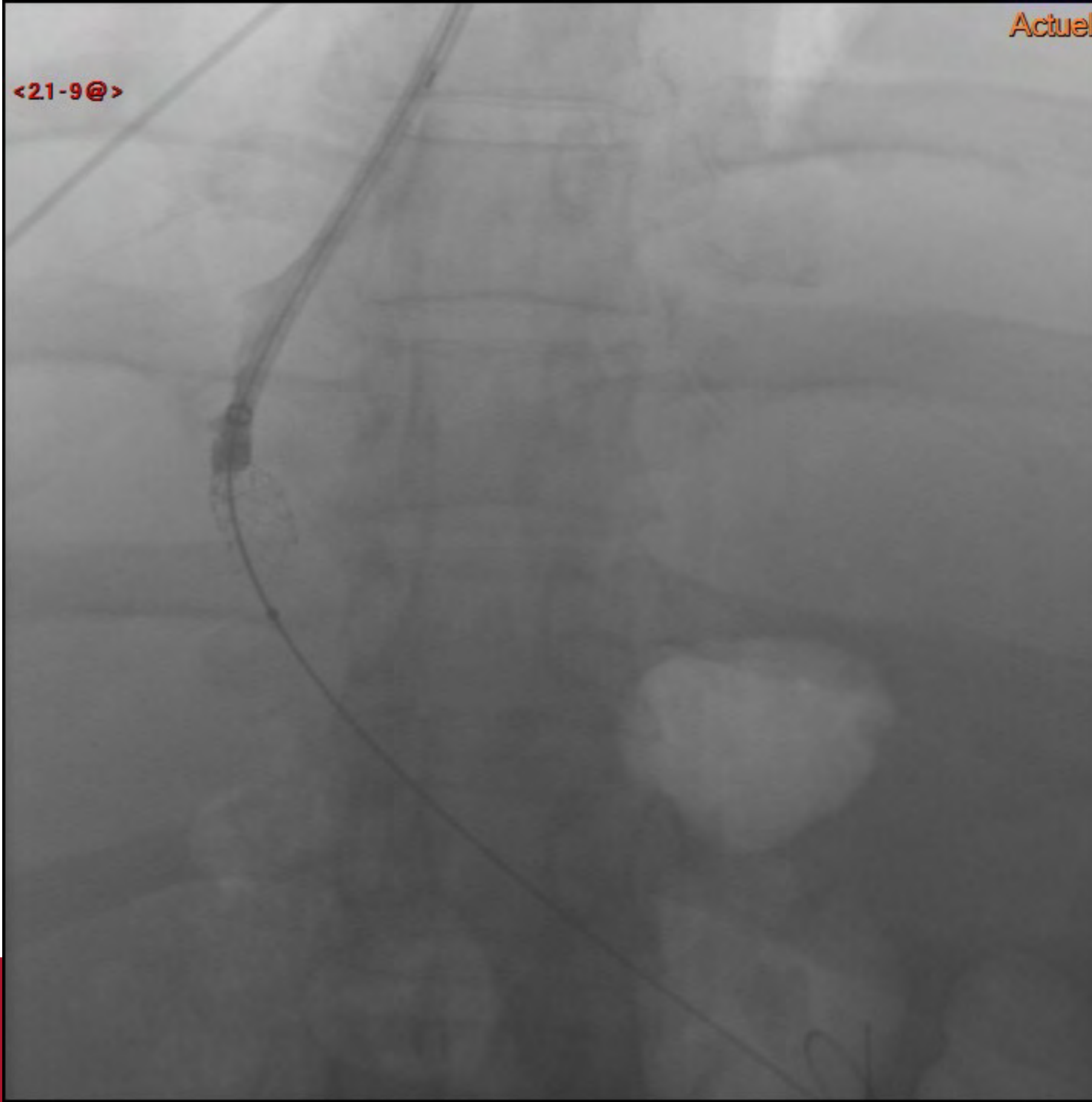<21-7@>



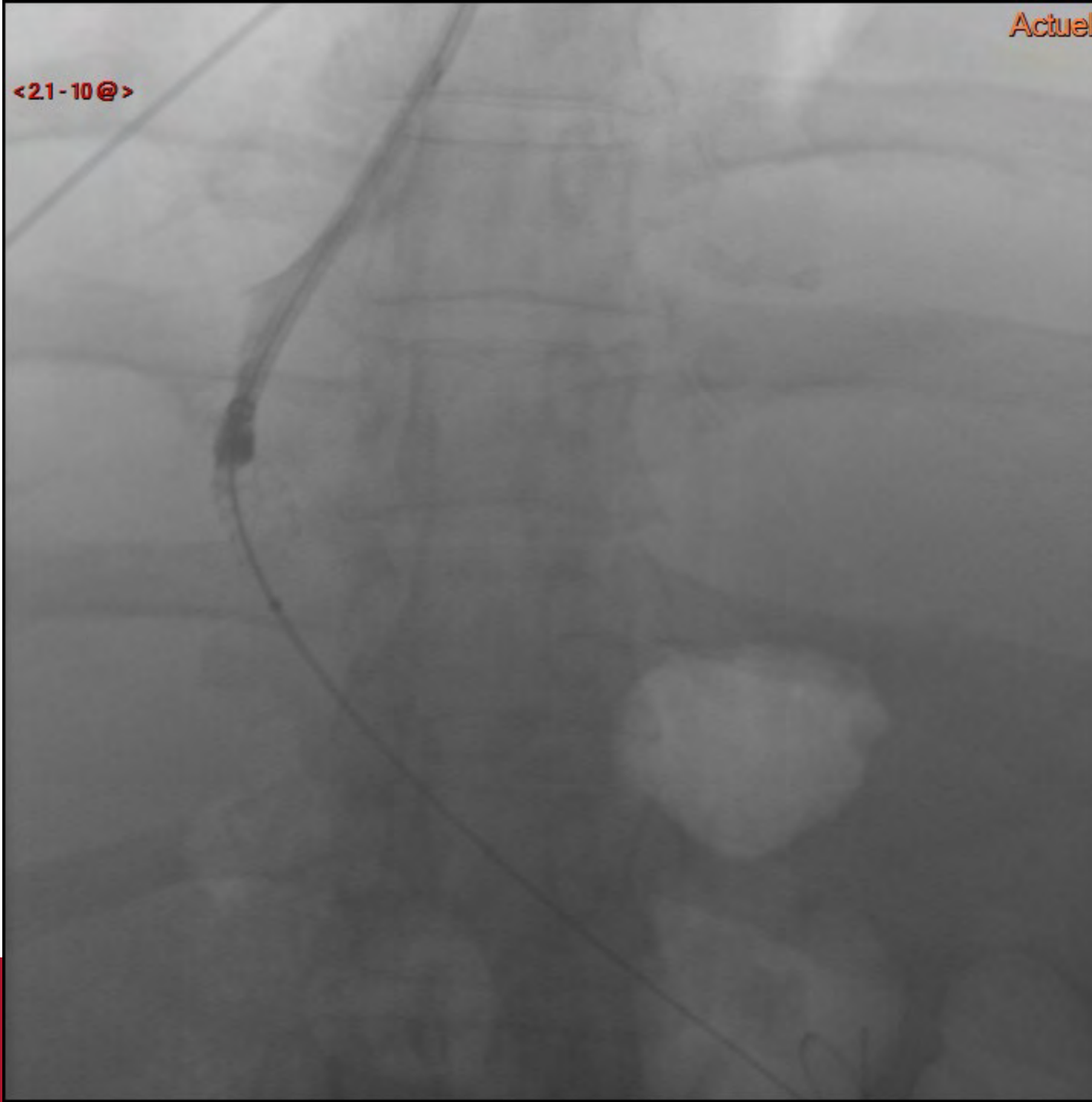
<21-8@>



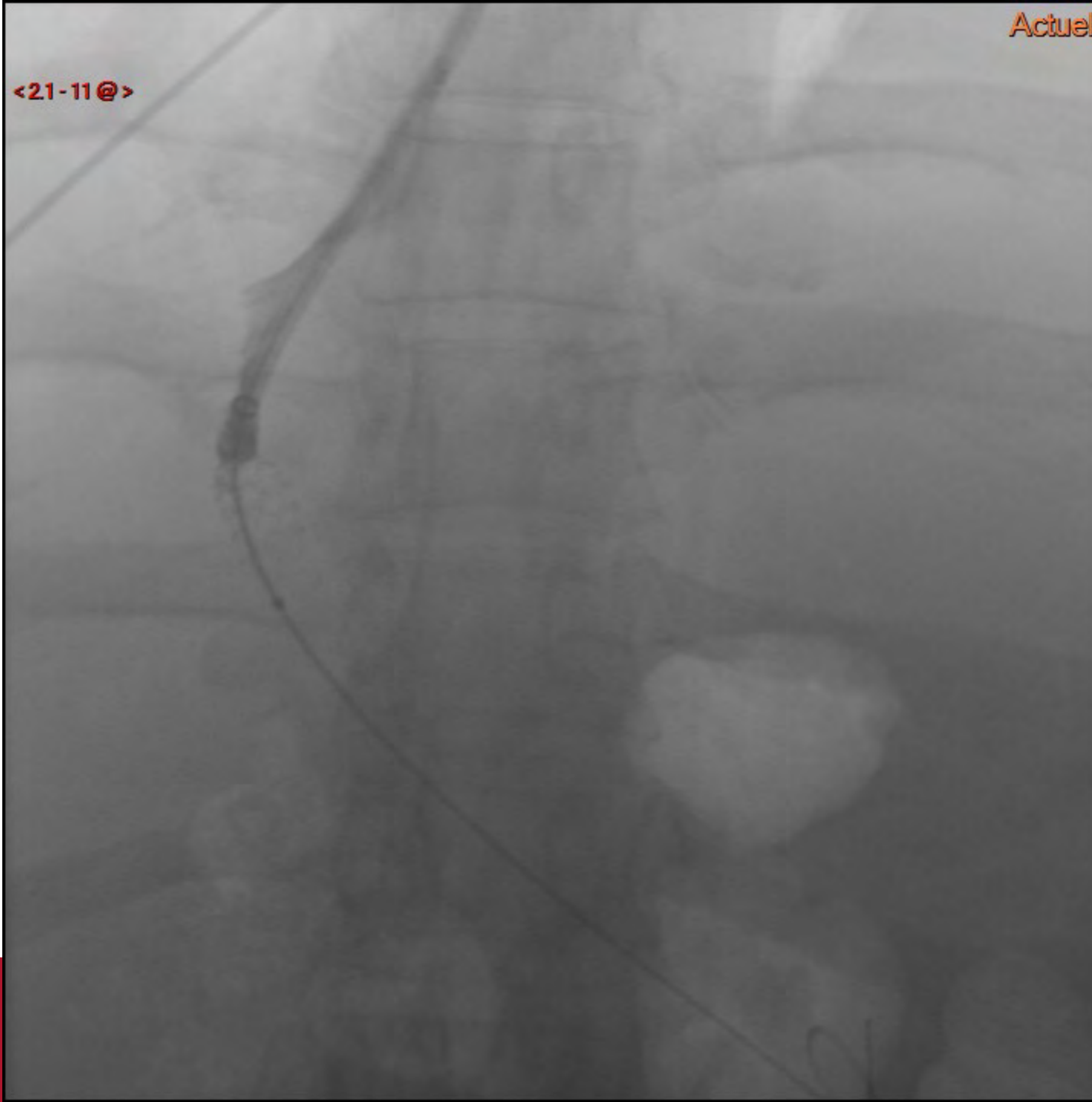
<21-9@>



<21-10@>



<21-11@>

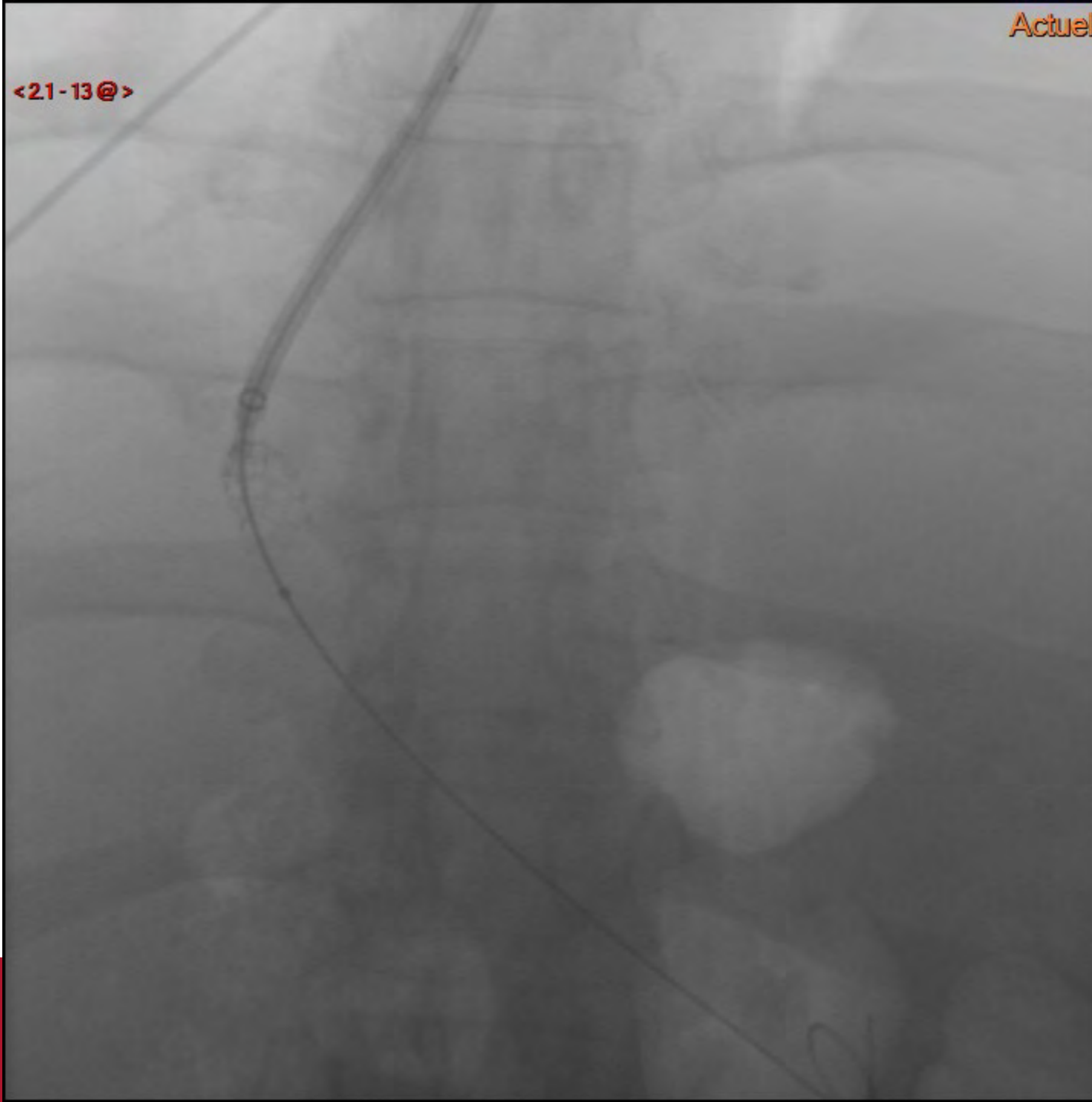


<21-12@>

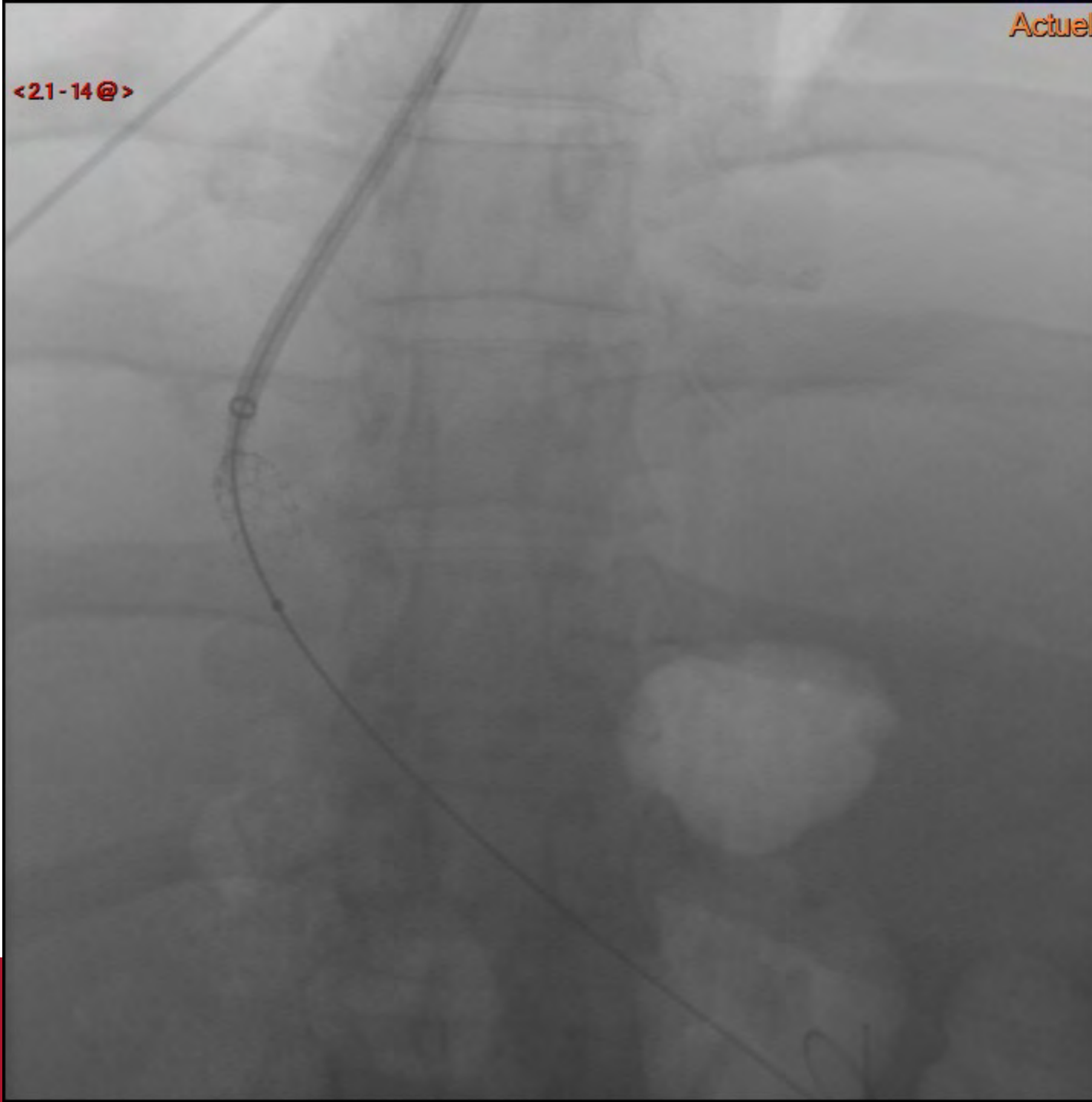
Entrée

Sortie

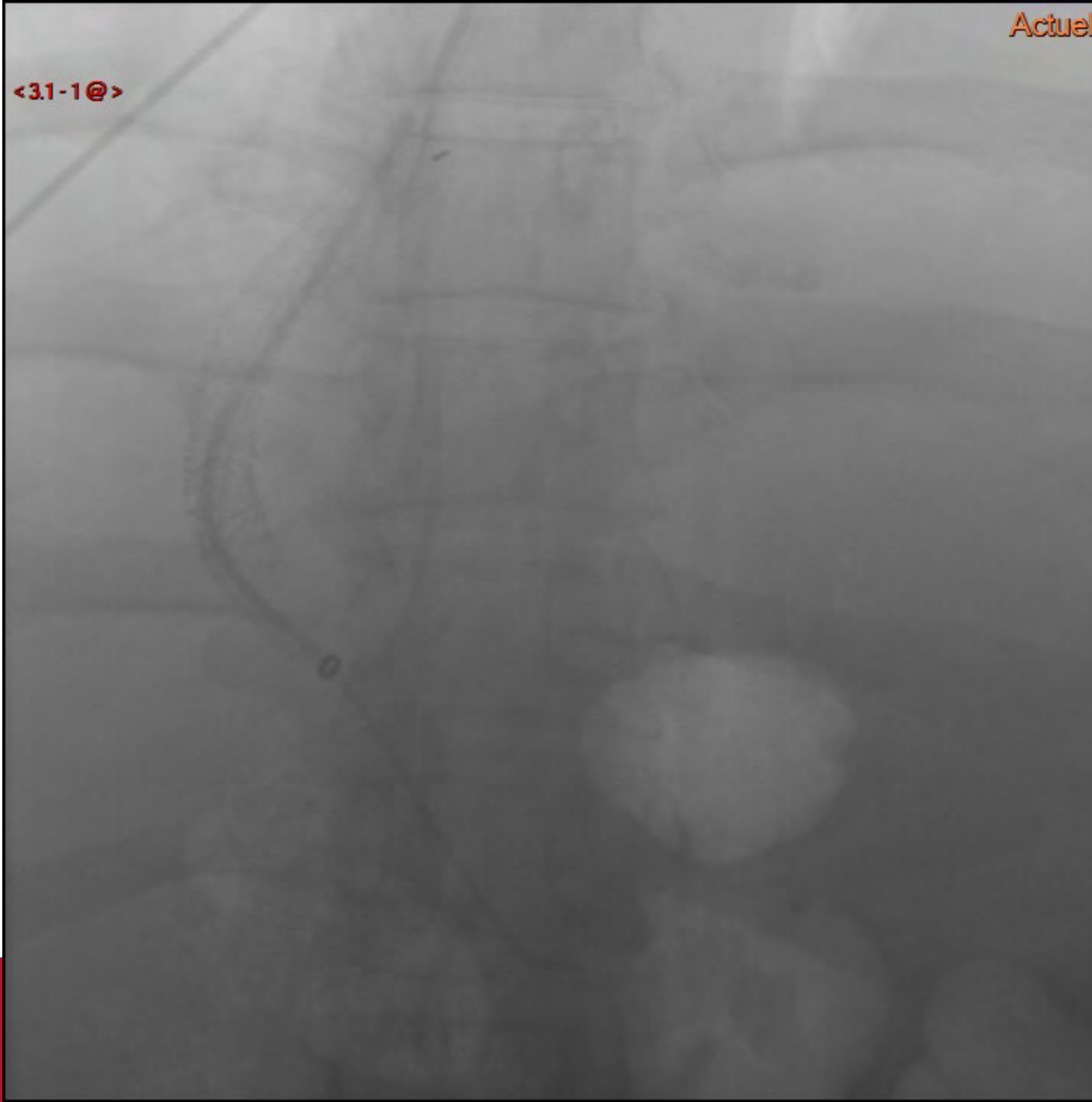<21-13@>



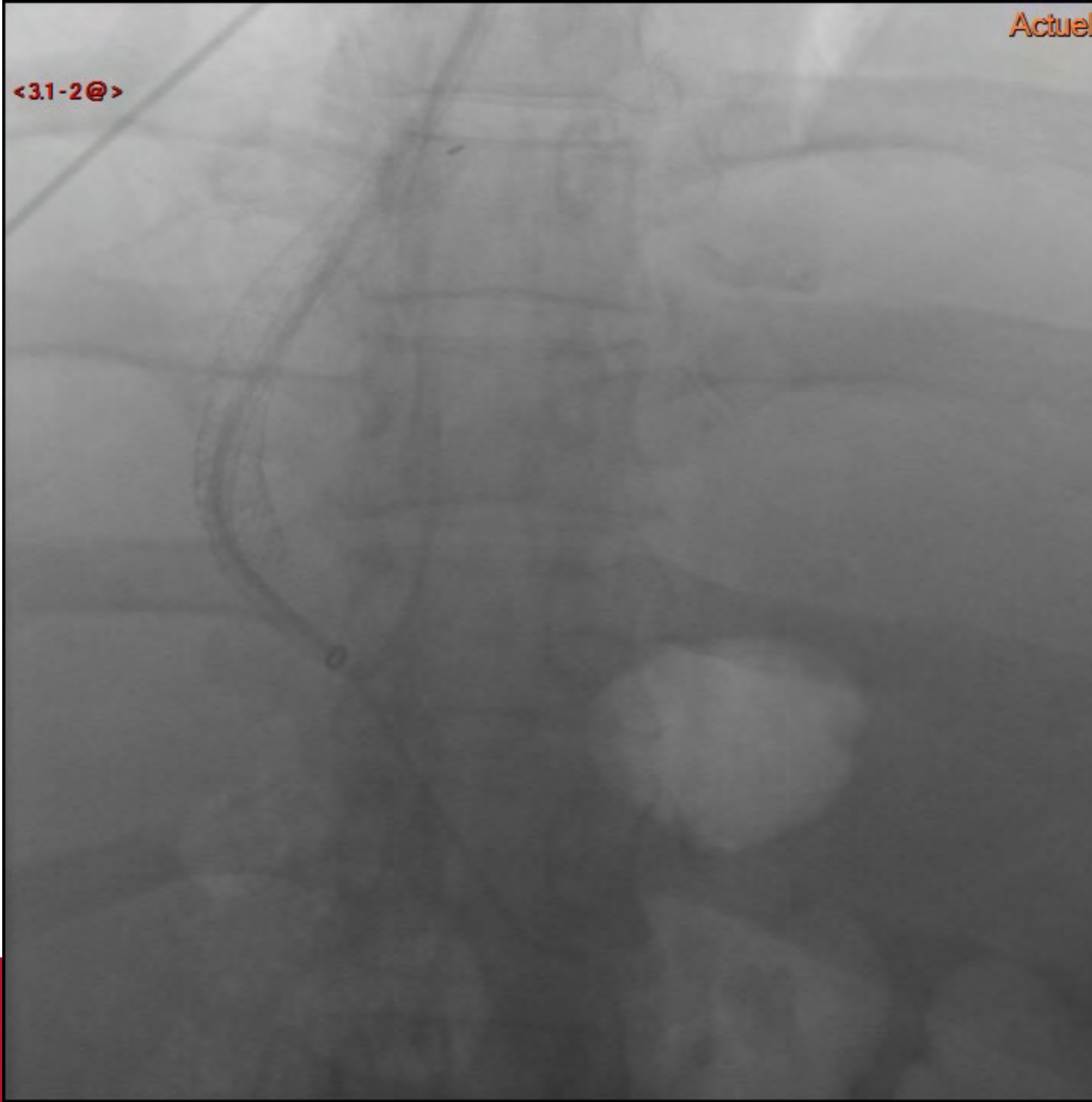
<21-14@>



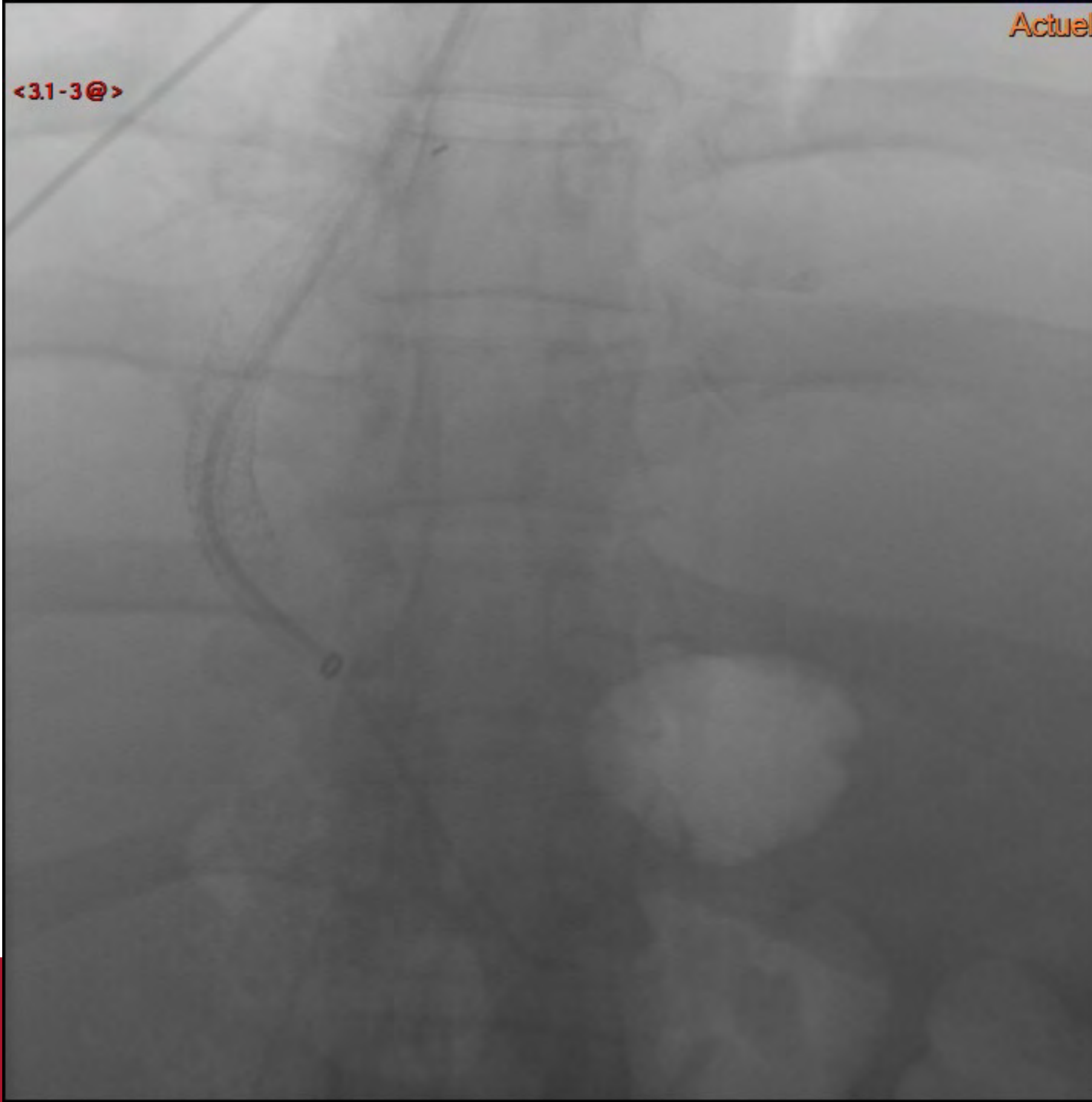<3.1-1@>



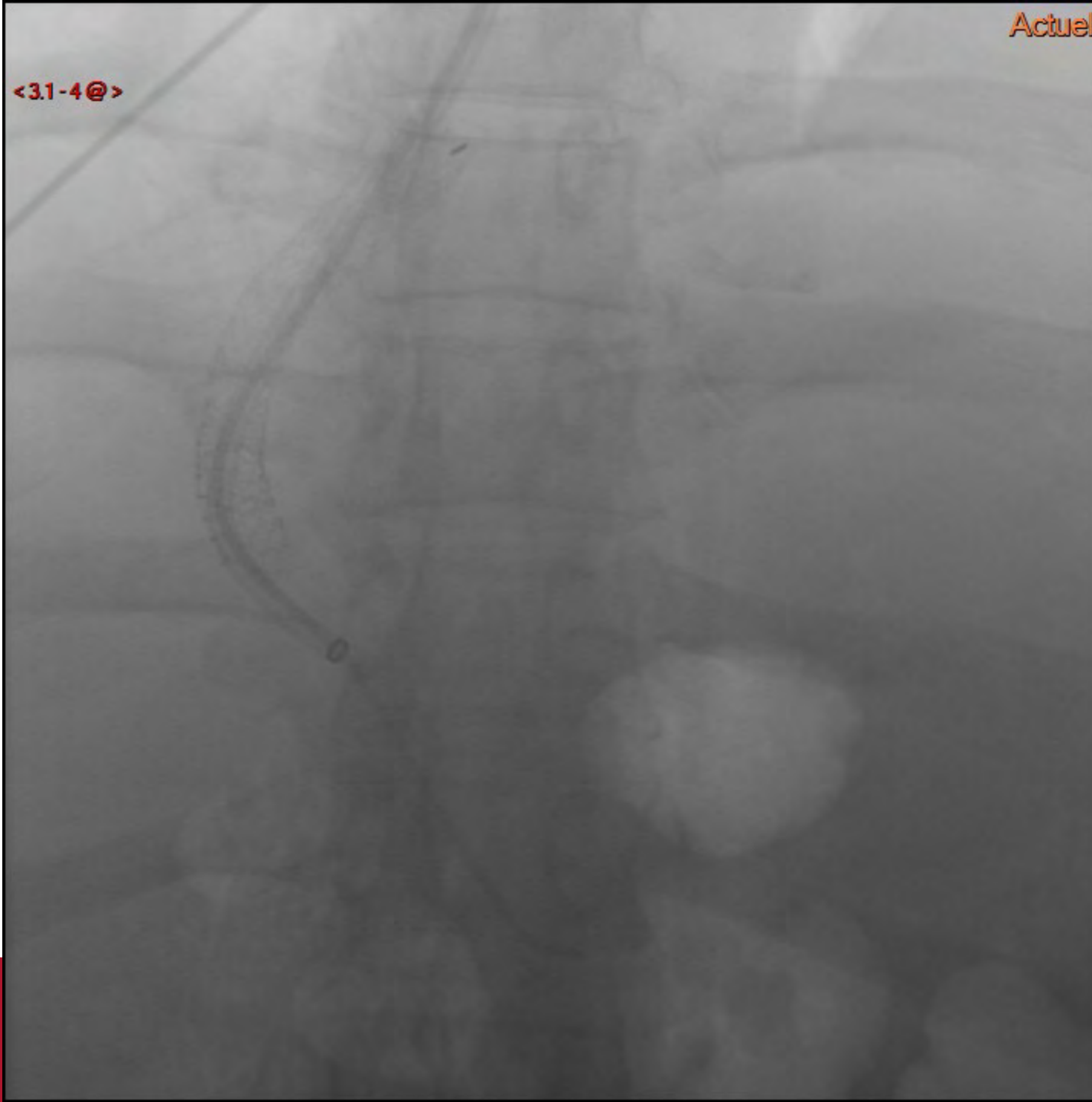
<3.1-2@>



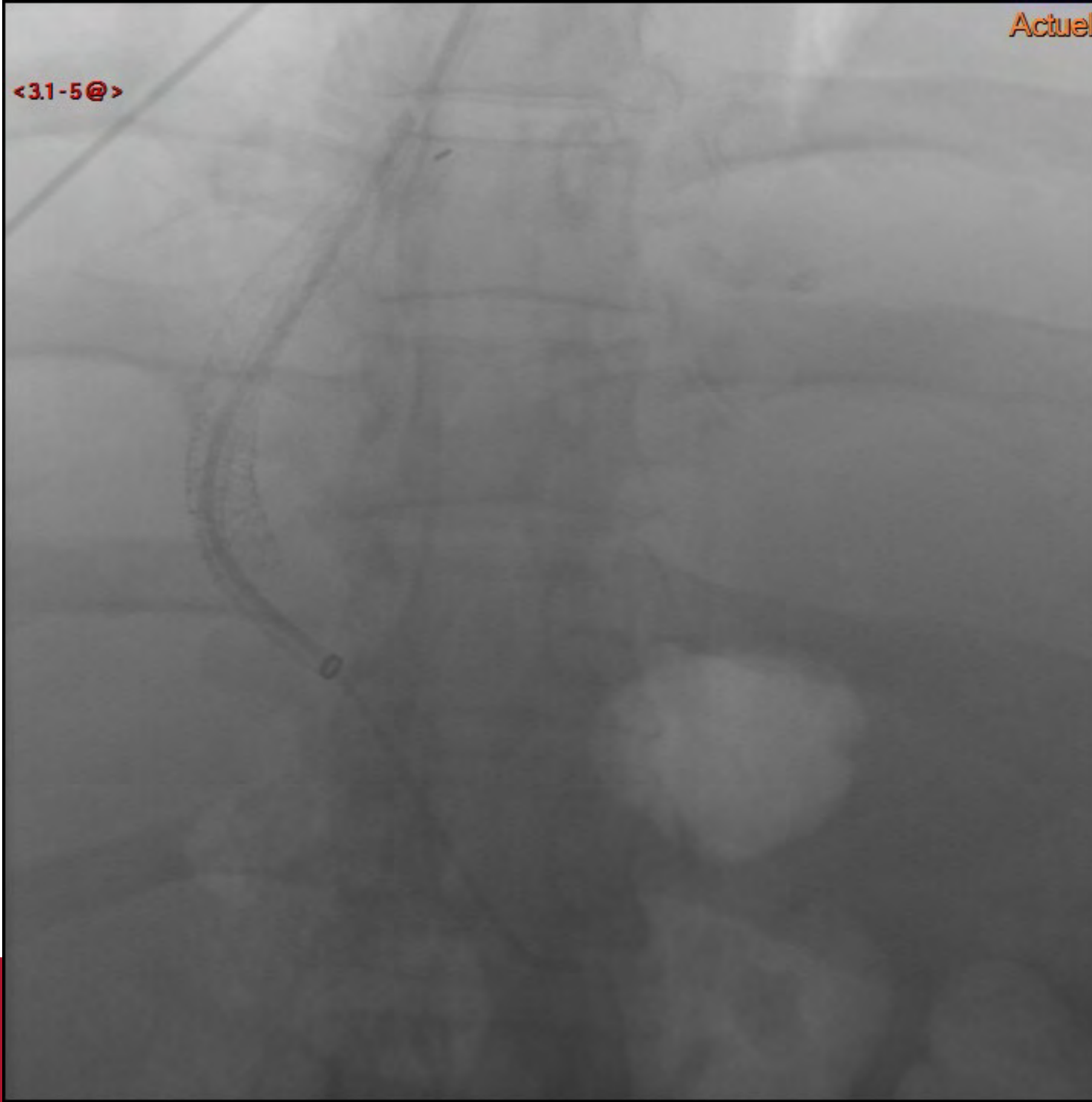
<3.1-3@>



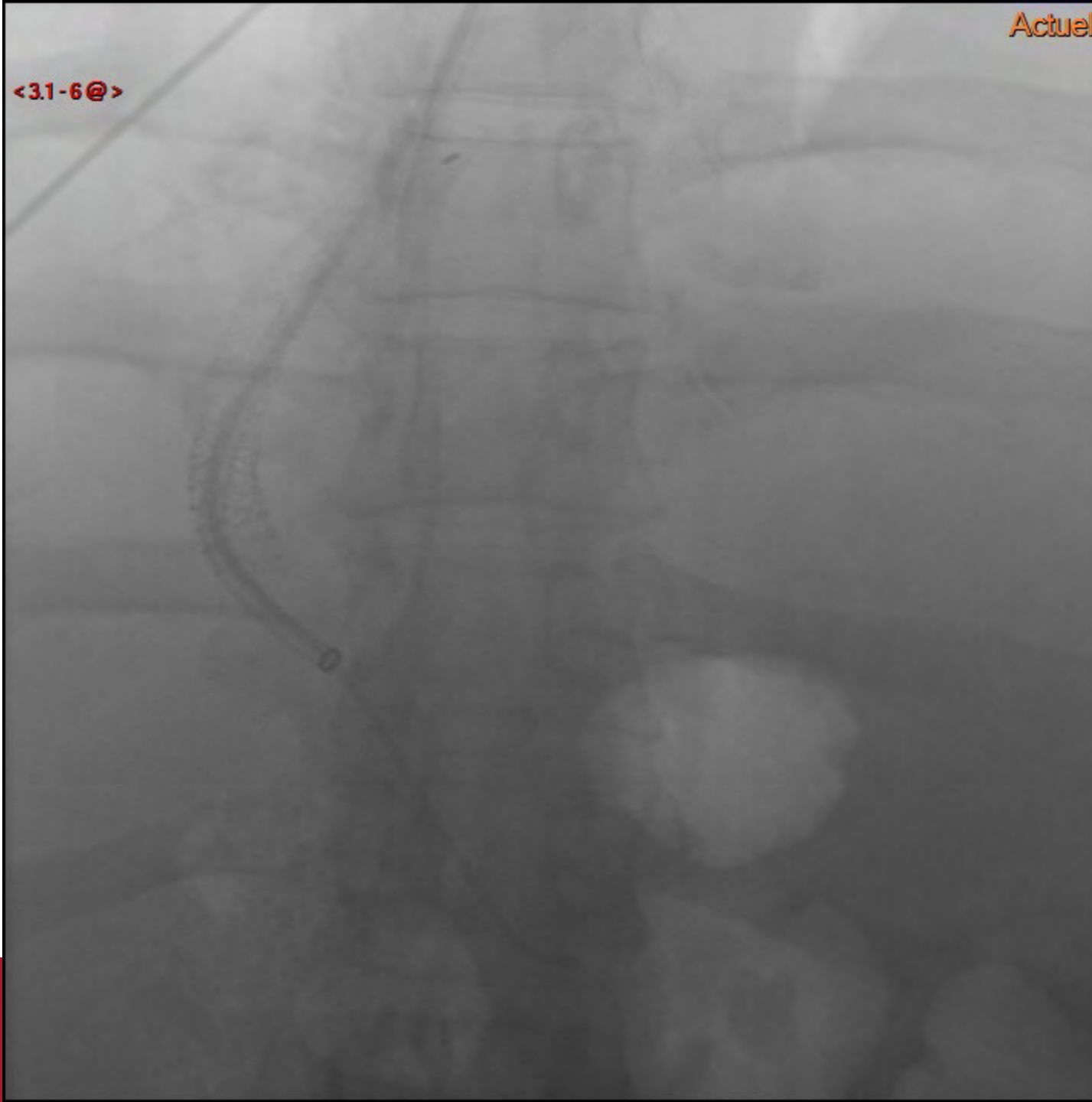<3.1-4@>



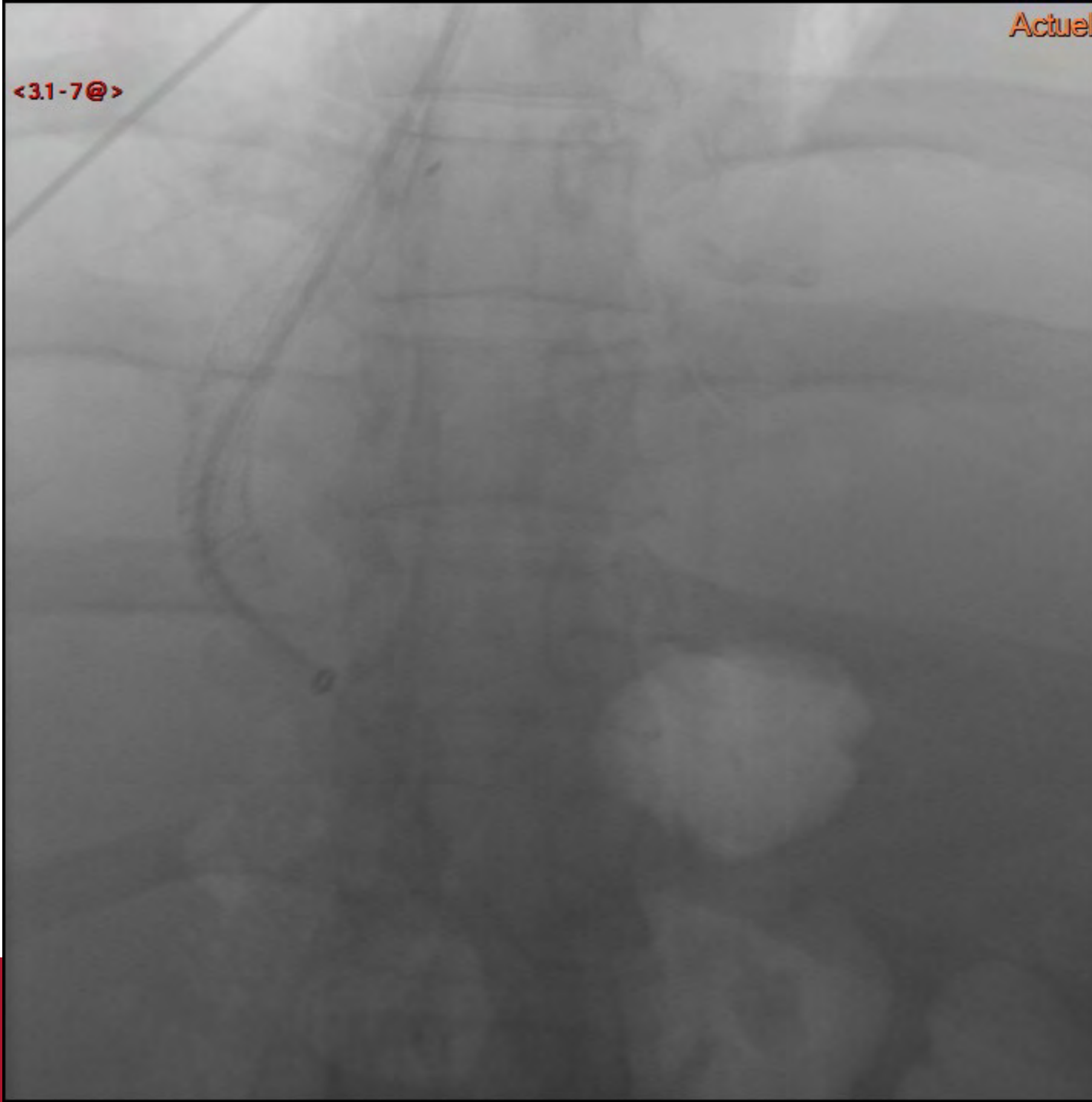
<3.1-5@>



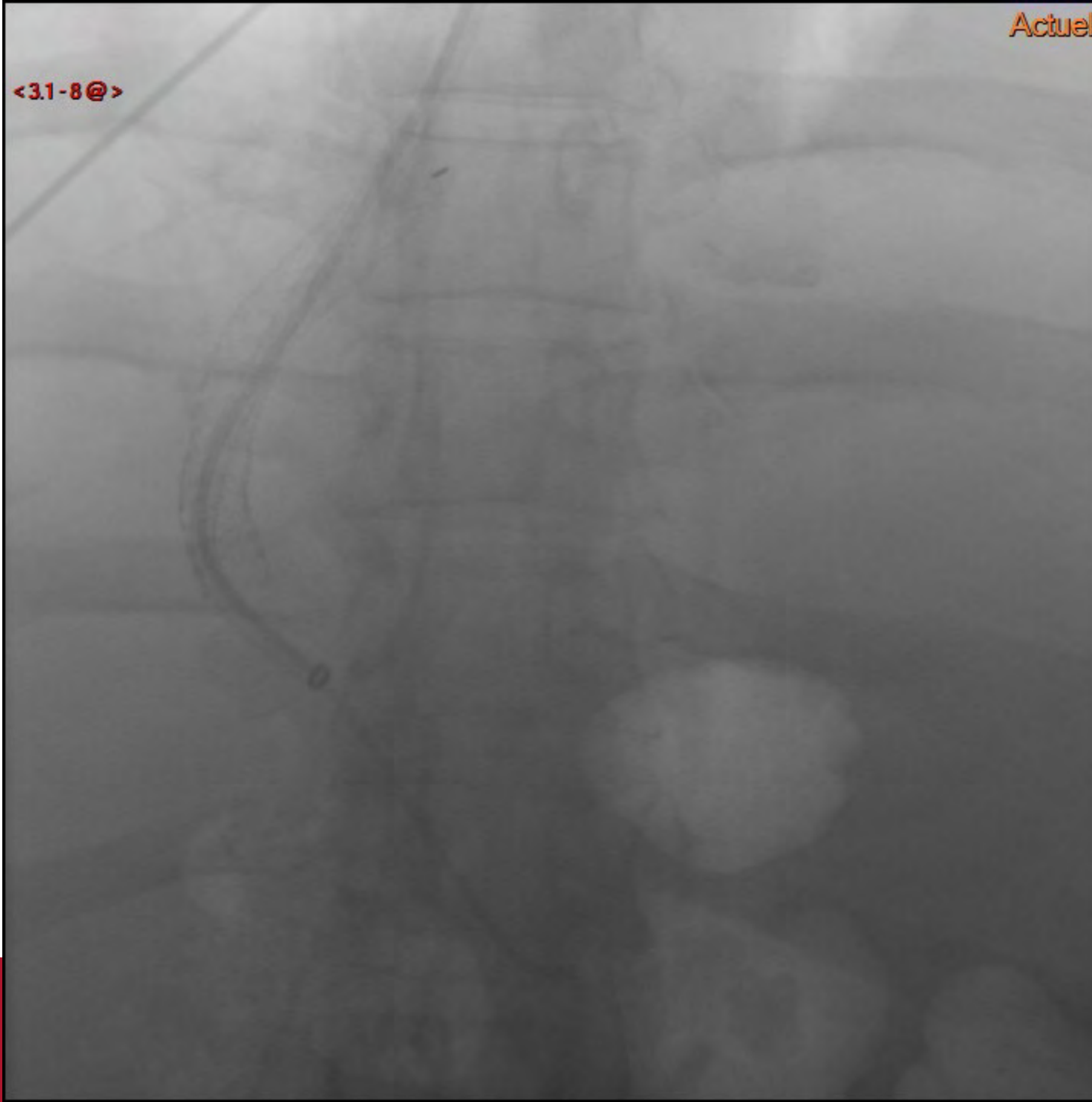
<3.1-6@>



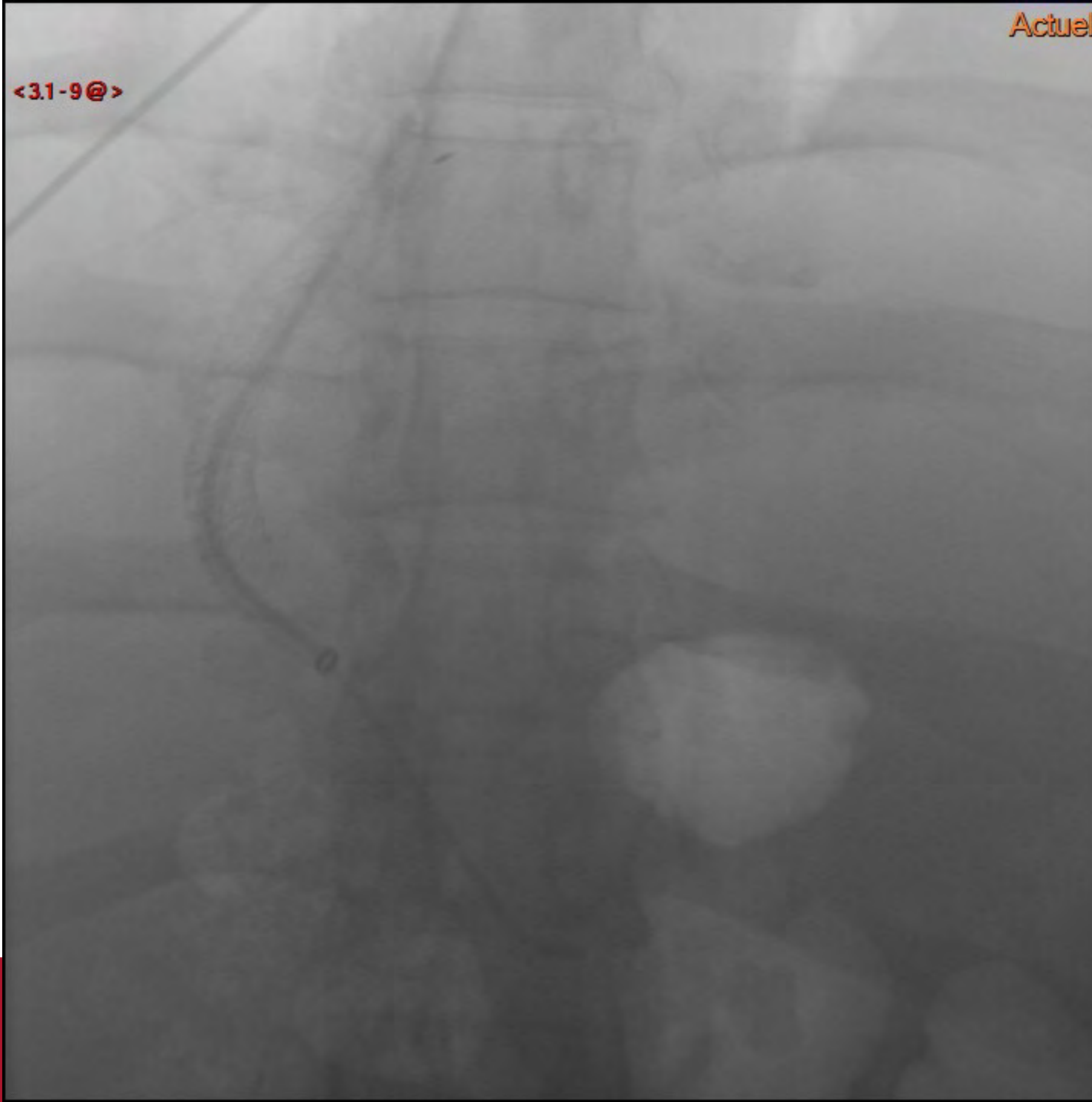
<3.1-7@>



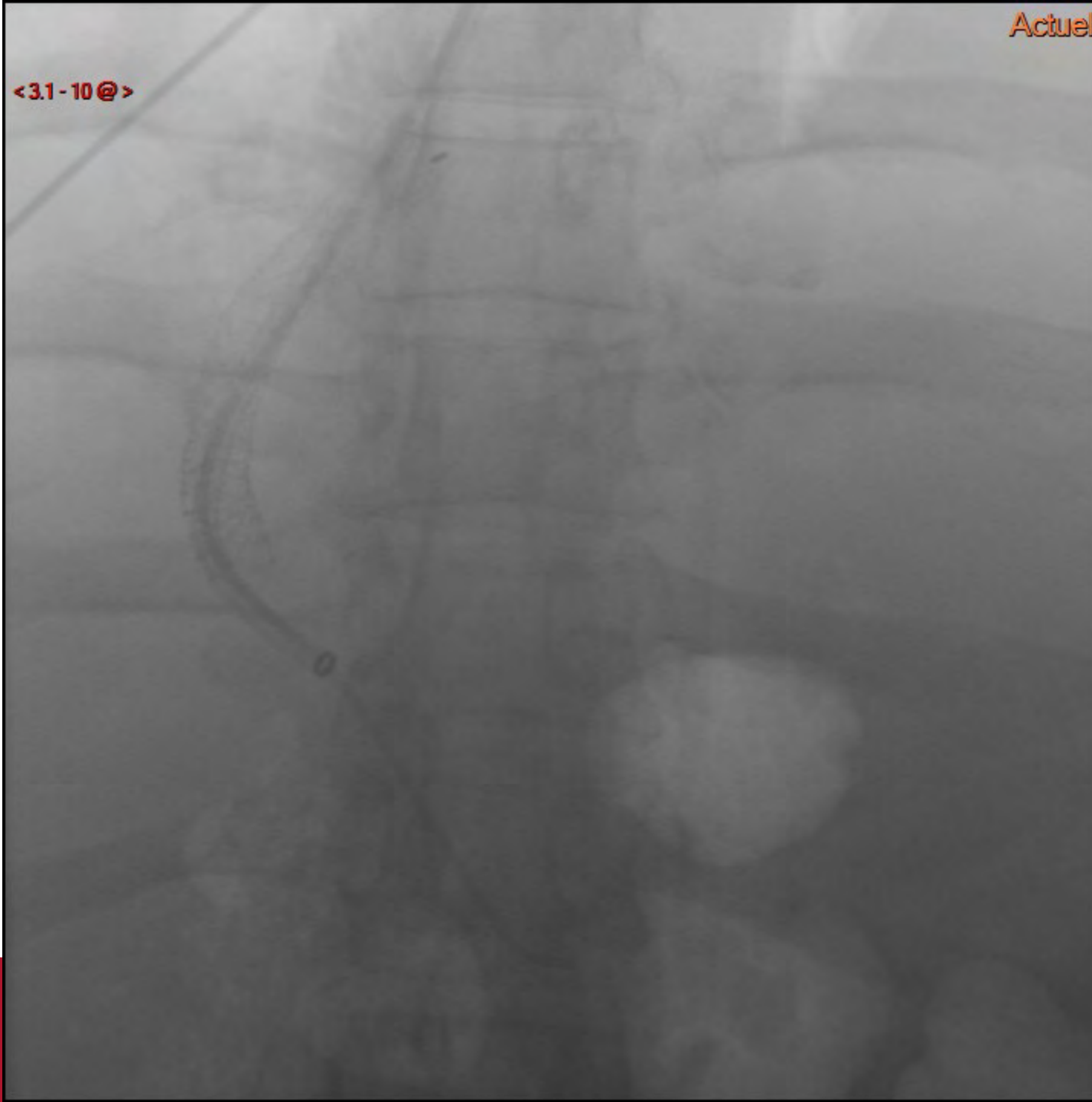
<3.1-8@>



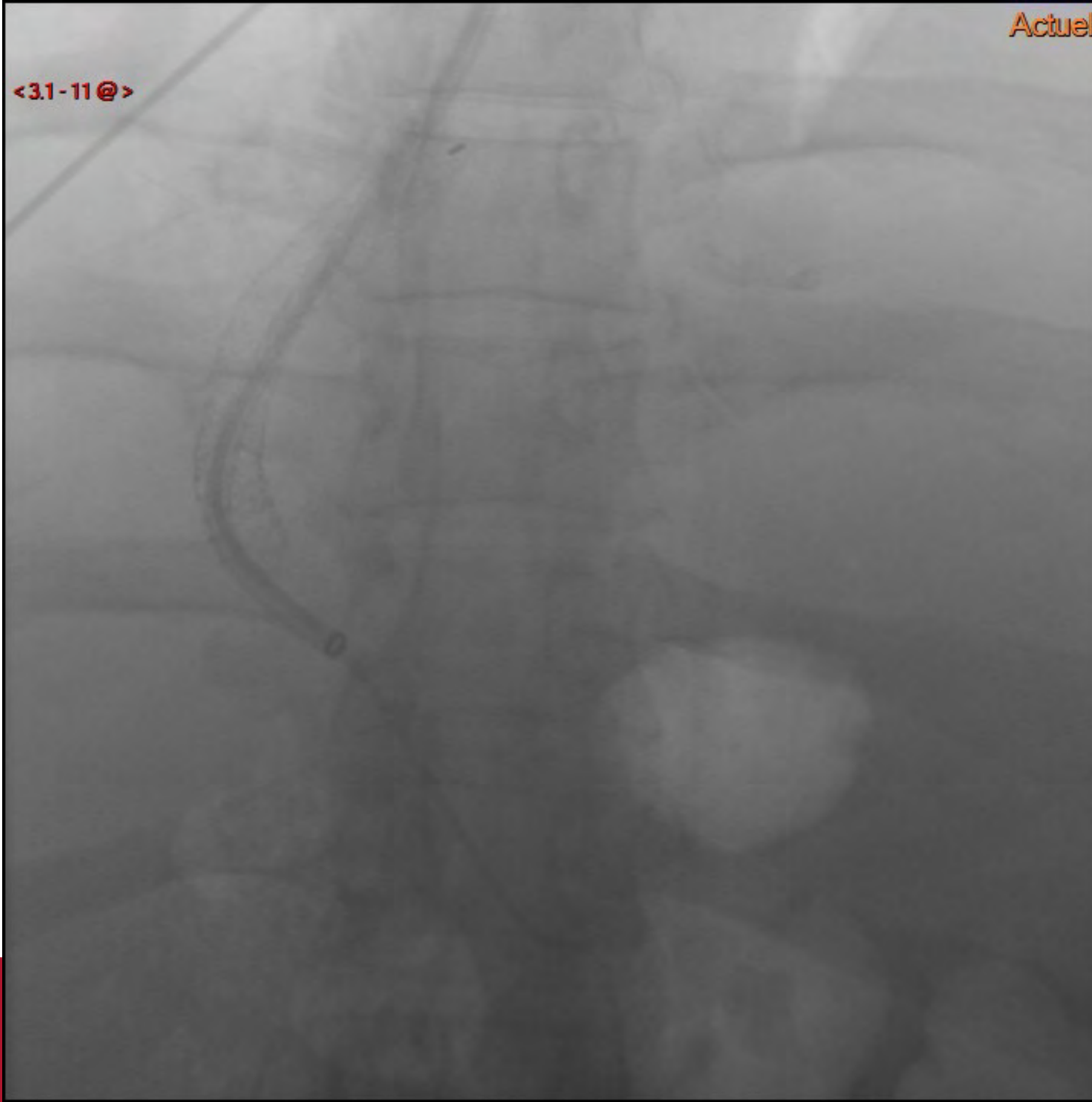
<3.1-9@>



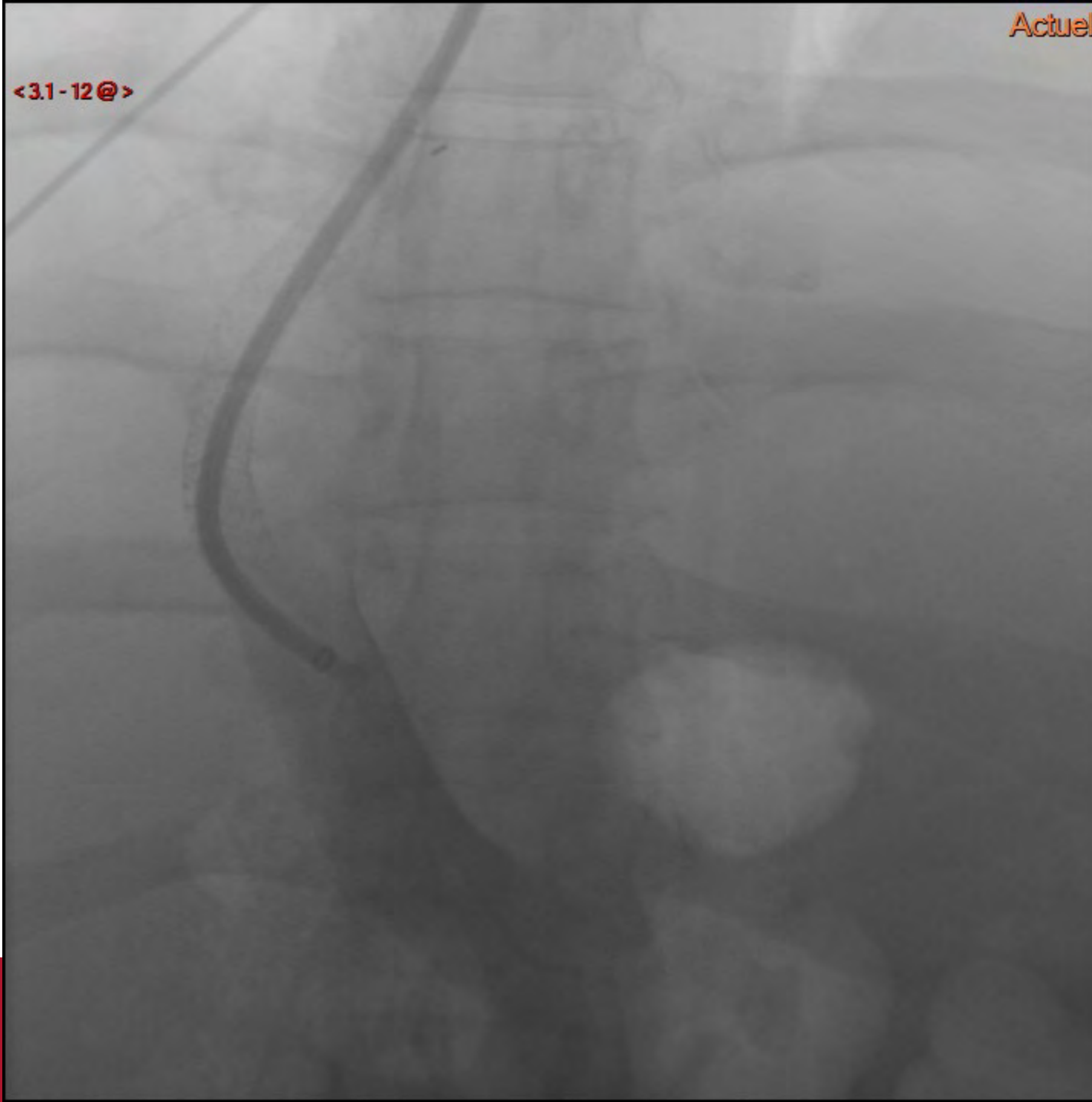
<3.1-10@>



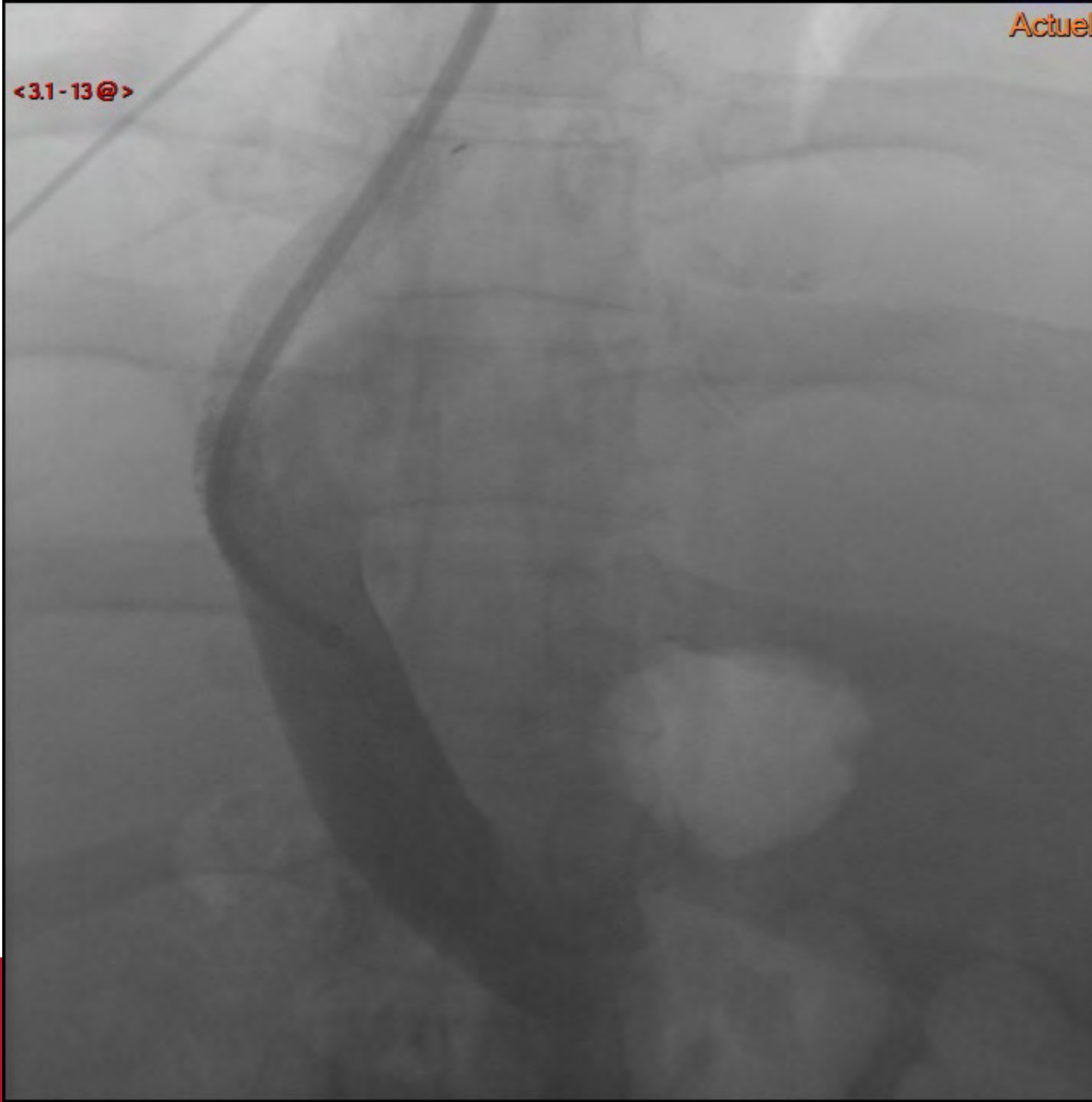
<3.1-11@>



<3.1-12@>



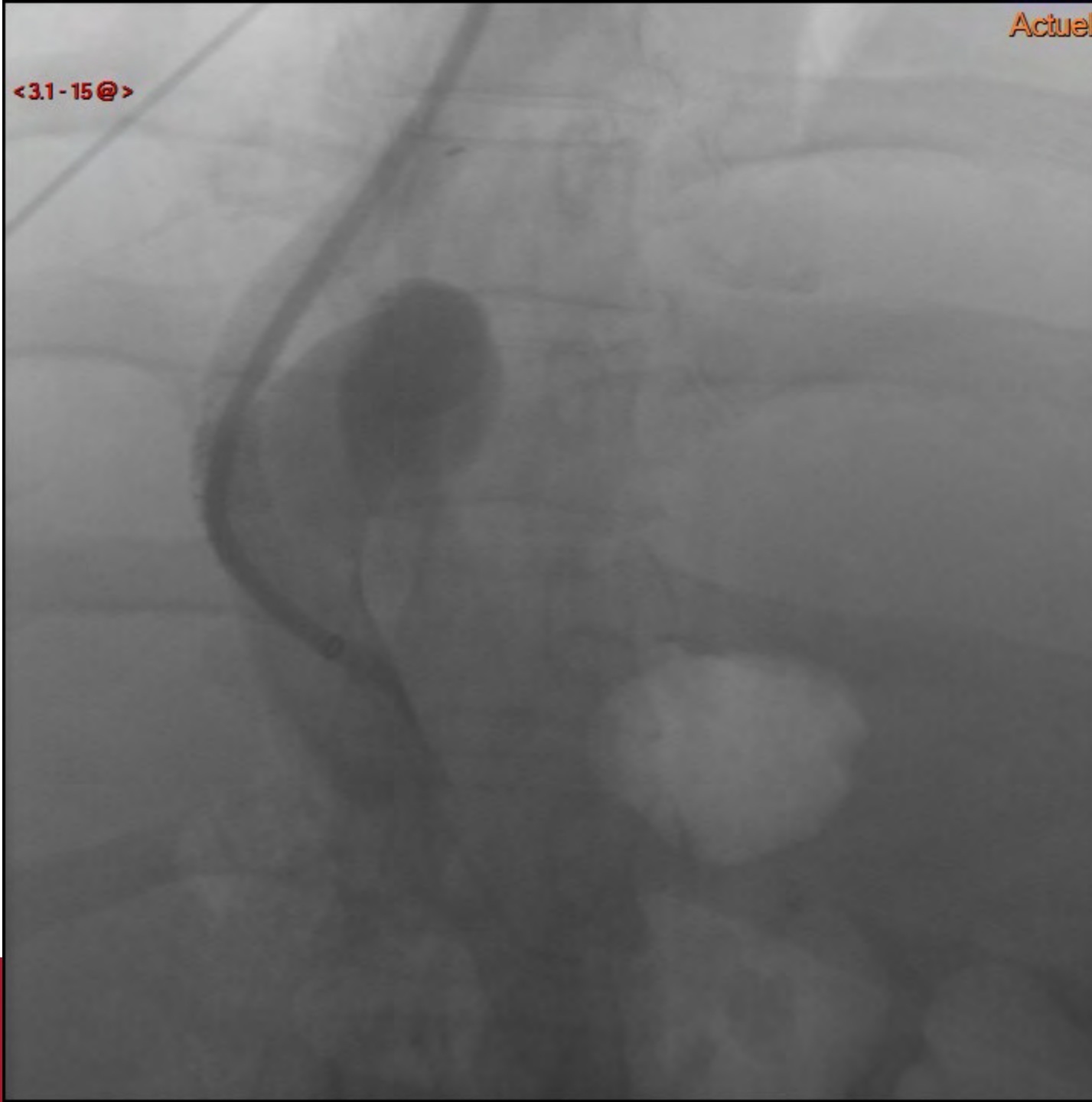
<3.1-13@>



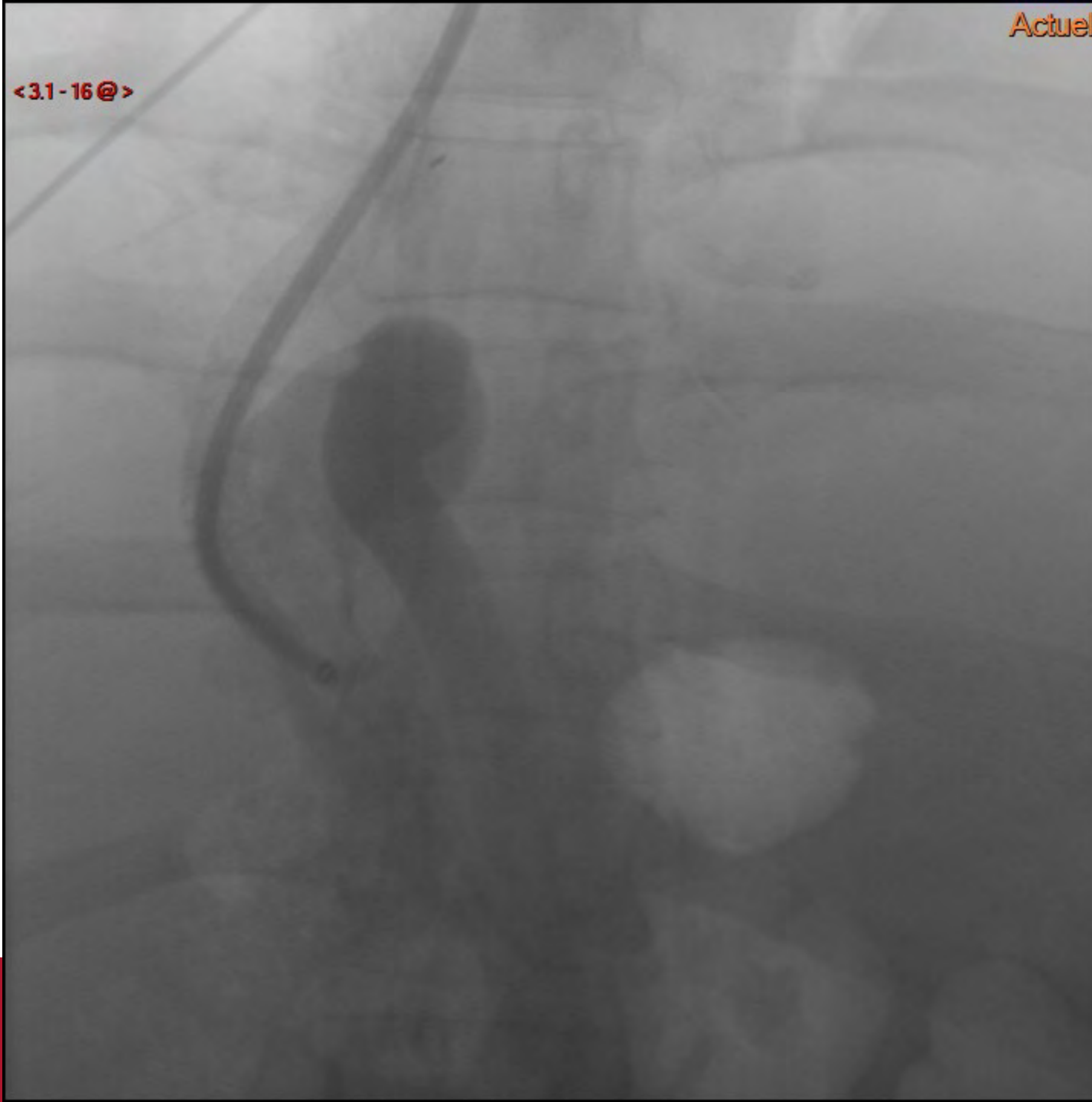<3.1-14@>

Calibre 8 mm

<3.1-15@>



<3.1-16@>

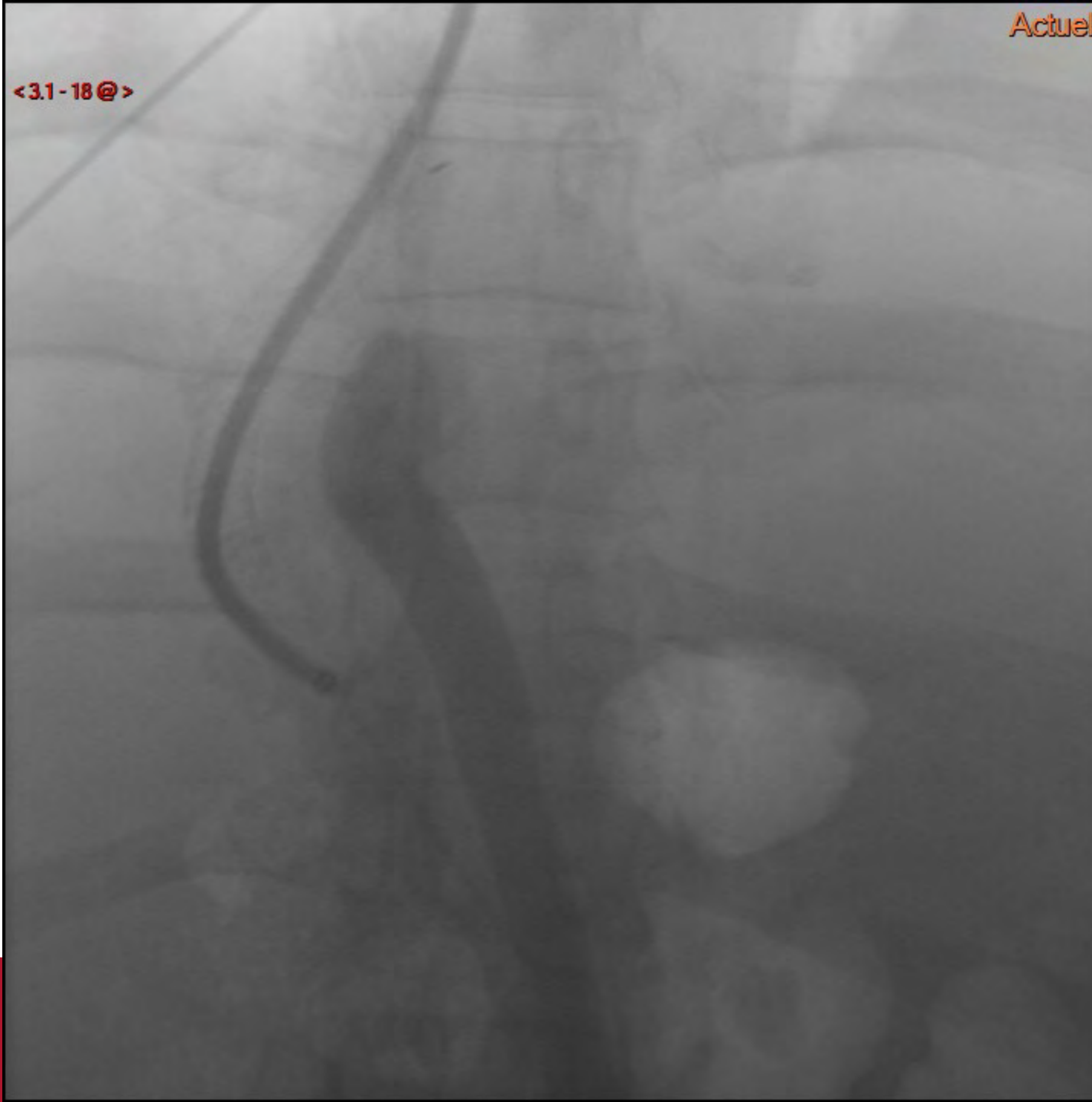


<3.1-17@>

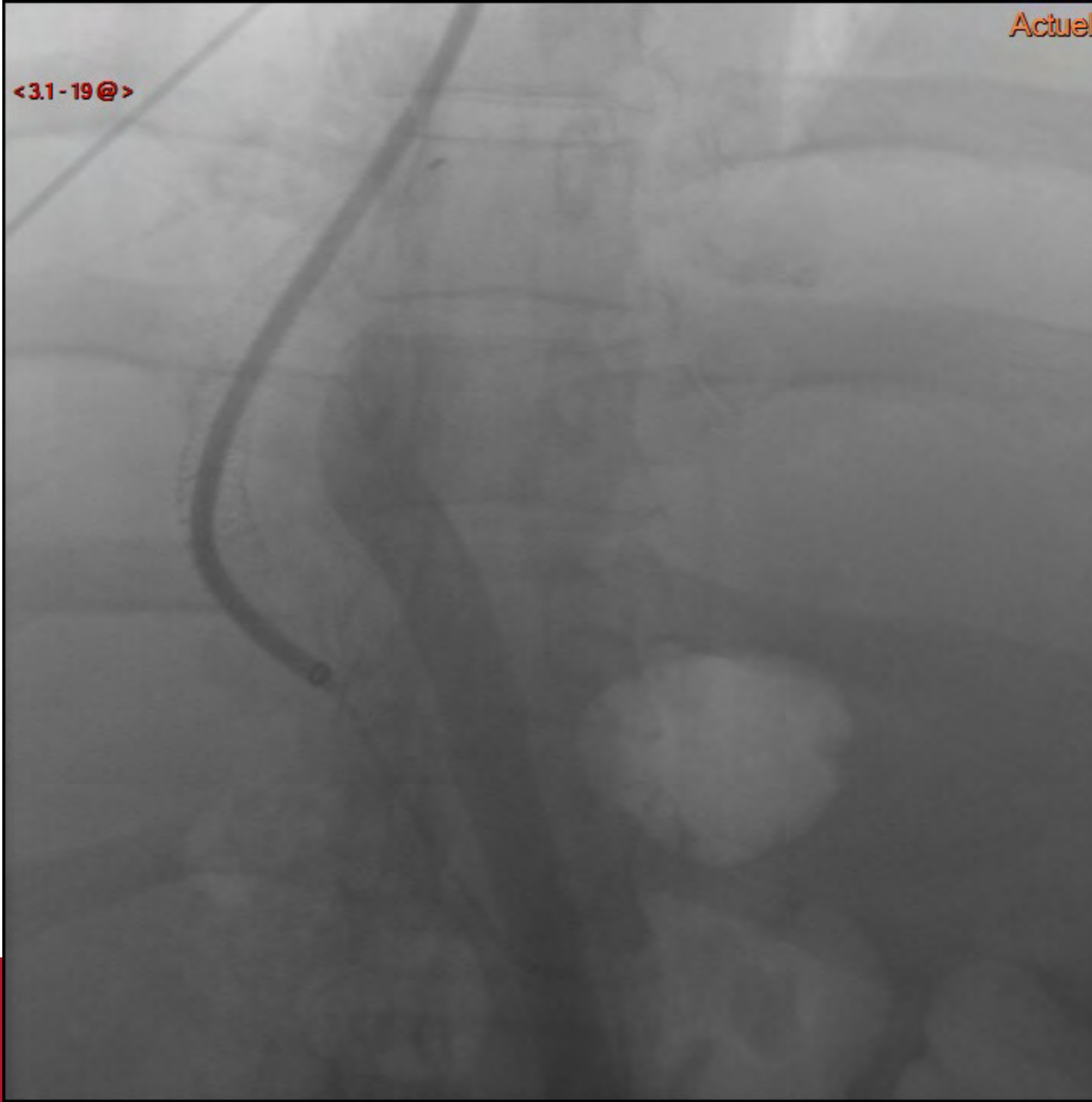
Veine ombilicale
persistante



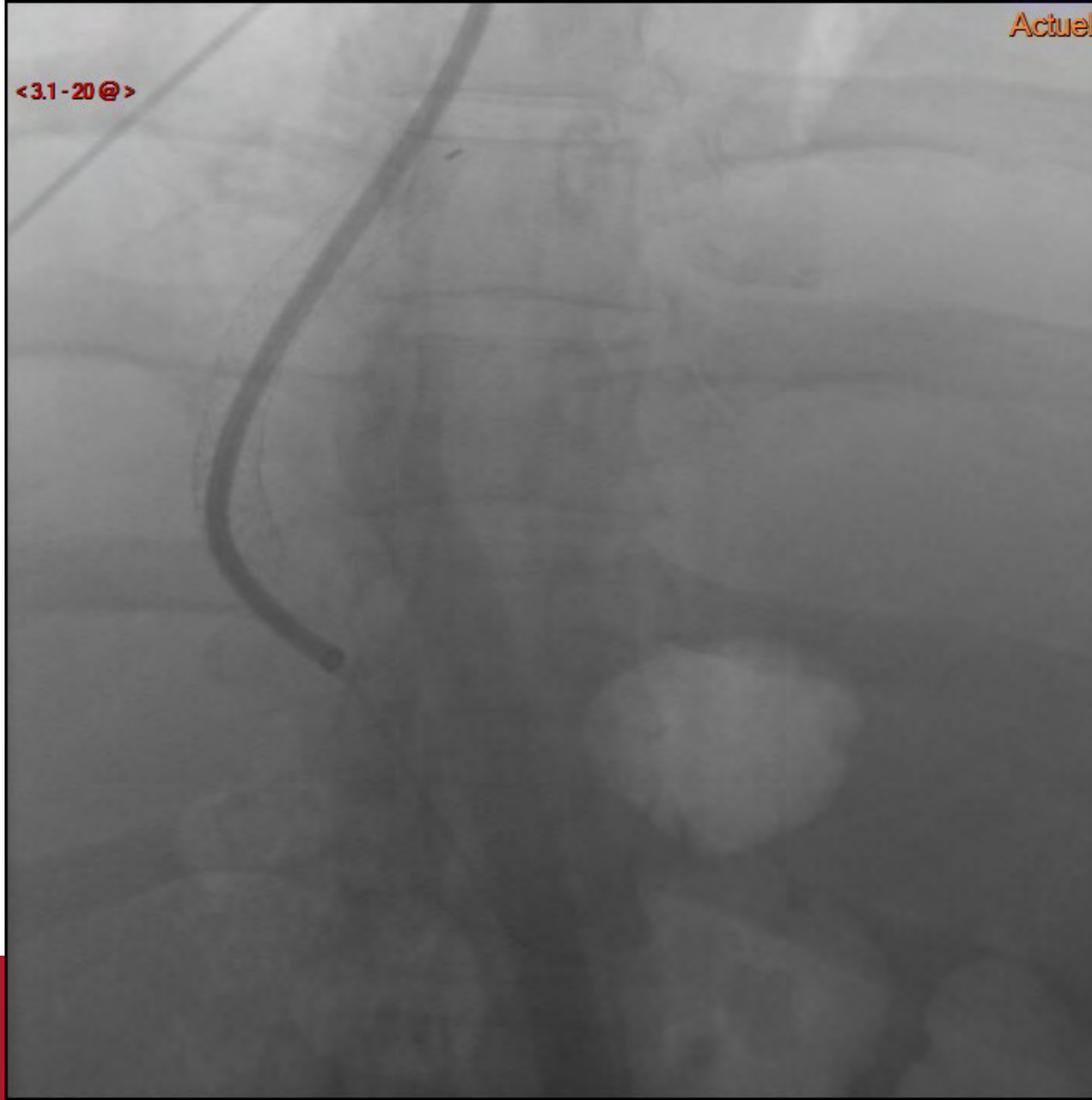
<3.1-18@>



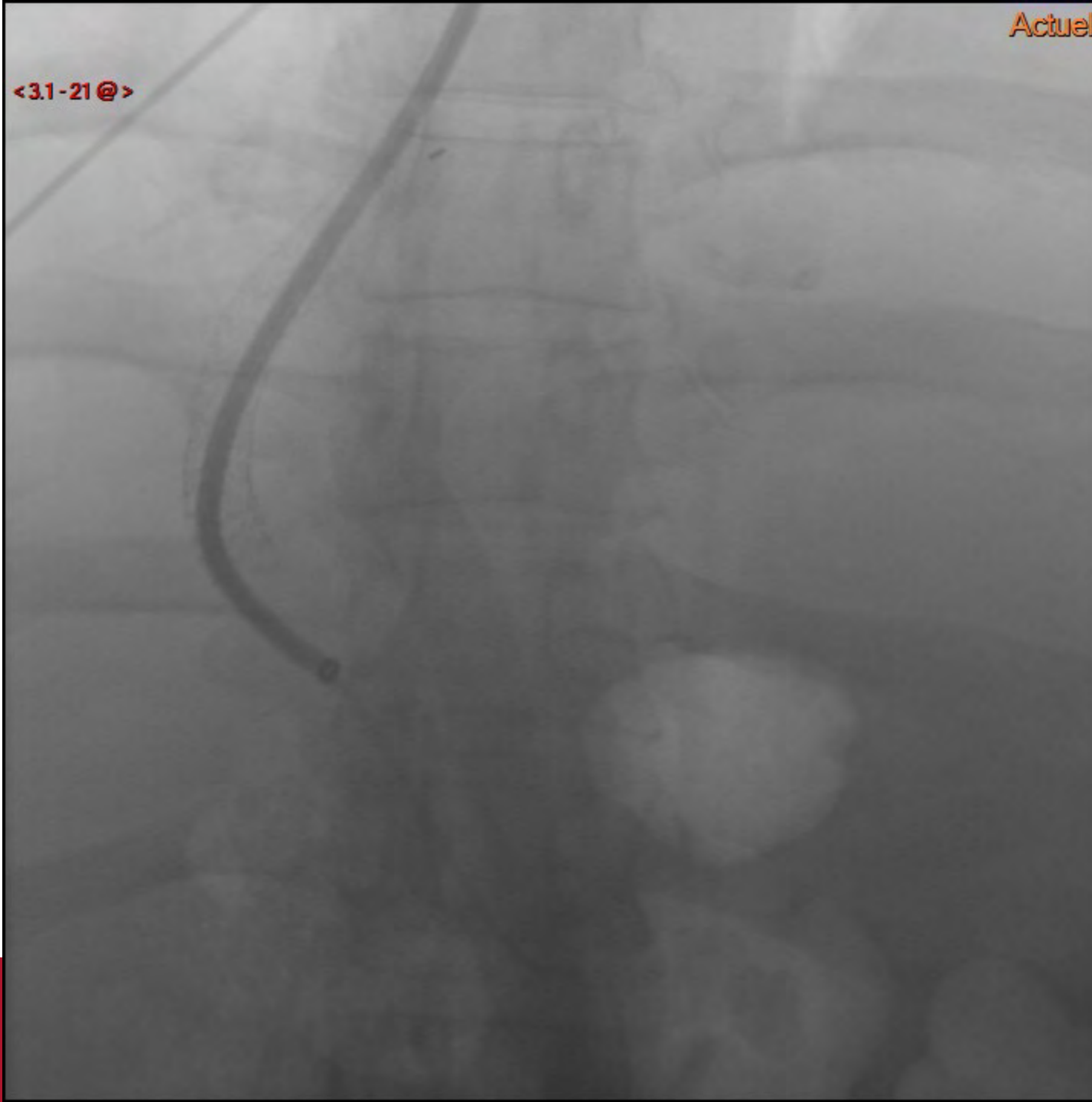
<3.1-19@>



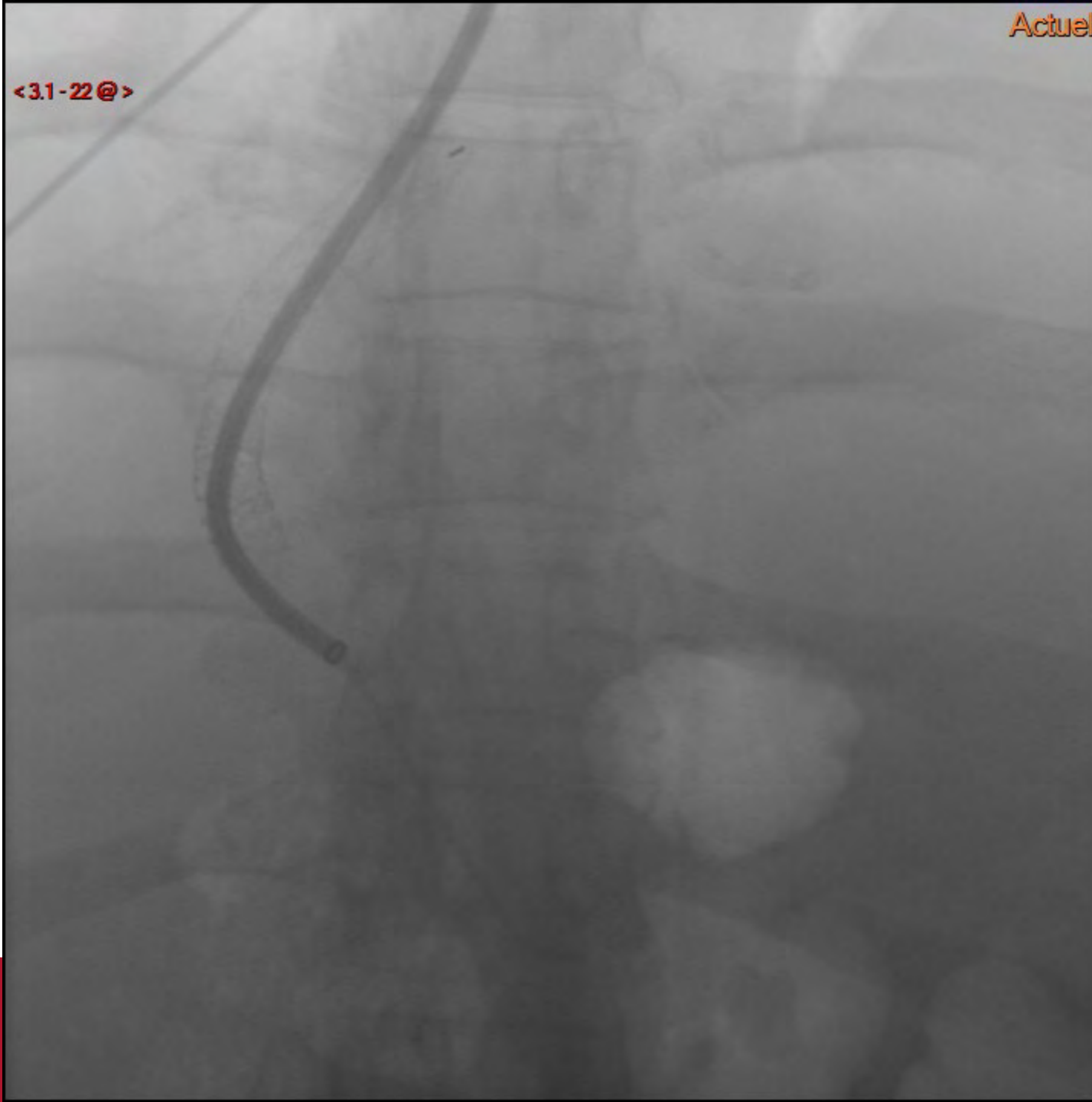
<3.1-20@>



<3.1-21@>



<3.1-22@>



Evolution

- Pose de TIPS
 - Grad post 8mmHg
 - Flapping isolé à J1, résolutif
 - Pas d'IHC
 - Sortie à J3 en brancard
- Contrôle à M1
 - Debout, perte de 41 kg; pas d'EH, fragilité 4,12
 - 2 ponctions
 - Child C12, MELD 21

Réunion de concertation multidisciplinaire TIPS/TH

160 patients discutés TIPS ou TH



Décision multidisciplinaire



**TIPS seul
n= 30**

**TIPS et TH si besoin
n=37**

**Pas de TIPS TH seule
n=29**

**Patients récusés
TIPS et TH n=64**

**TIPS seul posé
n=58**

**TIPS et TH
n=9**

**TH seule
n=12**

**Ni TIPS ni TH
n=81**

**Survie à 1 an
67 %**

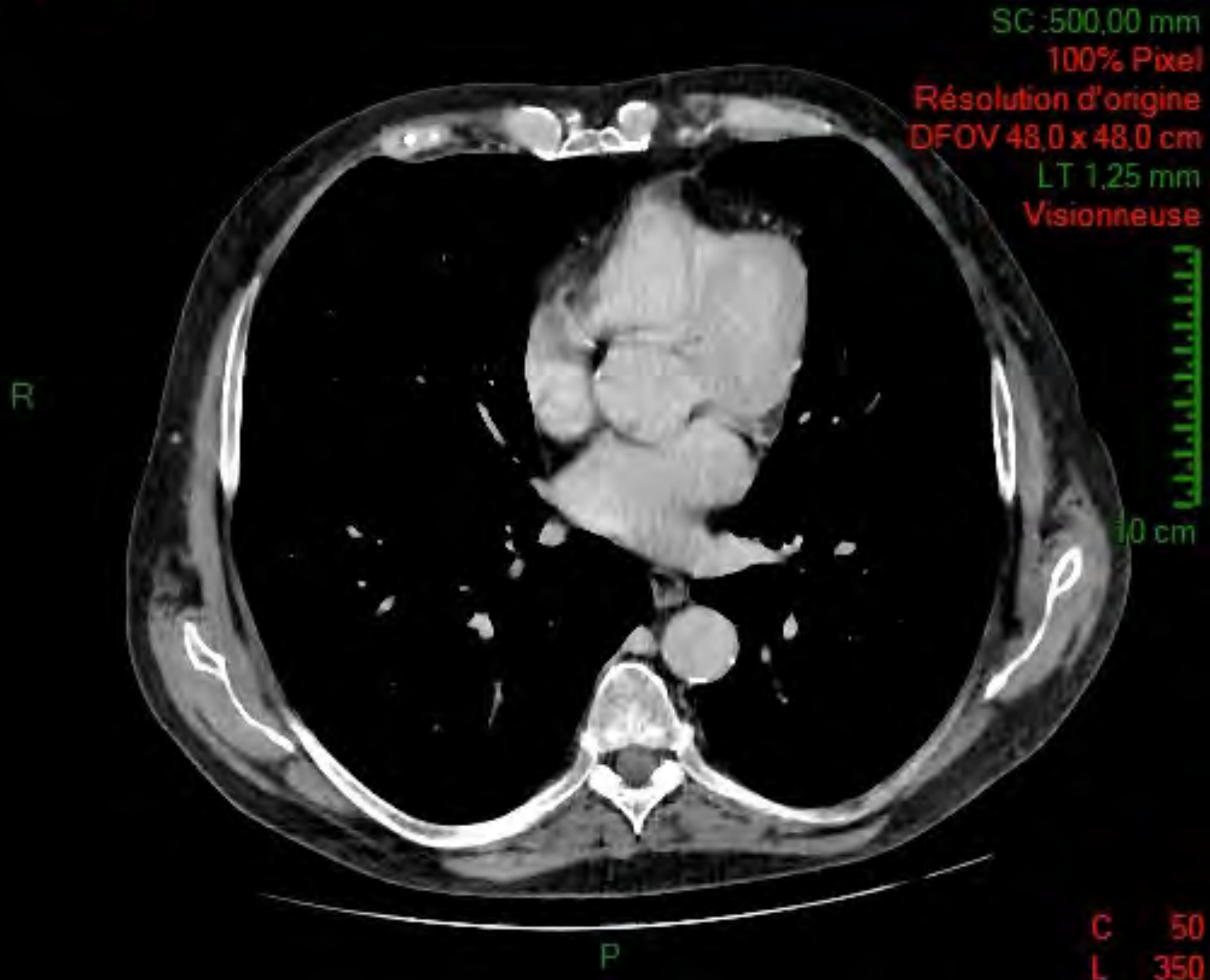
**Survie à 1 an
87 %**

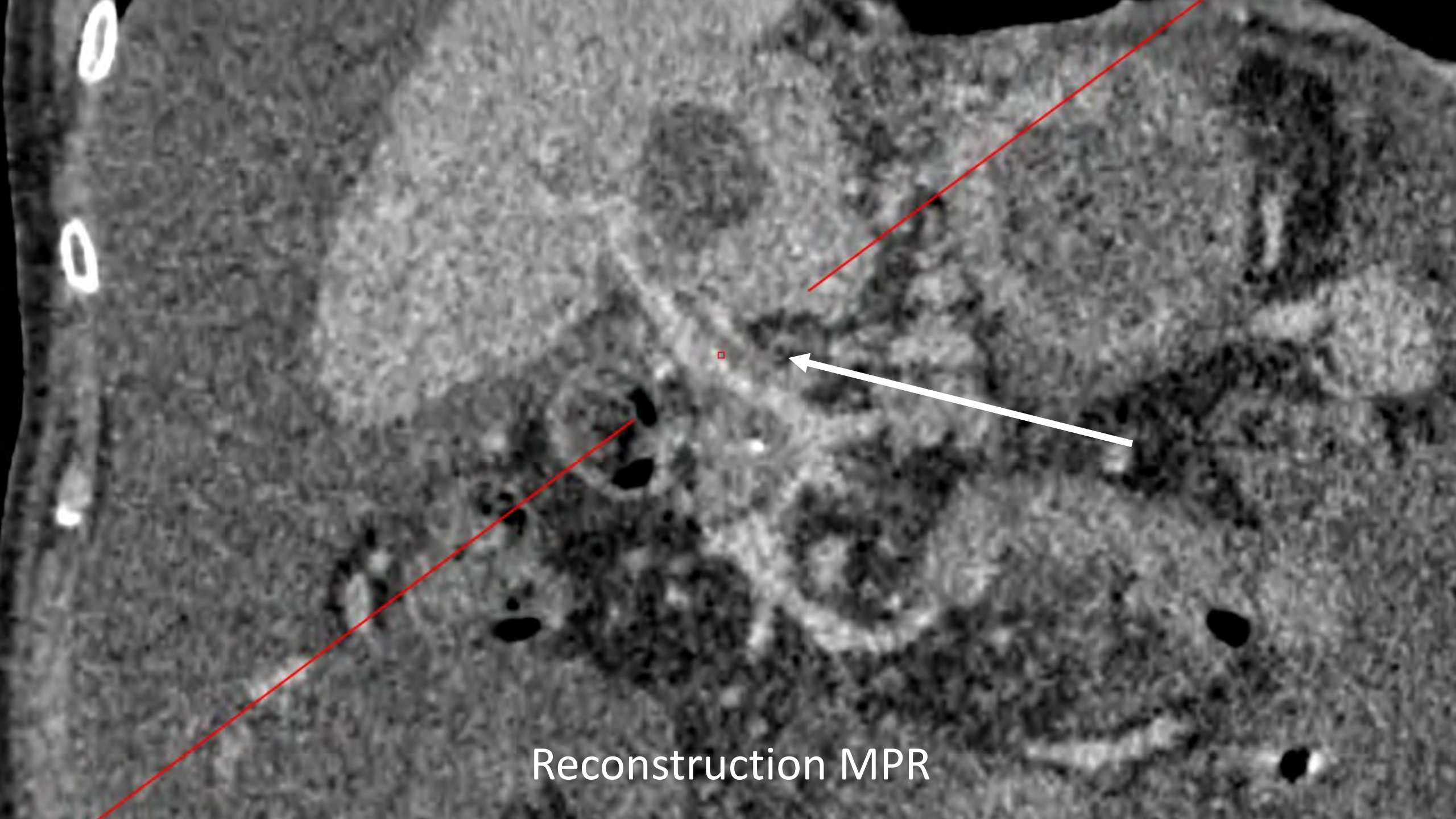
**Survie à 1 an
100 %**

**Survie à 1 an
64 %**

Cas n°2

- Homme 76 ans
- Cirrhose liée à une conso OH et un syndrome métabolique (ancien obèse), sevrage OK
- Ascite R (IR sous diurétiques), 1 ISLA, 1 ponction de 8L par semaine, jamais EH, pas de CHC ni de thrombose porte
- 19 animaux en 60 secondes
- Bio: Hb 9 g/dL, Plaq 91.000/mm³, Bili 18/11 micromol/L , Albu 24, créat 114 micromol/L, TP 60%, FV 68%
- Bilan cardiaque bio et morphologique N
- Child B9, MELD 15
- **79 ans**
- BMI 29 au moment de la discussion (mais ascite grande abondance)
- **Fragilité: 5,21 (lever impossible)**
- **FIPS score: 0,53**





Reconstruction MPR

Cas n°2

TIPS

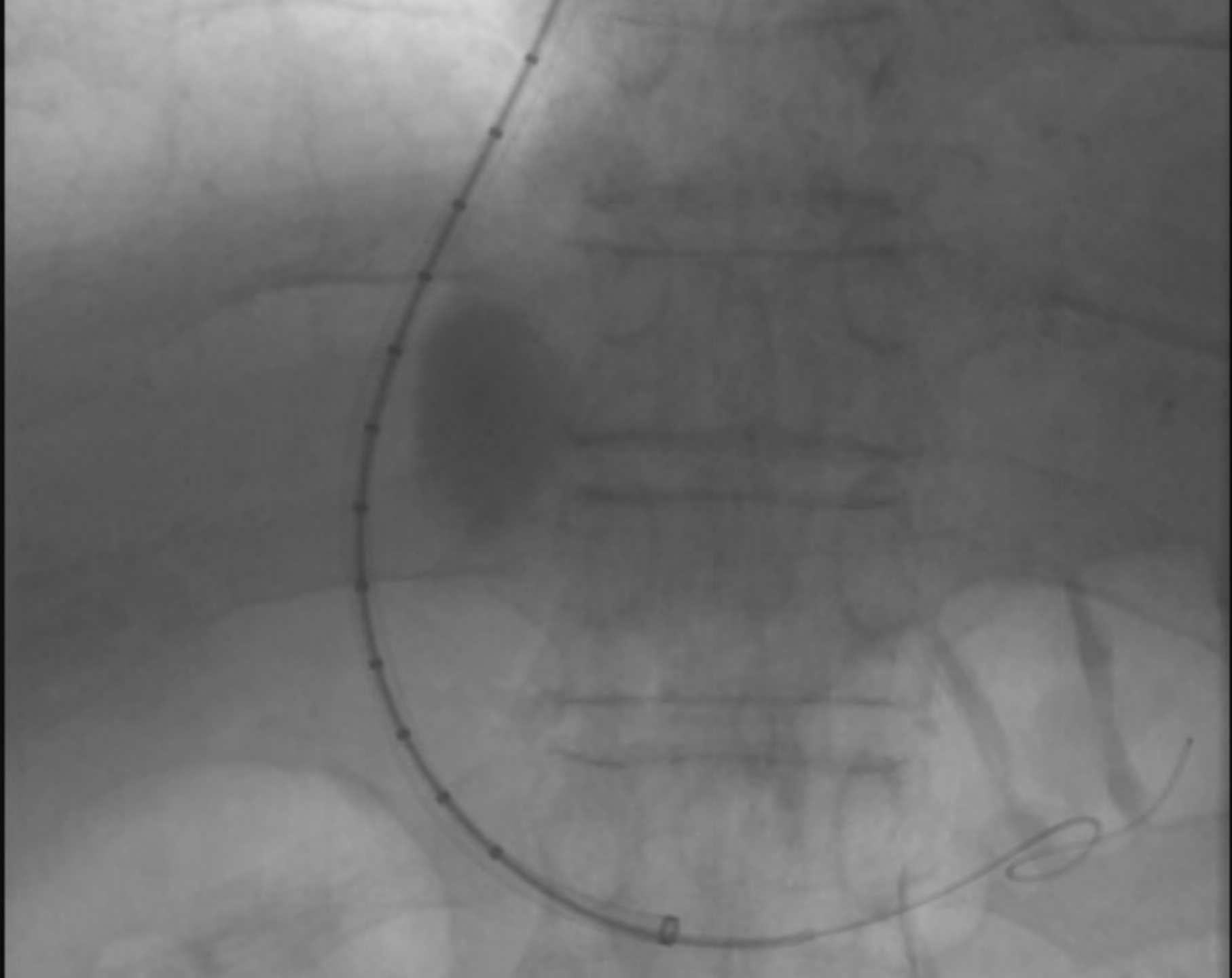
- Le pour
 - Indication de TIPS
 - Patient très actif, très gêné par l'ascite
- Le contre
 - Age
 - Risque important d'EH
 - Pas de TH possible

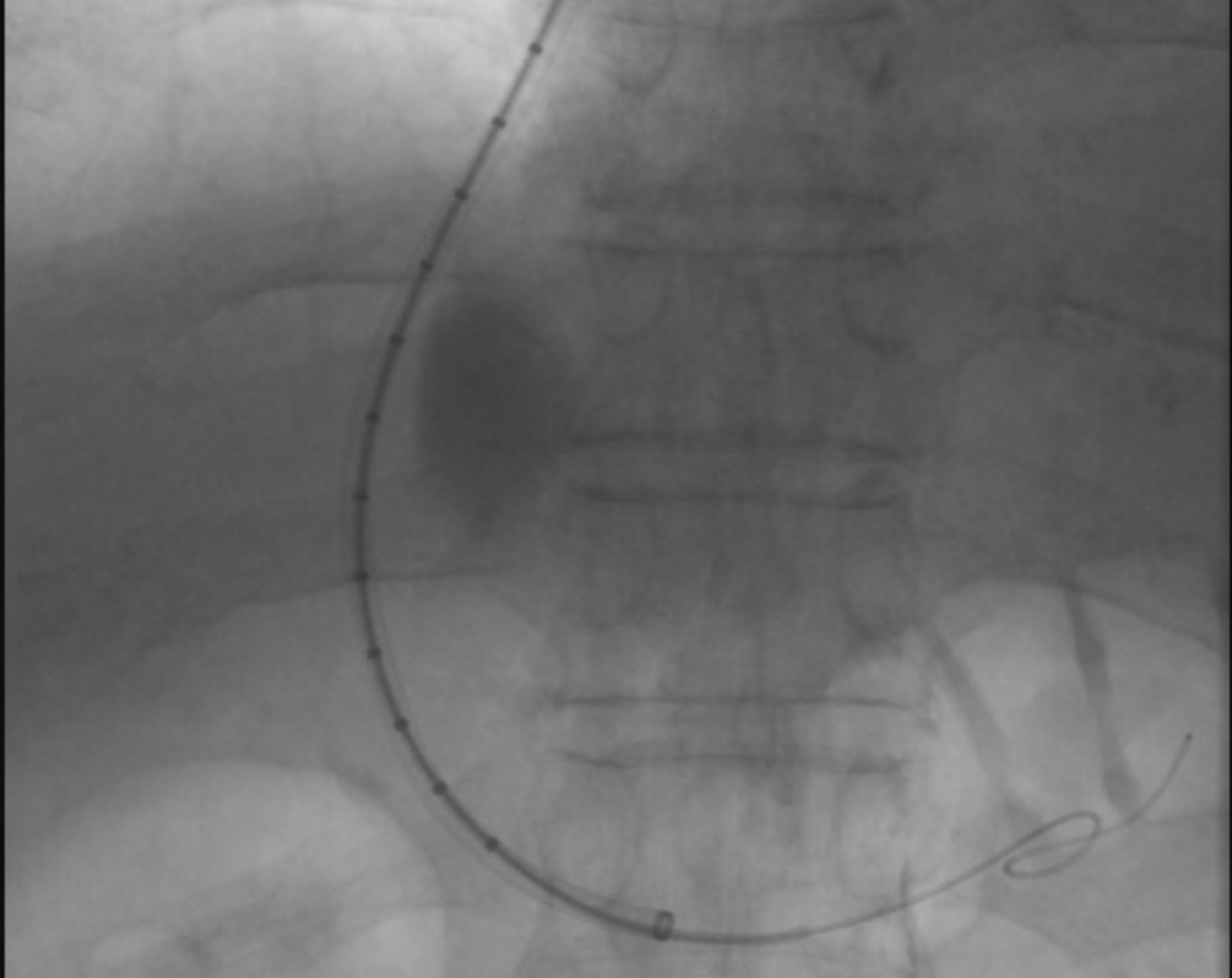
TH

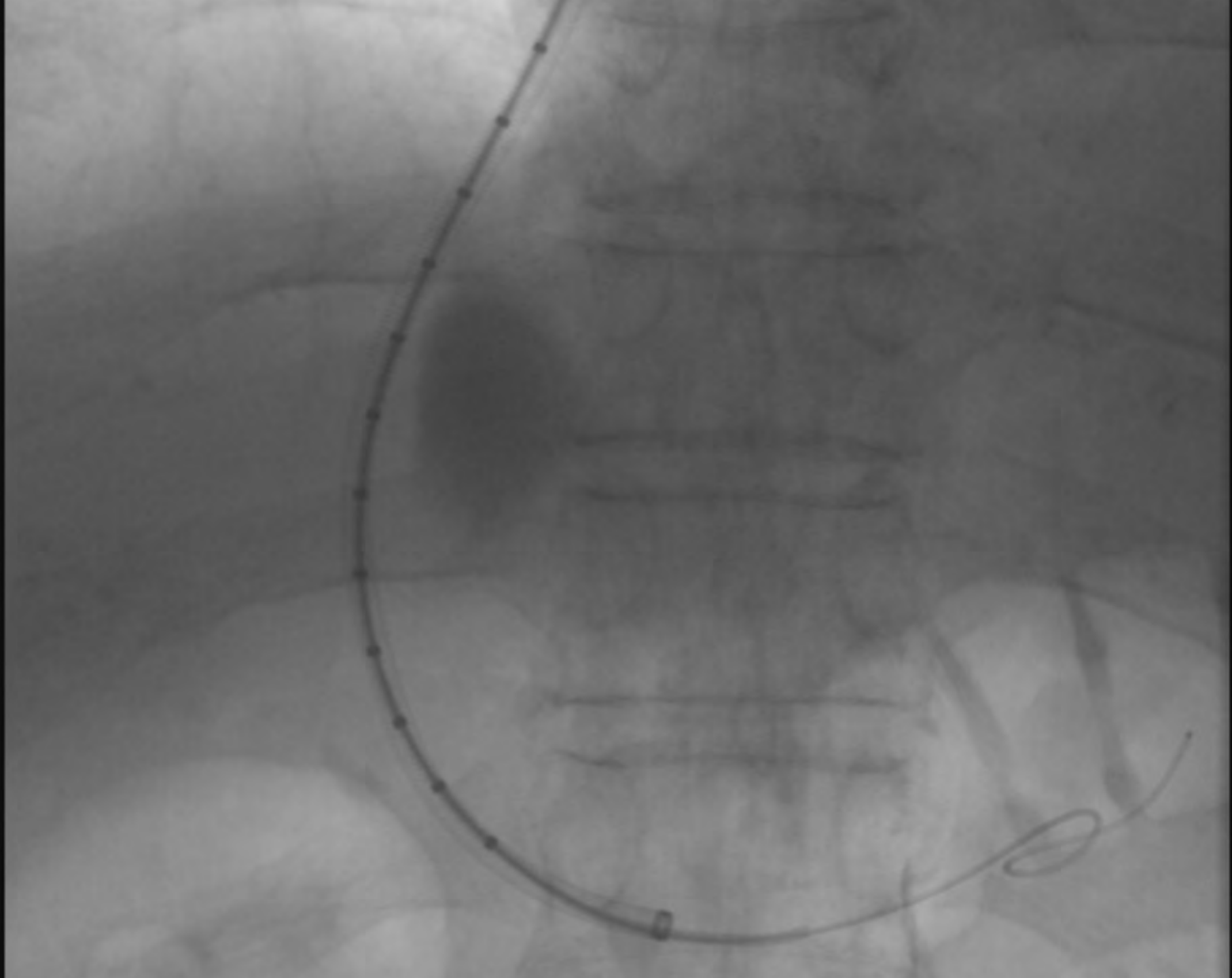
- Le pour
 - Indication de TH
 - Sevrage complet
- Le contre
 - Age

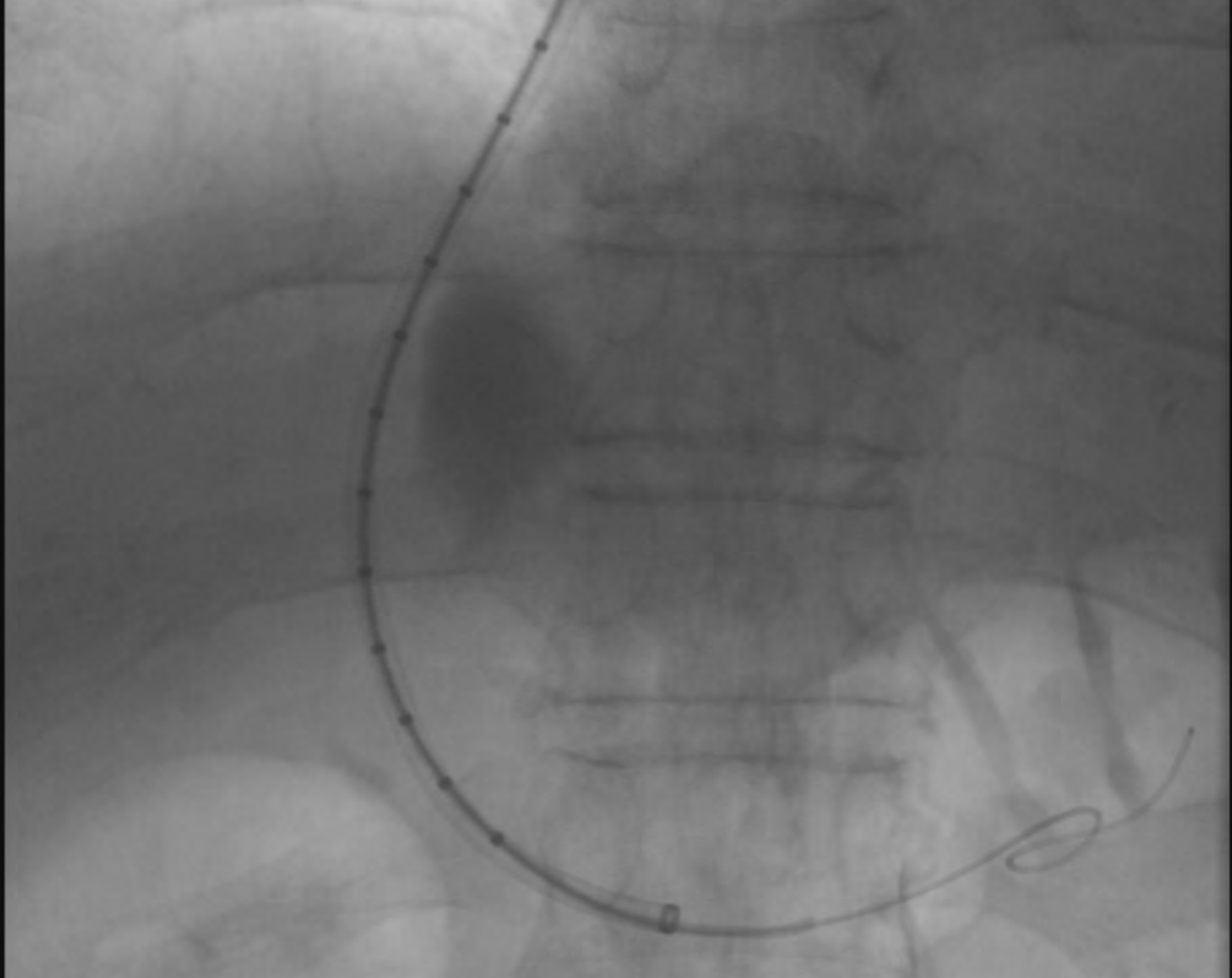
Décision RCP

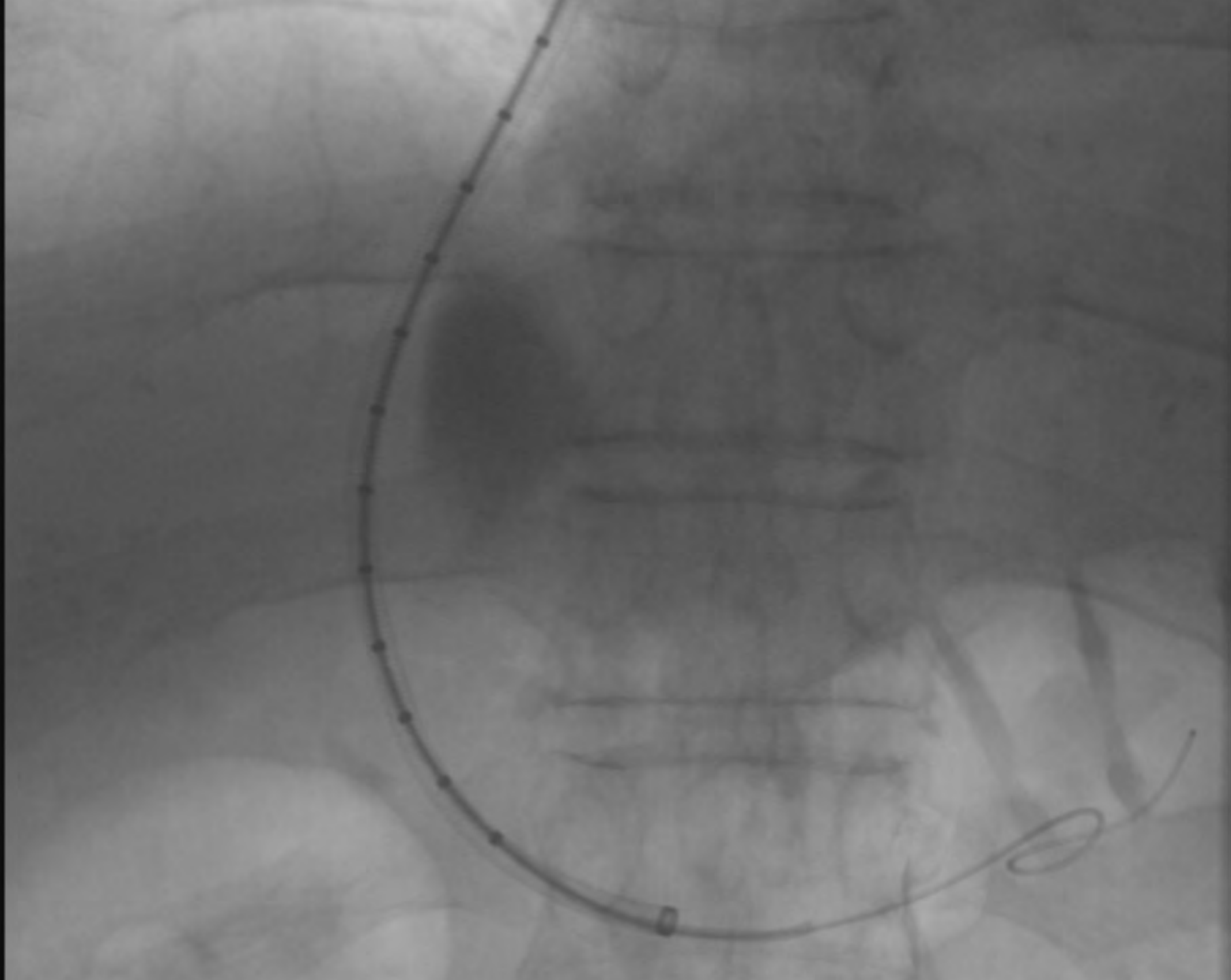
- TIPS sans TH

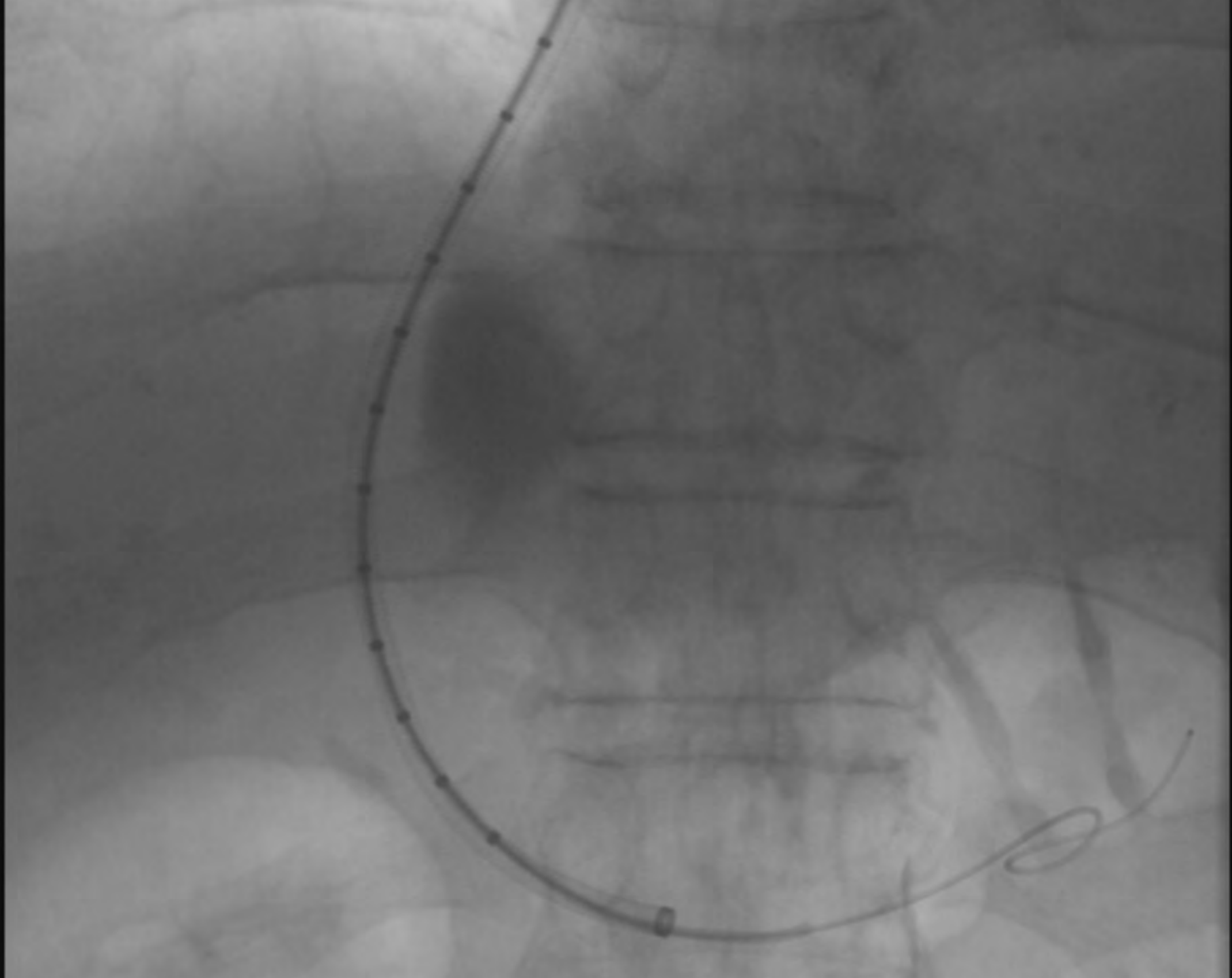


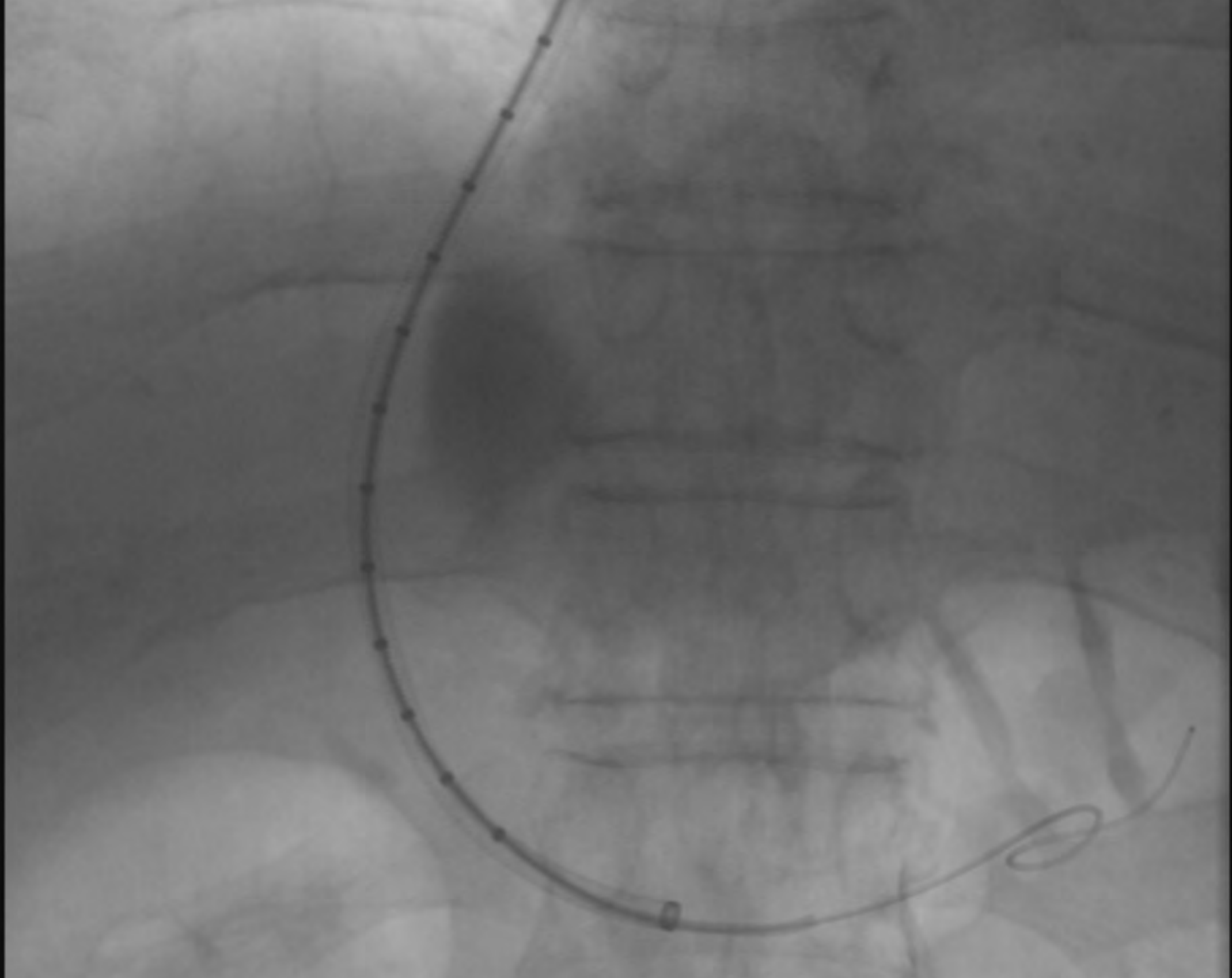


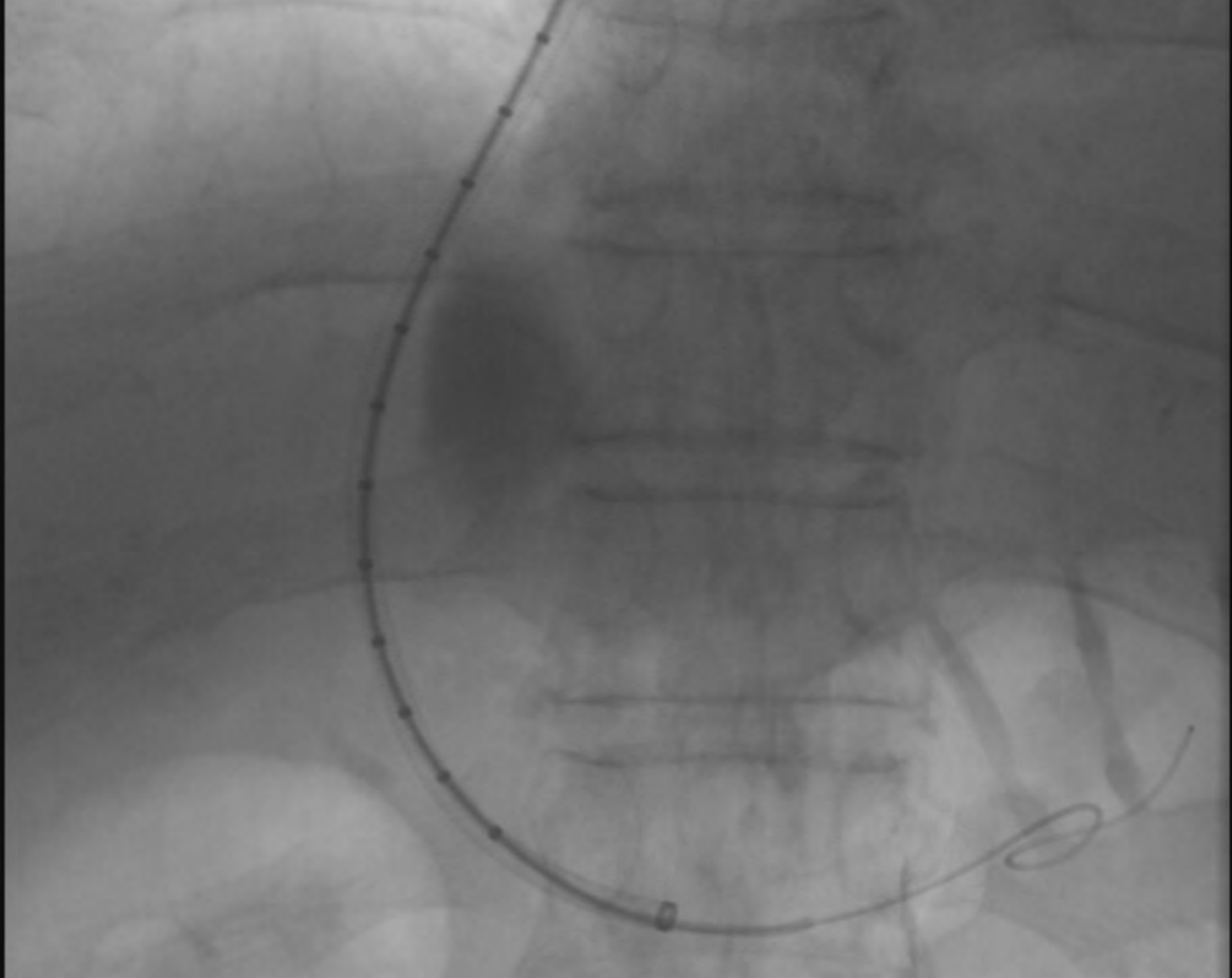


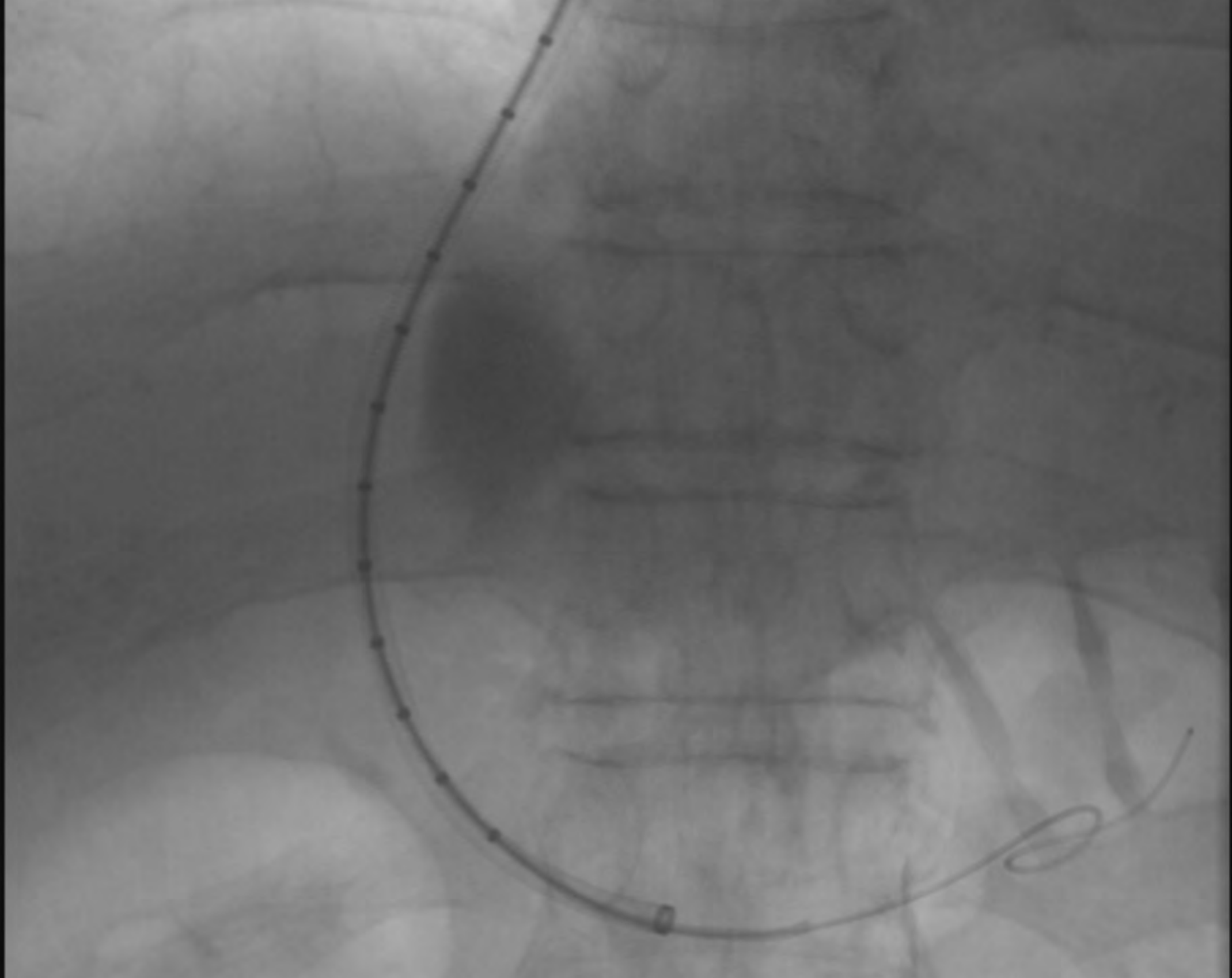


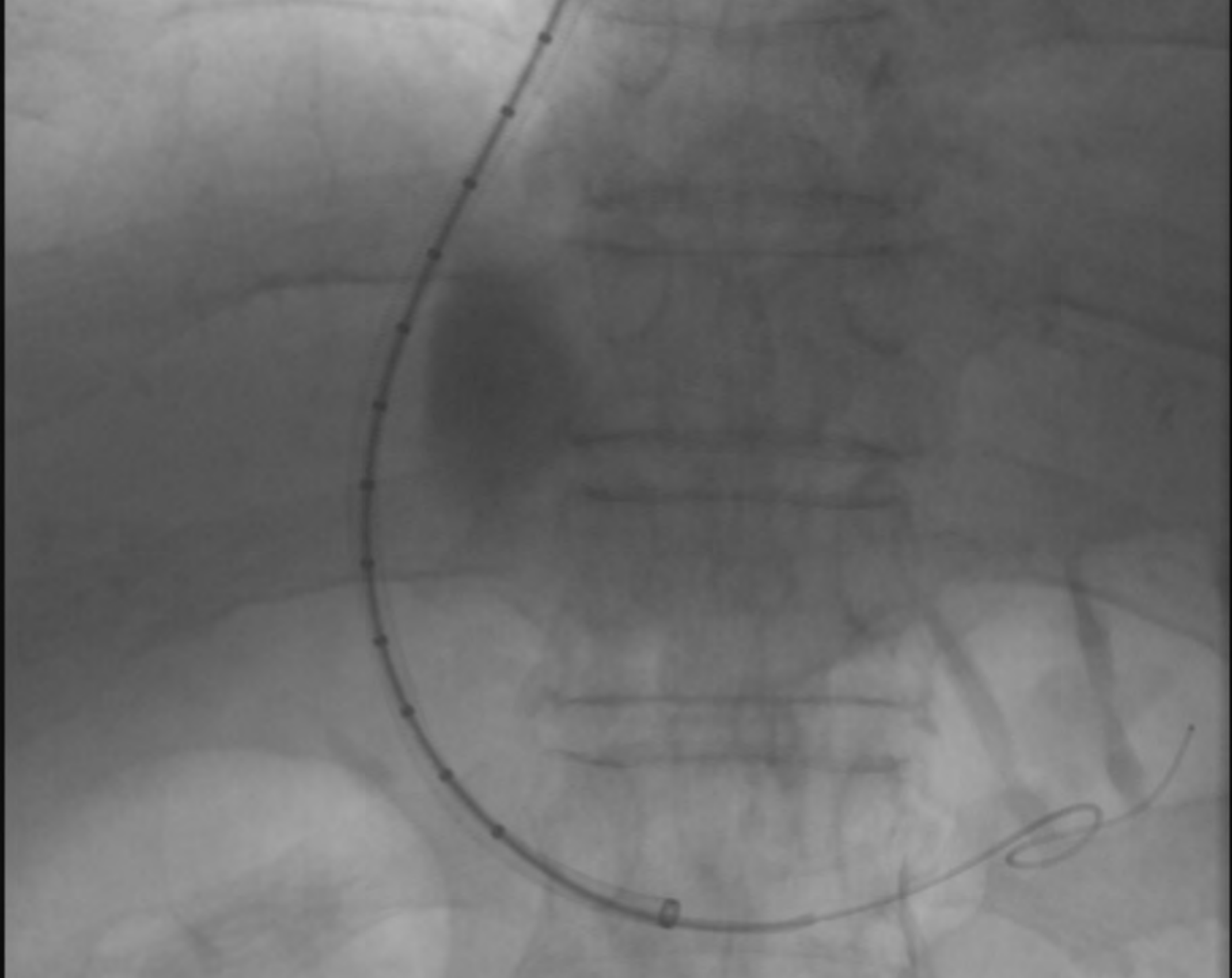


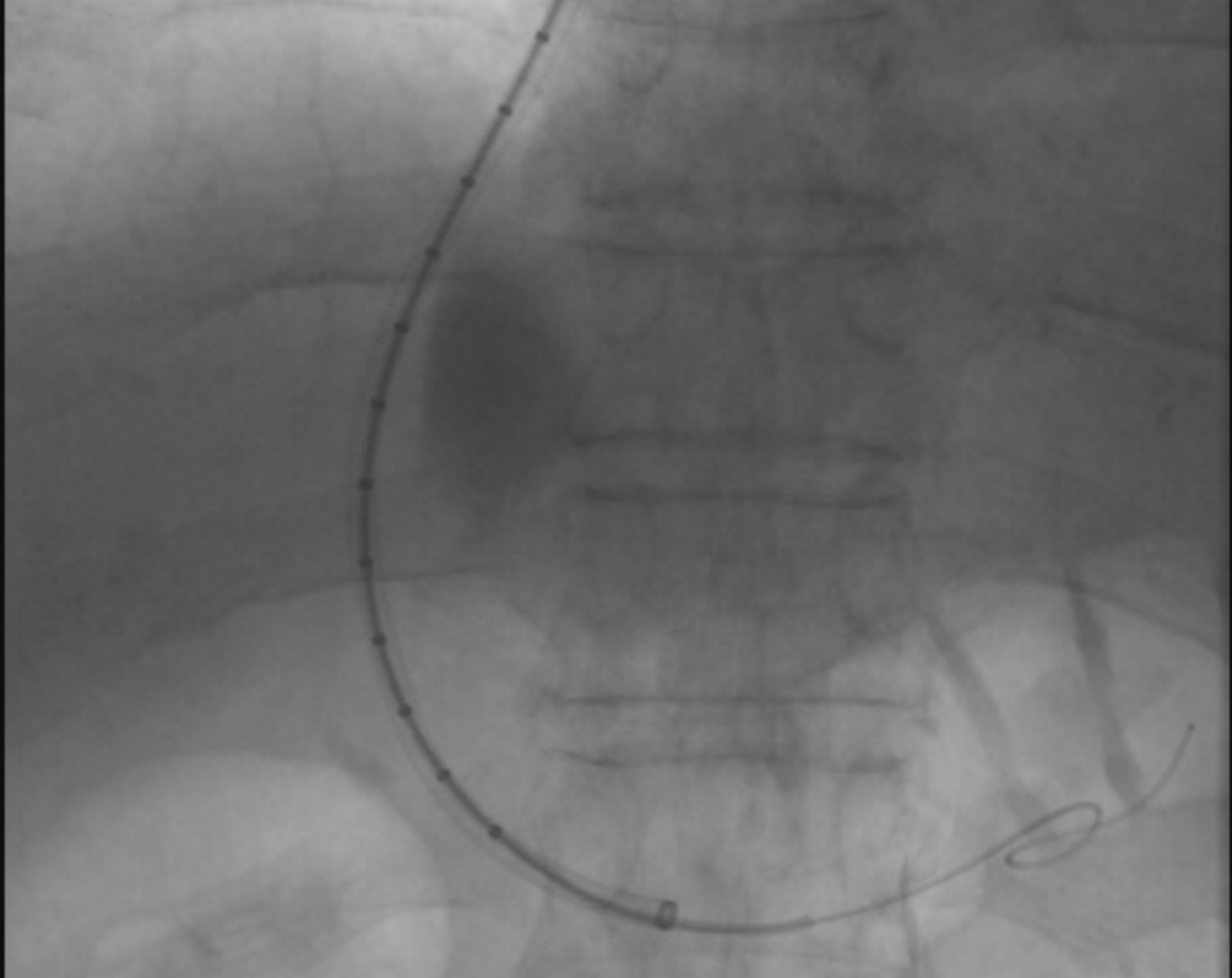


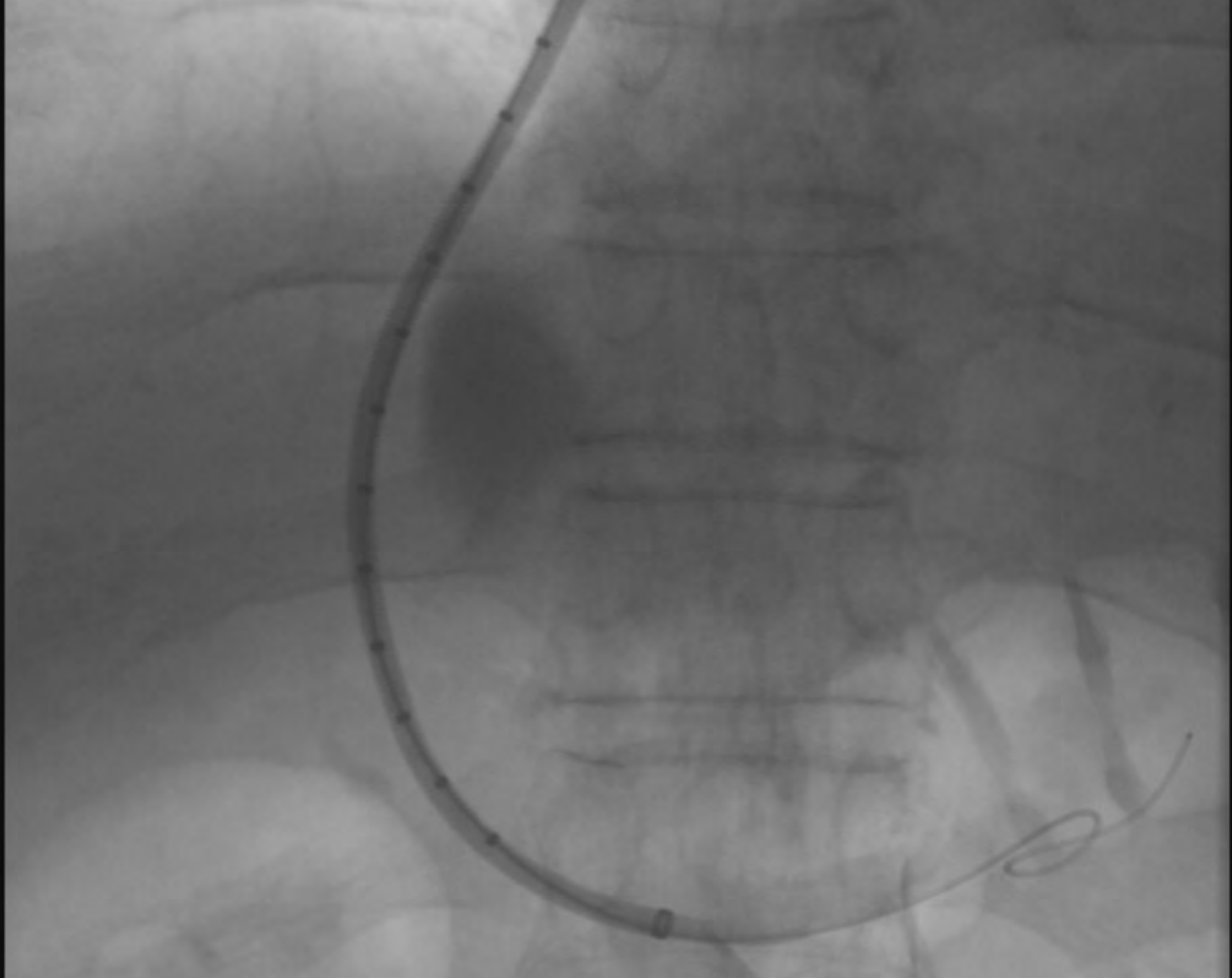


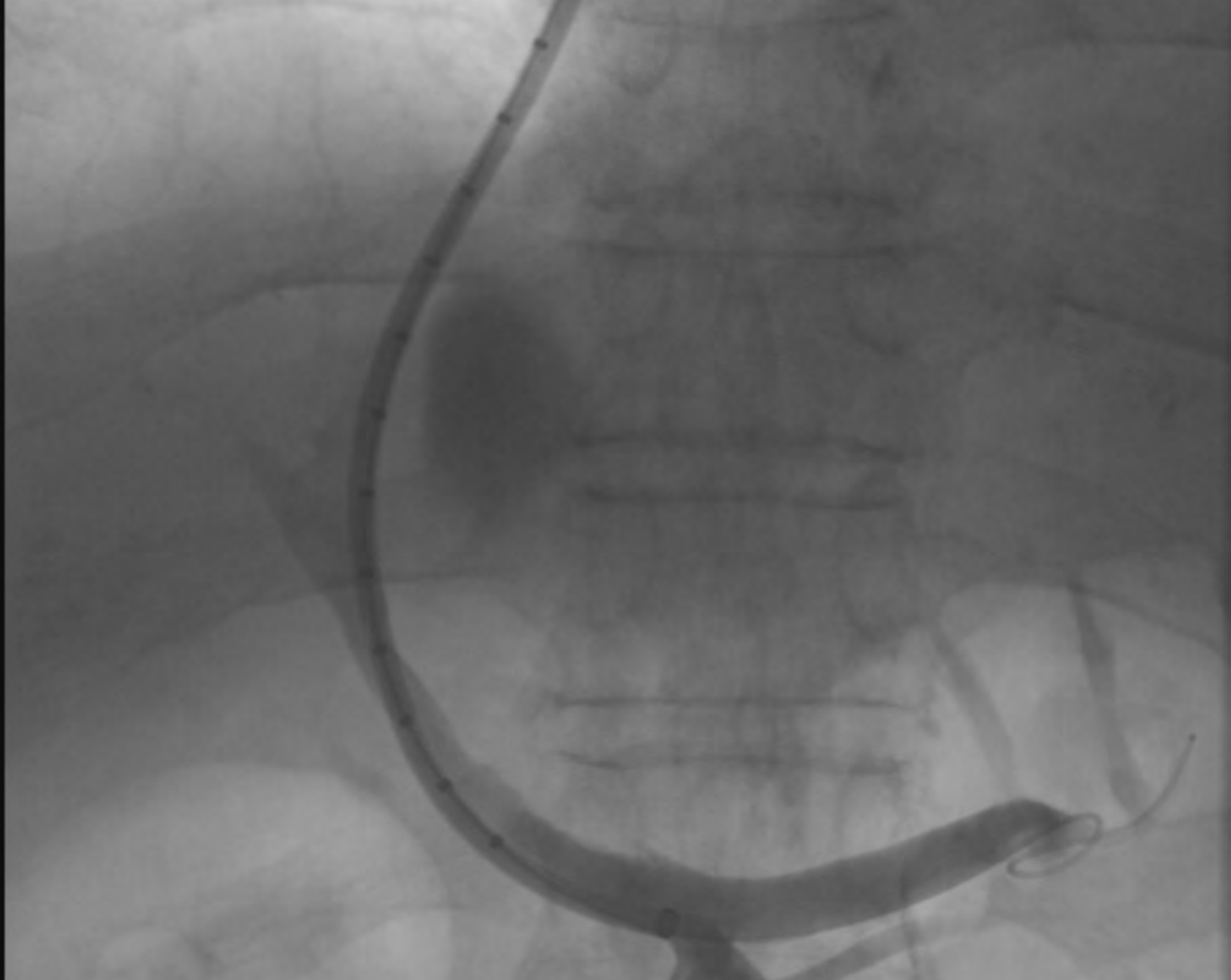


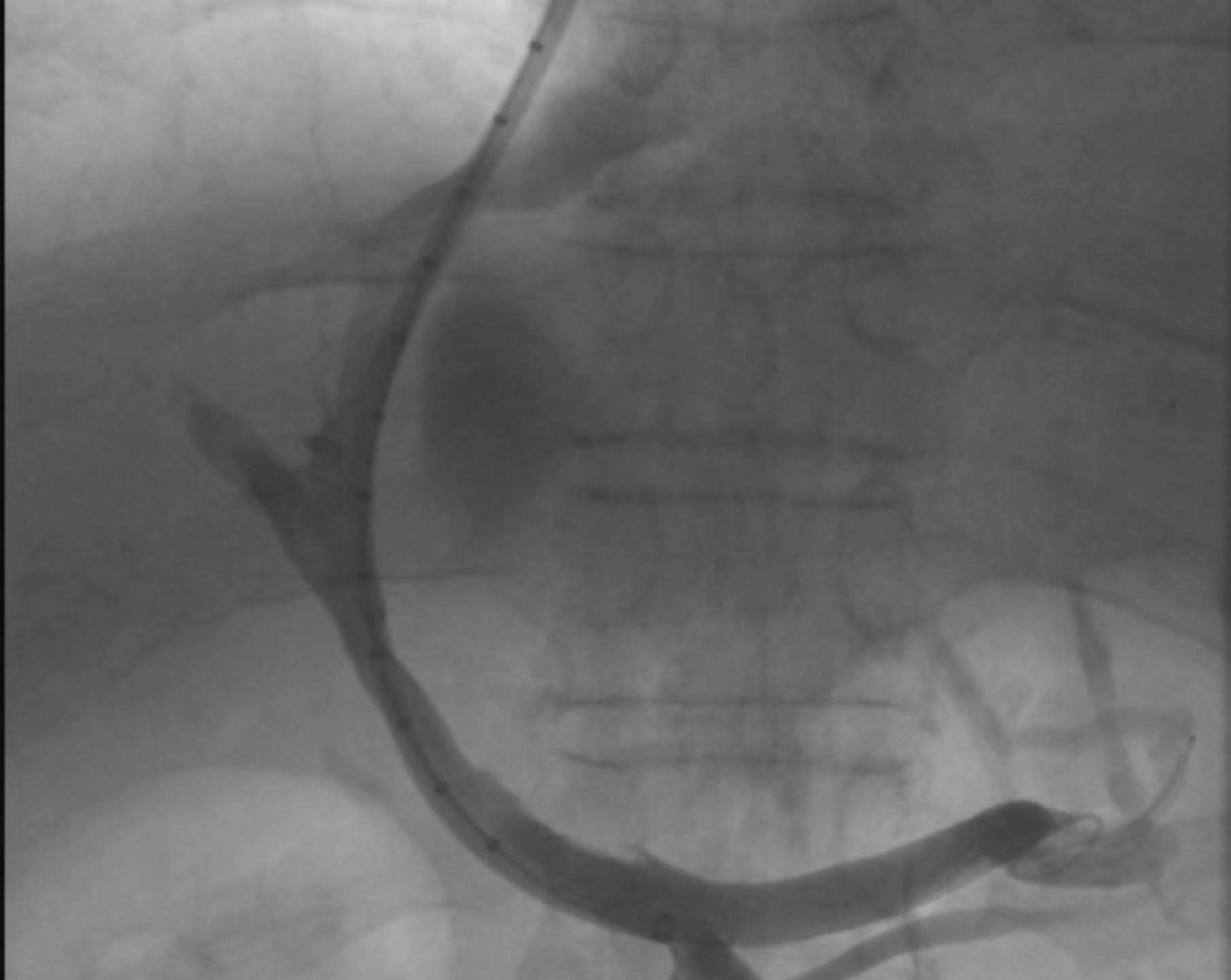
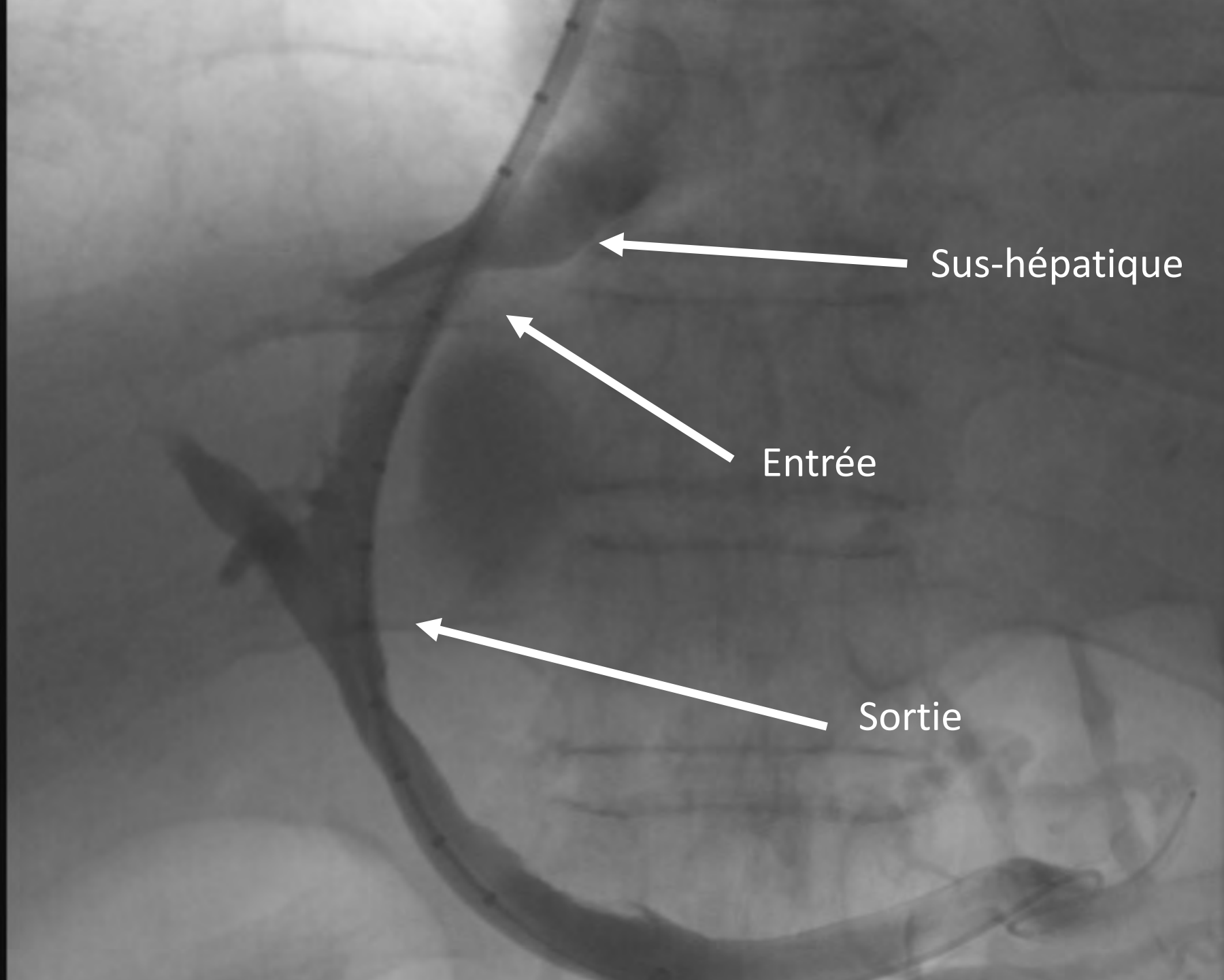




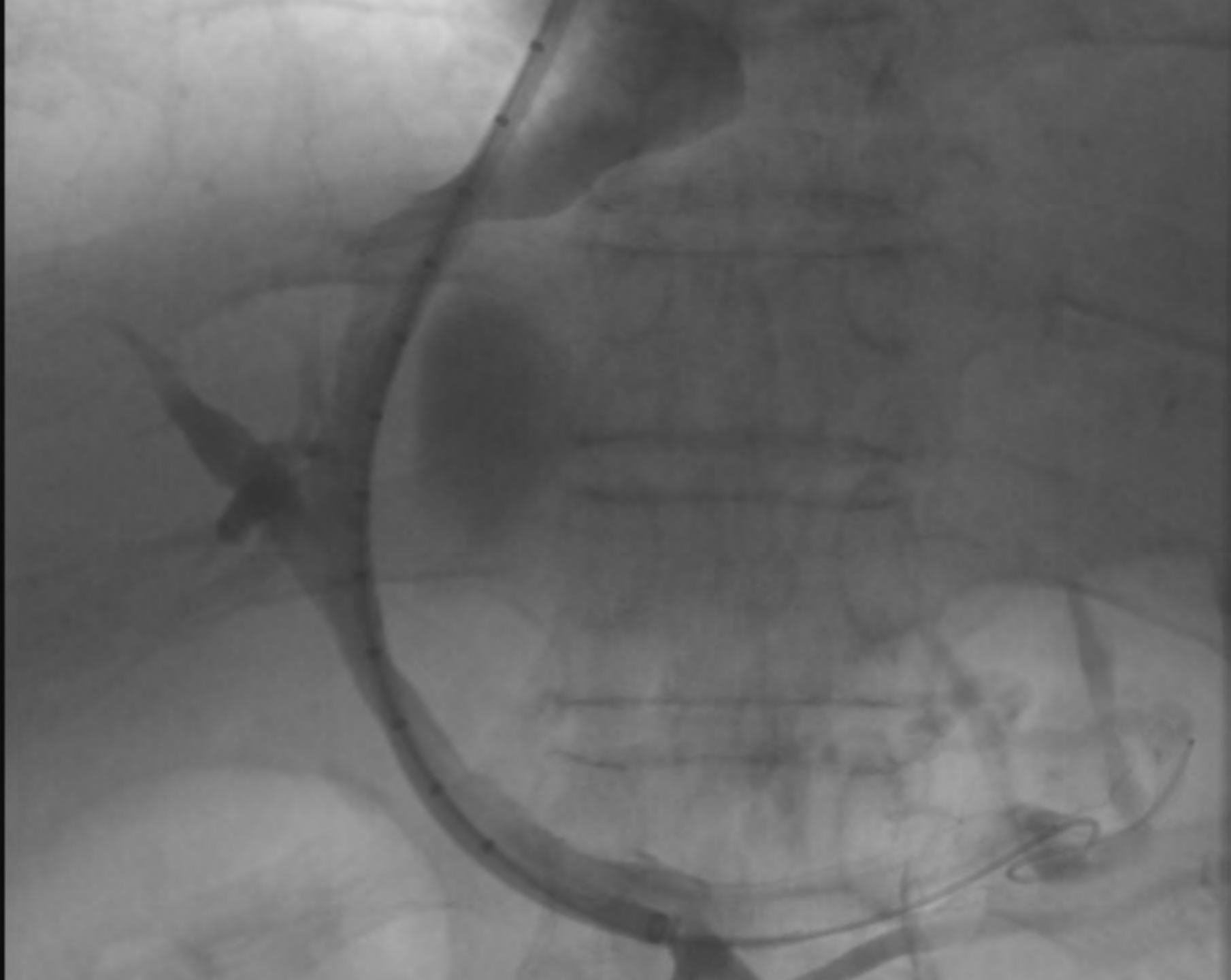


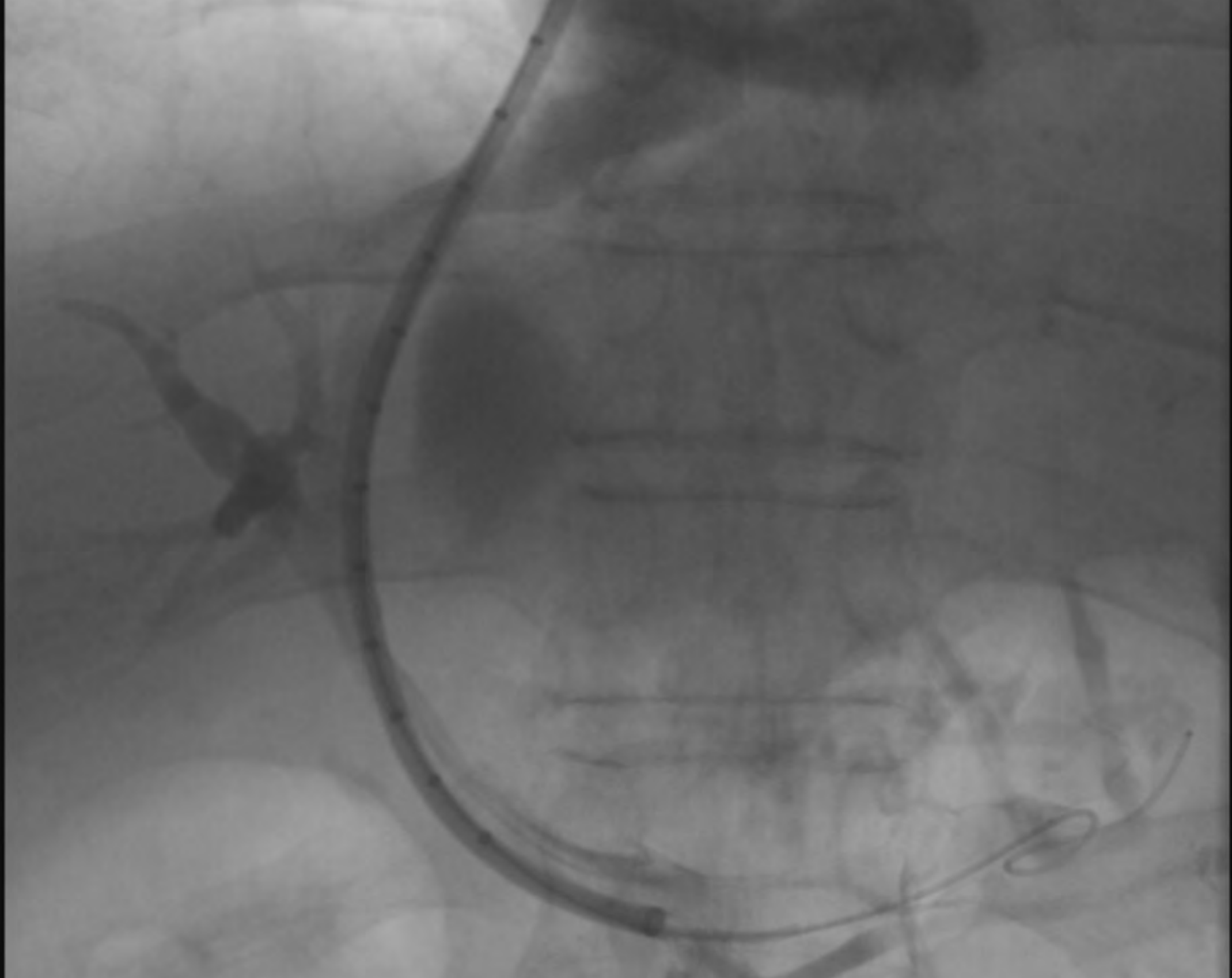
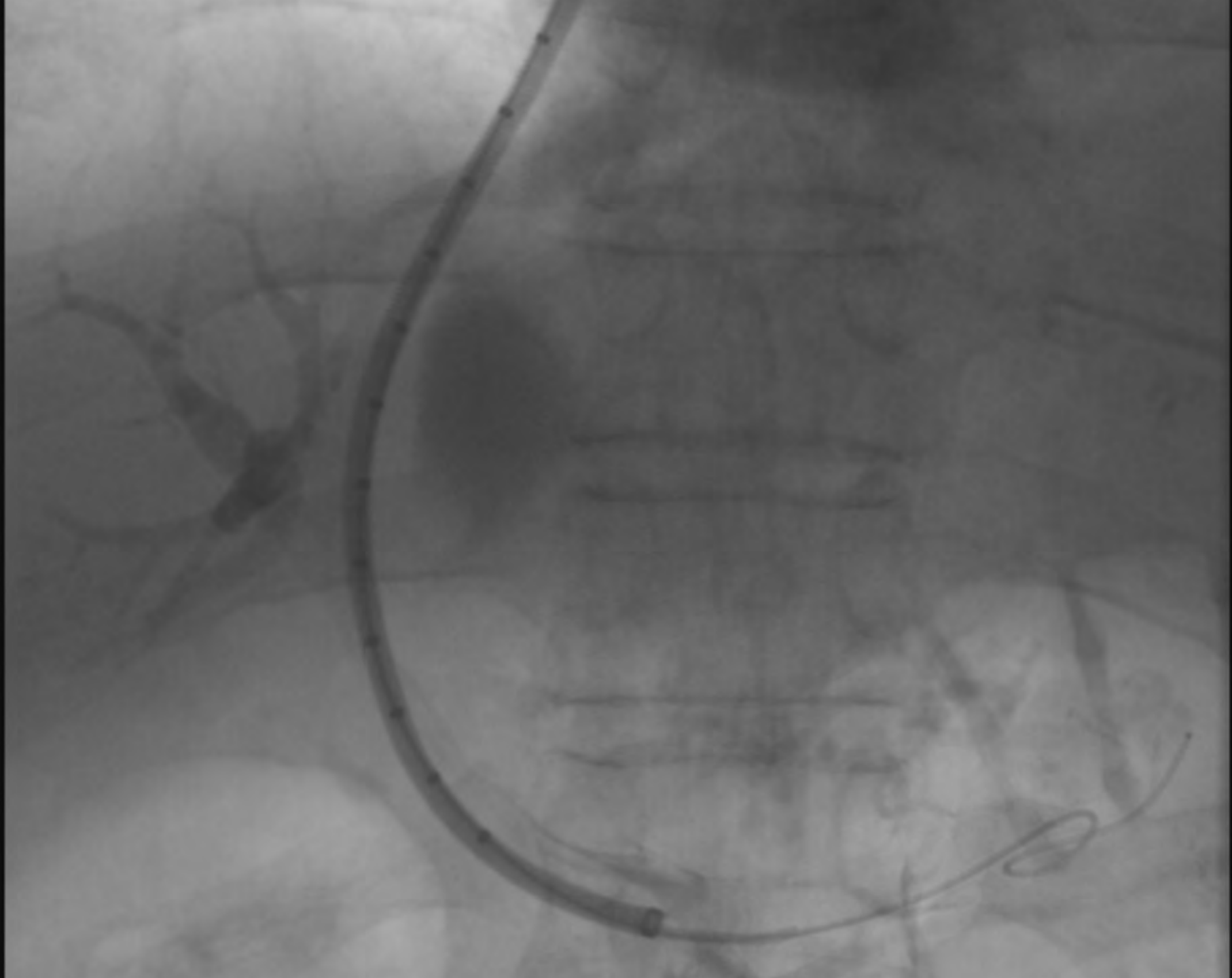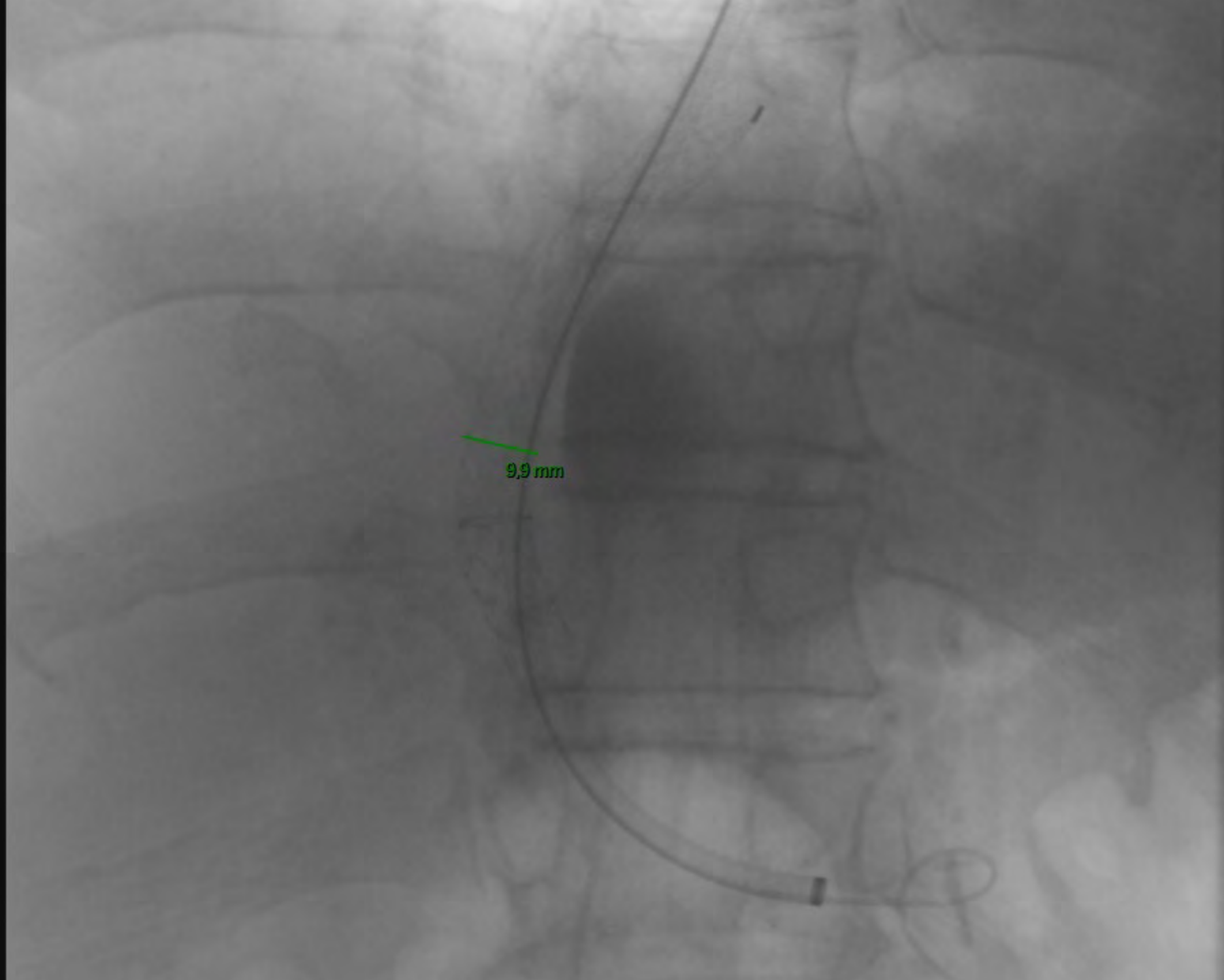


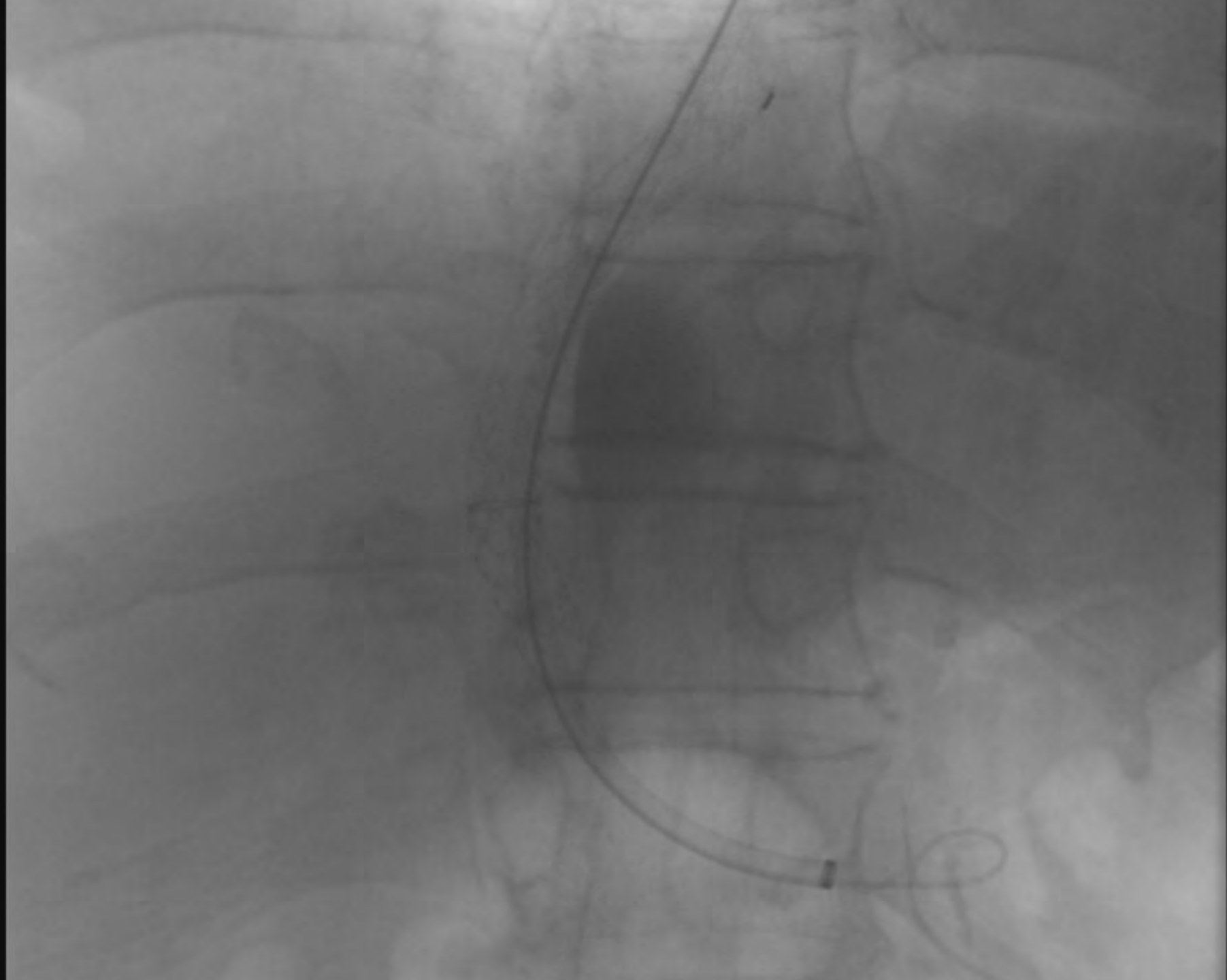


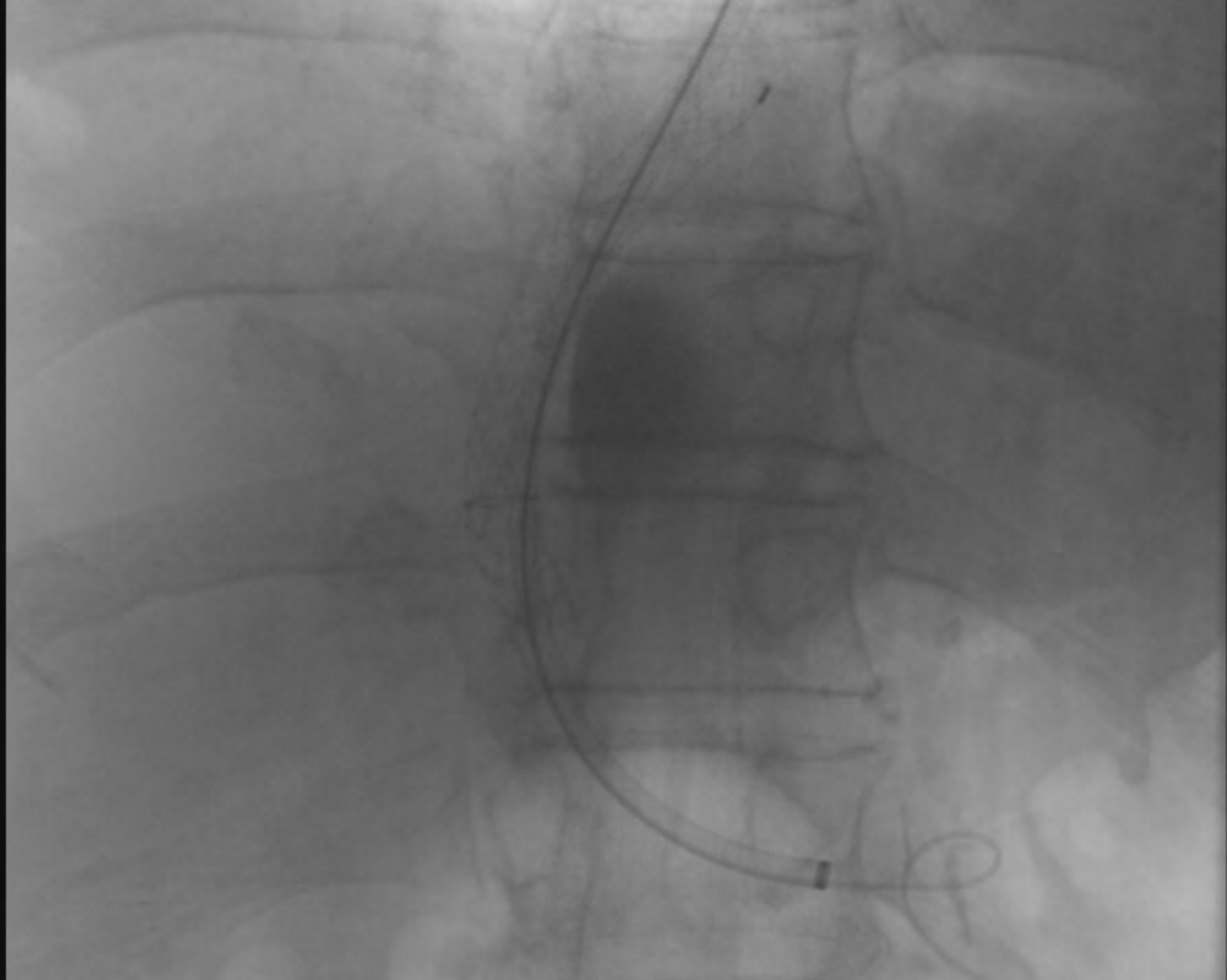


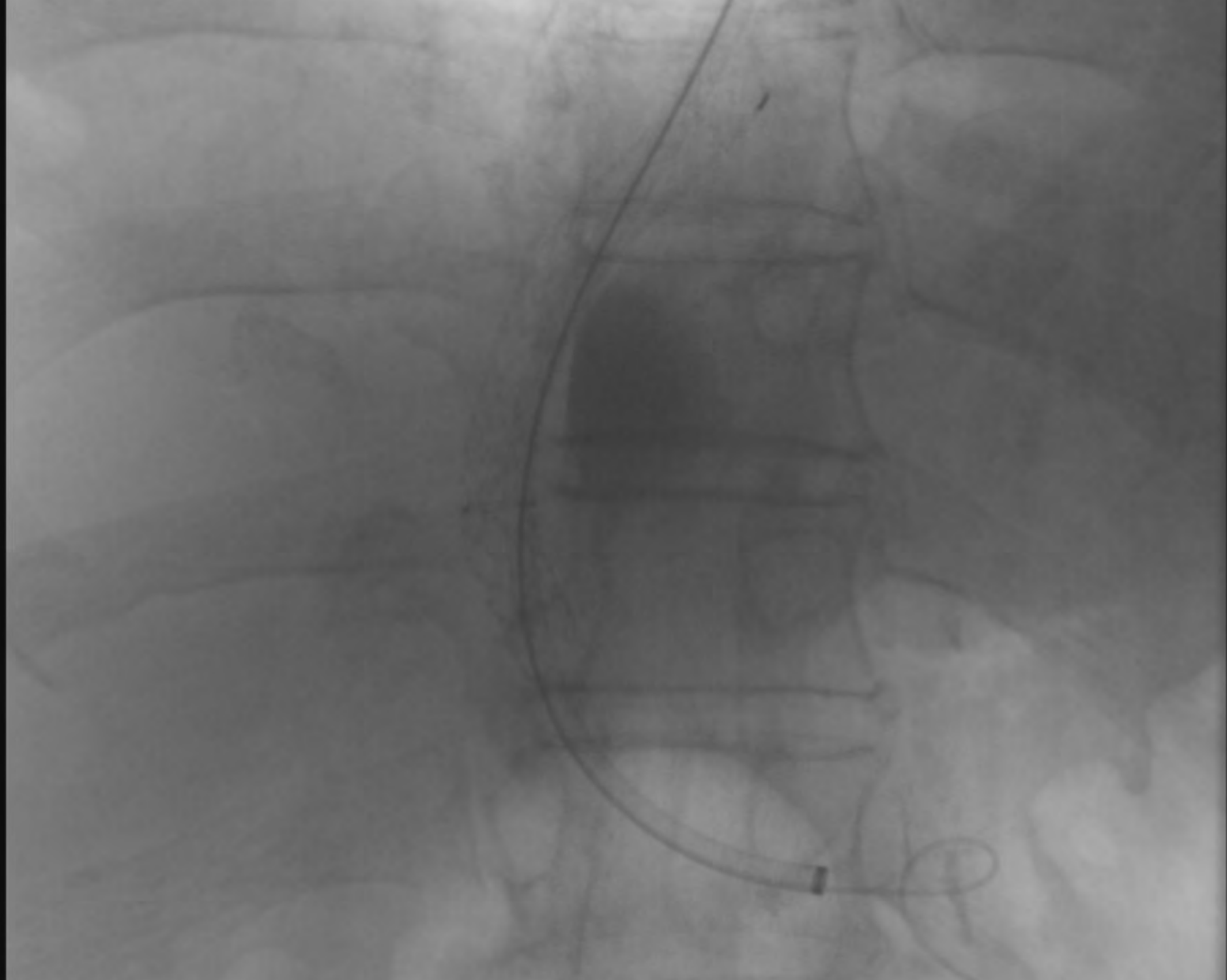


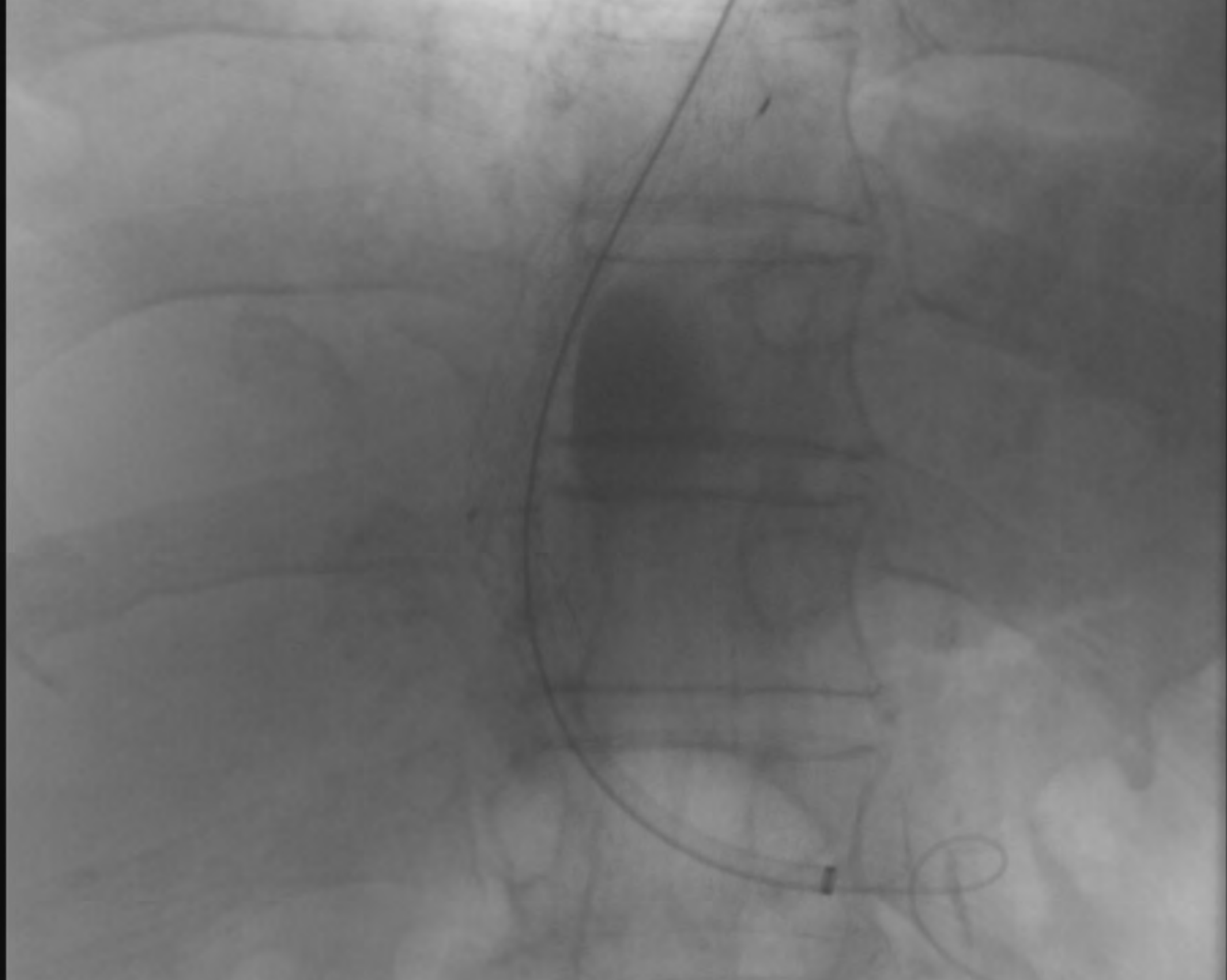


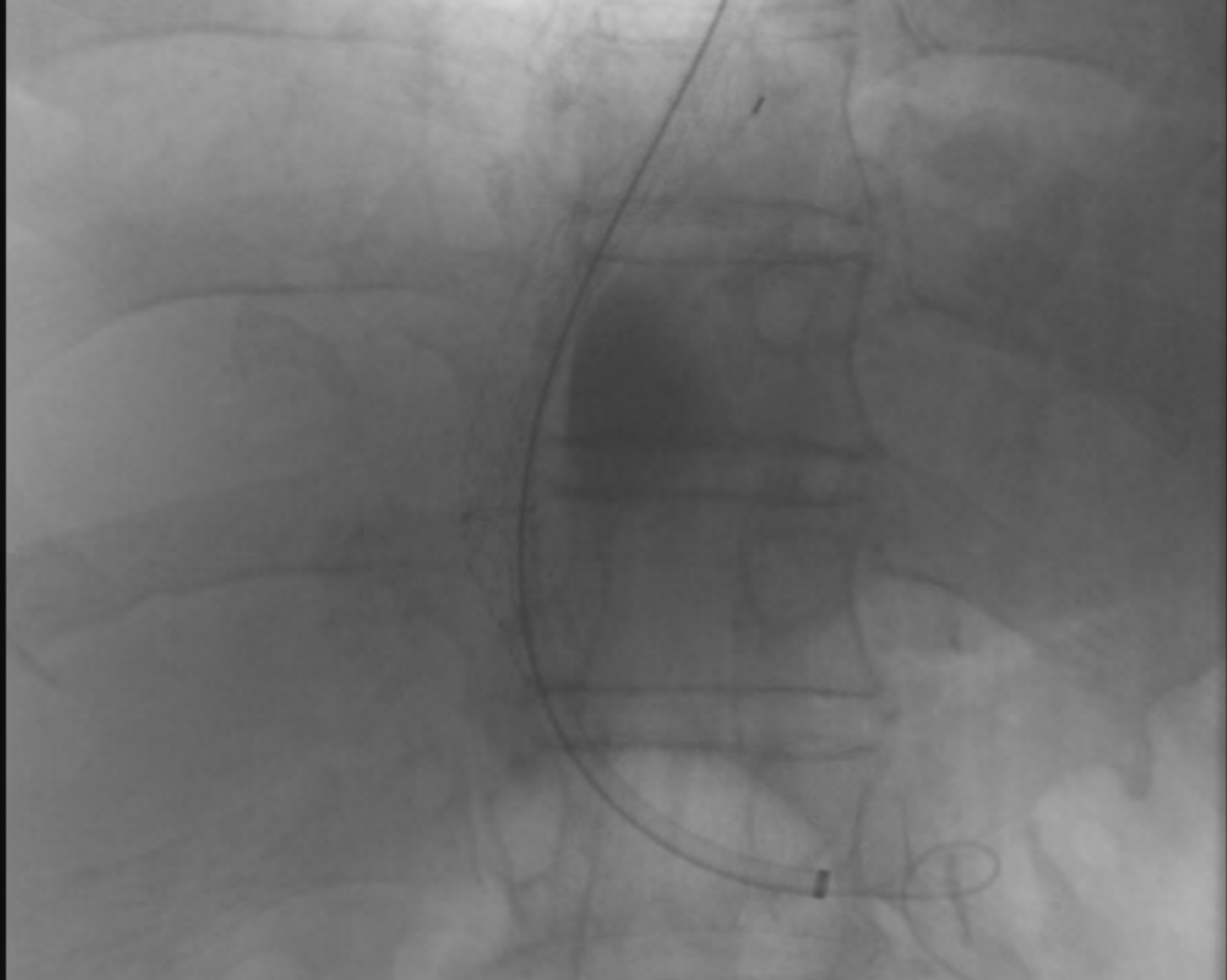


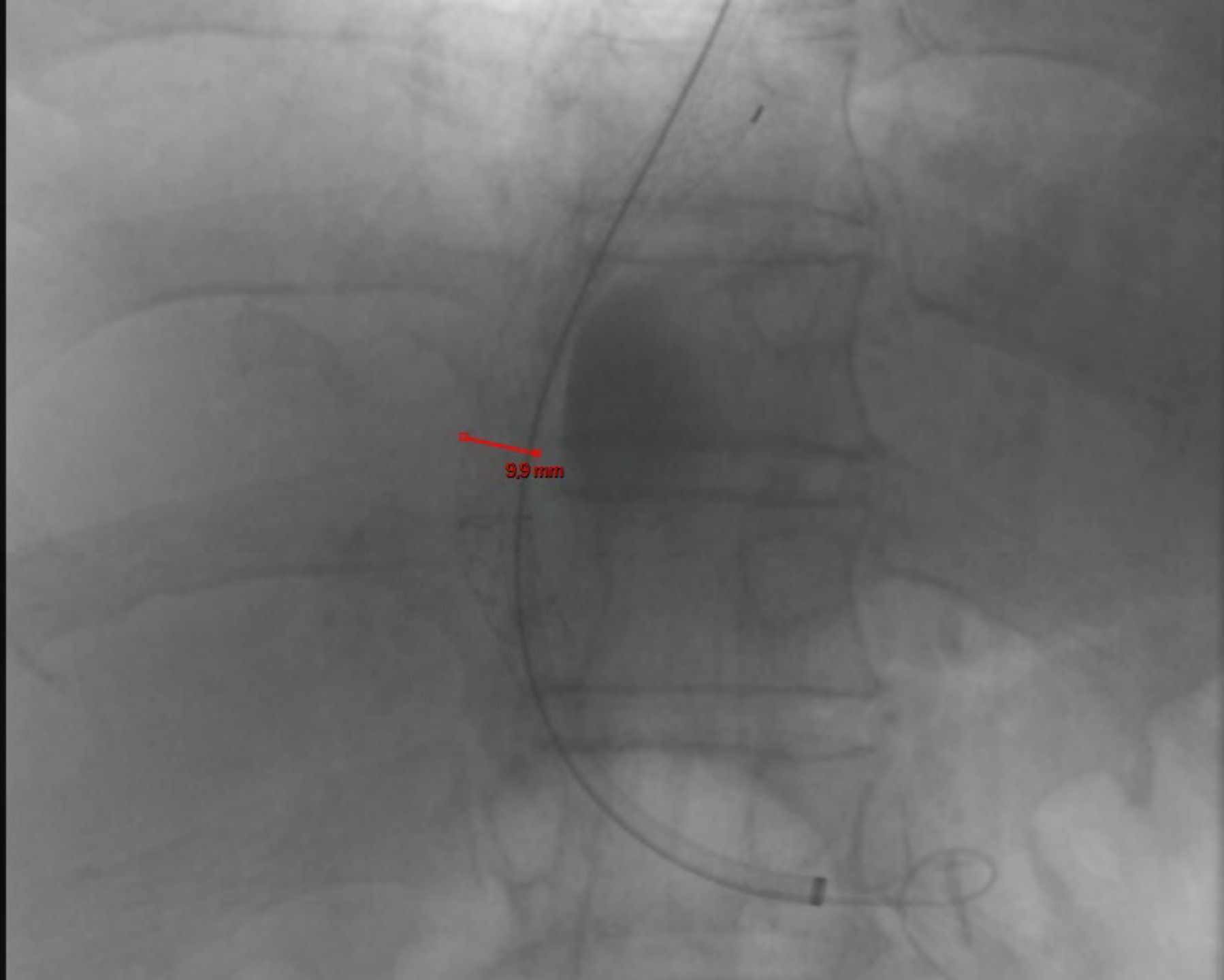


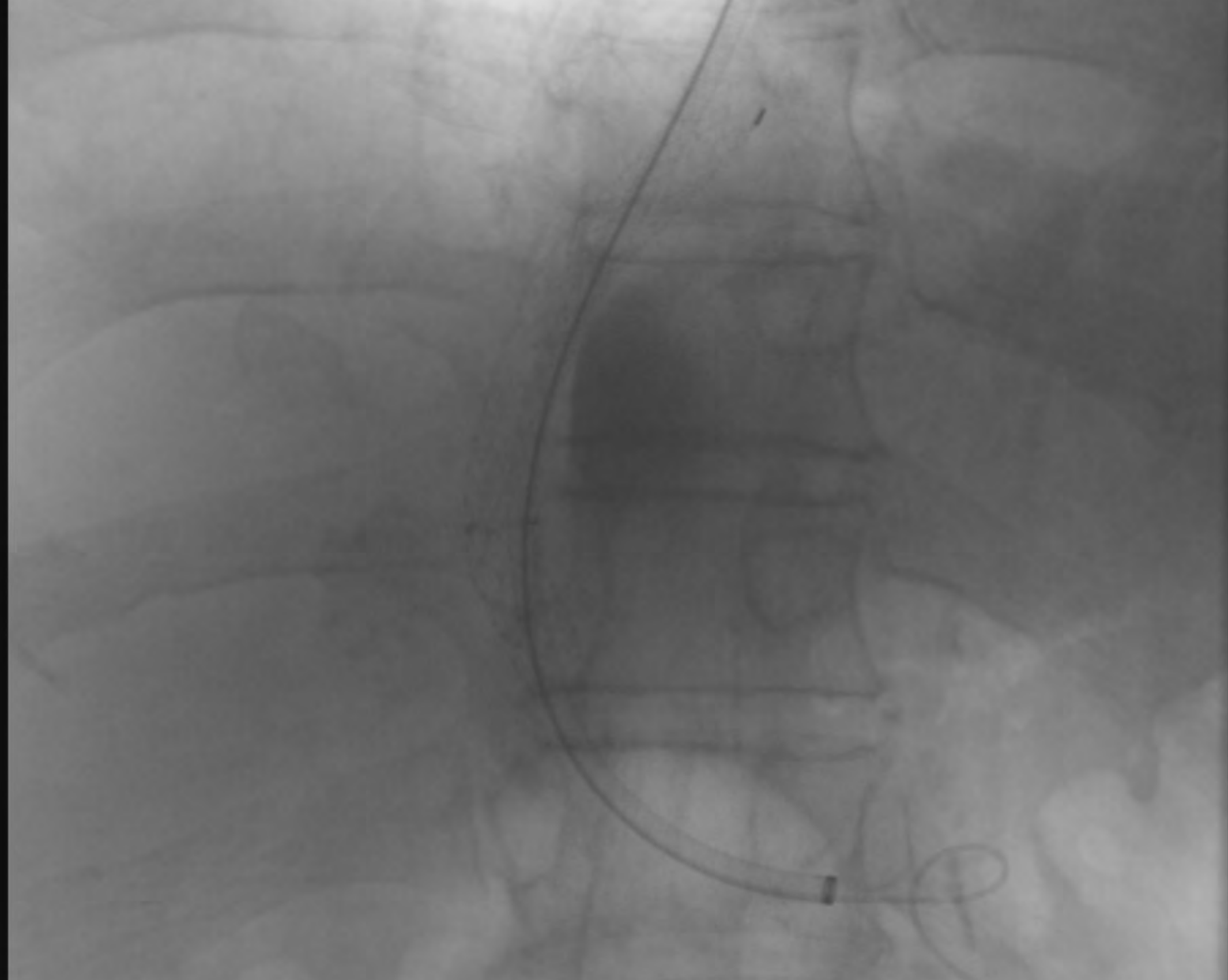


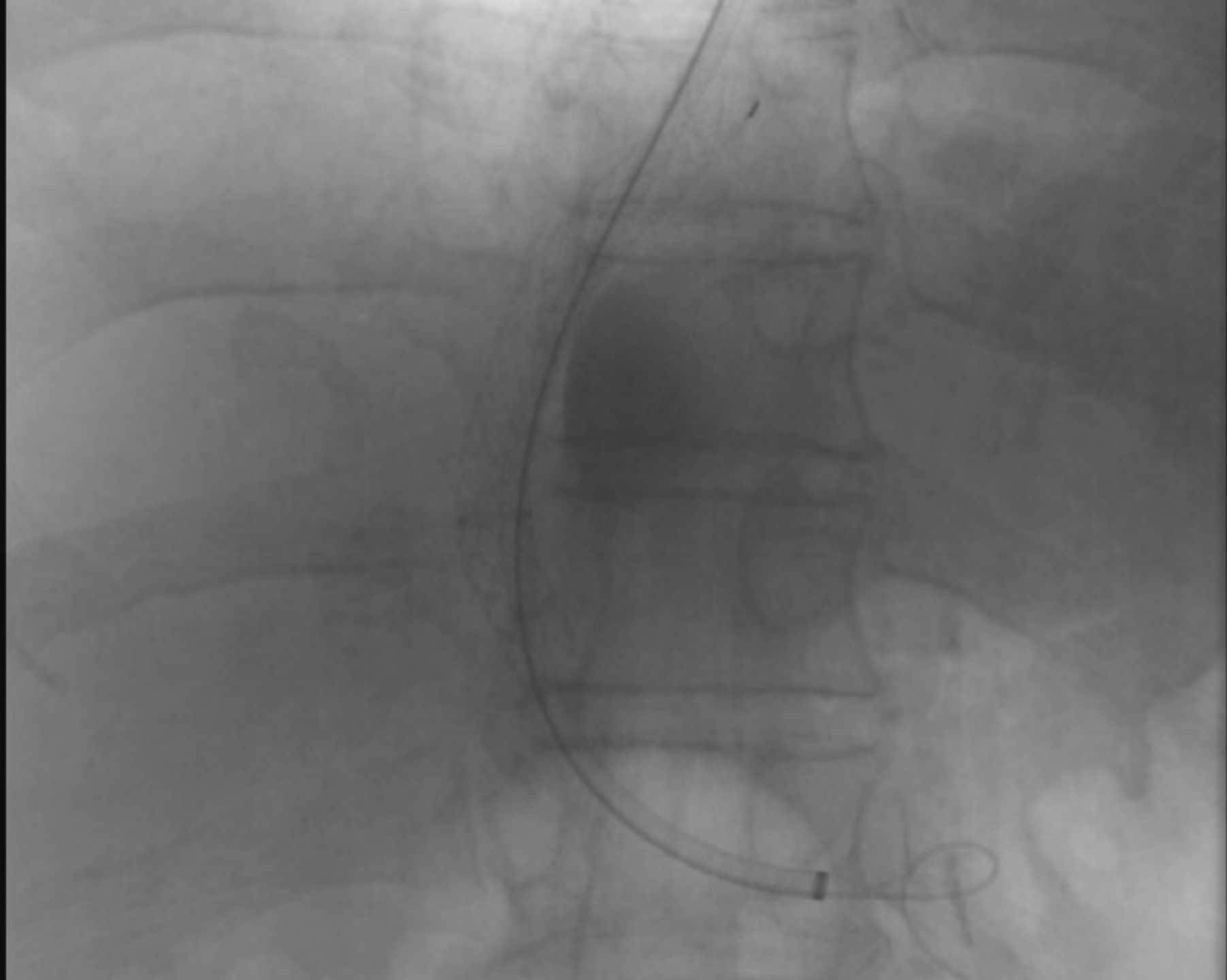


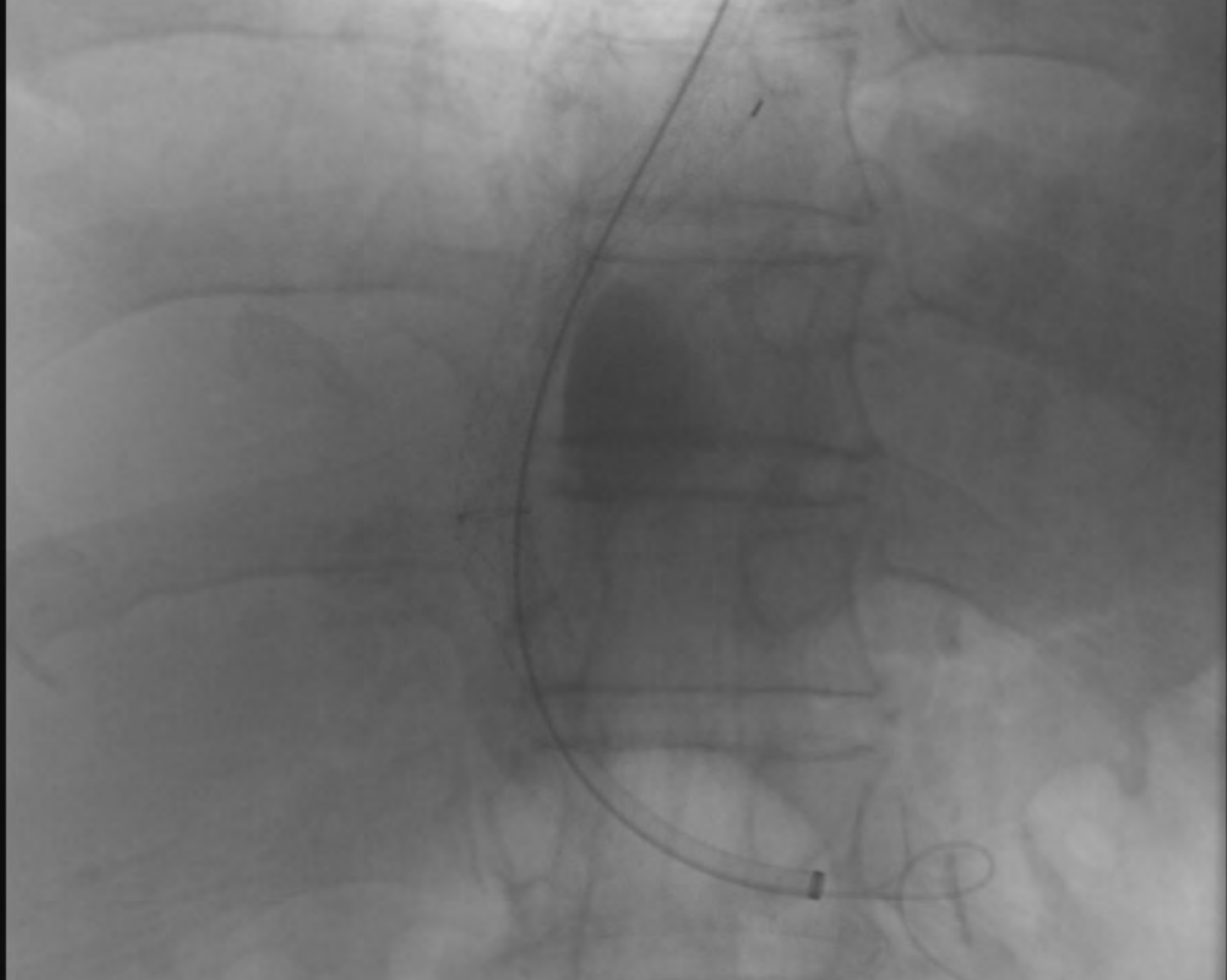


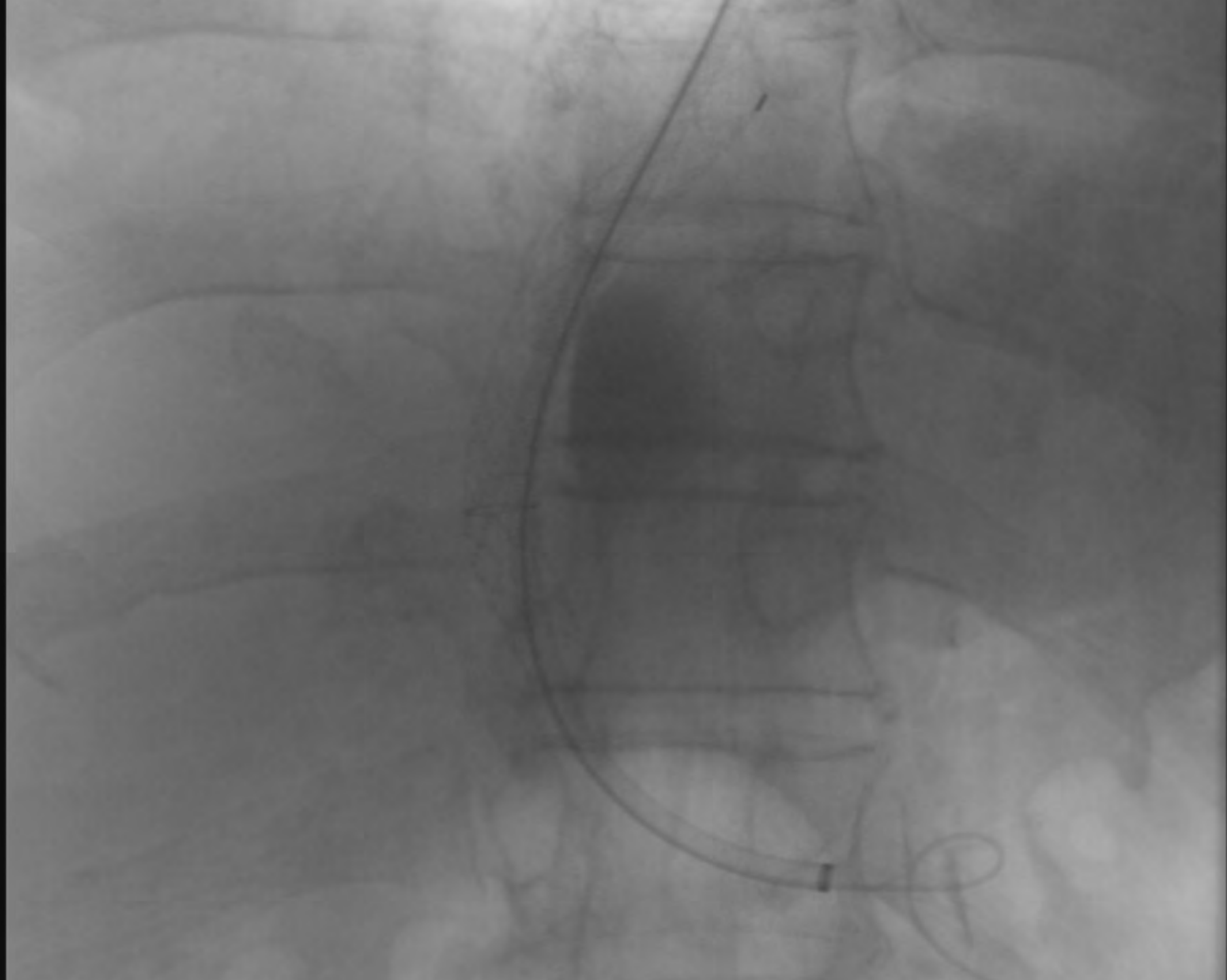


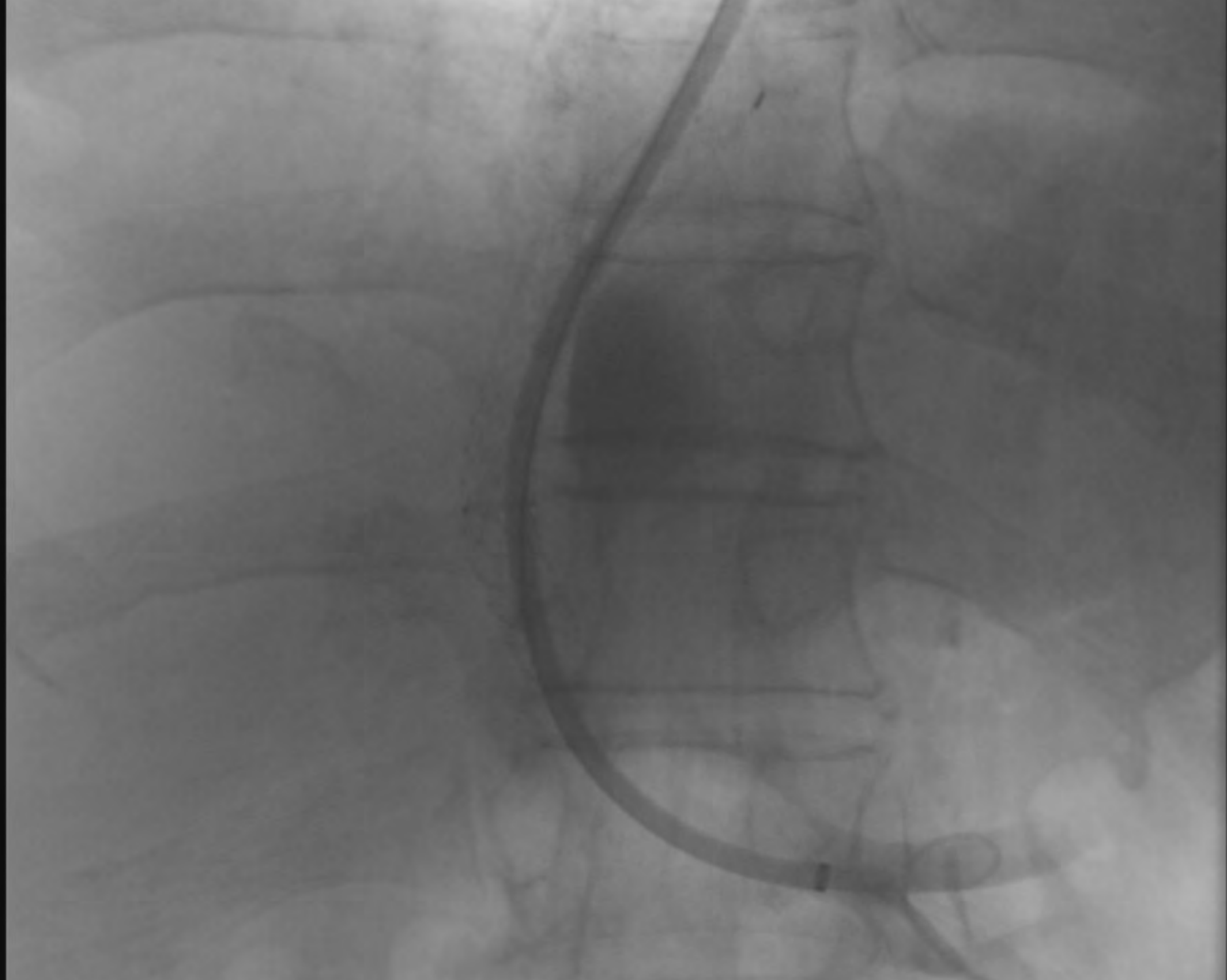






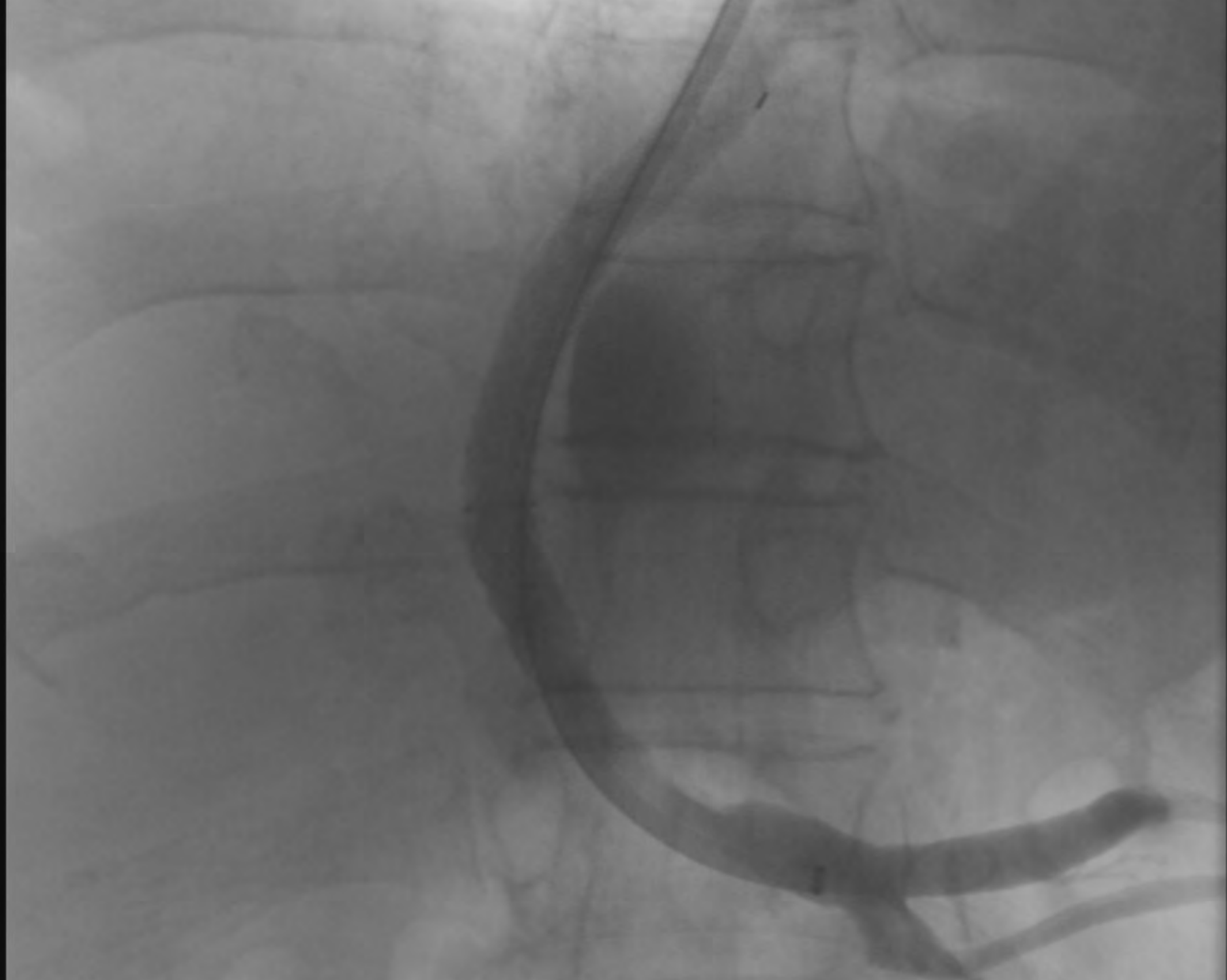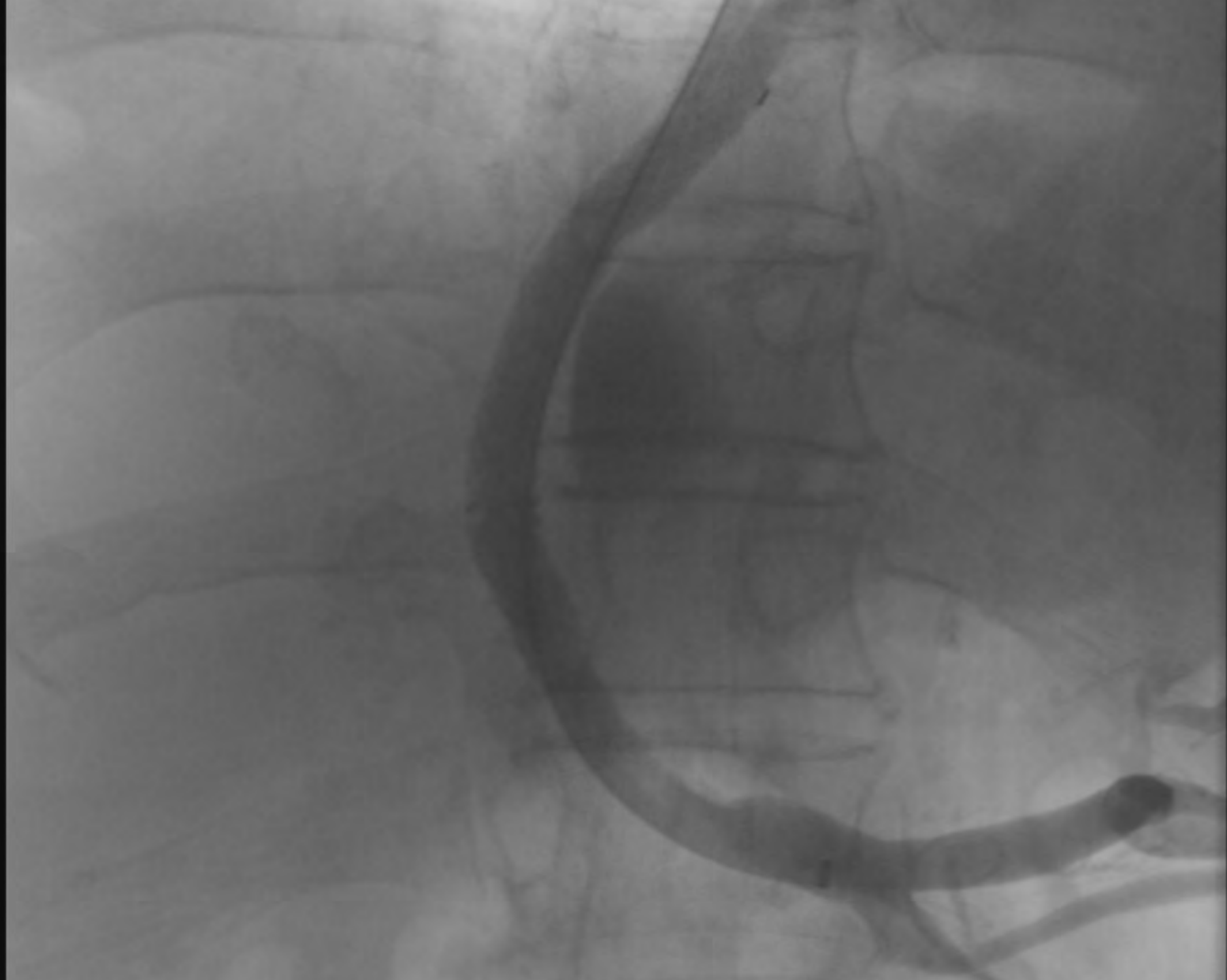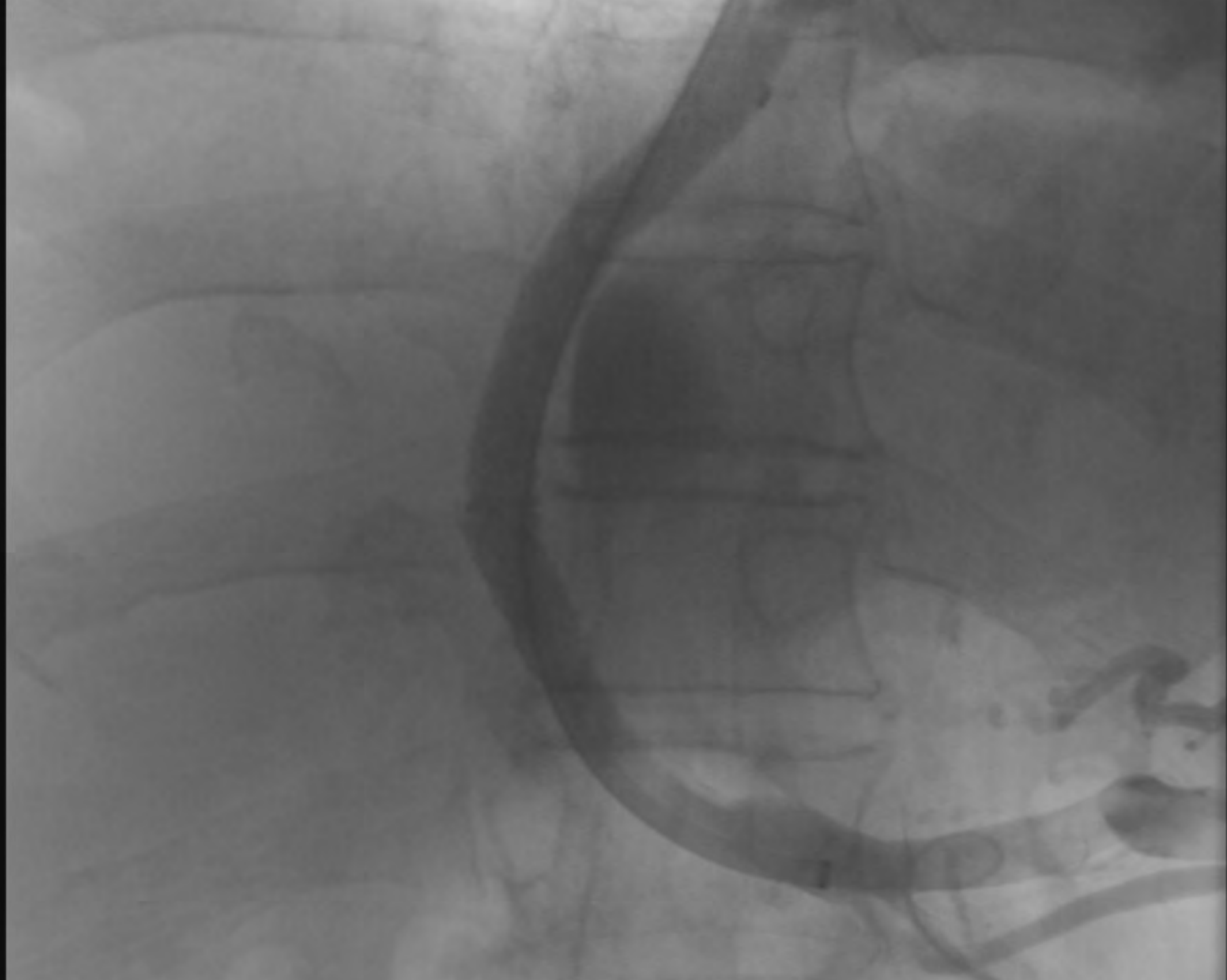






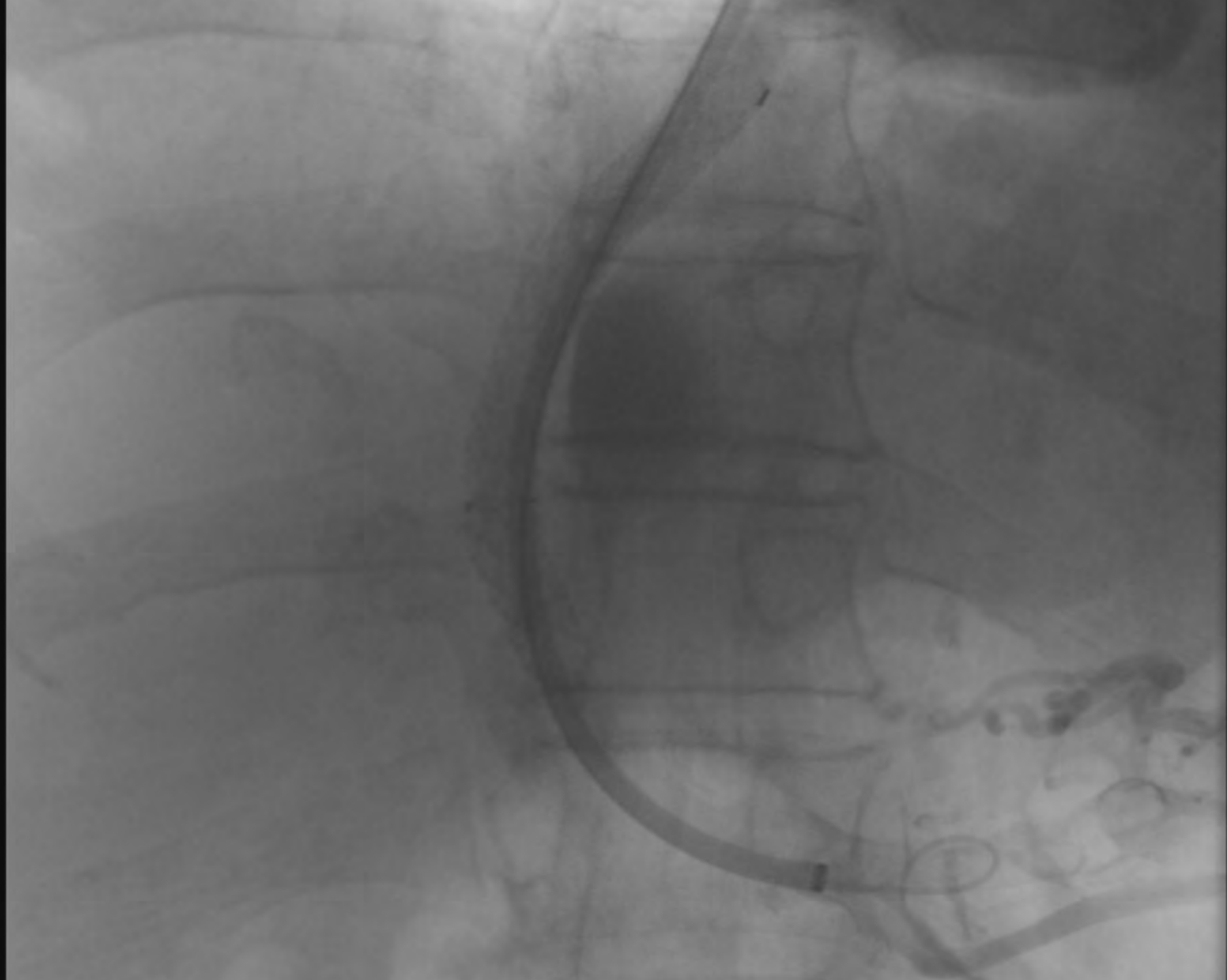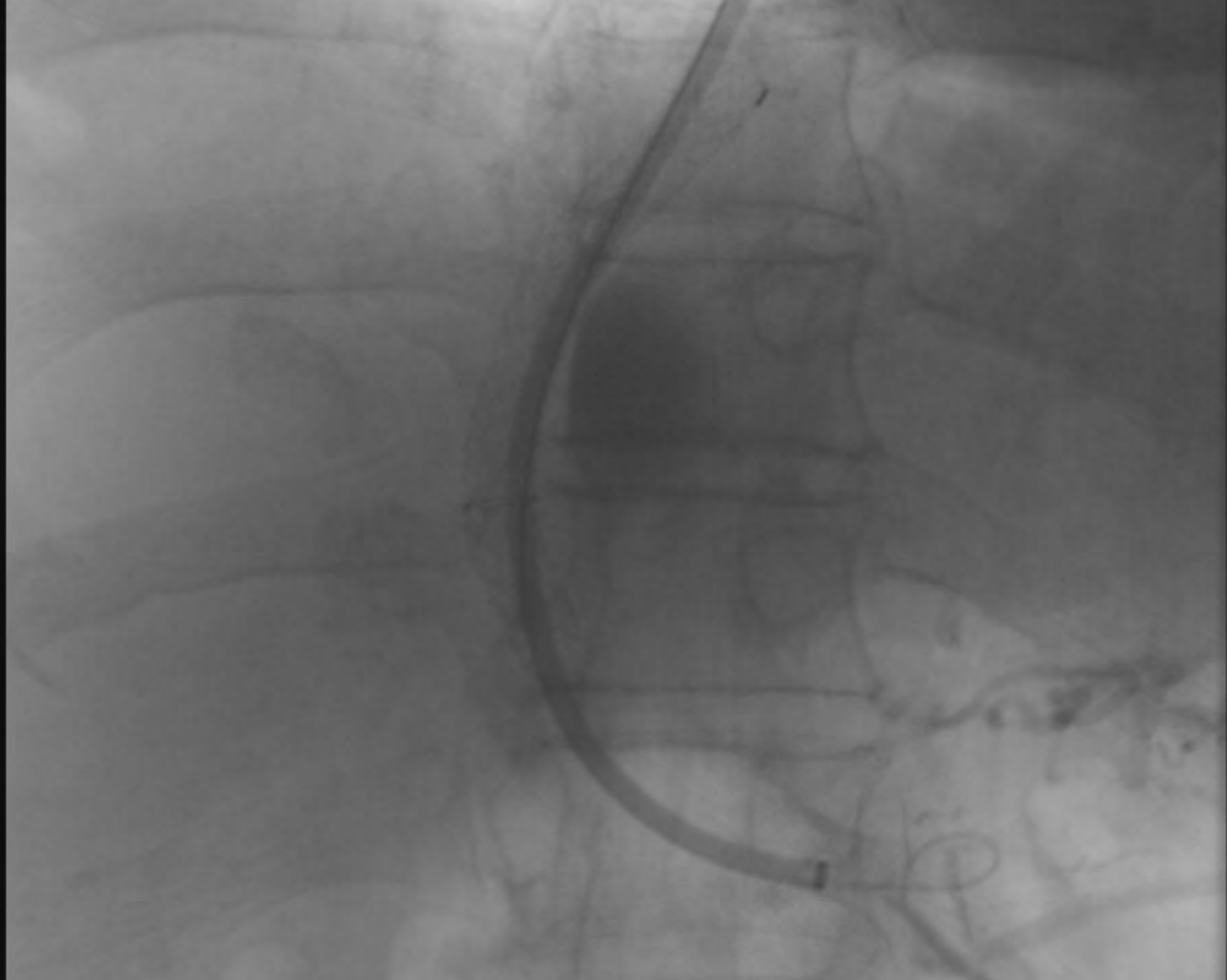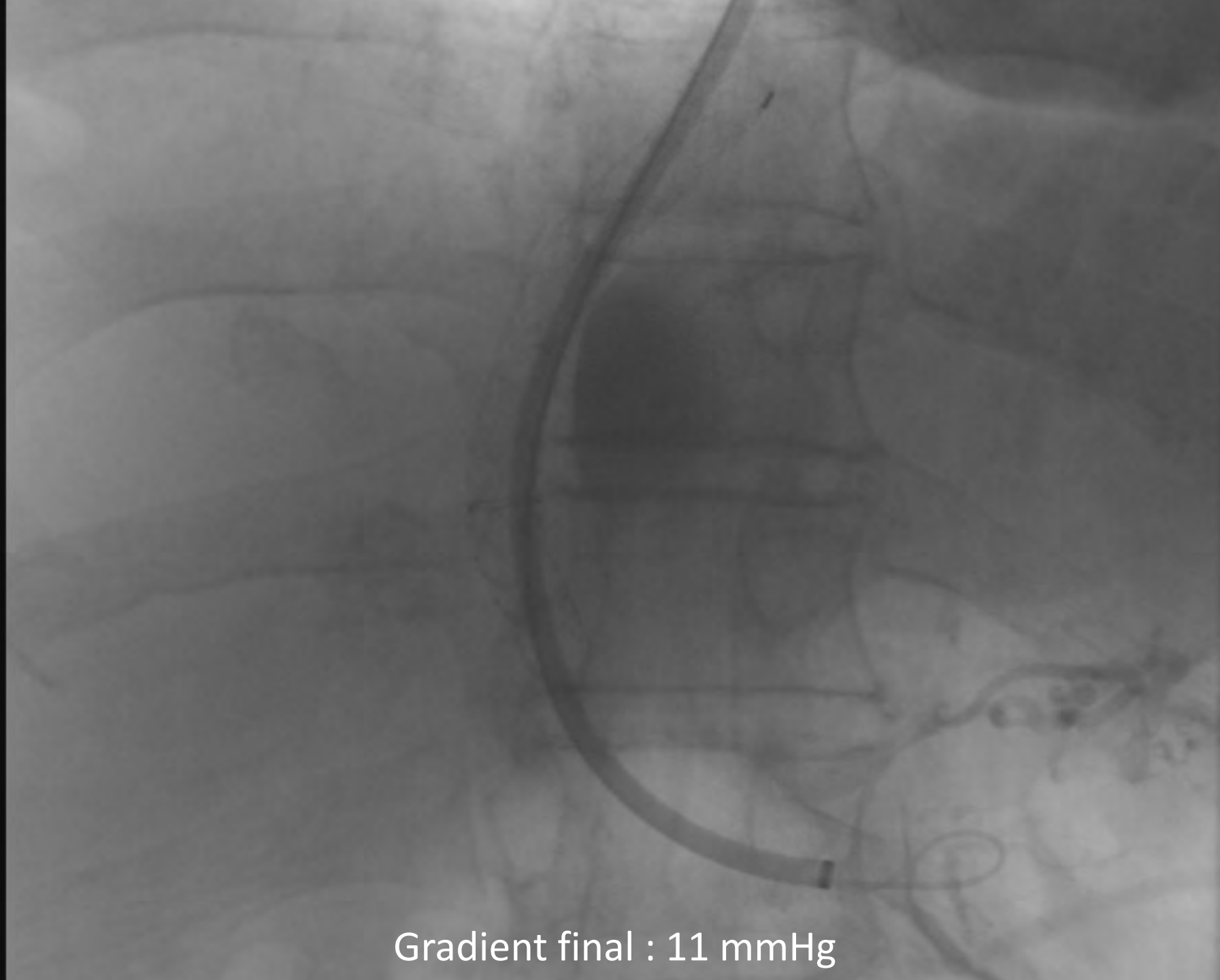




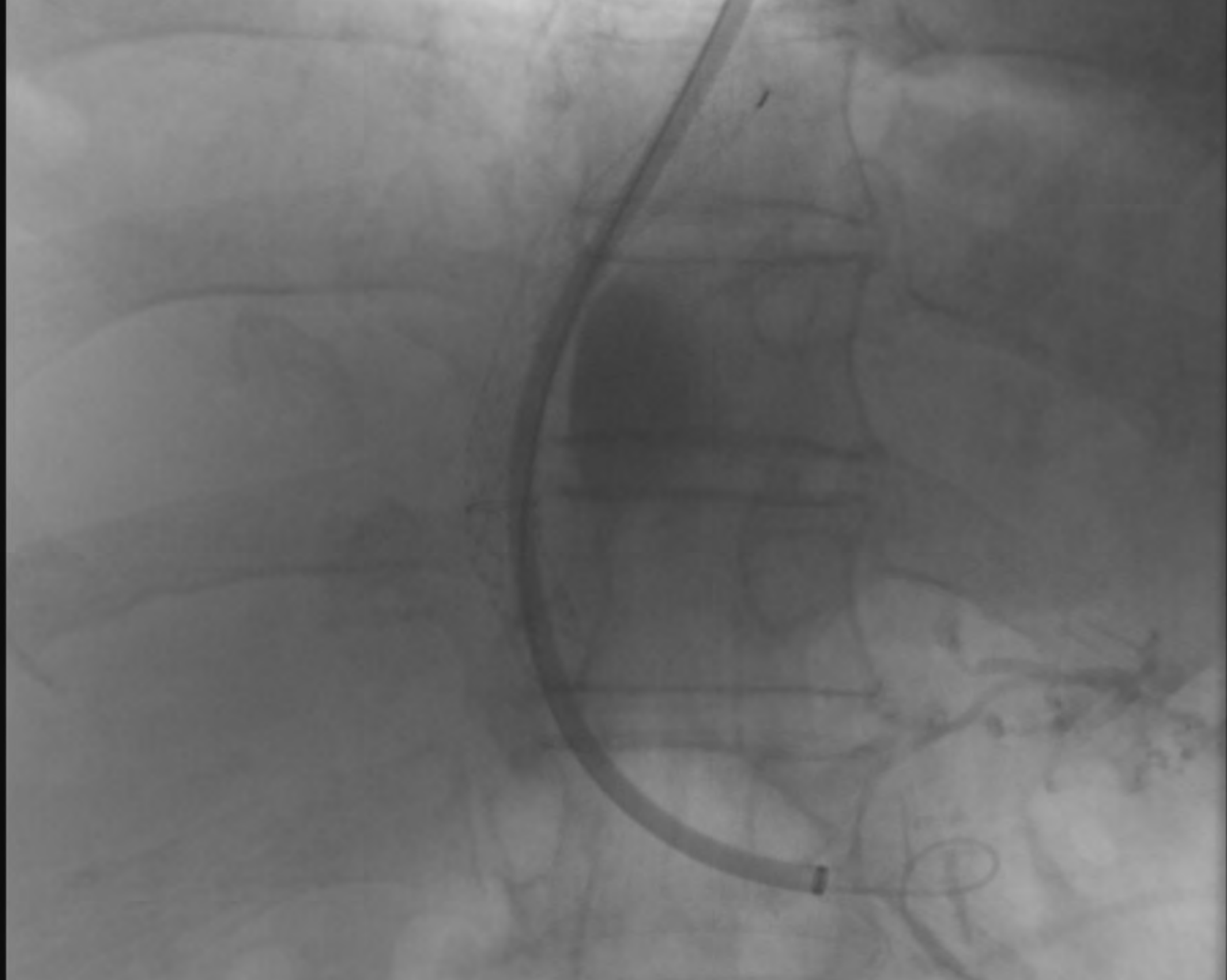








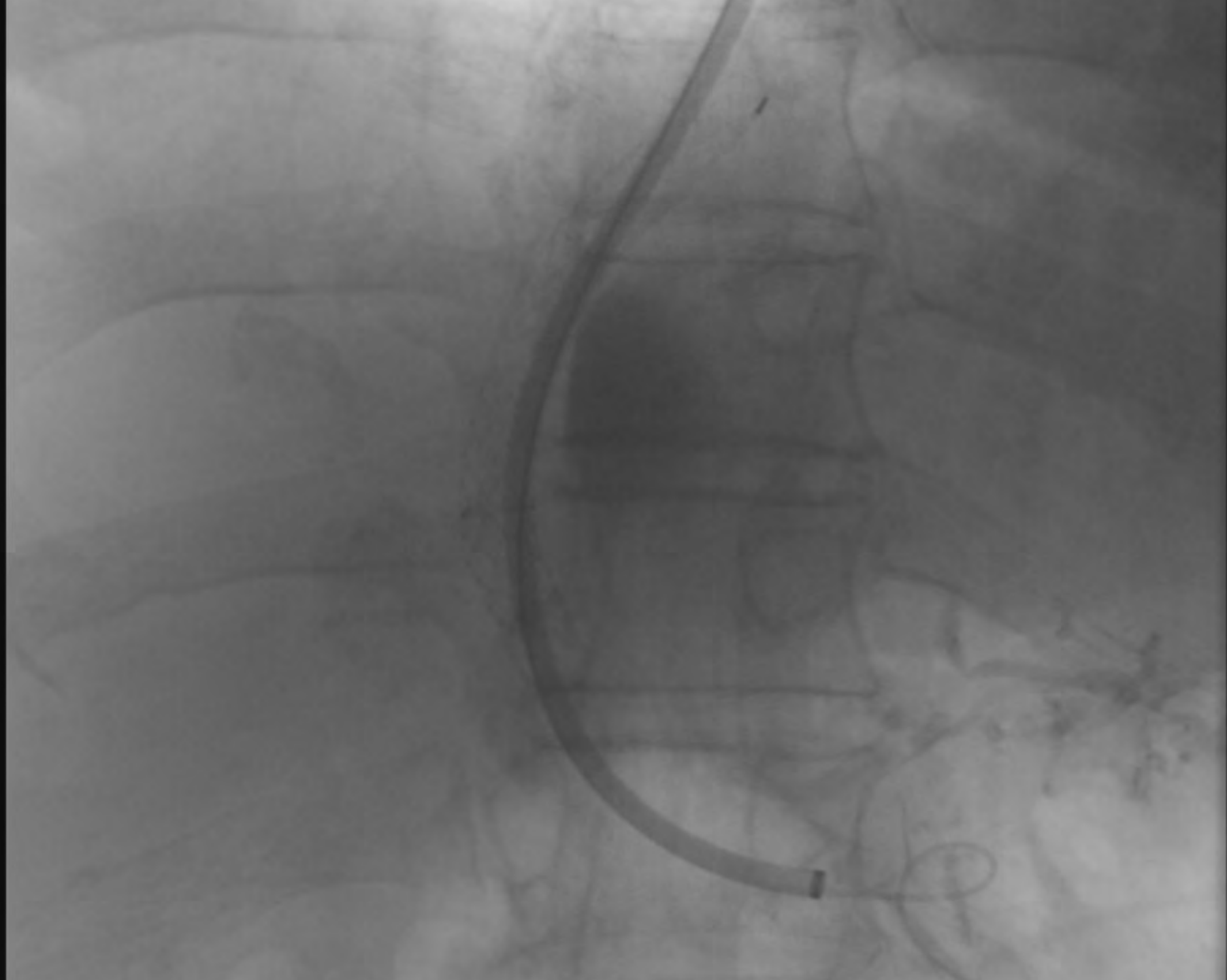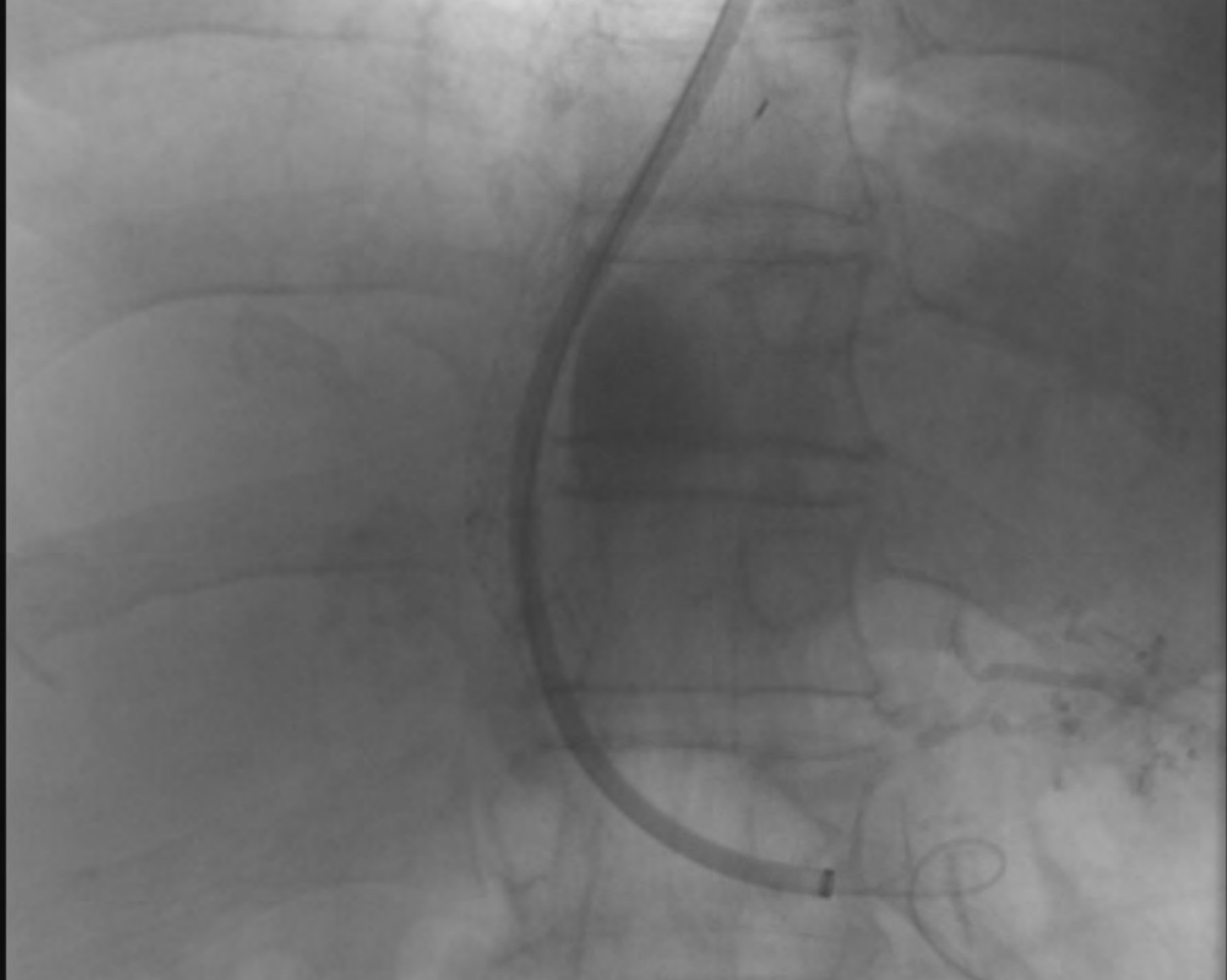Gradient final : 11 mmHg







Evolution

- Pose de TIPS
 - Grad post 11 mmHg
 - Pas d'IHC
 - Sortie à J3
- Contrôle à M3
 - Bonne qualité de vie, a augmenté ses activités quotidiennes, responsabilités politiques
 - Epouse très aidante
 - Pas d'EH clinique, EHM (9 animaux en 60 secondes), fragilité 4,63
 - 2 ponctions/mois
 - Child C10, MELD 16
 - Discussion de dilatation du TIPS après mise sous lactulose pour EHM
 - Mesure gradients
 - Discussion stent non couvert VP en fonction
 - Puis éventt ac acetyl salicylique ou anticoagulants

Réunion de concertation multidisciplinaire TIPS/TH

160 patients discutés TIPS ou TH



Décision multidisciplinaire



**TIPS seul
n= 30**

**TIPS et TH si besoin
n=37**

**Pas de TIPS TH seule
n=29**

**Patients récusés
TIPS et TH n=64**

**TIPS seul posé
n=58**

**TIPS et TH
n=9**

**TH seule
n=12**

**Ni TIPS ni TH
n=81**

**Survie à 1 an
67 %**

**Survie à 1 an
87 %**

**Survie à 1 an
100 %**

**Survie à 1 an
64 %**

FIPS score 0.53 (faible risque selon la publication)

Cas n°3

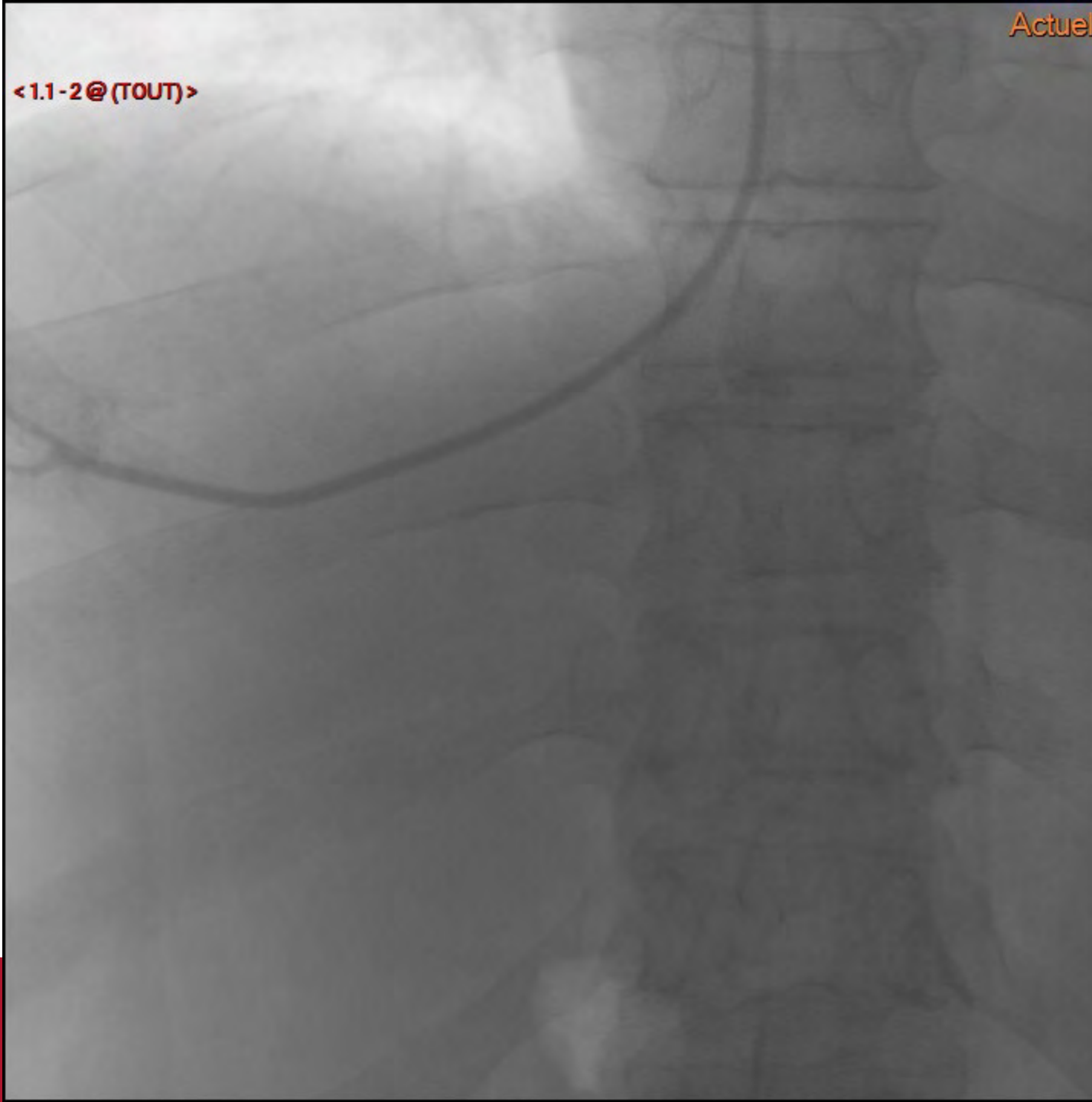
- ATCD: Vit en concubinage, un fils de 5 ans, ouvrier dans une scierie, très actif, ne fume pas, sœur médecin généraliste. 99 Kg, 1m85
- Cirrhose liée à une consommation excessive d'OH +sd métabolique découverte en 2021 (HAA)
- Sevrage complet depuis sauf une bouteille de whisky une fois (partie de pêche)
- HDM:
 - Hématémèse massive le 30/4/22 (Reims), choc, acidose, Hb 5 g/dl, 8CG
 - Endoscopie: rupture VCT, échec aetoxysclérol, transfert PSL Réa HM le 1/5/22 (intubé, sous NA 10 mg/h)
 - Bio: Hb 5,6 g/dl, K⁺ 7,3, lactates 18, Ph 6,96, HCO₃⁻ 7, LDH 5612, Plaq 55000/mm³, Bili 19, AST 5338, ALT 1889, GGT 72 micromol/L, Albumine 28 g/L, créat 139 micromol/L, TP 20%, INR 3,41, tropo 499
 - Child C14, MELD 38

e-RCP

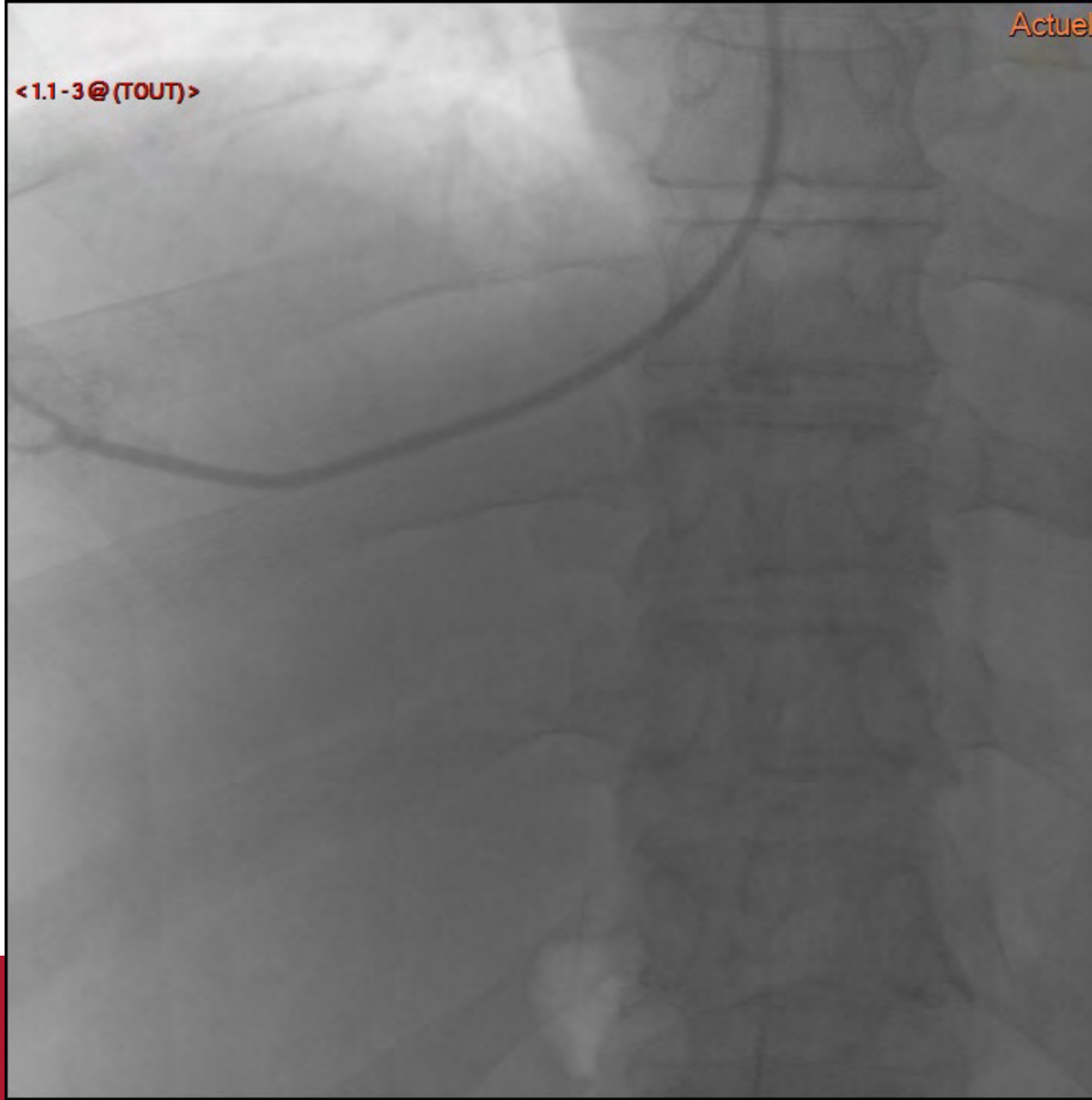
- TIPS de sauvetage
- TH ?

<1.1-1@TOUT>

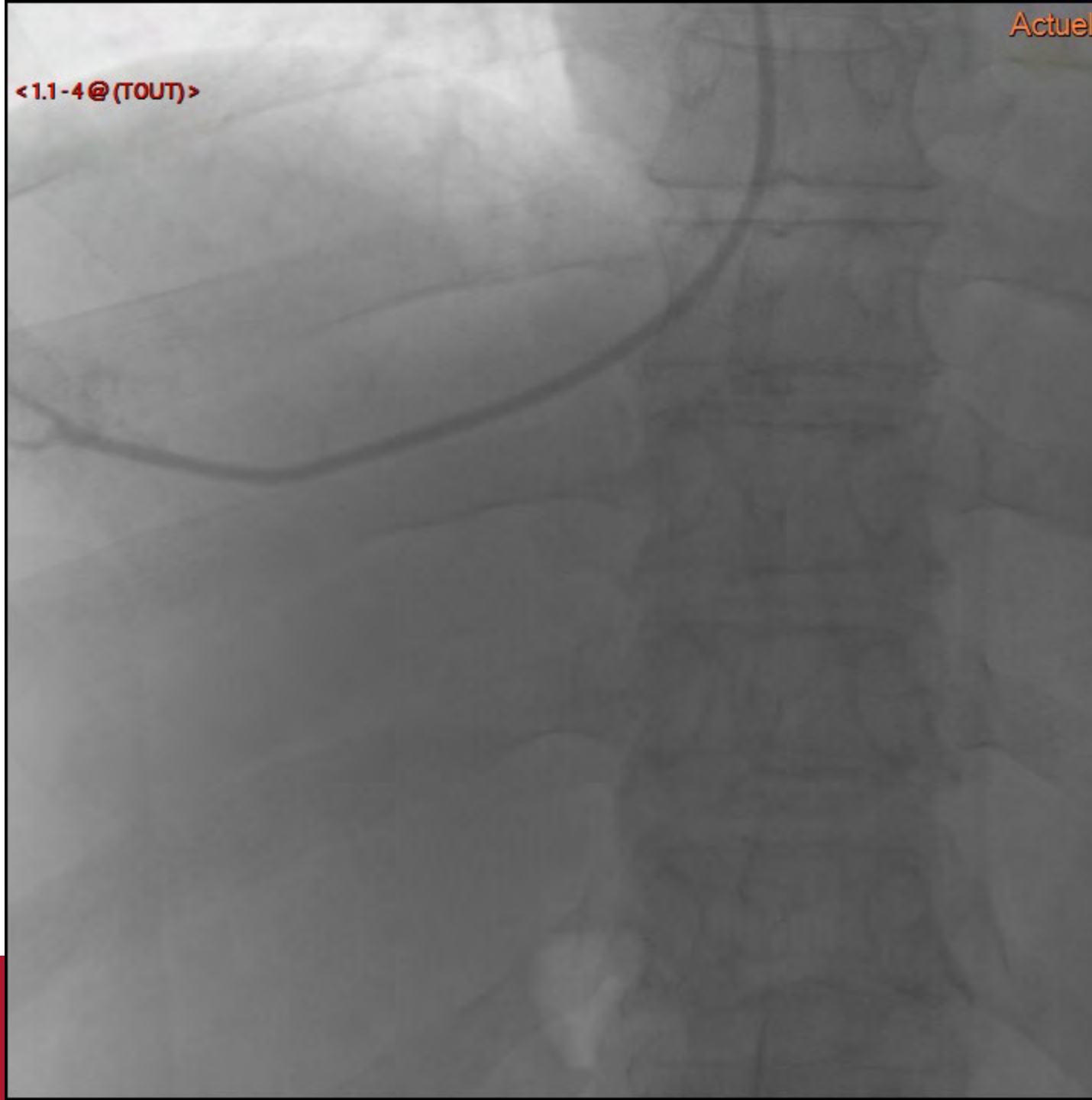
<1.1-2@(TOUT)>



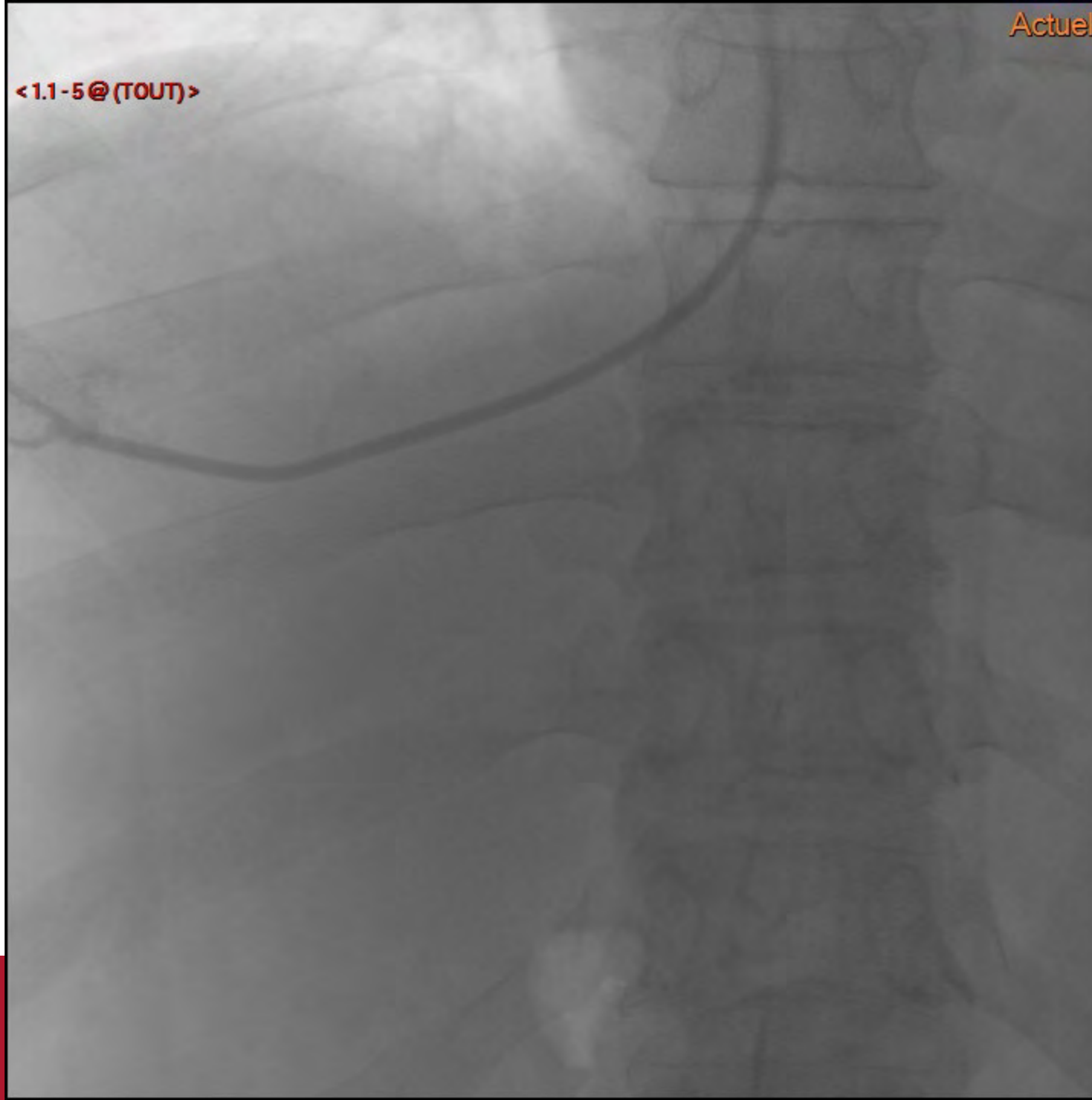
<1.1-3@ (TOU) >



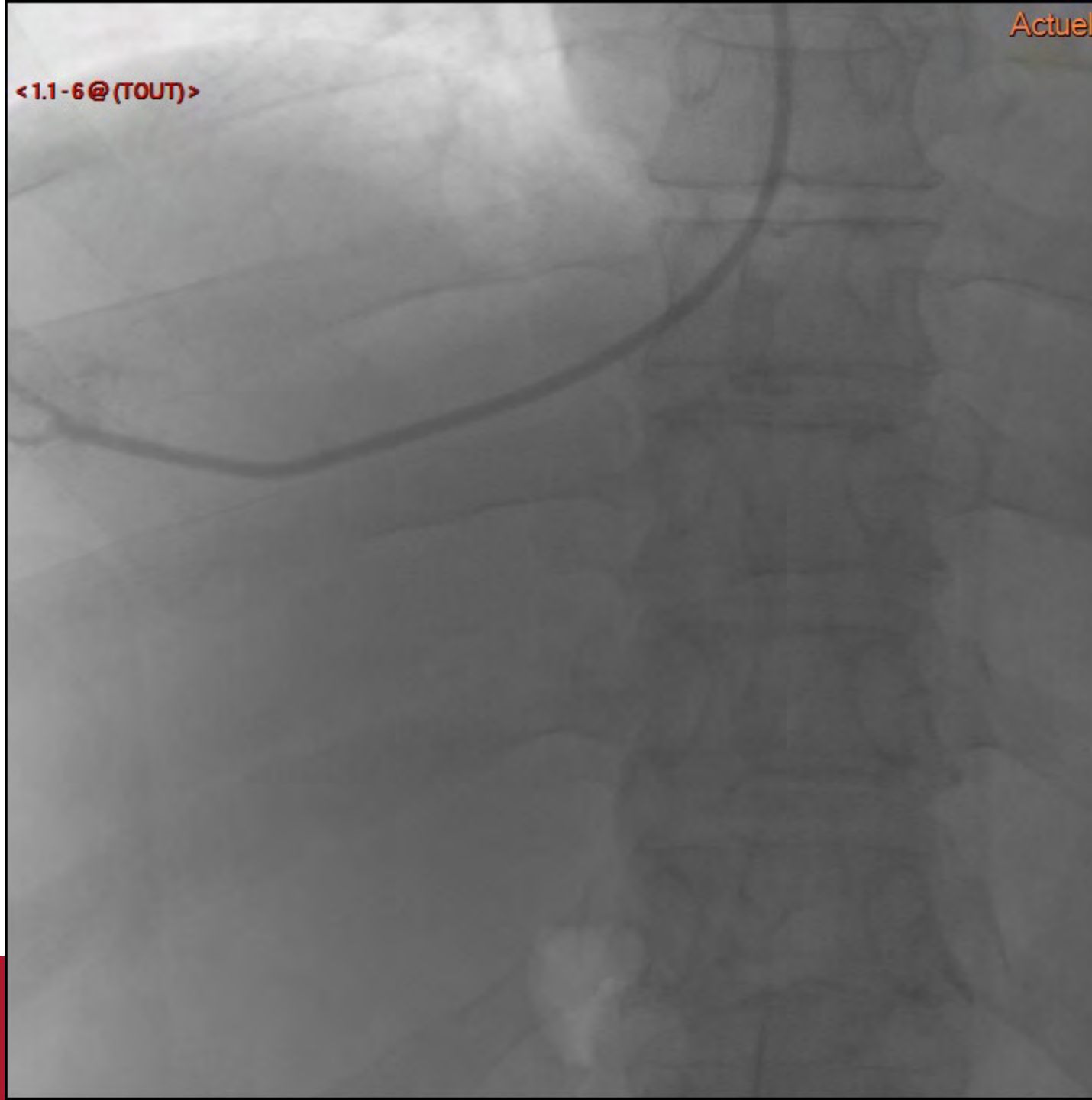
<1.1-4@(TOUT)>



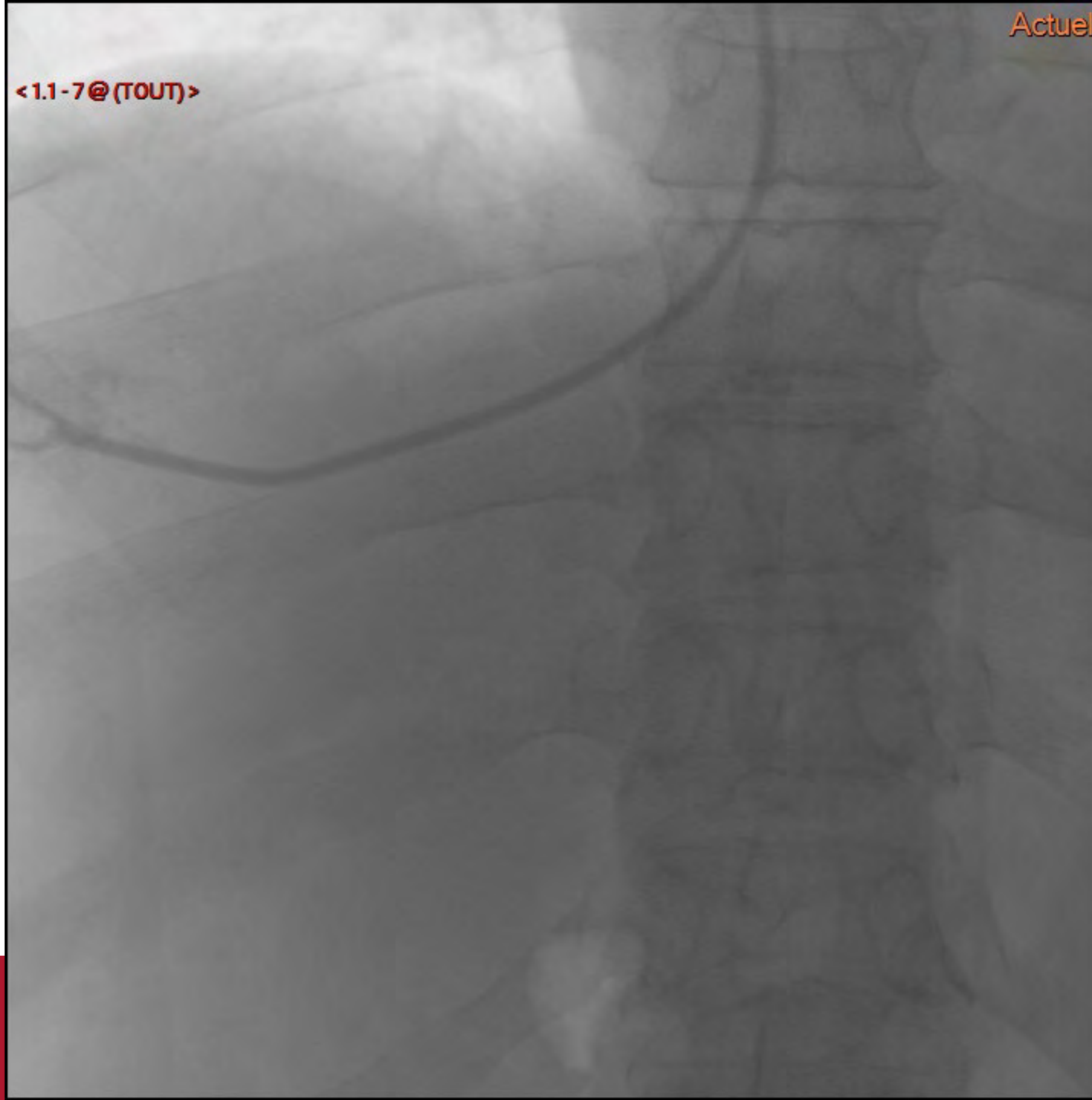
<1.1-5@ (TOUT)>



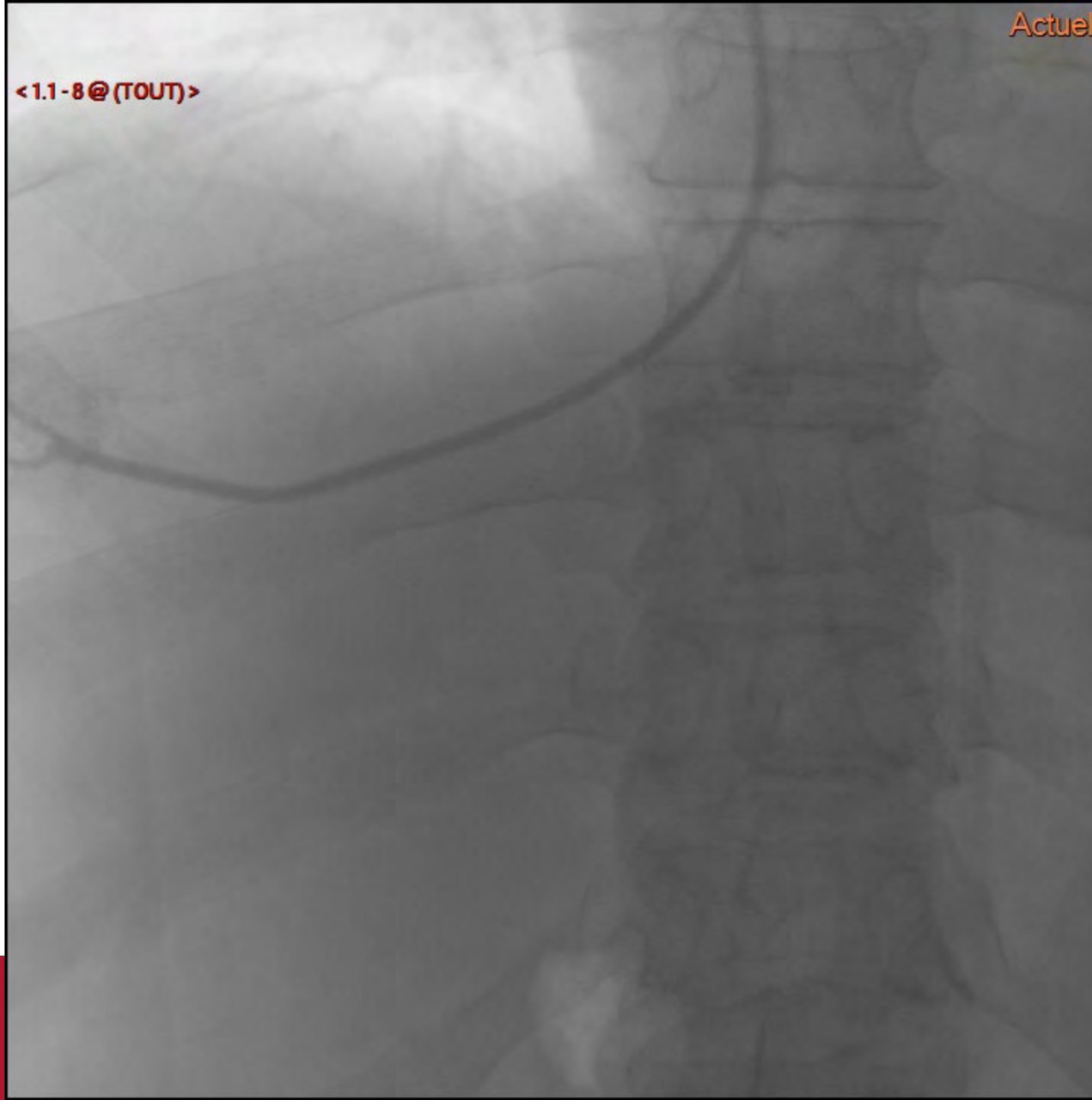
<1.1-6@ (TOU) >



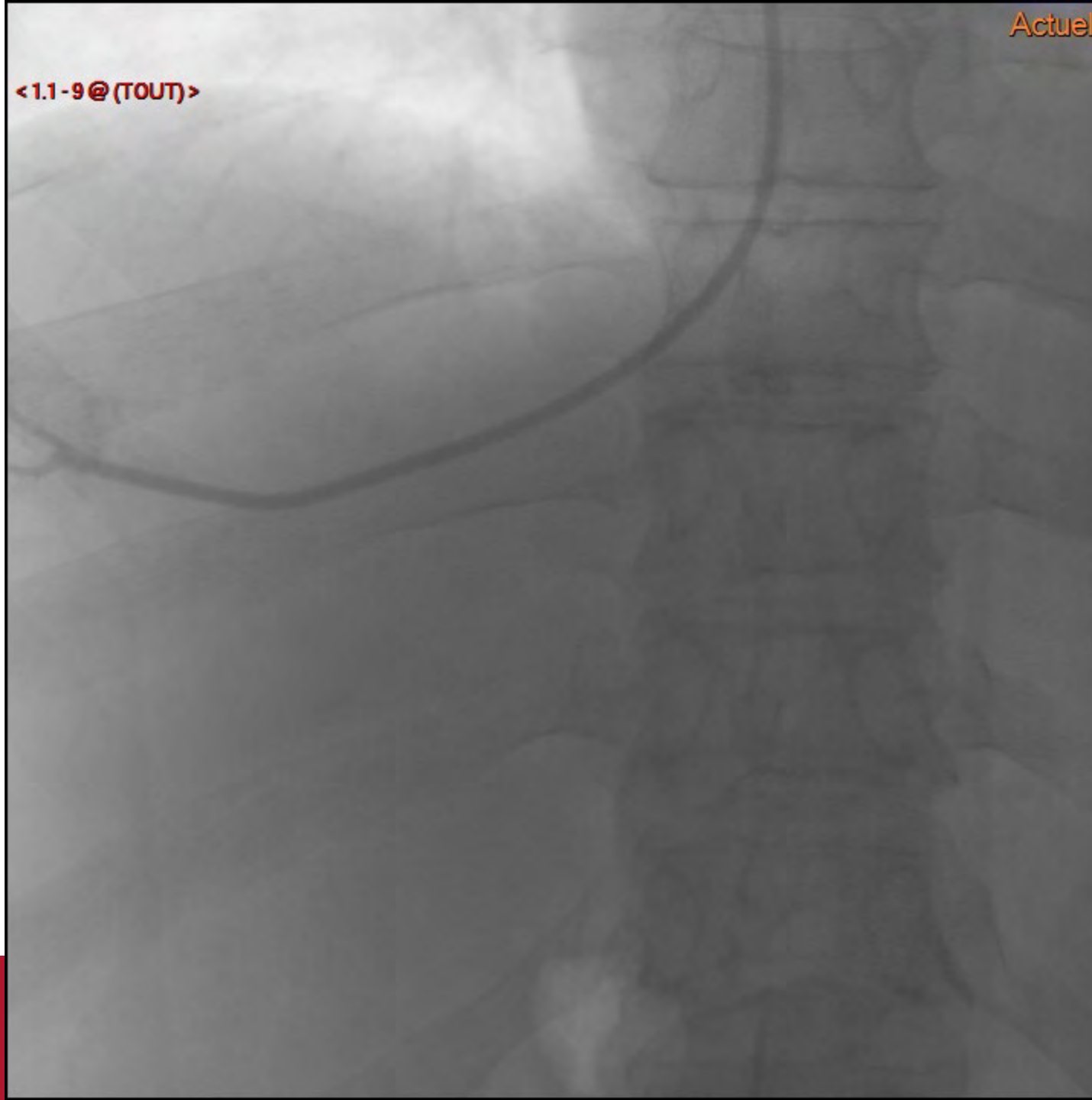
<1.1-7@ (TOUT)>



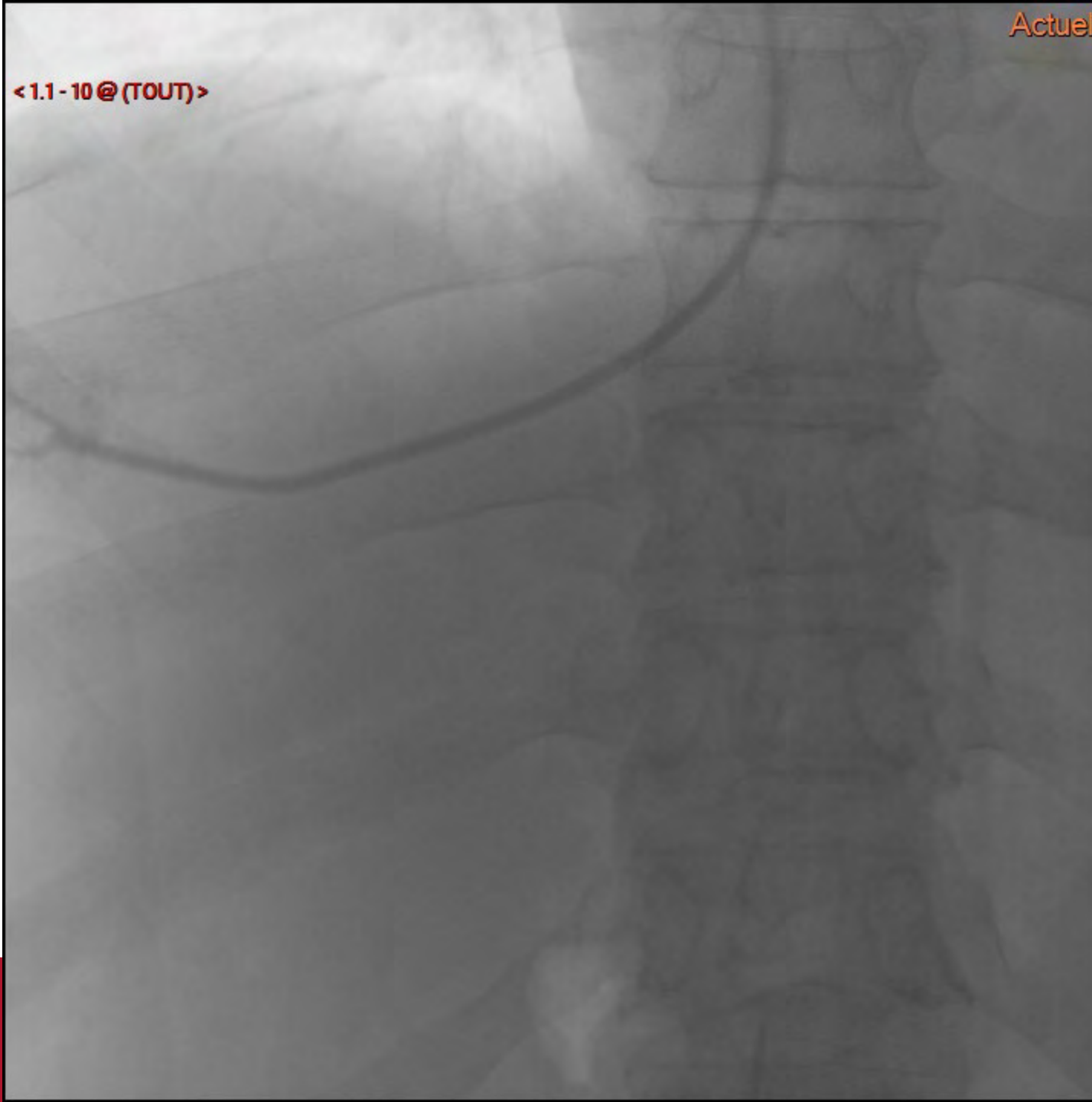
<1.1-8@(TOUT)>



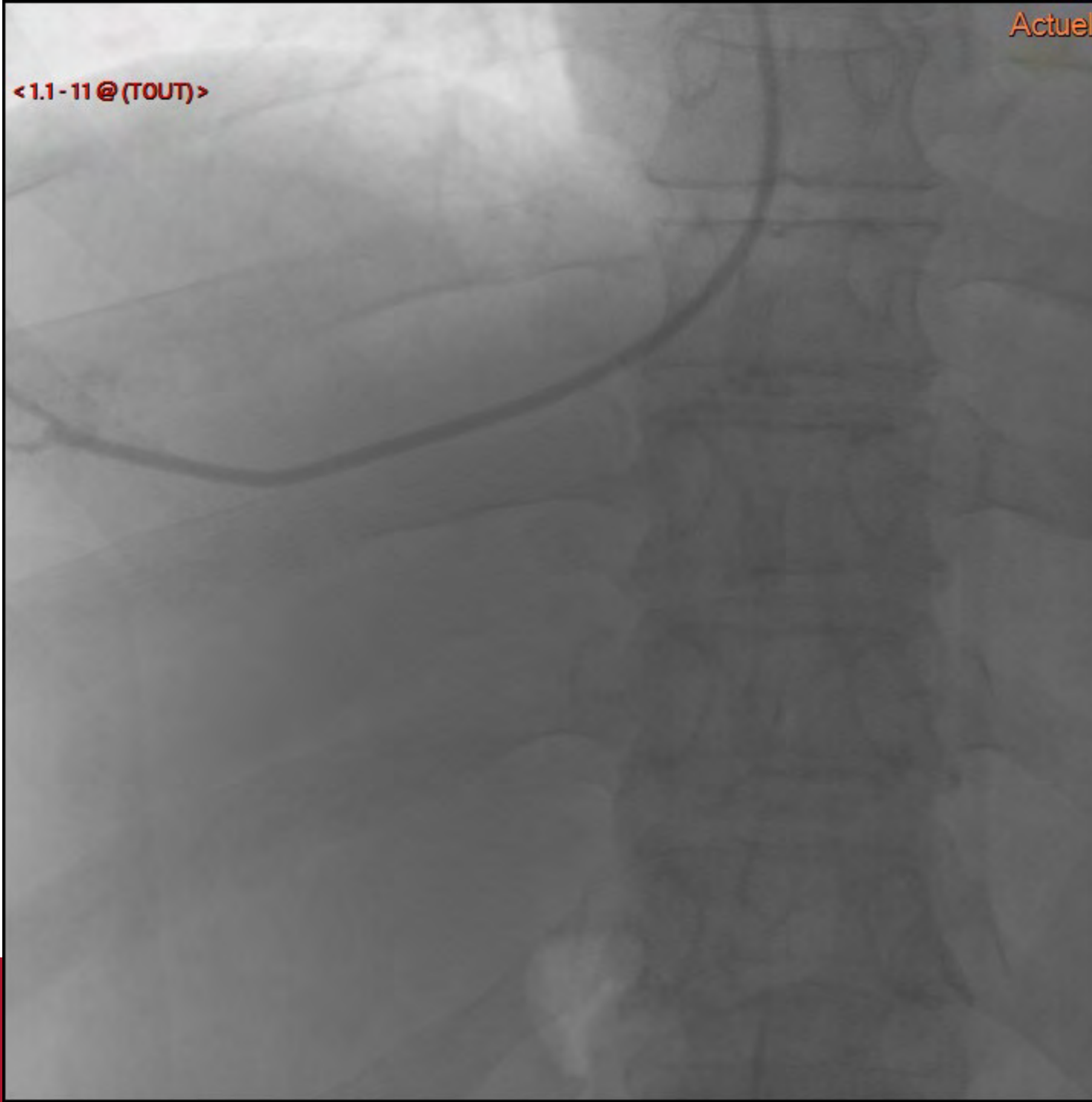
<1.1-9@ (TOU7)>



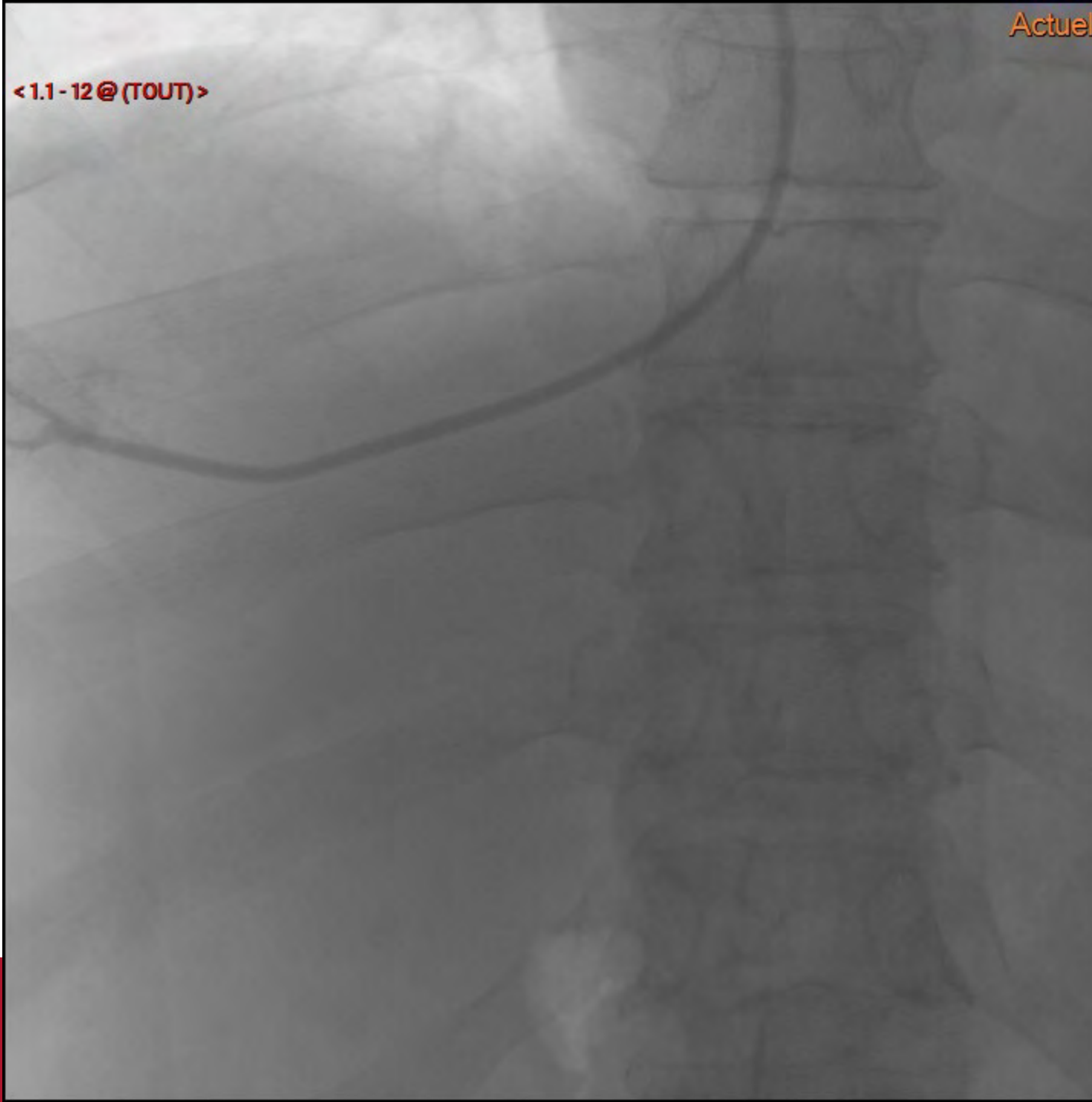
<1.1-10@ (TOUT)>



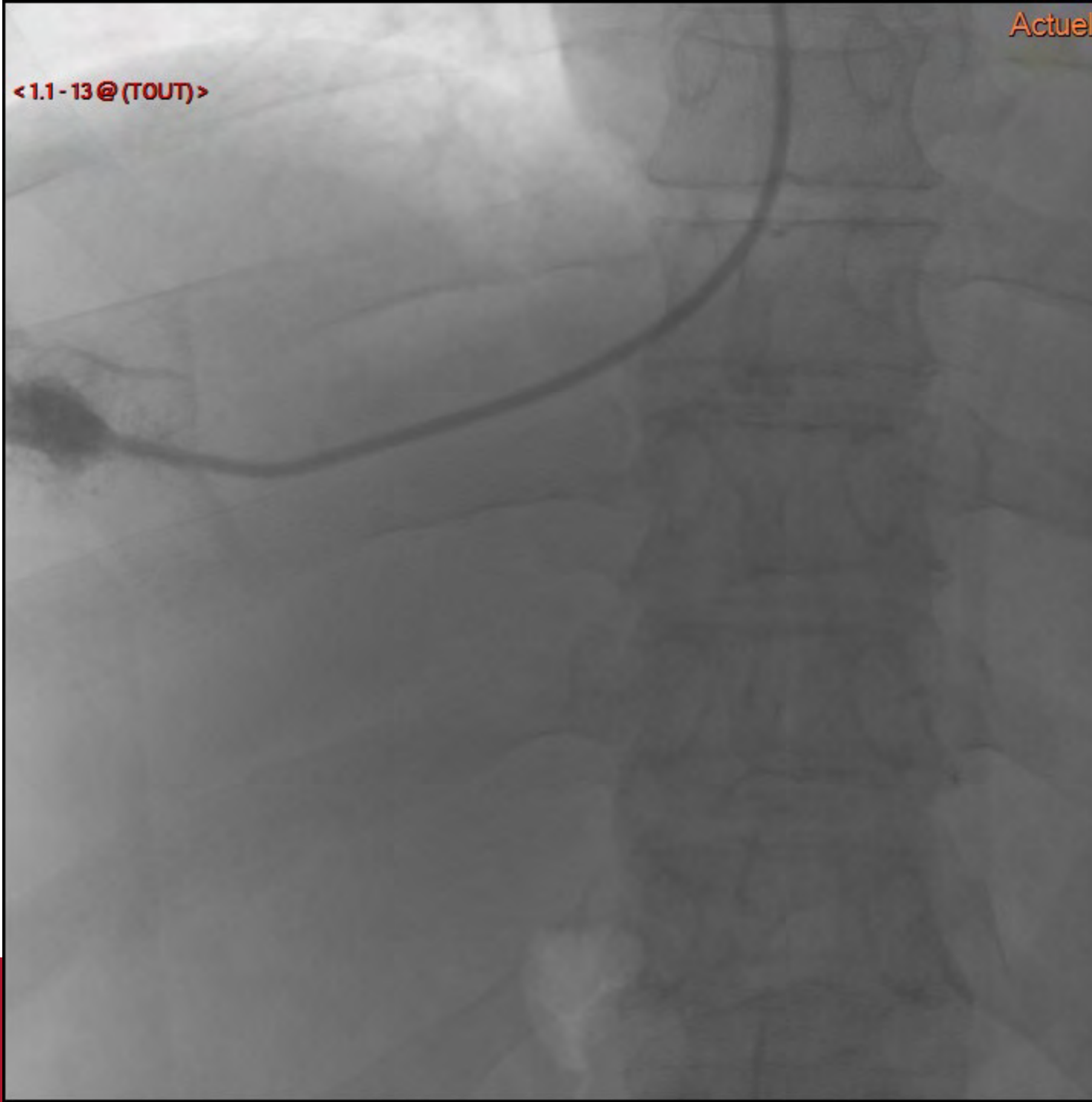
<1.1-11@ (TOU7)>



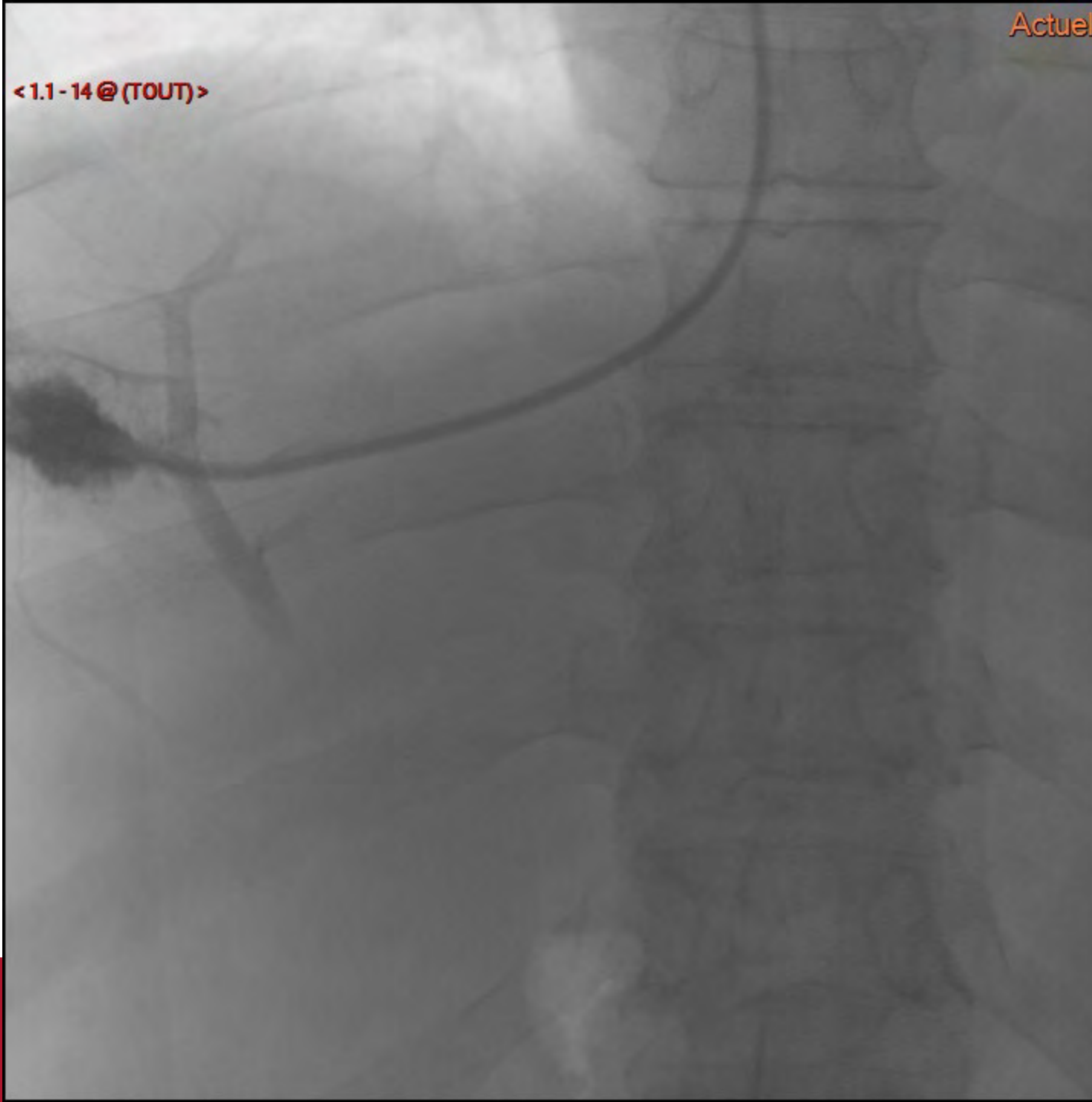
<1.1-12@ (TOUT)>



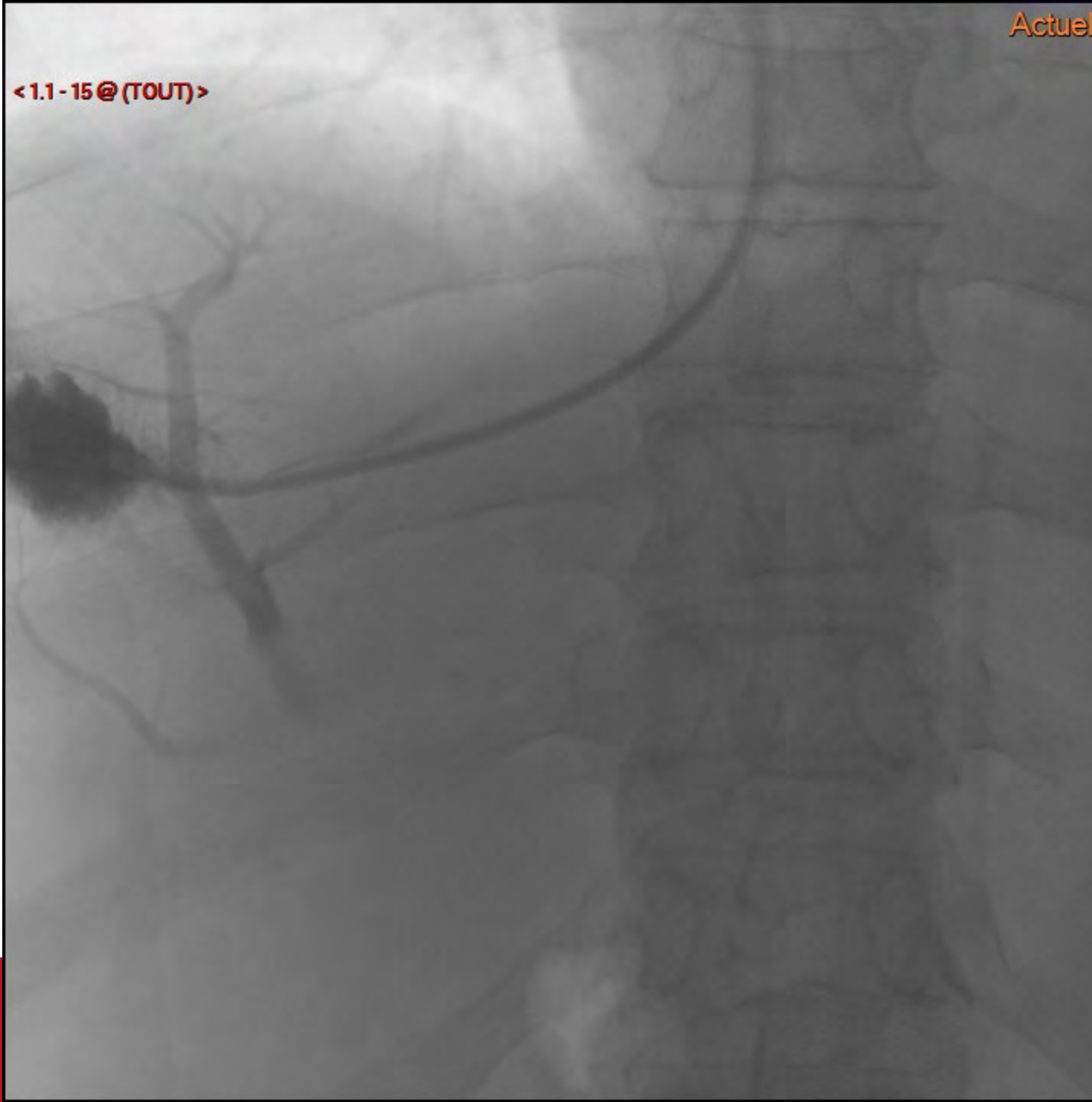
<1.1-13@TOUT>



<1.1-14@ (TOUT)>



<1.1-15@ (TOUT)>



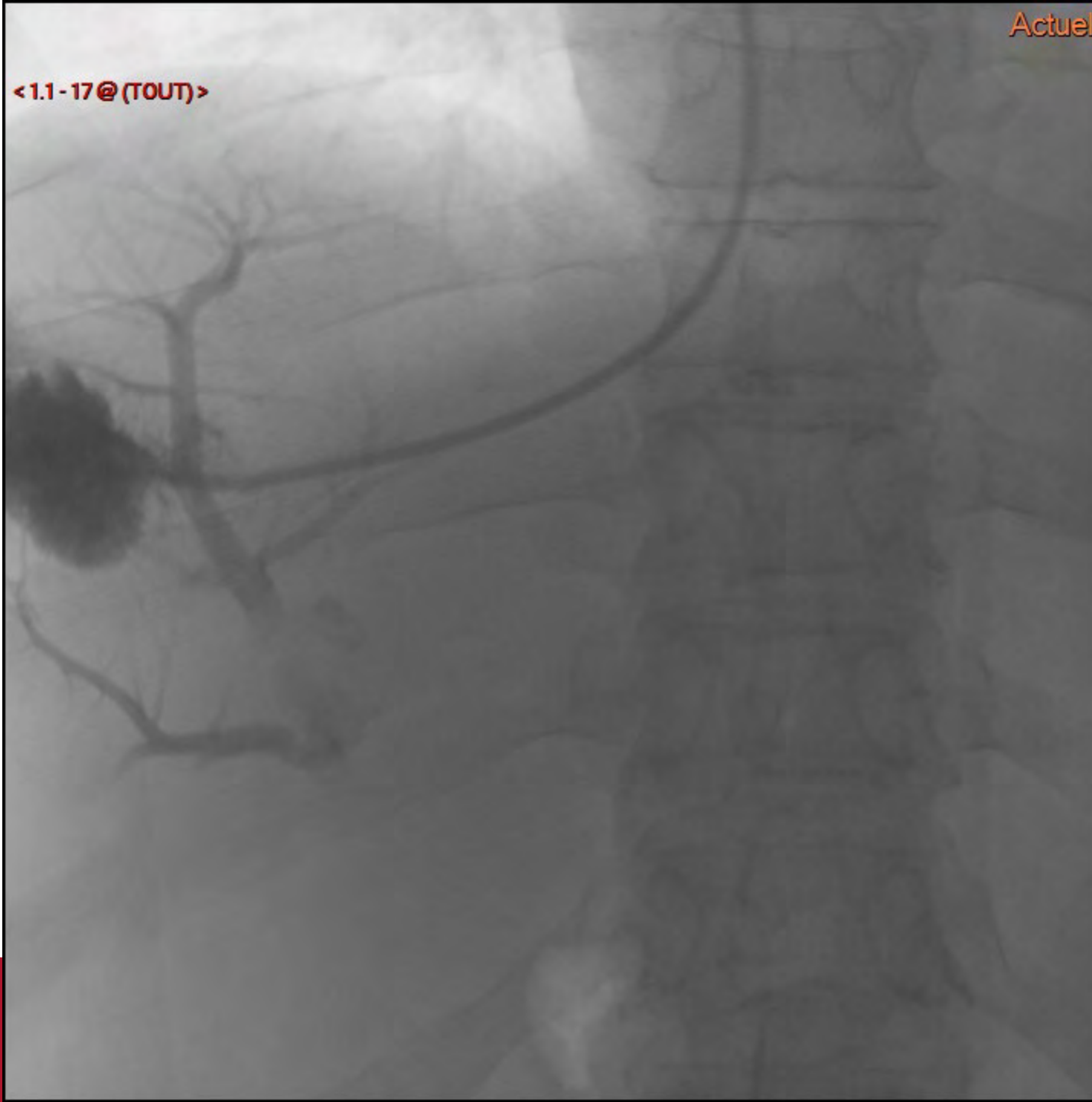<1.1-16@(TOUT)>

Portographie rétrograde

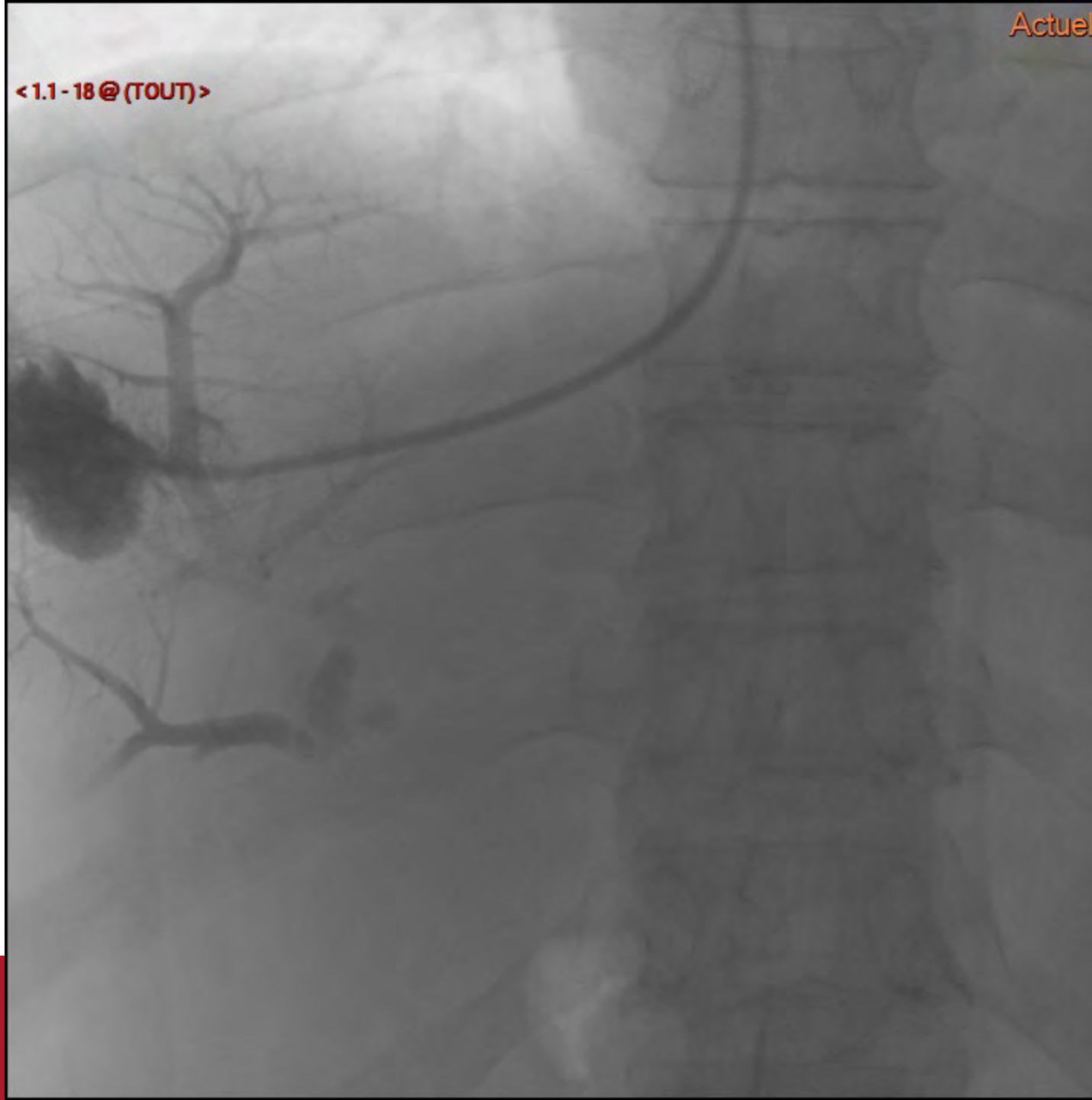


Pression bloquée: 35 mmHg

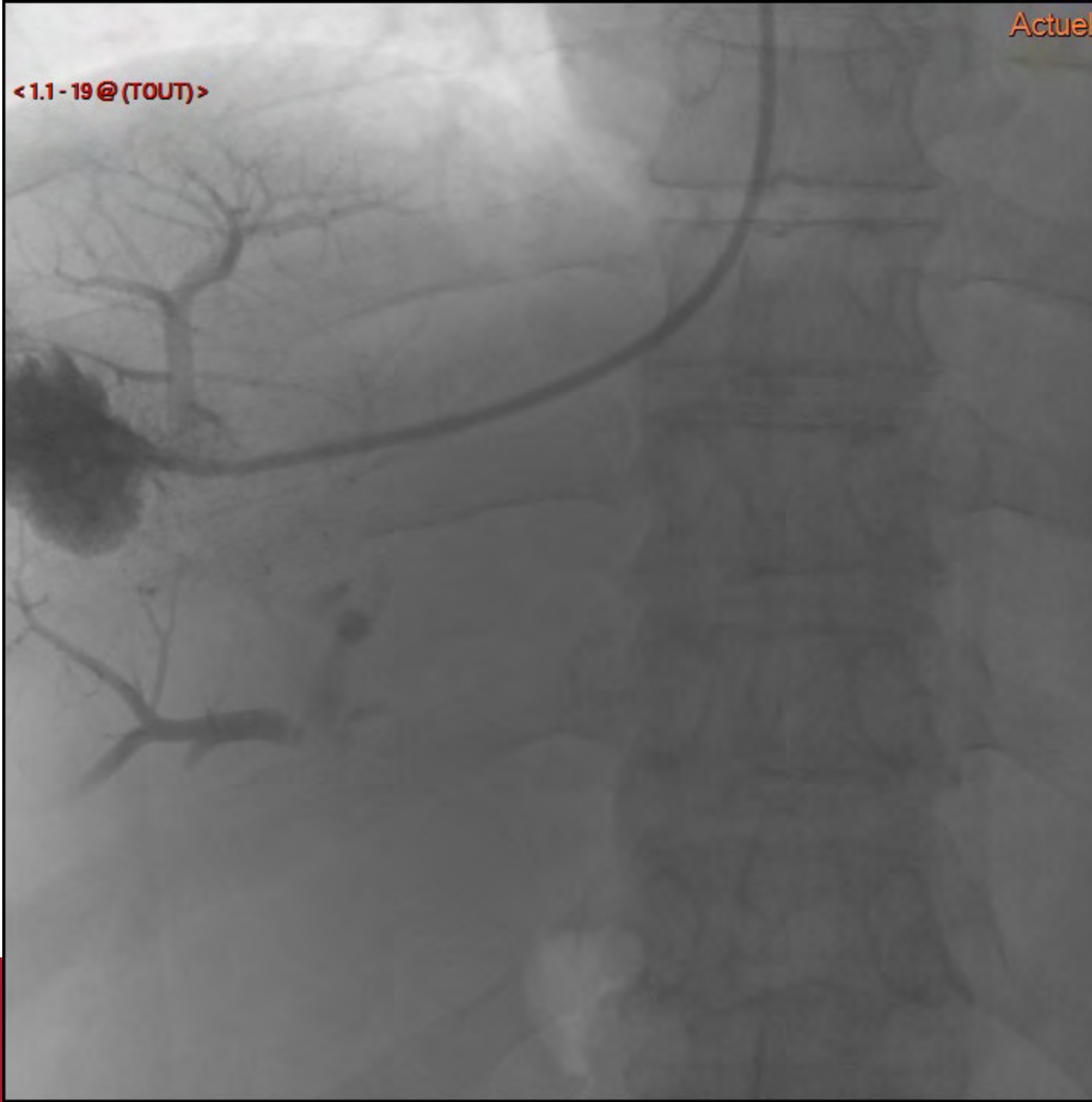
<1.1-17@ (TOUT)>



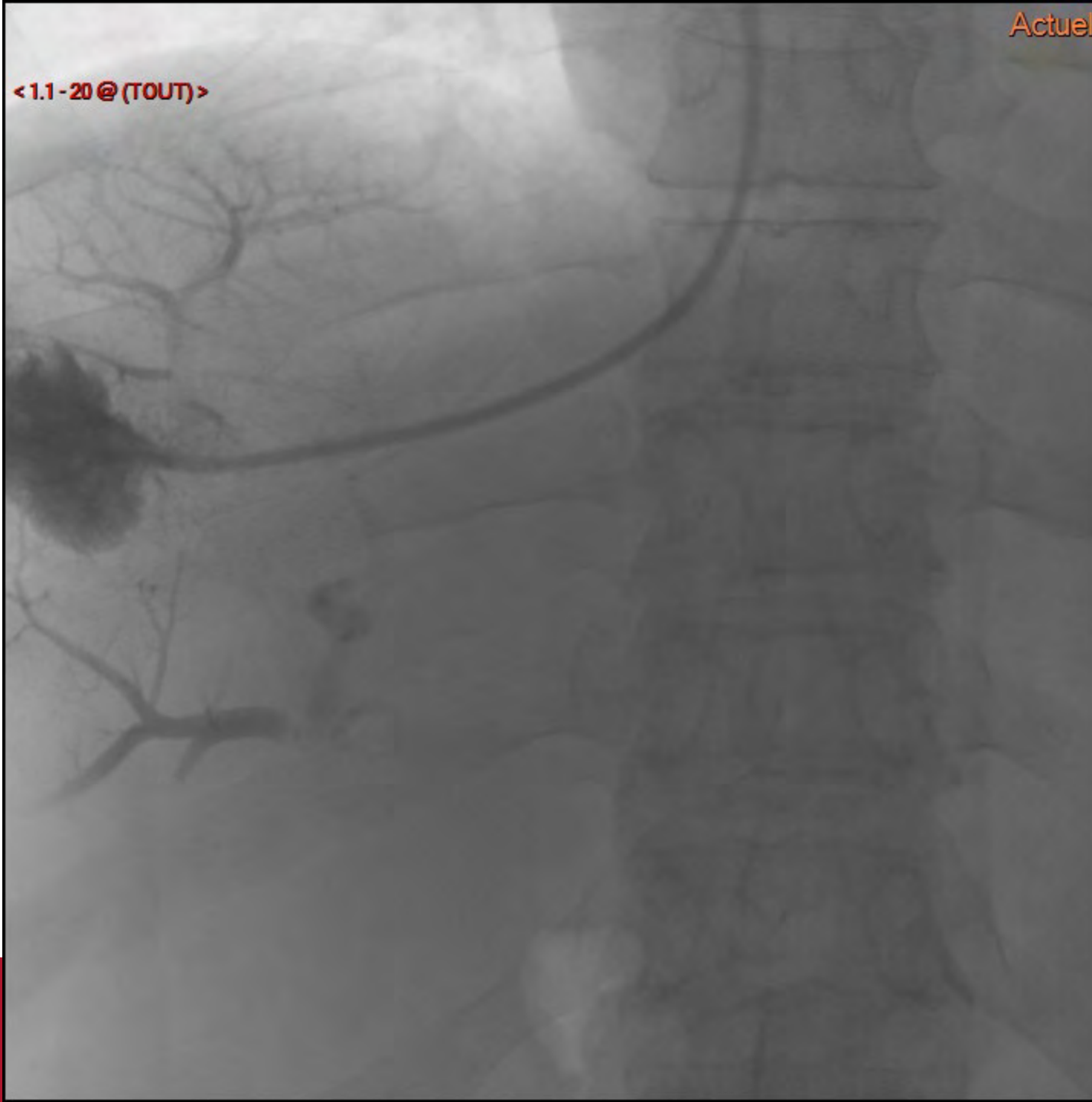<1.1-18@ (TOUT)>



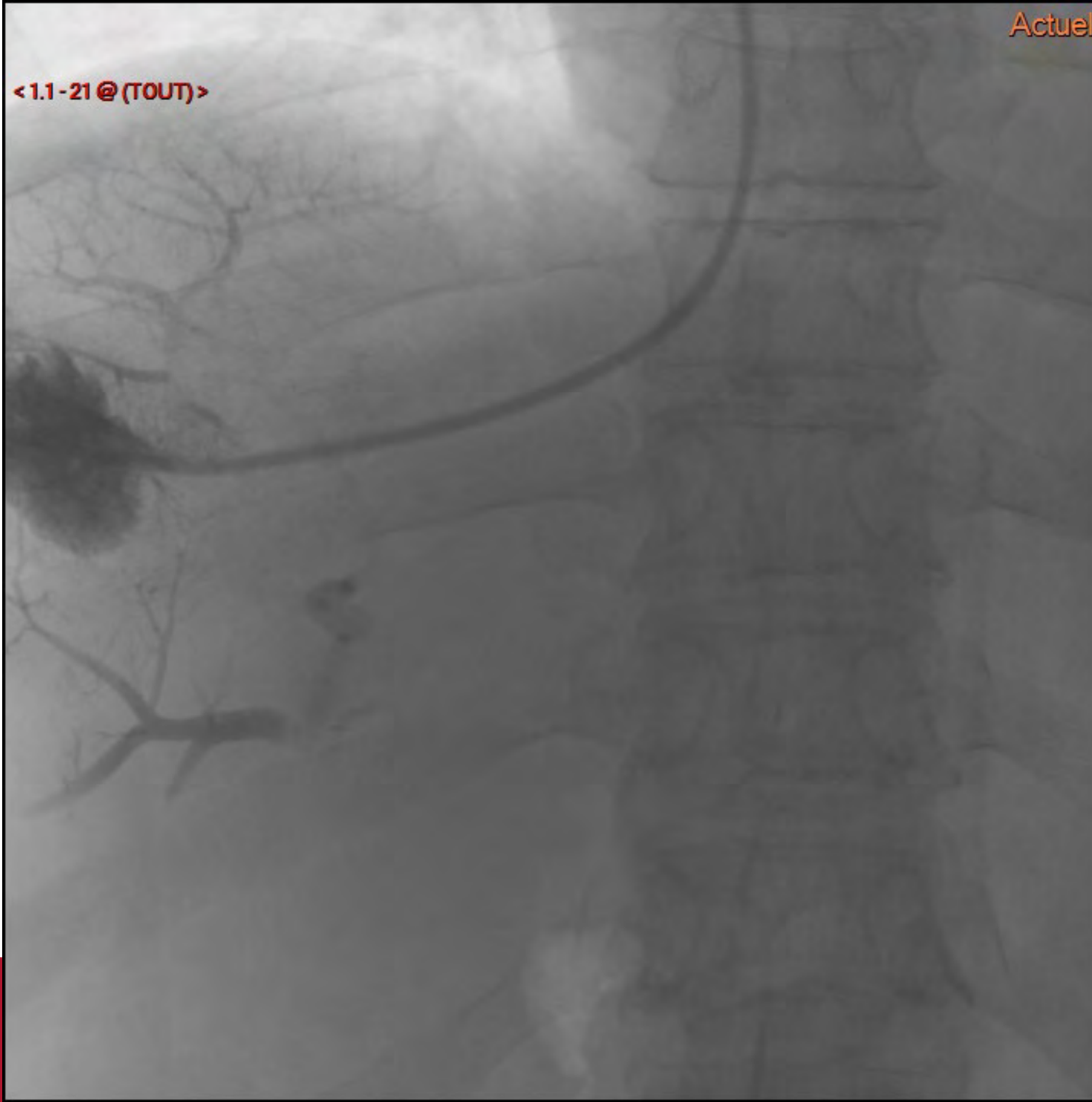
<1.1-19@ (TOUT)>



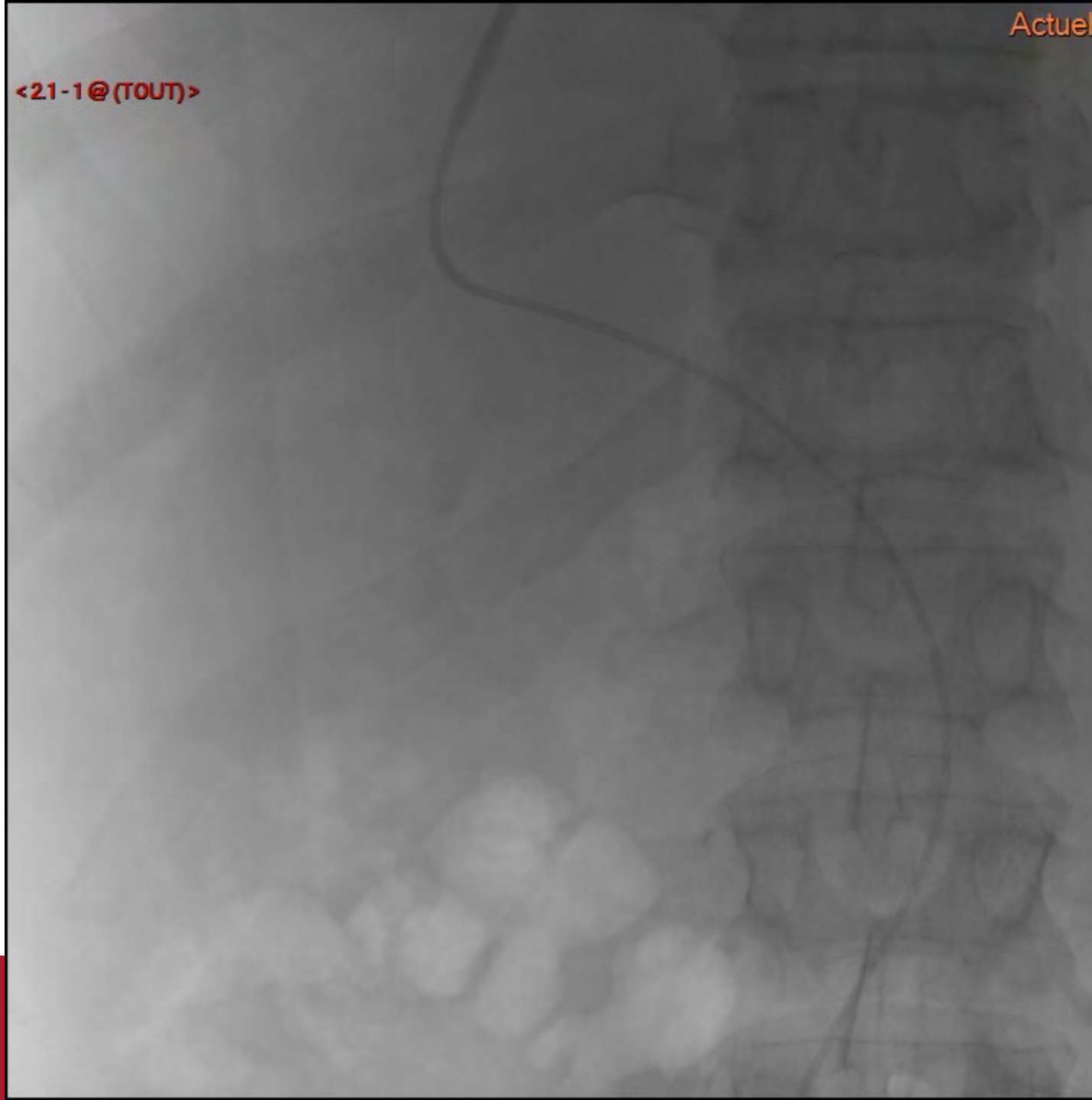
<1.1-20@ (TOUT)>



<1.1-21@TOUT>



<21-1@TOUT>

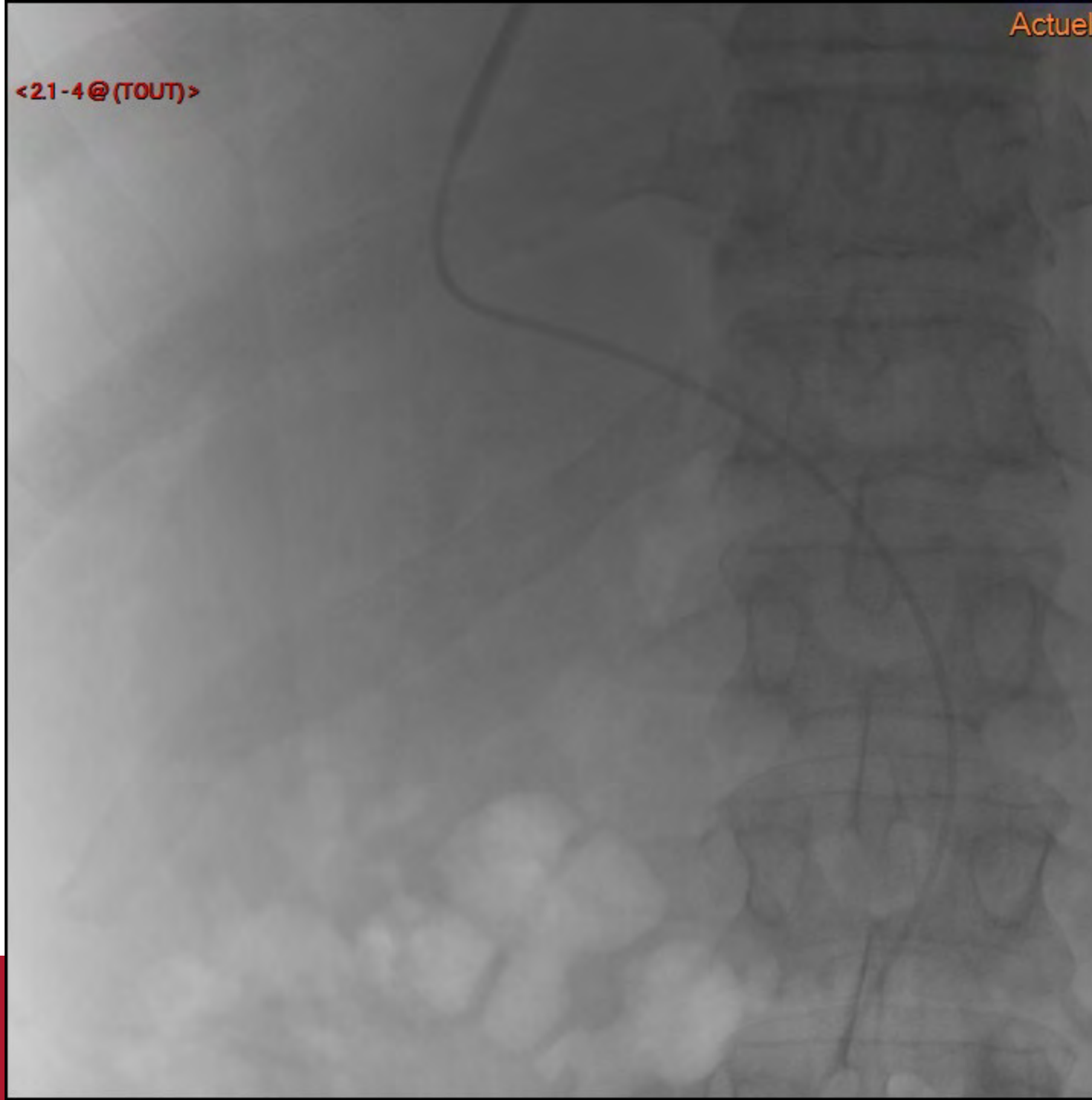


<21-2@ (TOUT)>

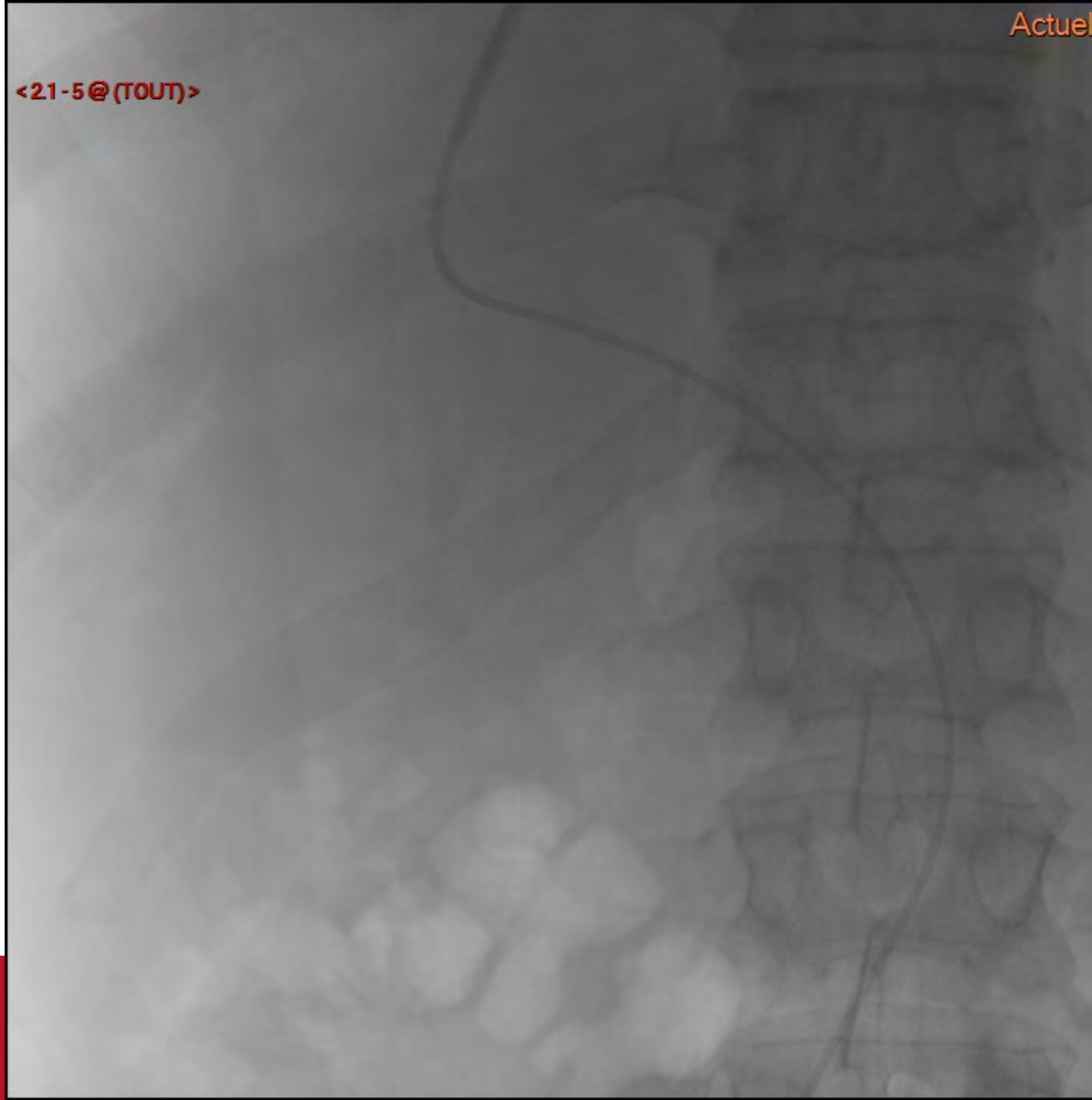
Cathétérisation du tronc porte

<21-3@ (TOU) >

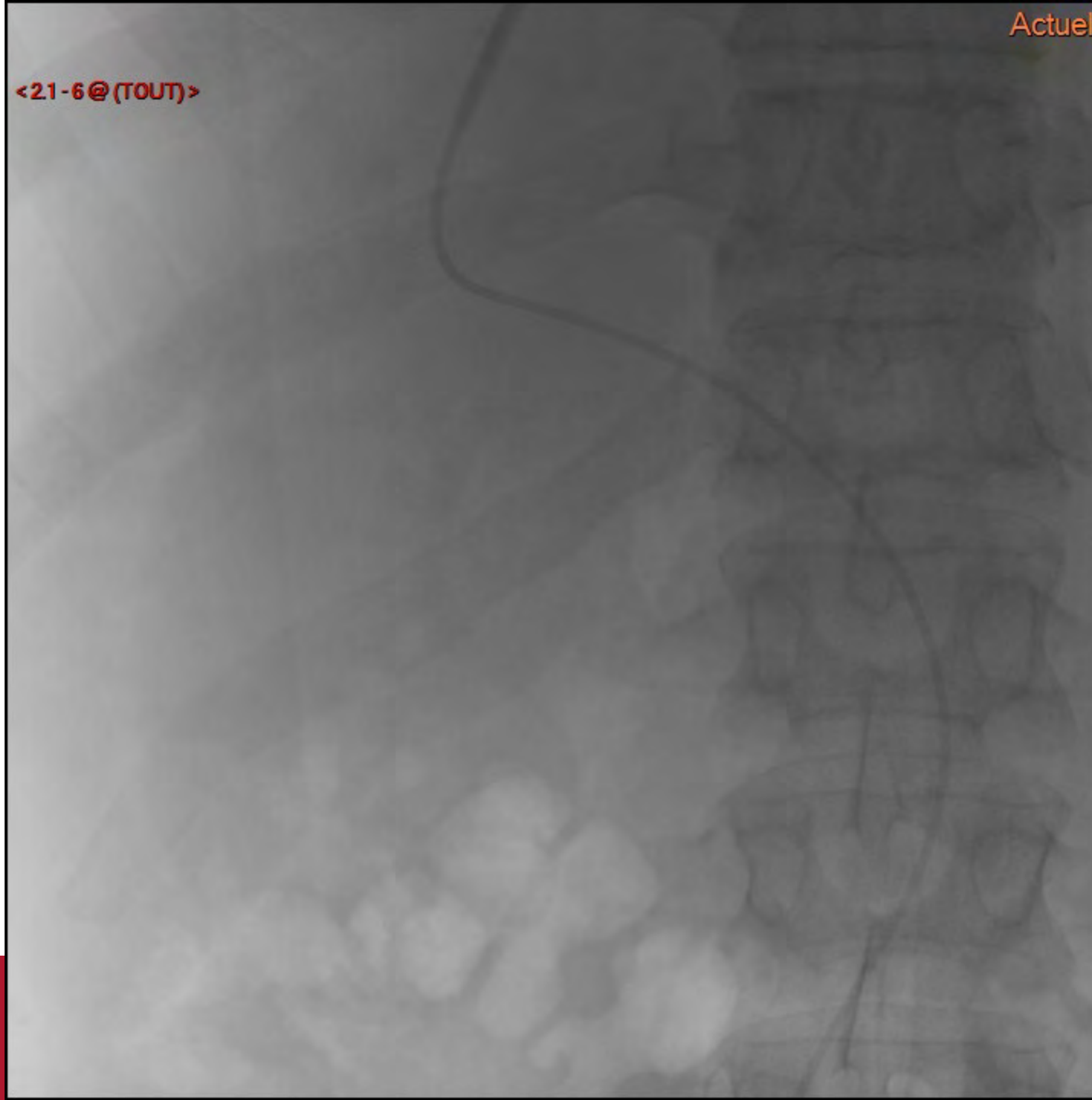
<21-4@ (TOUT)>



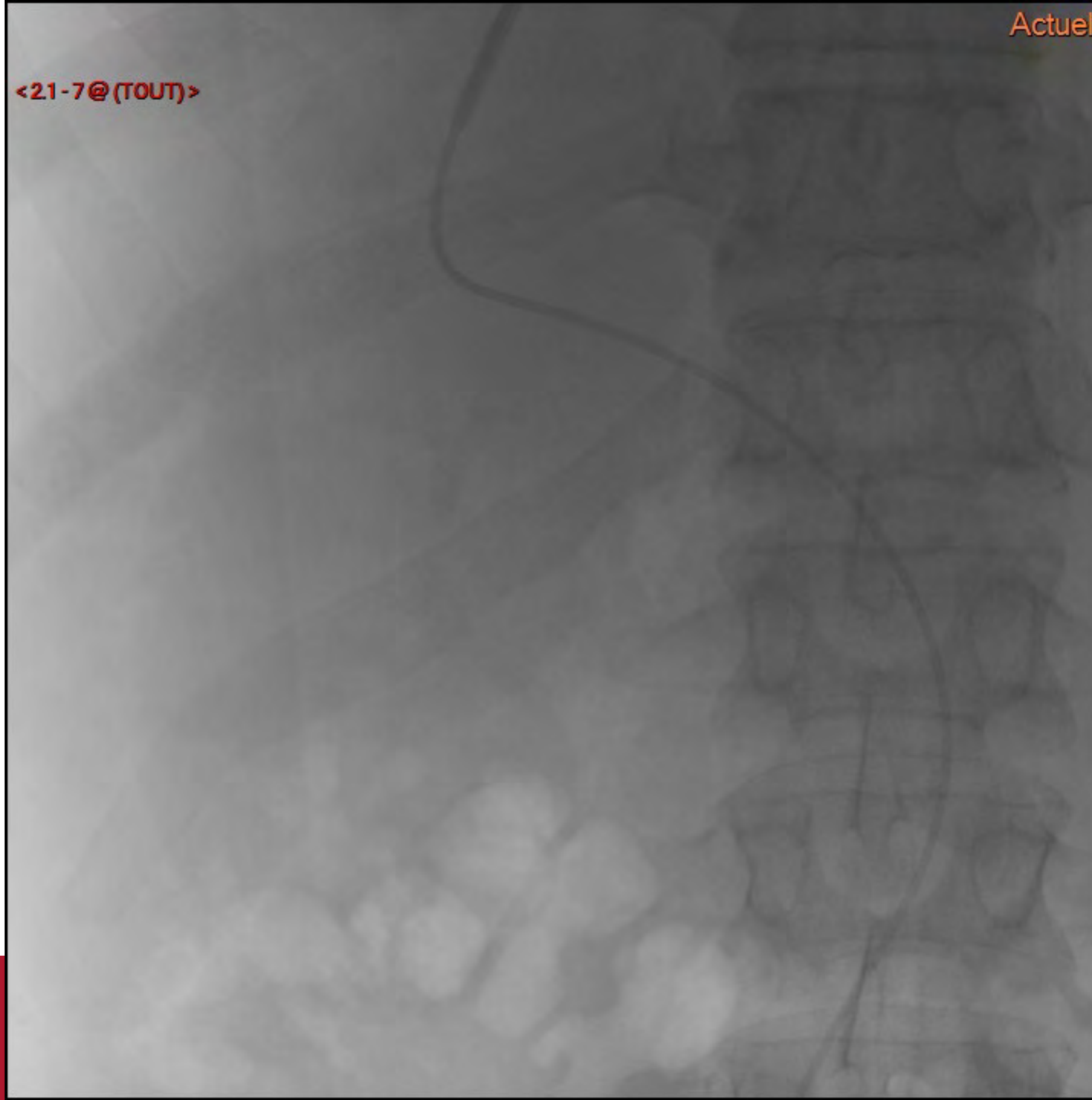
<21-5@ (TOUT)>



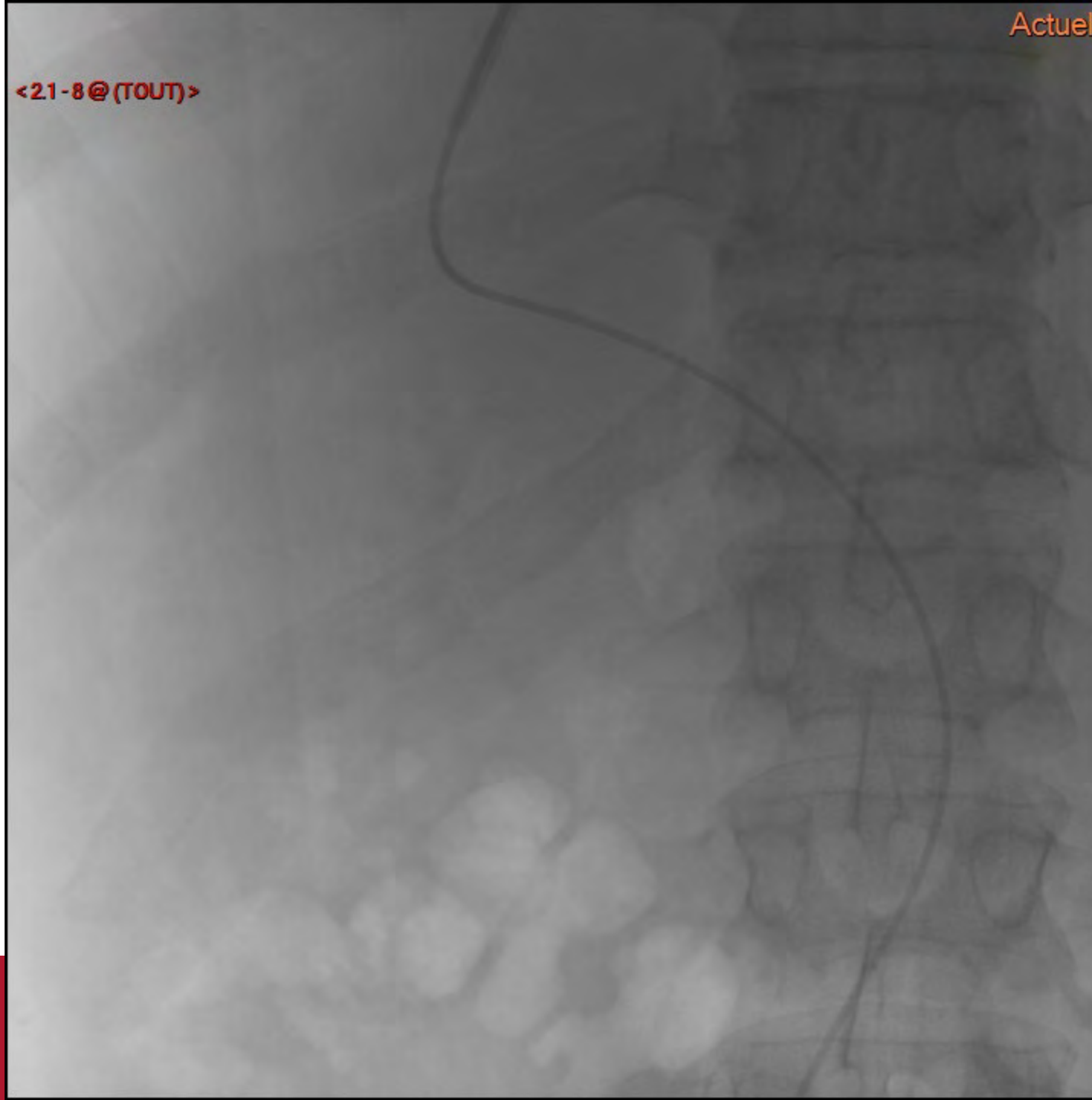
<21-6@ (TOUT)>



<21-7@ (TOUT)>

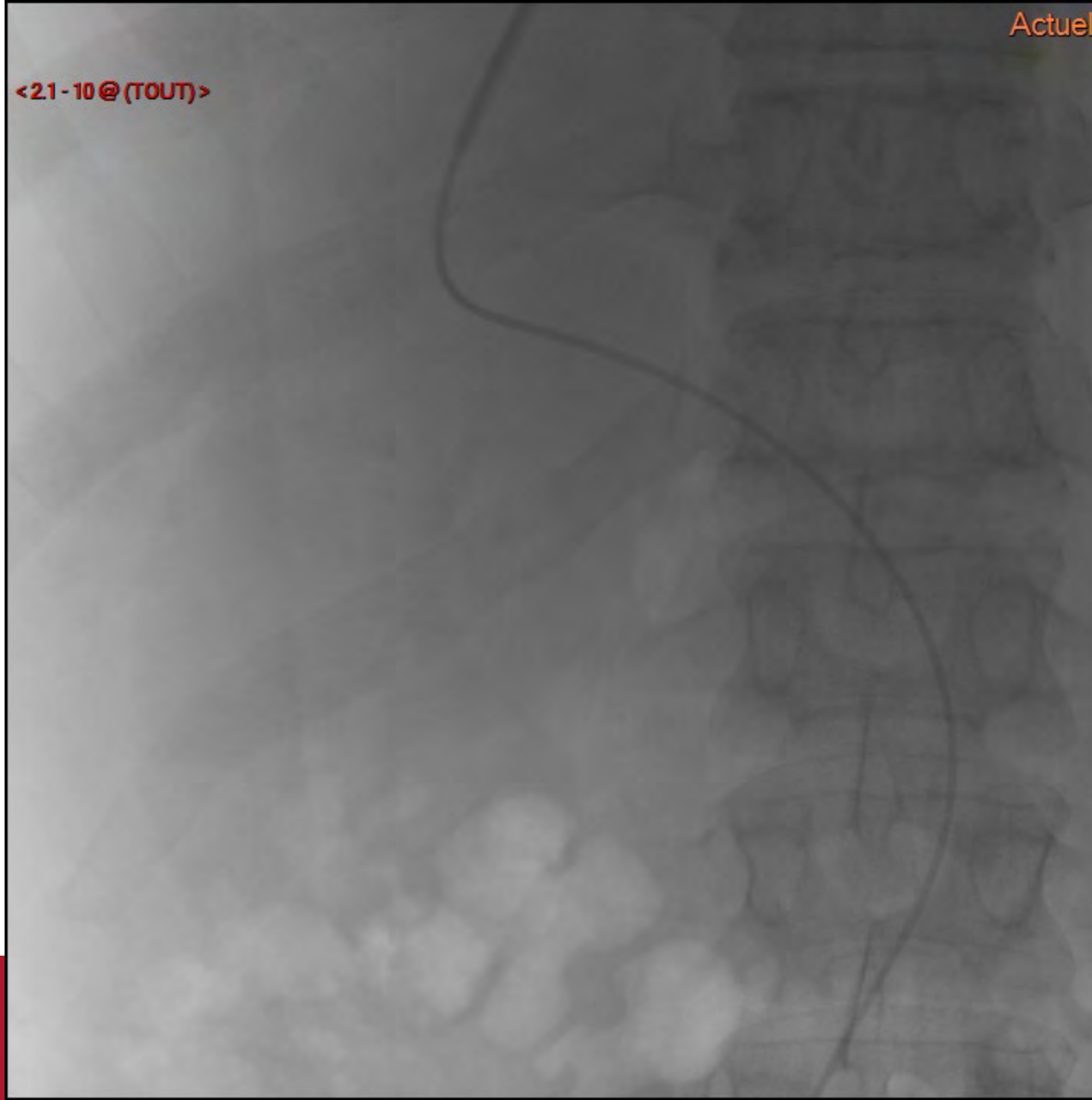


<21-8@ (TOUT)>



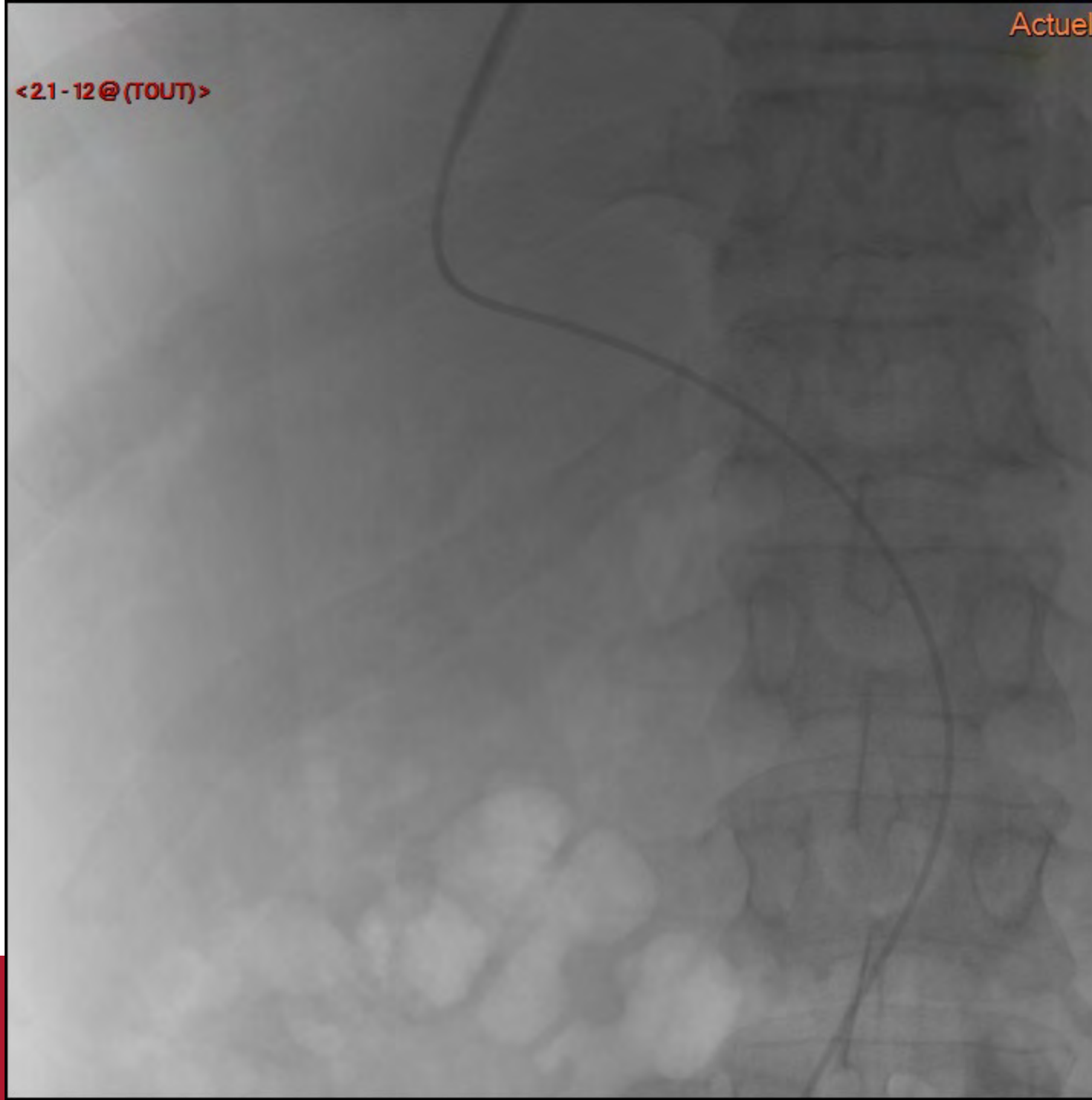
<21-9@ (TOUT)>

<21-10@ (TOUT)>

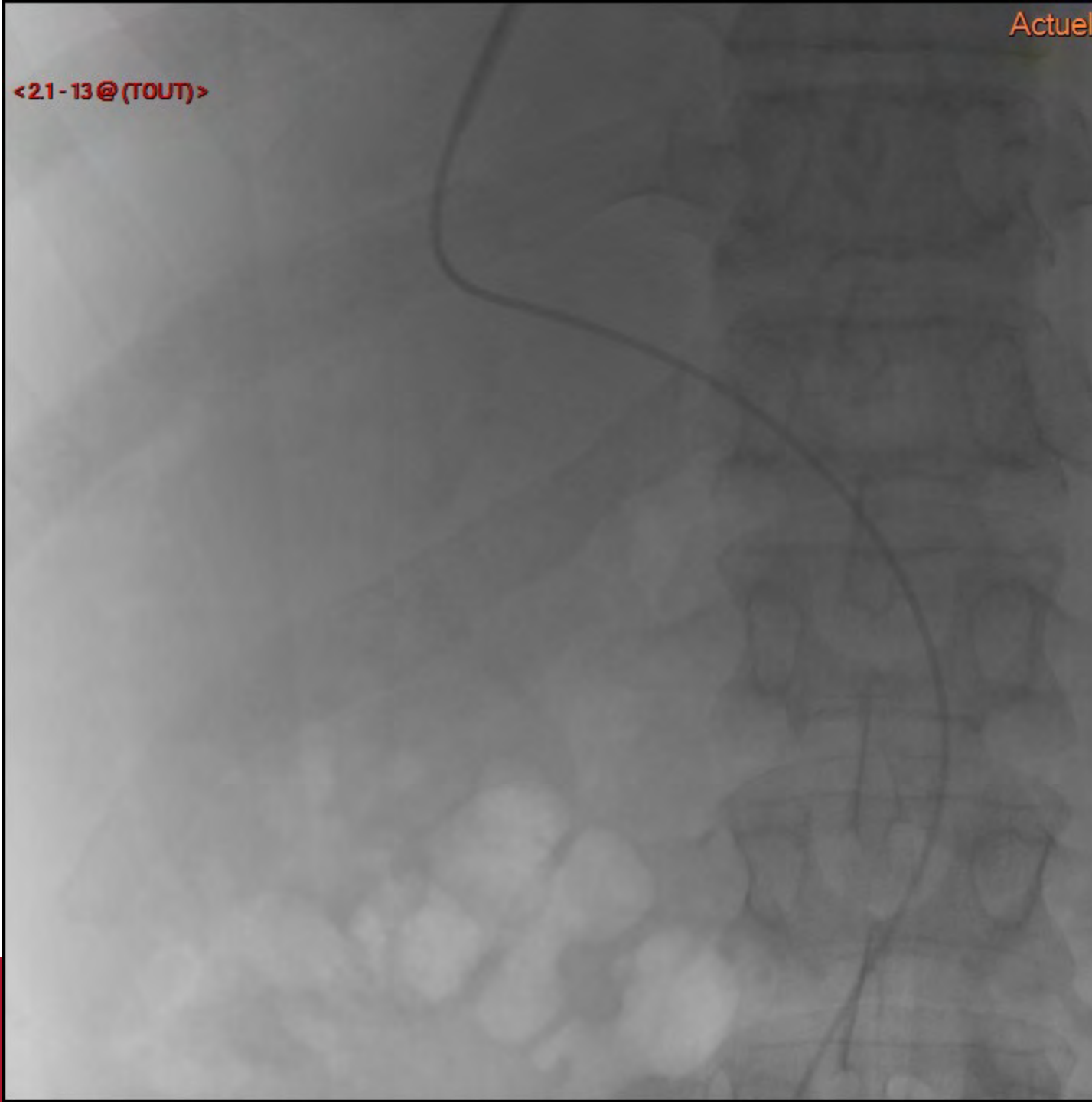


<21-11@tout>

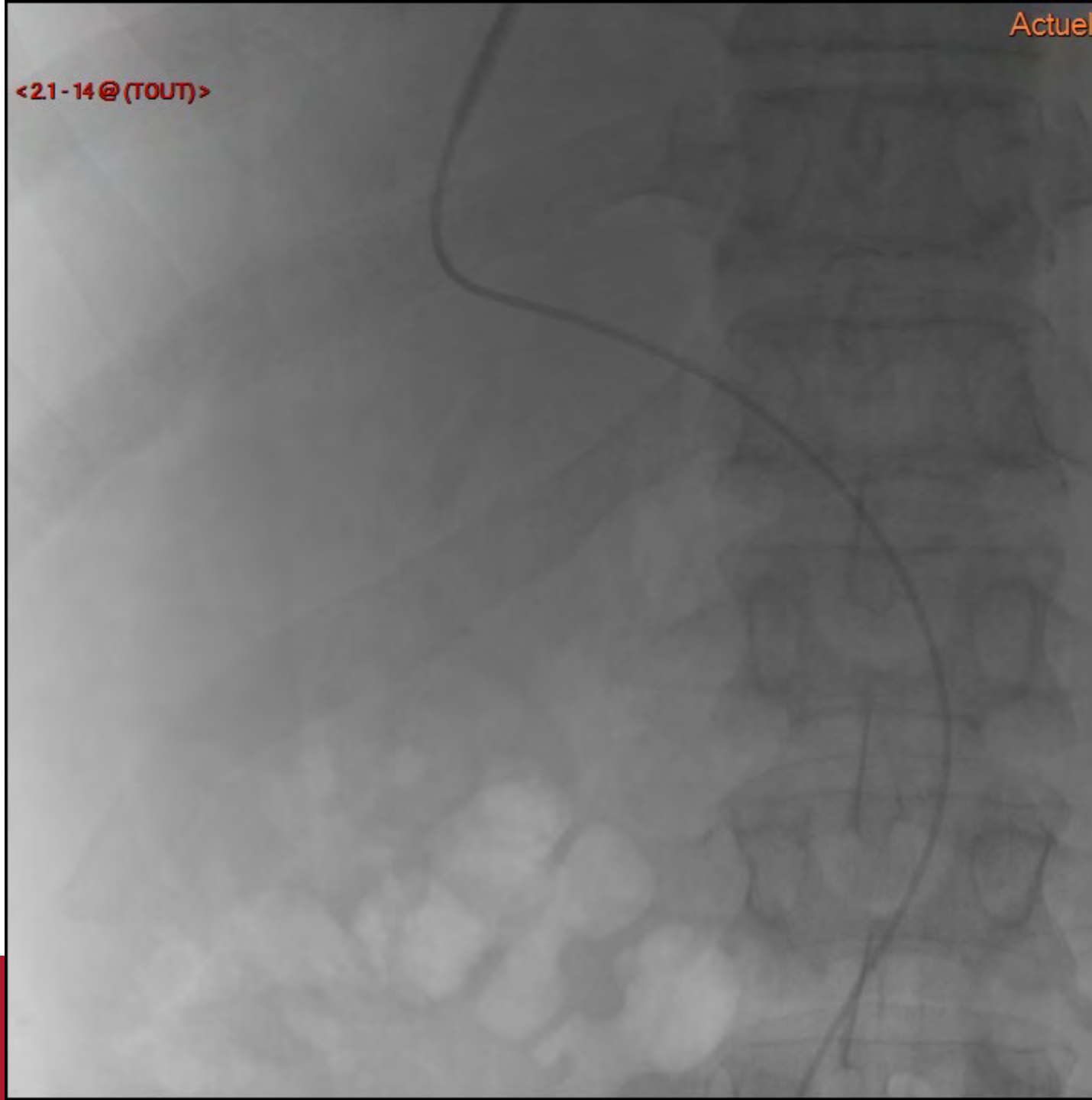
<21-12@TOUT>



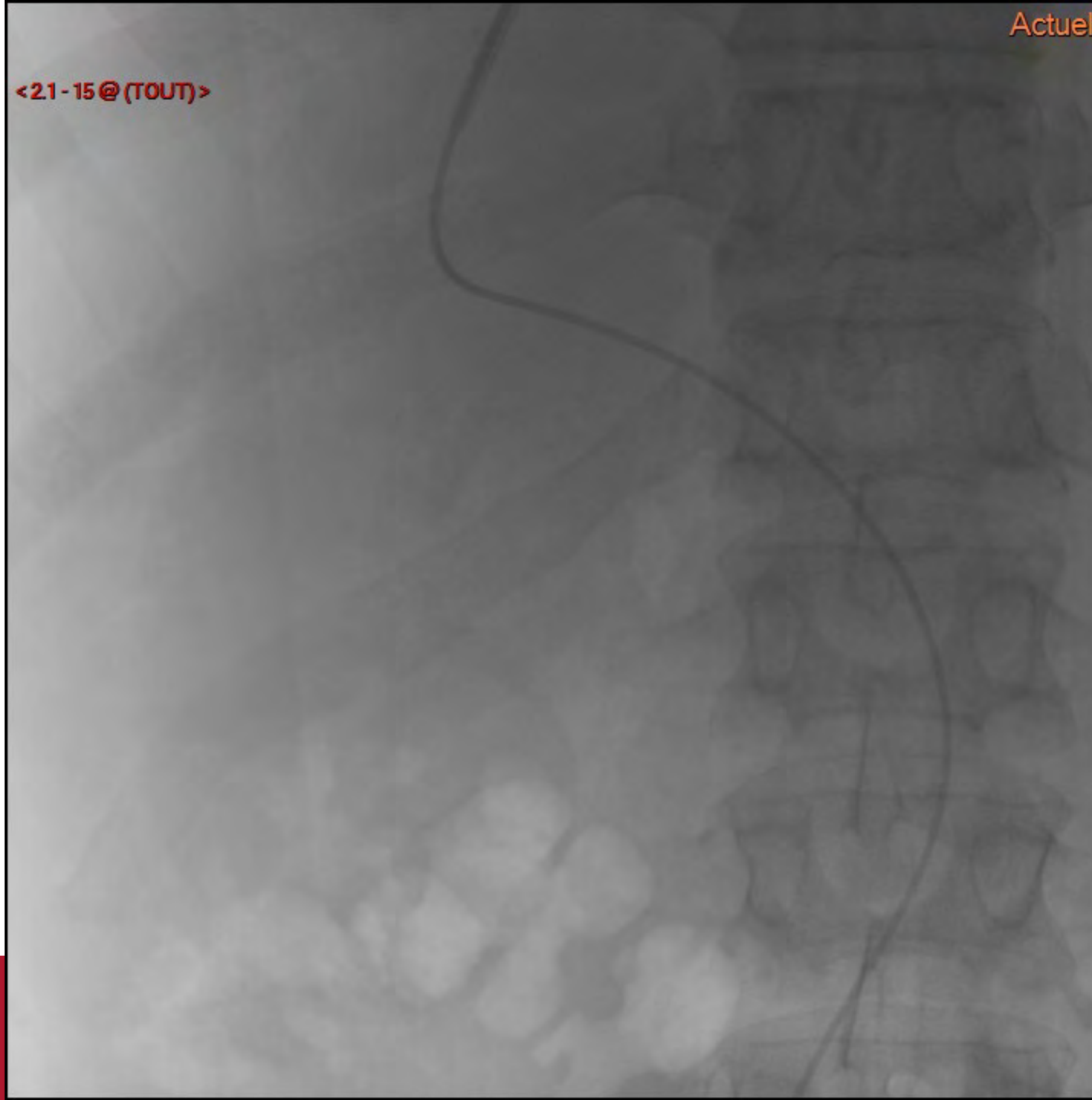
<21-13@TOUT>



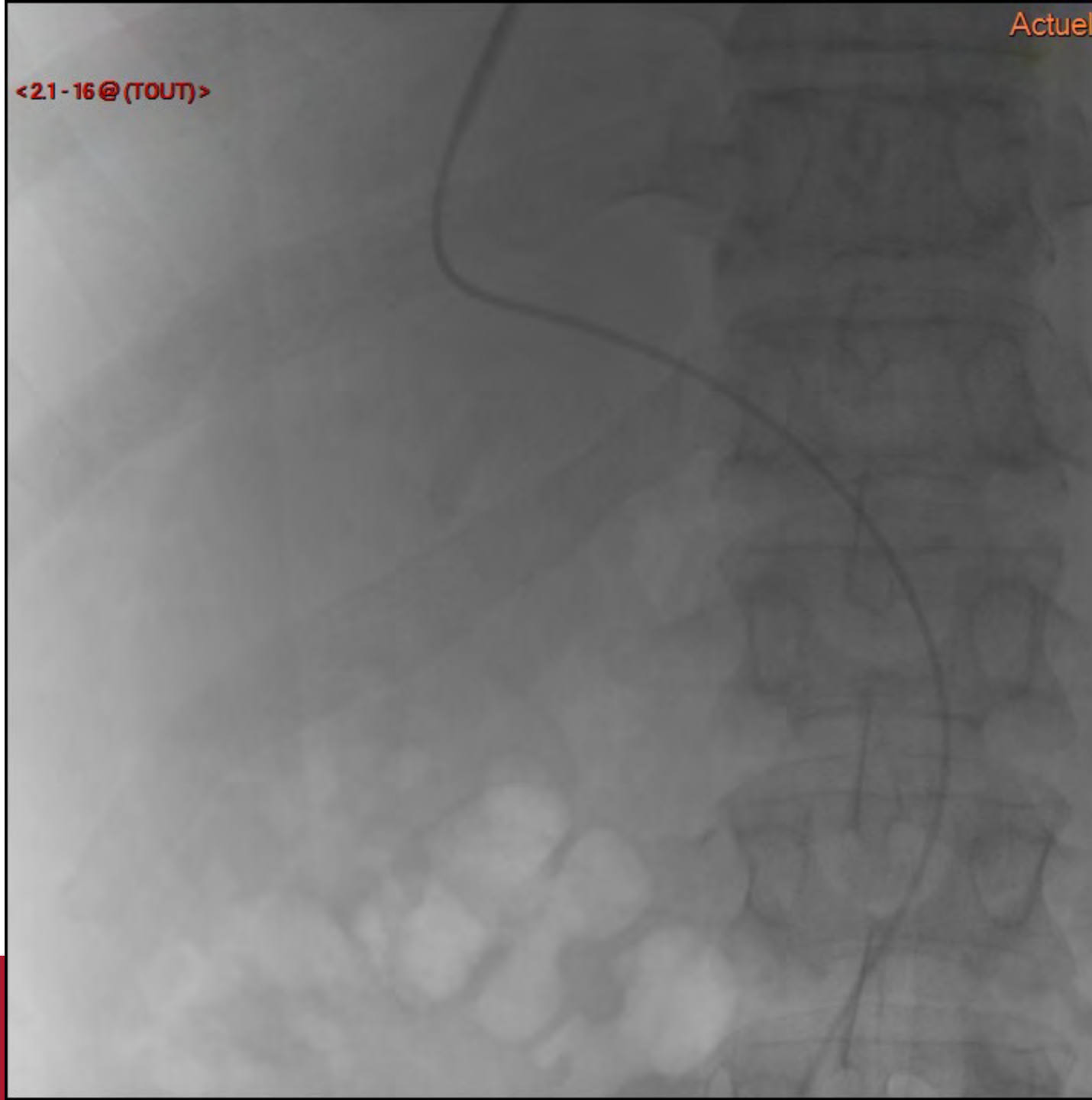
<21-14@TOUT>



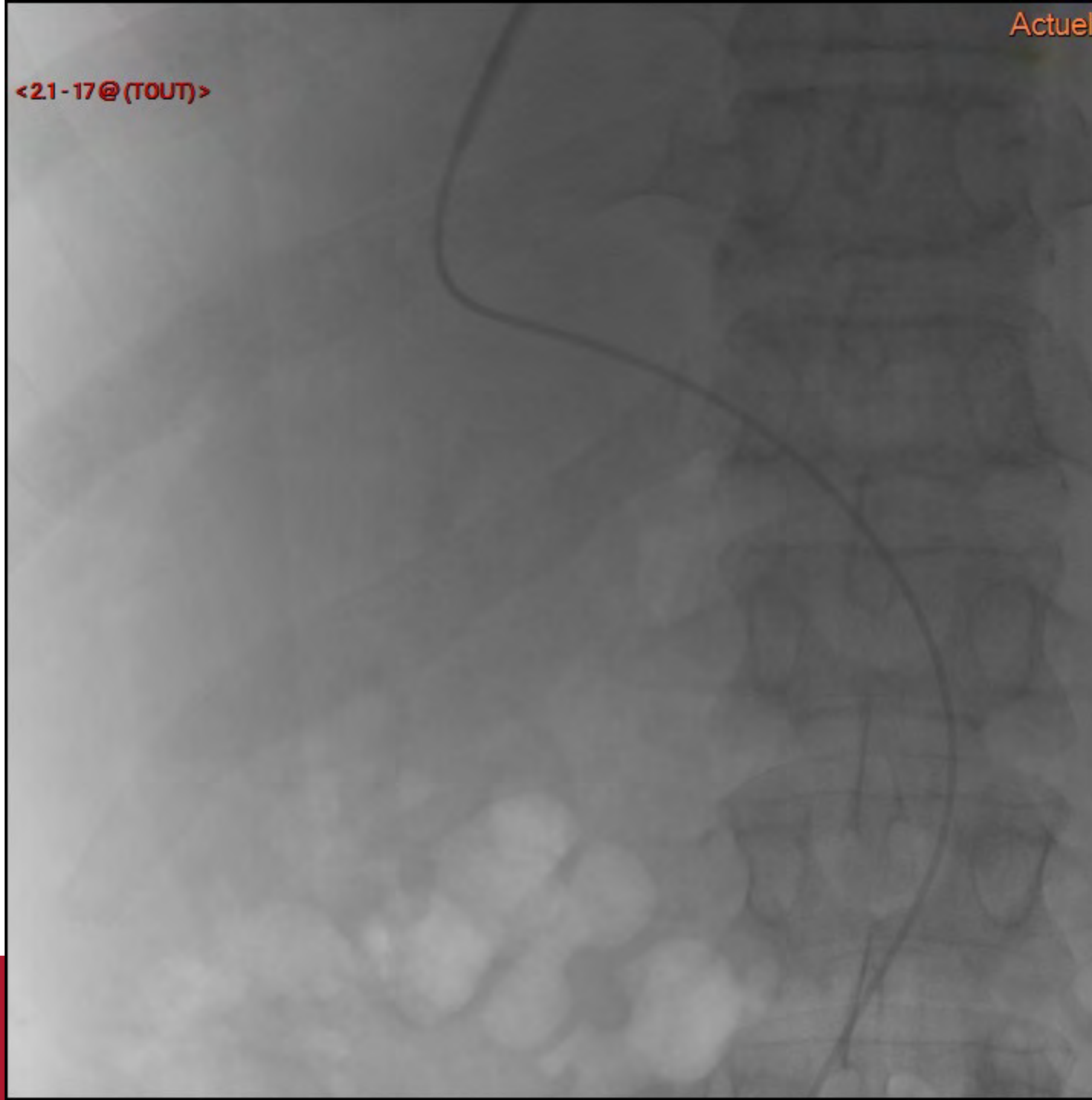
<21-15@ (TOUT)>



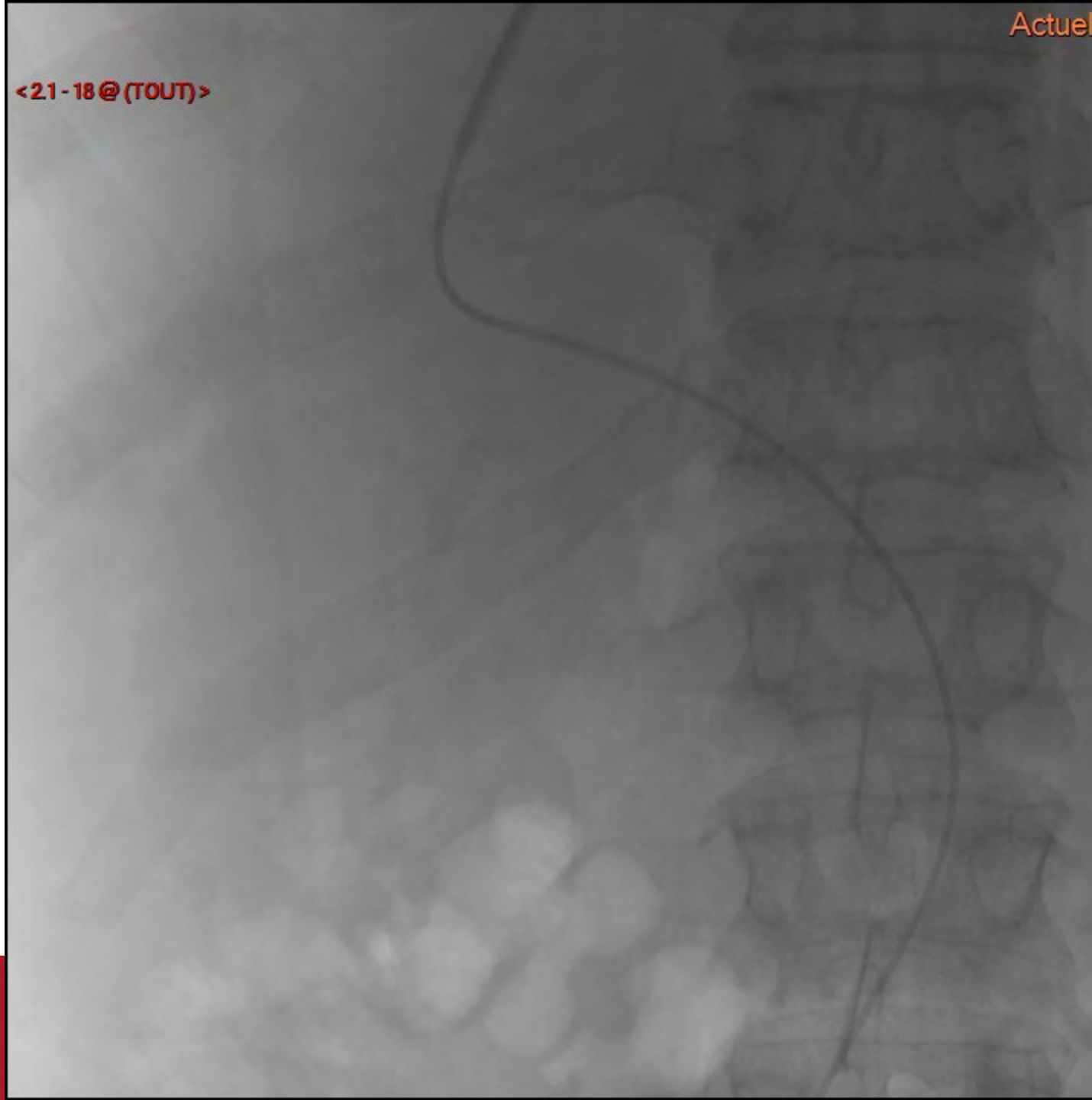
<21-16@TOUT>



<21-17@TOUT>

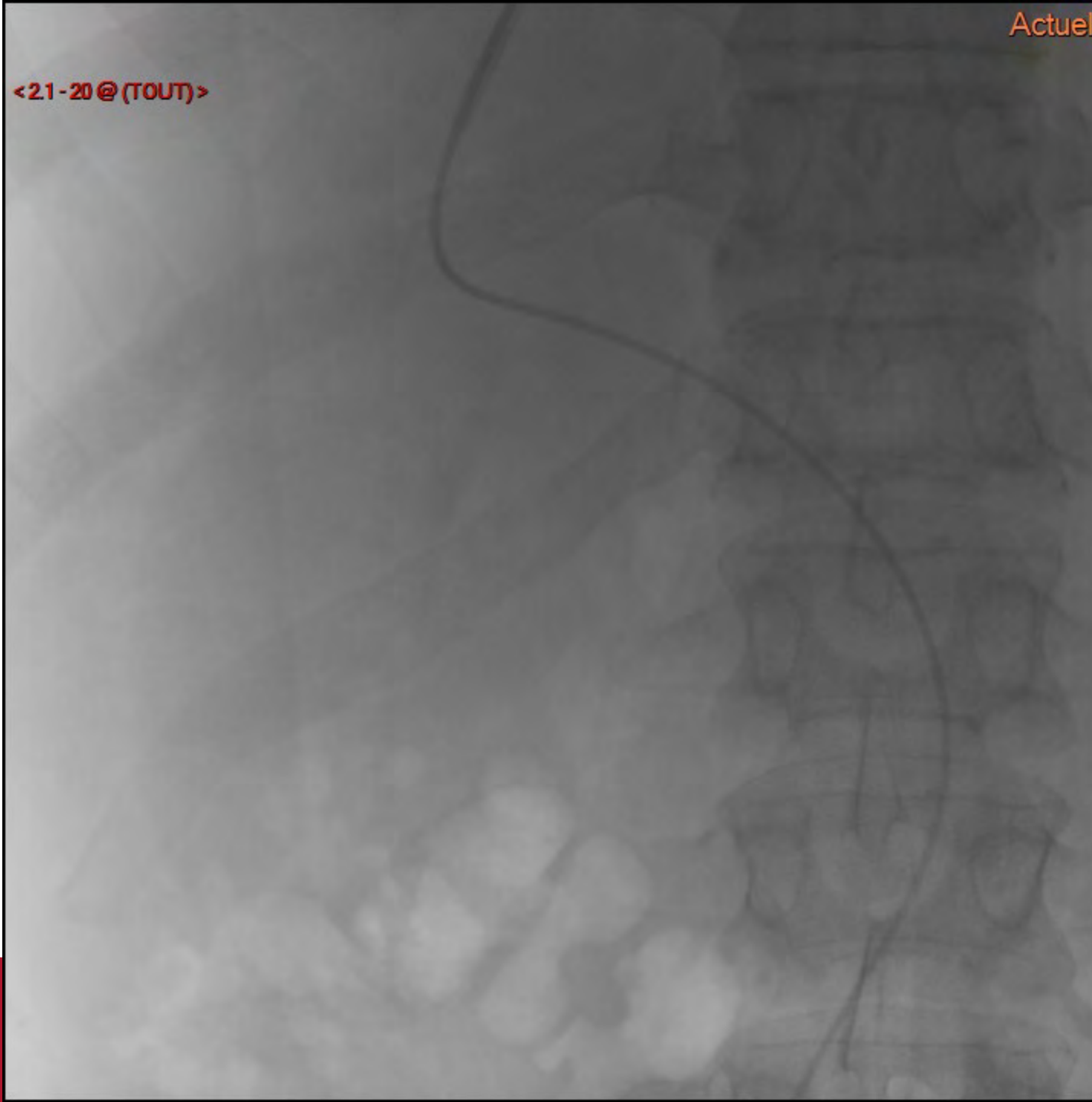


<21-18@TOUT>



<21-19@ (TOUT)>

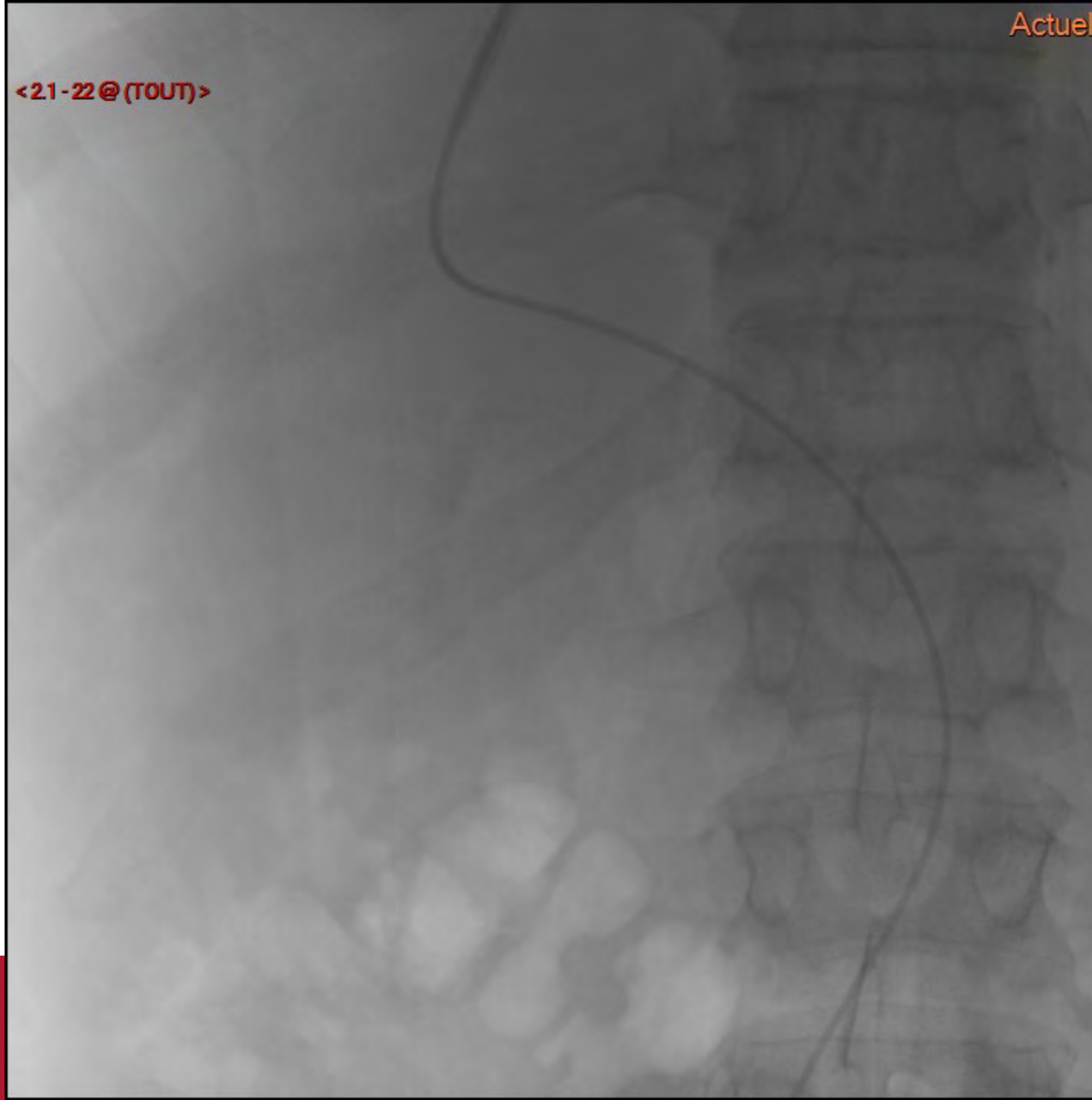
<21-20@TOUT>



<21-21@TOUT>

Opacification

<21-22@TOUT>



<21-23@TOUT>

<21-24@TOUT>

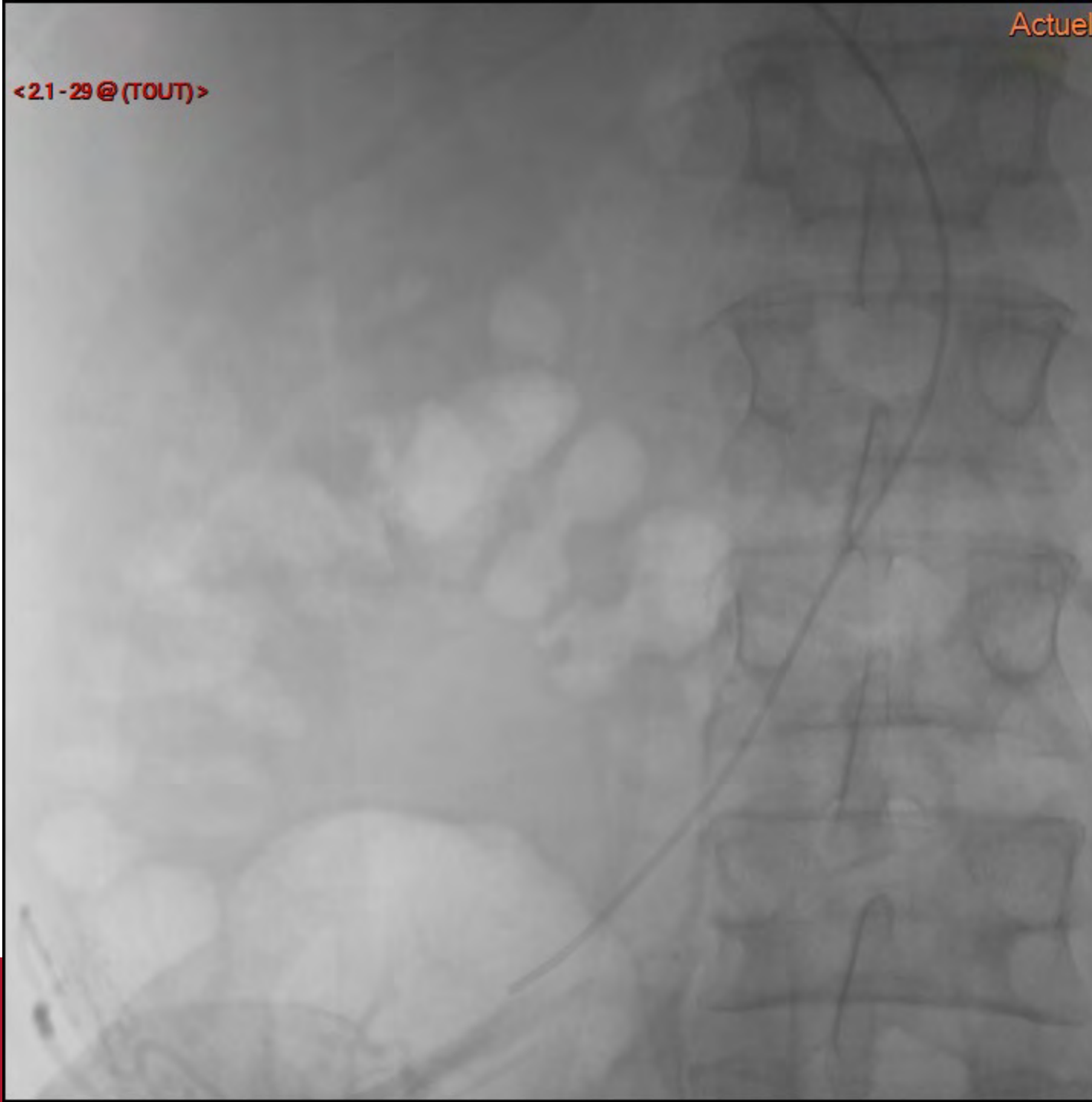<21-25@TOUT>

<21-26@ (TOUT)>

<21-27@TOUT>

<21-28@TOUT>

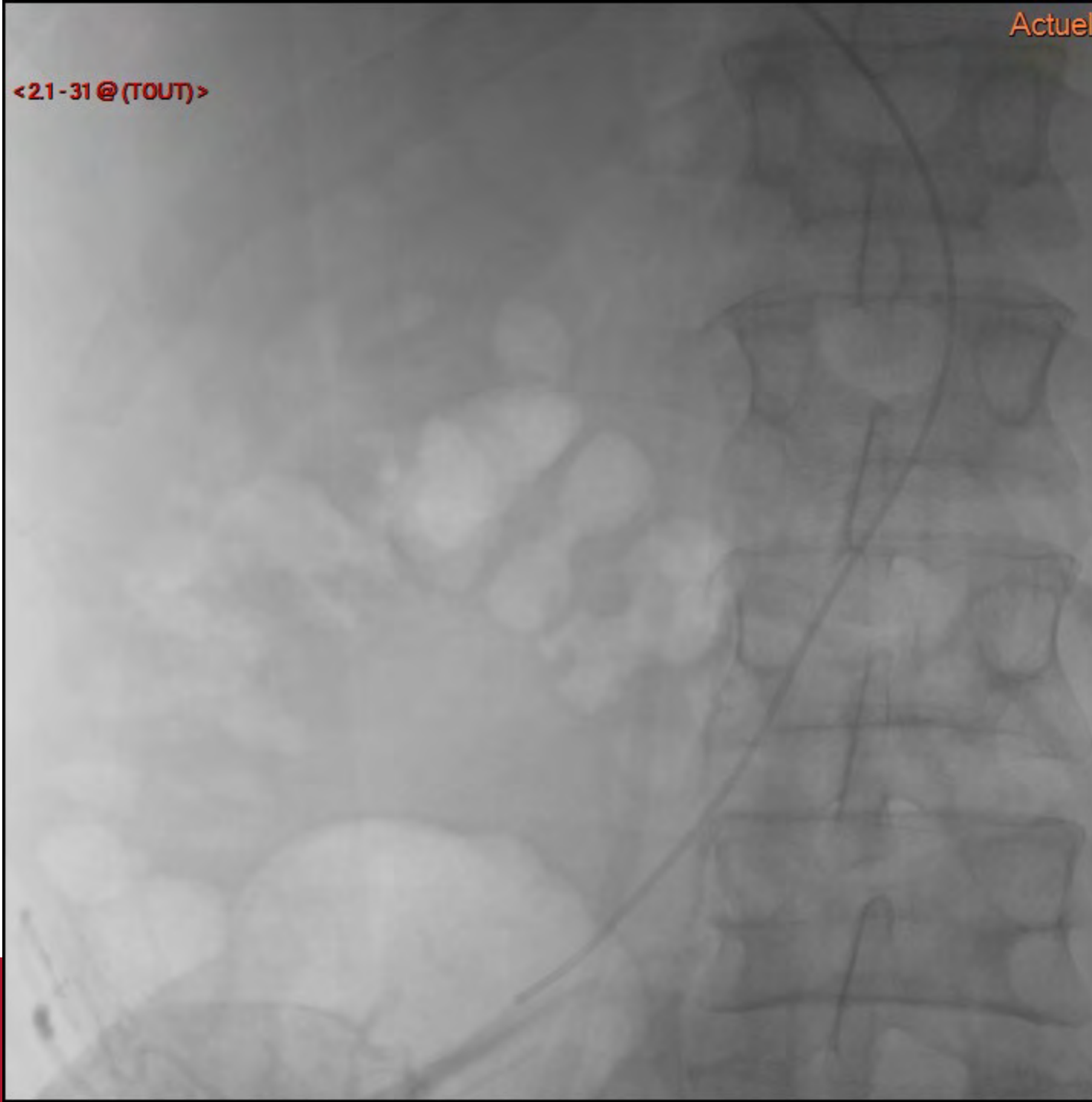
<21-29@TOUT>



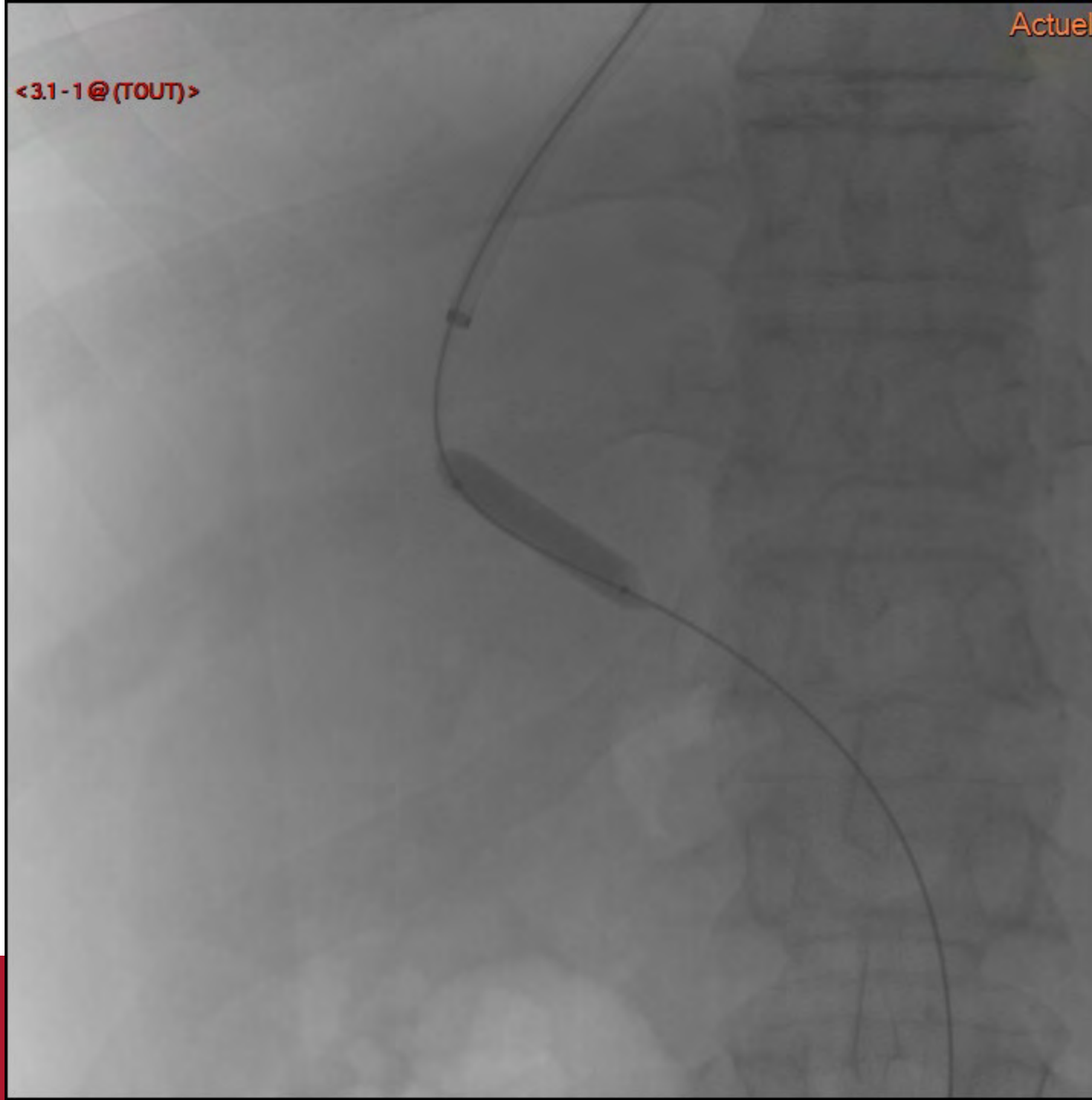
<21-30@TOUT>

Veine caeco-appendiculaire: rétrograde

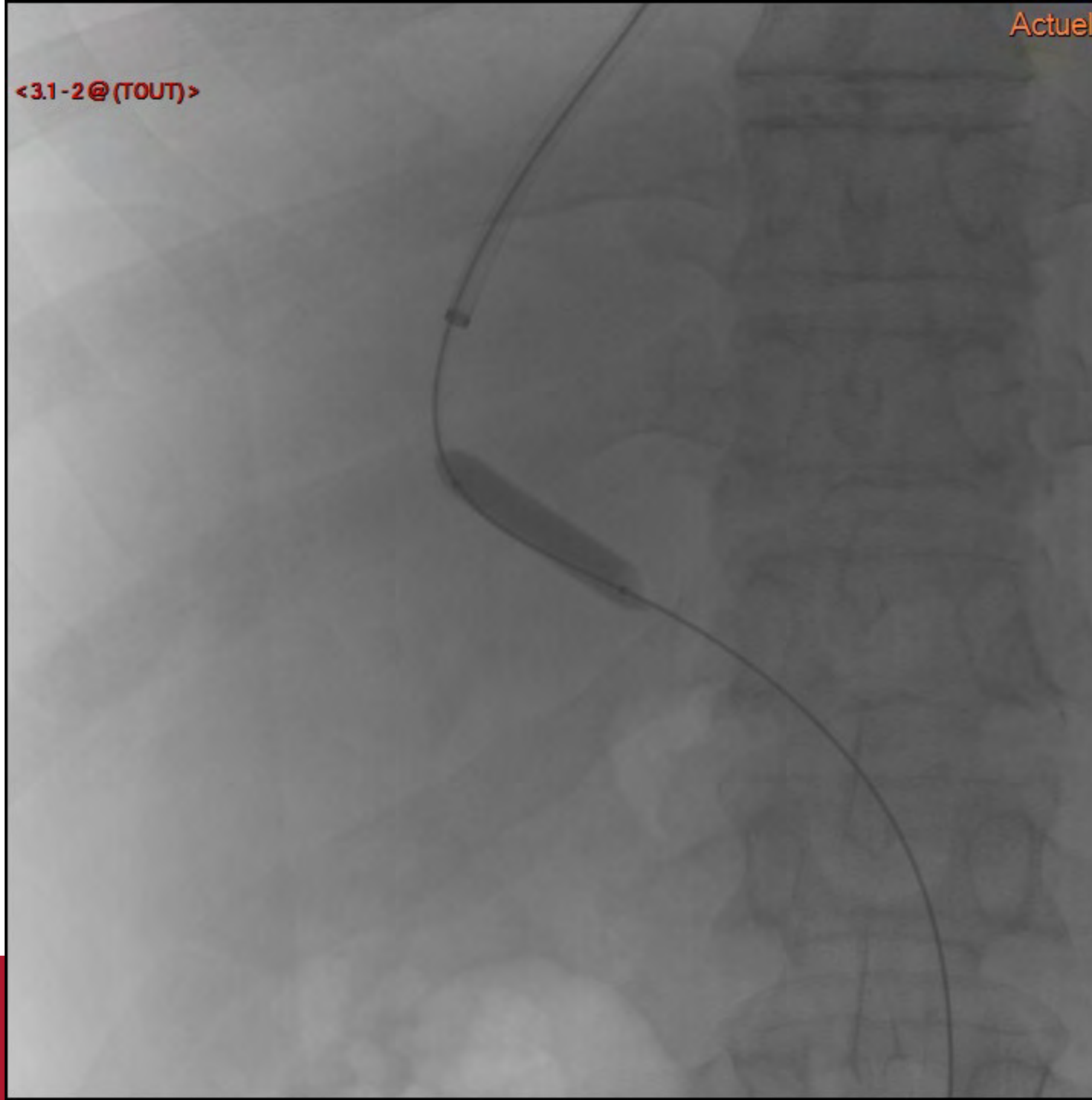
<21-31 @ (TOUT)>



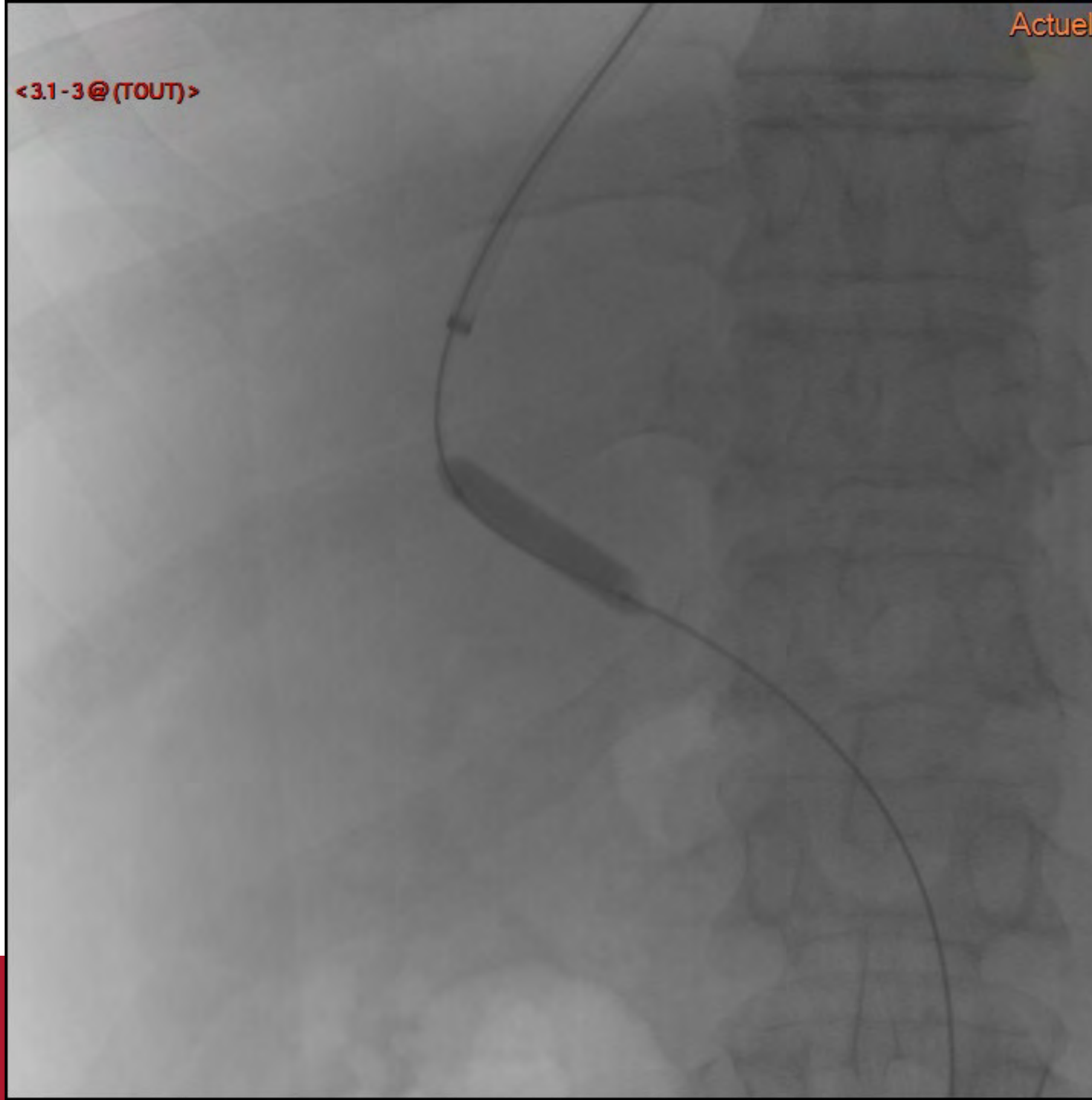
<3.1-1@ (TOUT)>



<3.1-2@ (TOUT)>



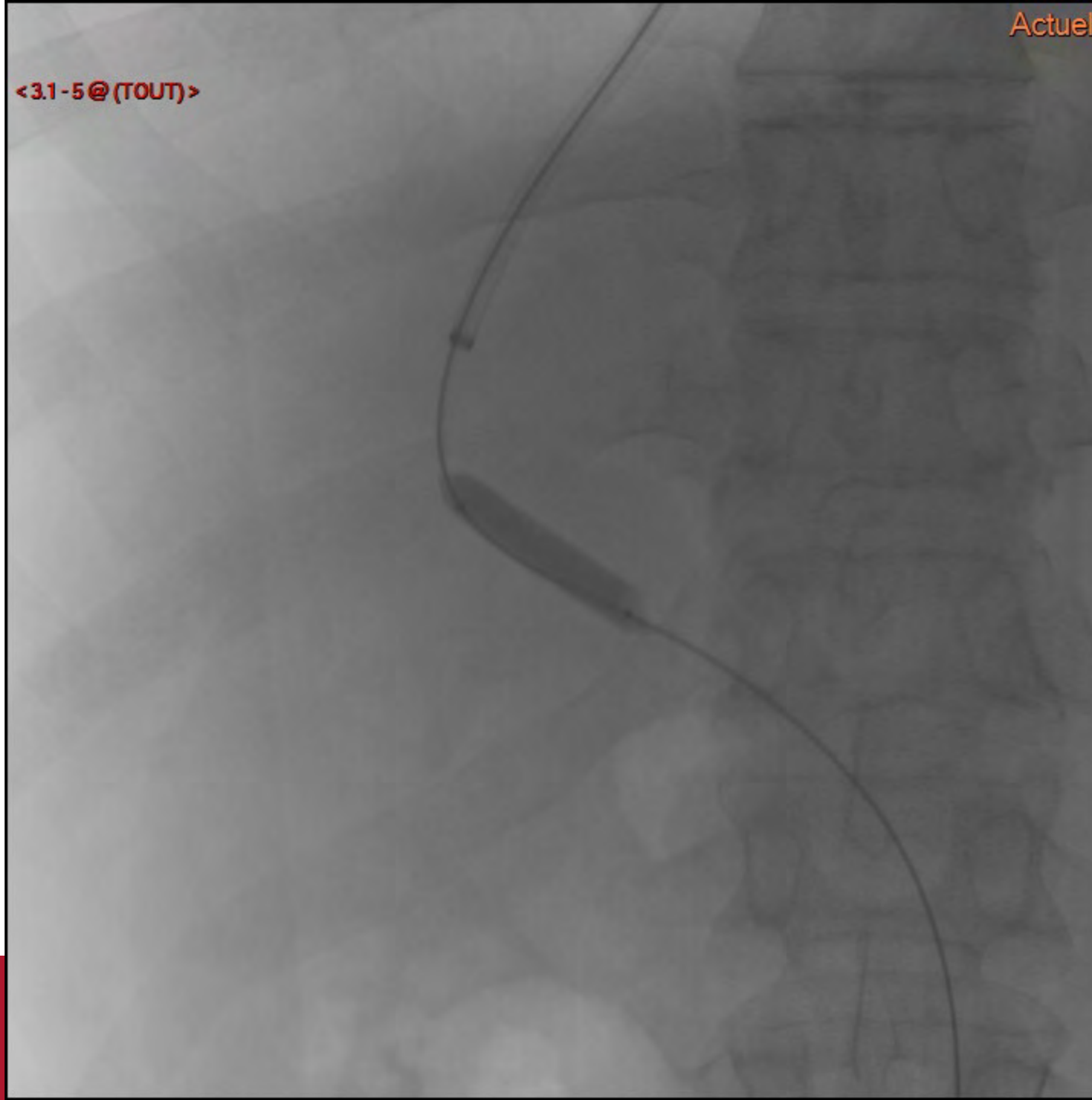
<3.1-3@ (TOU) >



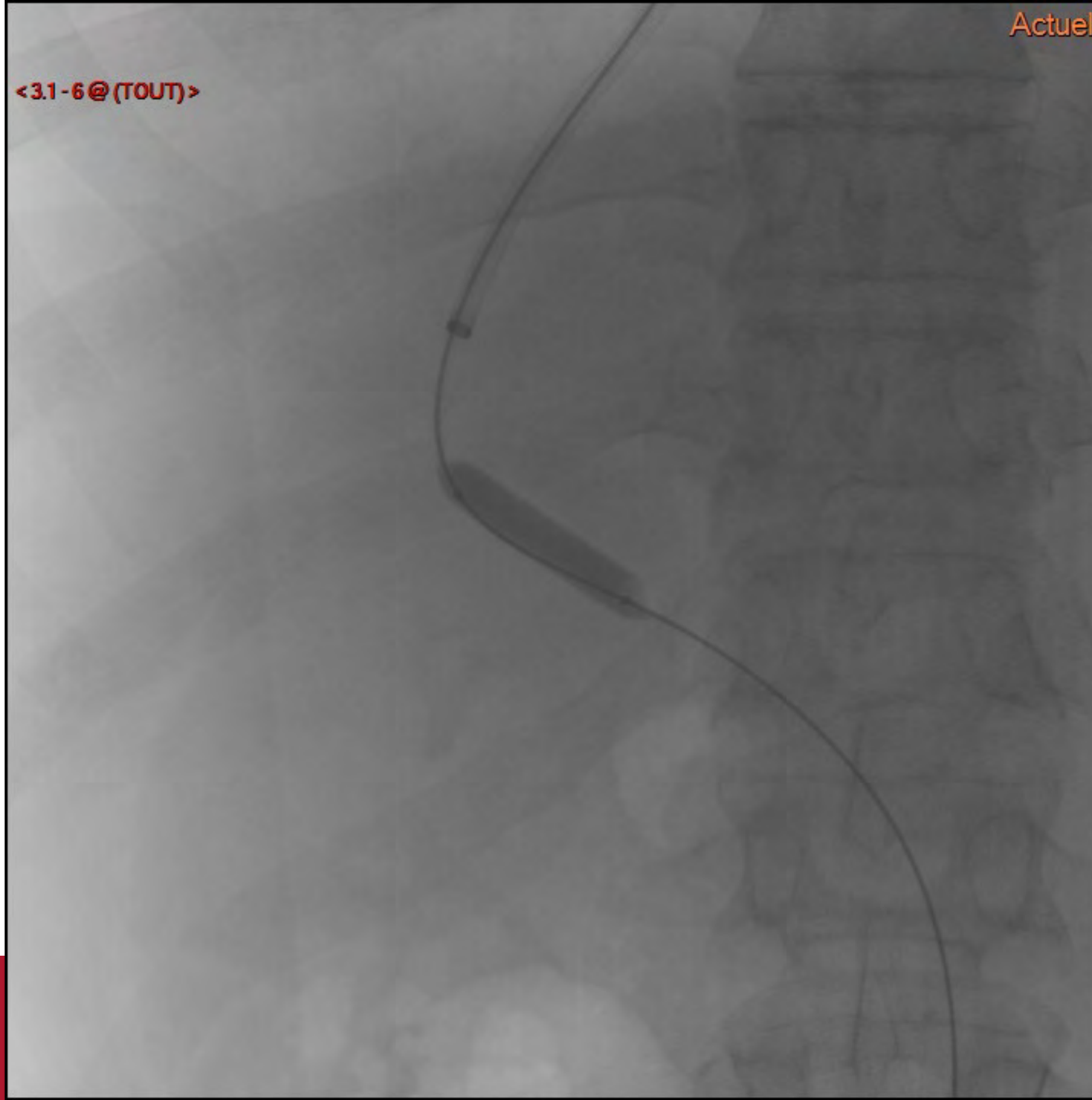
<3.1-4@(TOUT)>

Dilatation du trajet intra hépatique

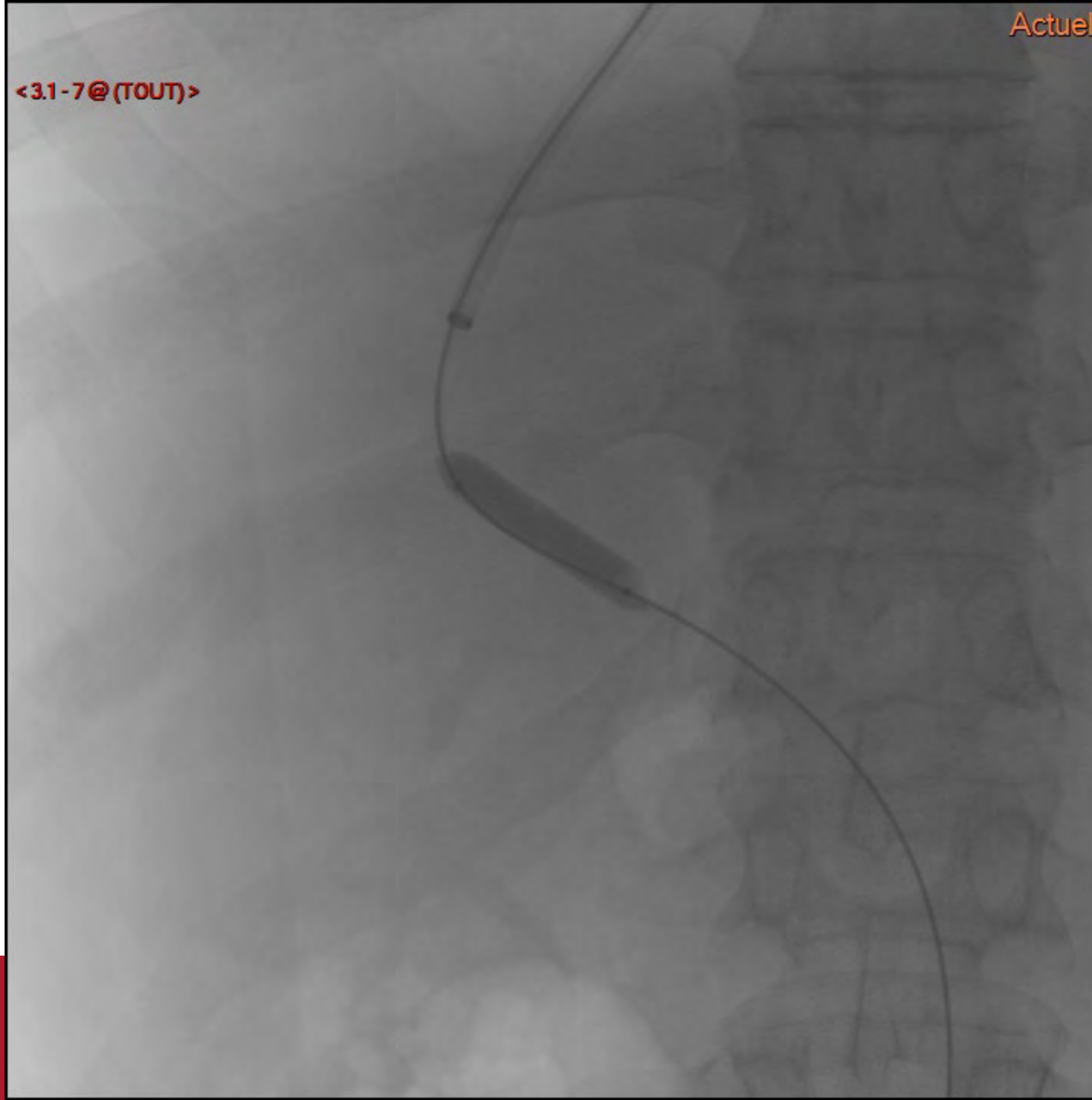
<3.1-5@ (TOUT)>



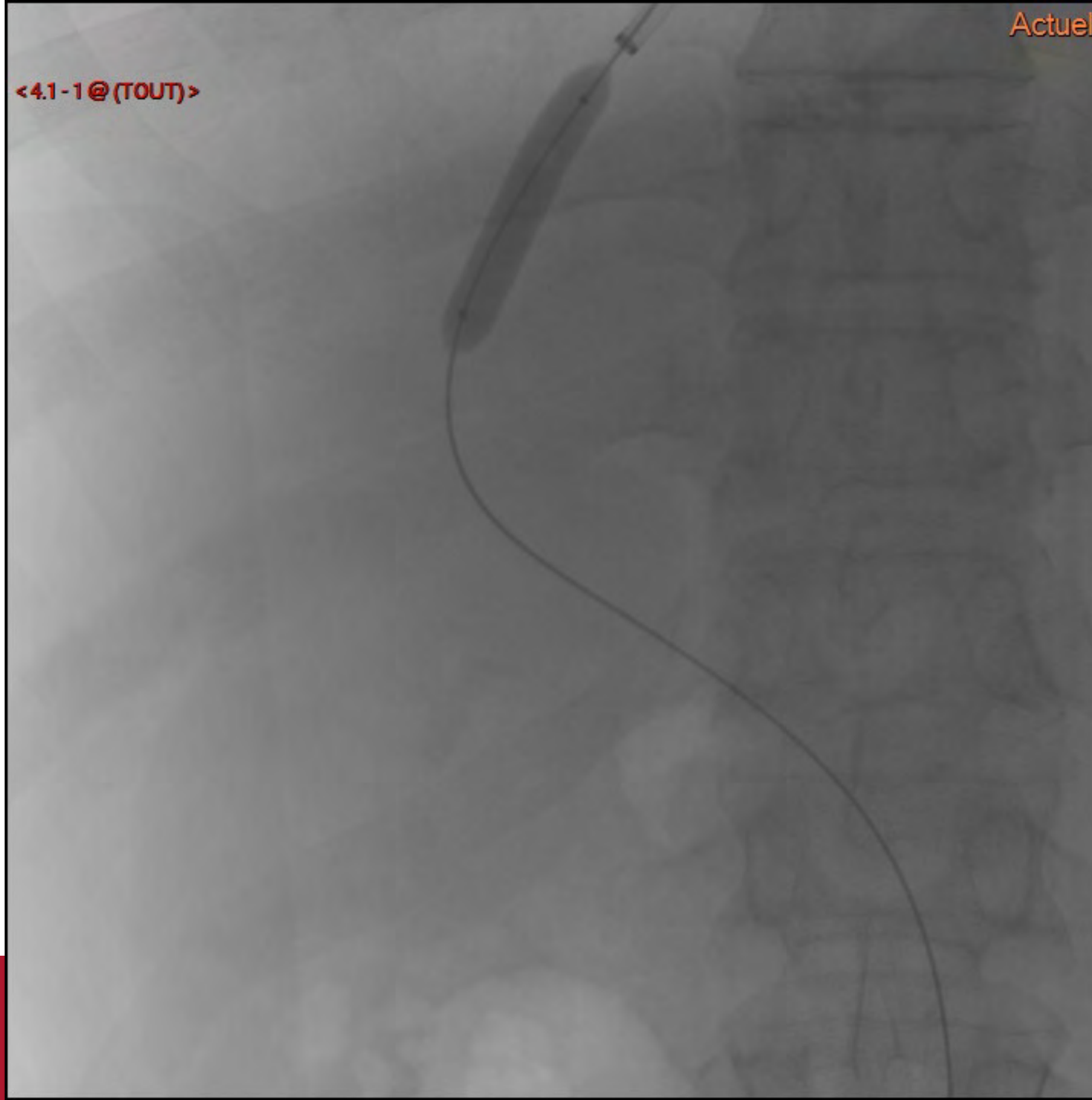
<3.1-6@ (TOU7)>



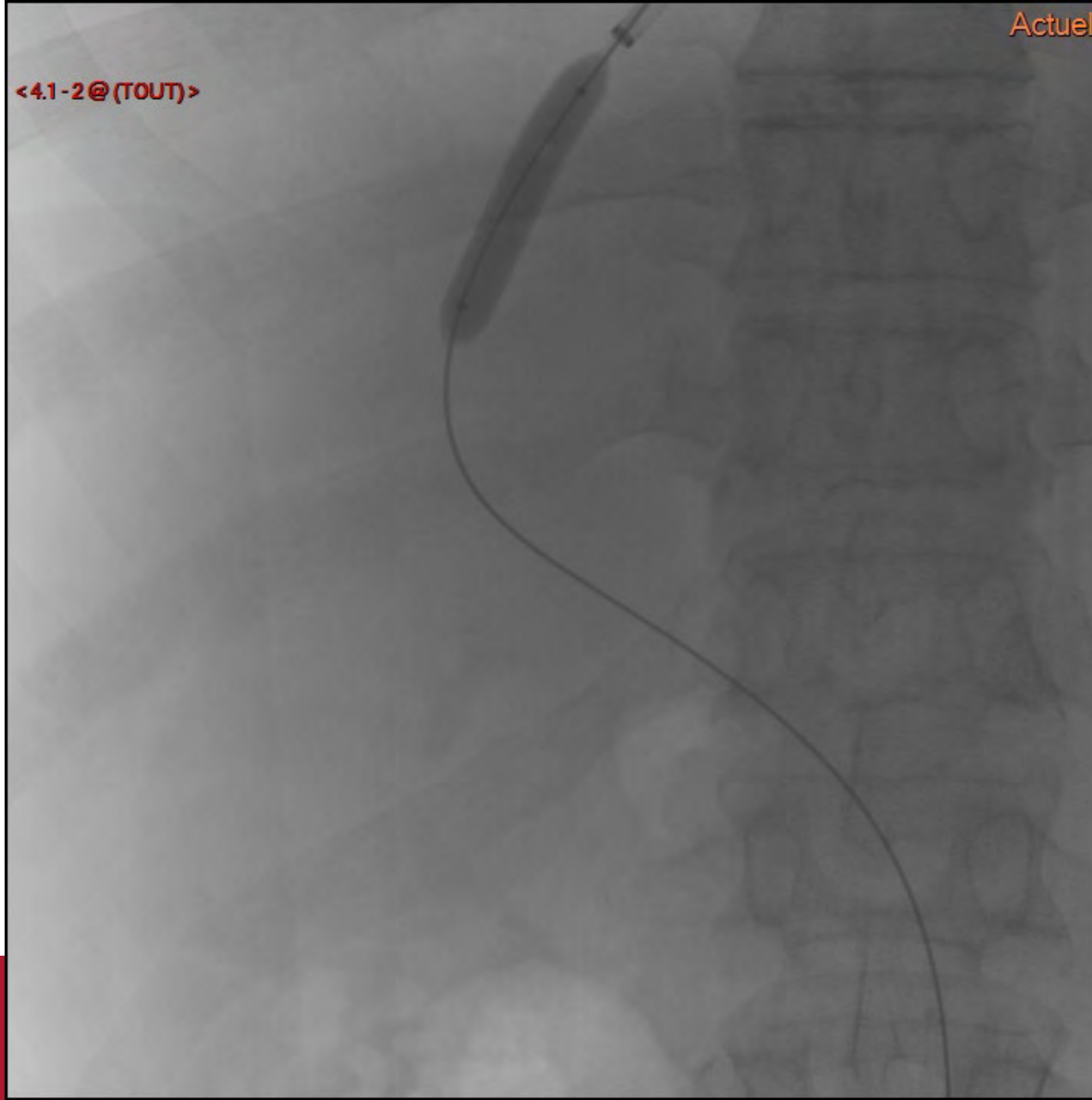
<3.1-7@ (TOUT)>



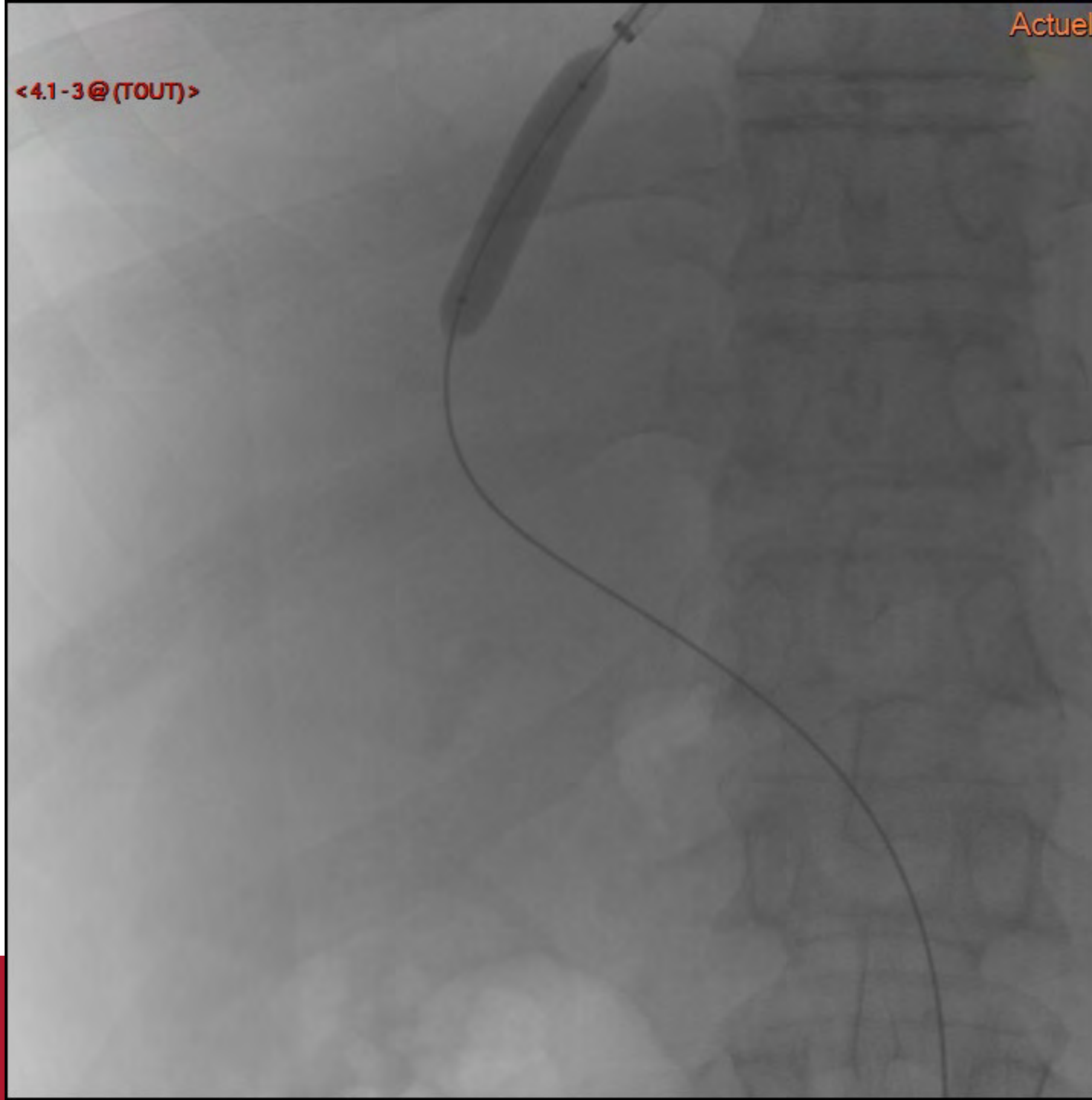
<4.1-1@(TOUT)>



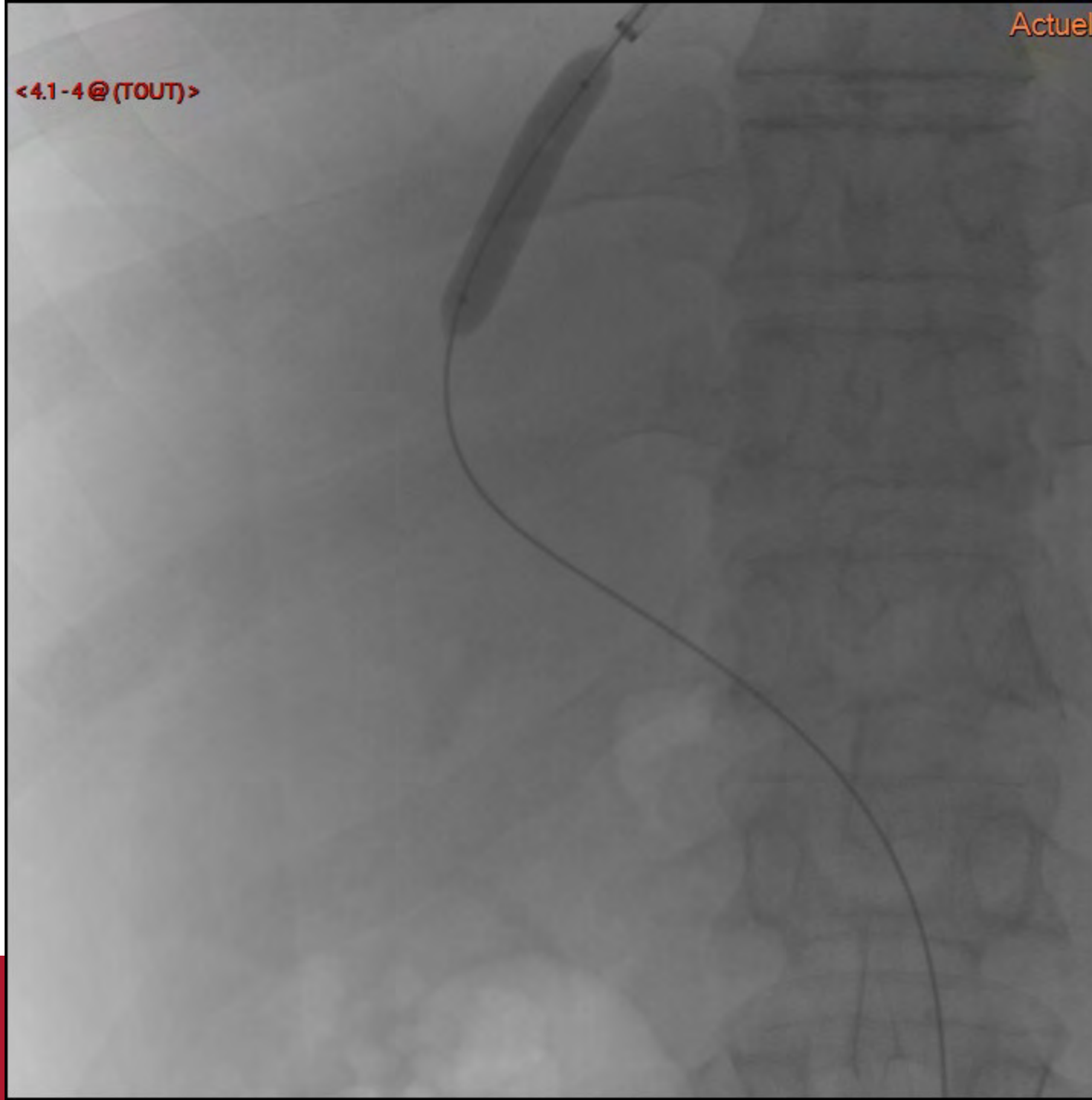
<4.1-2@ (TOUT)>



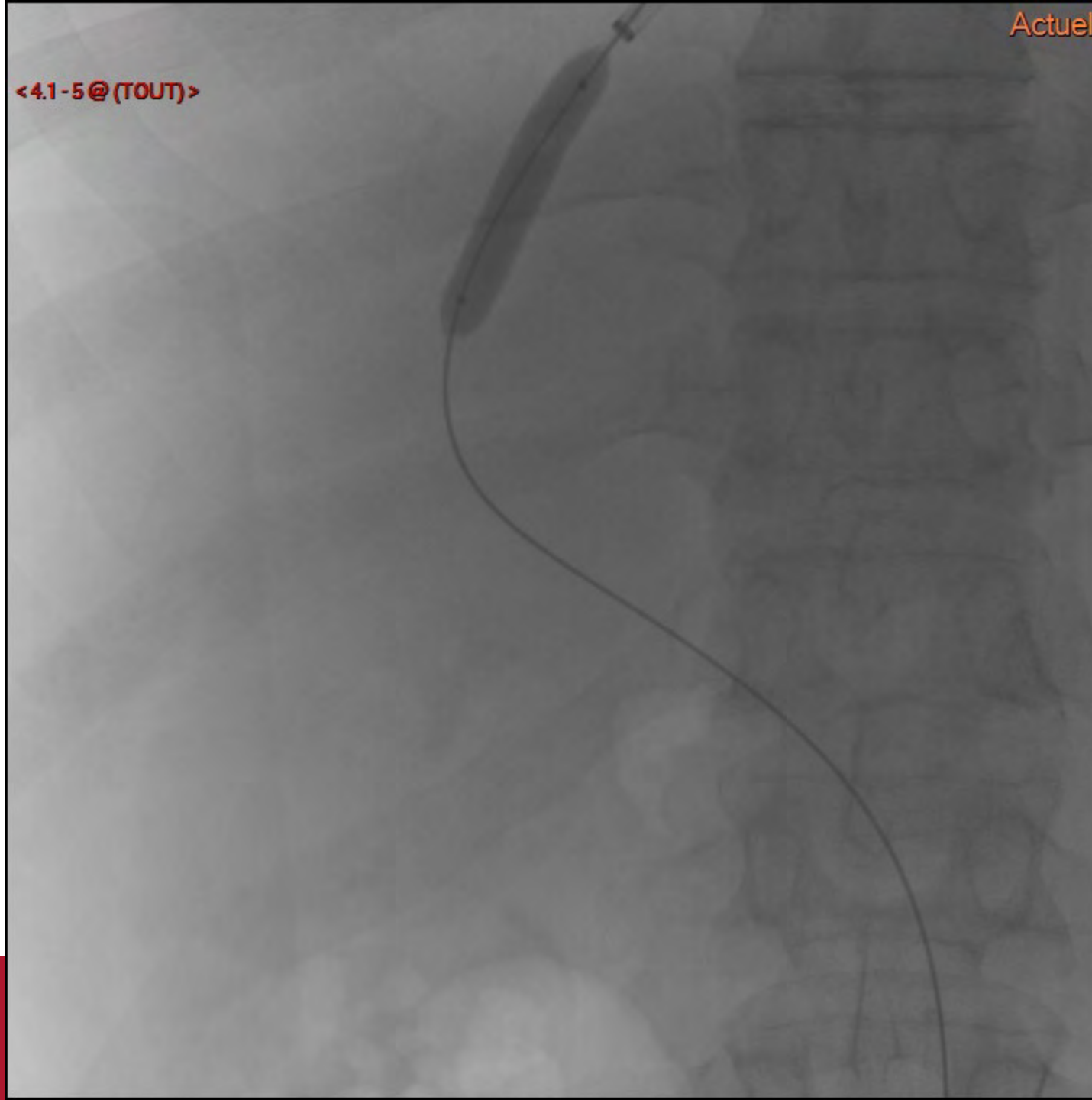
<4.1-3@ (TOU7)>



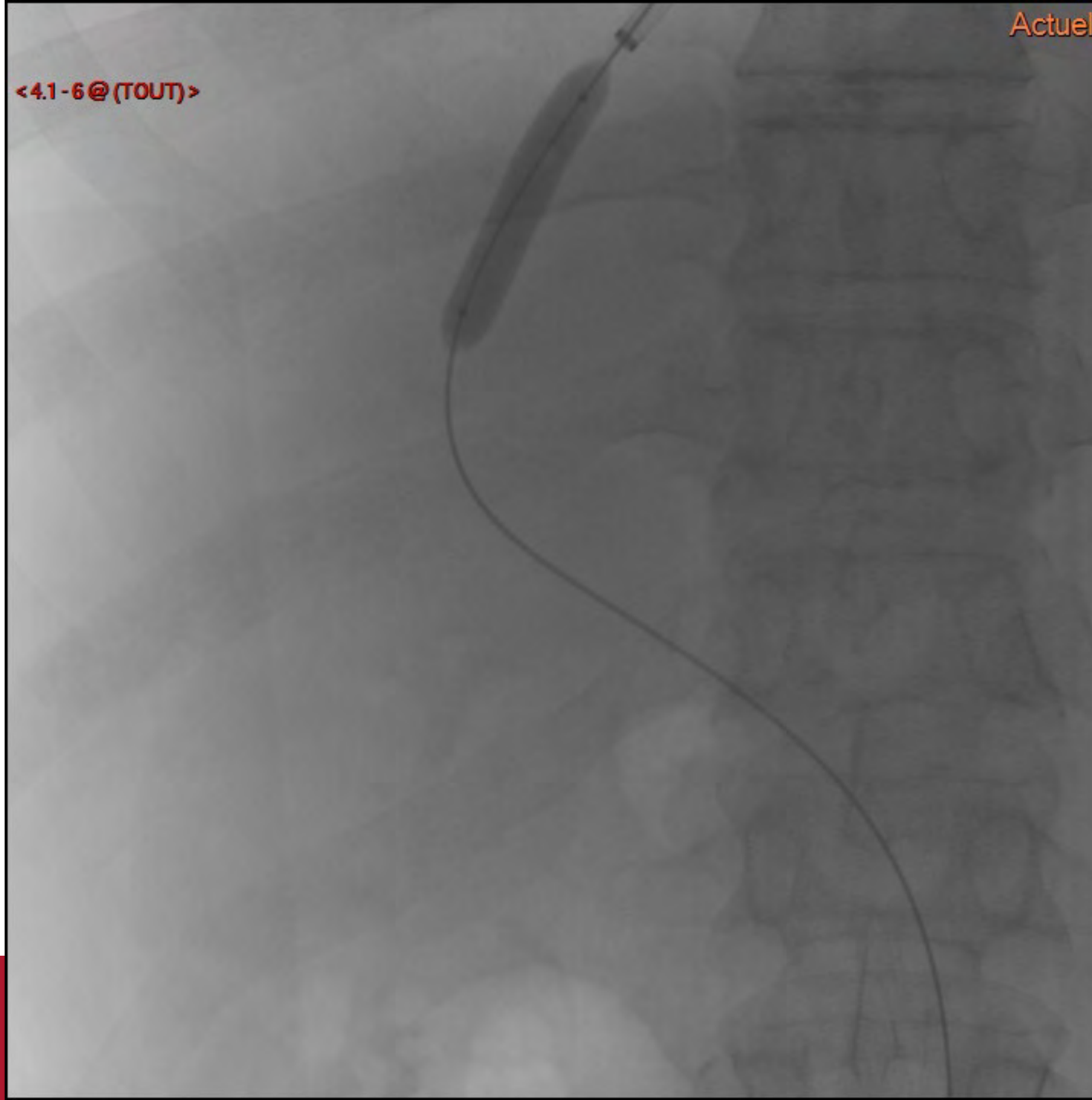
<4.1-4@ (TOUT)>



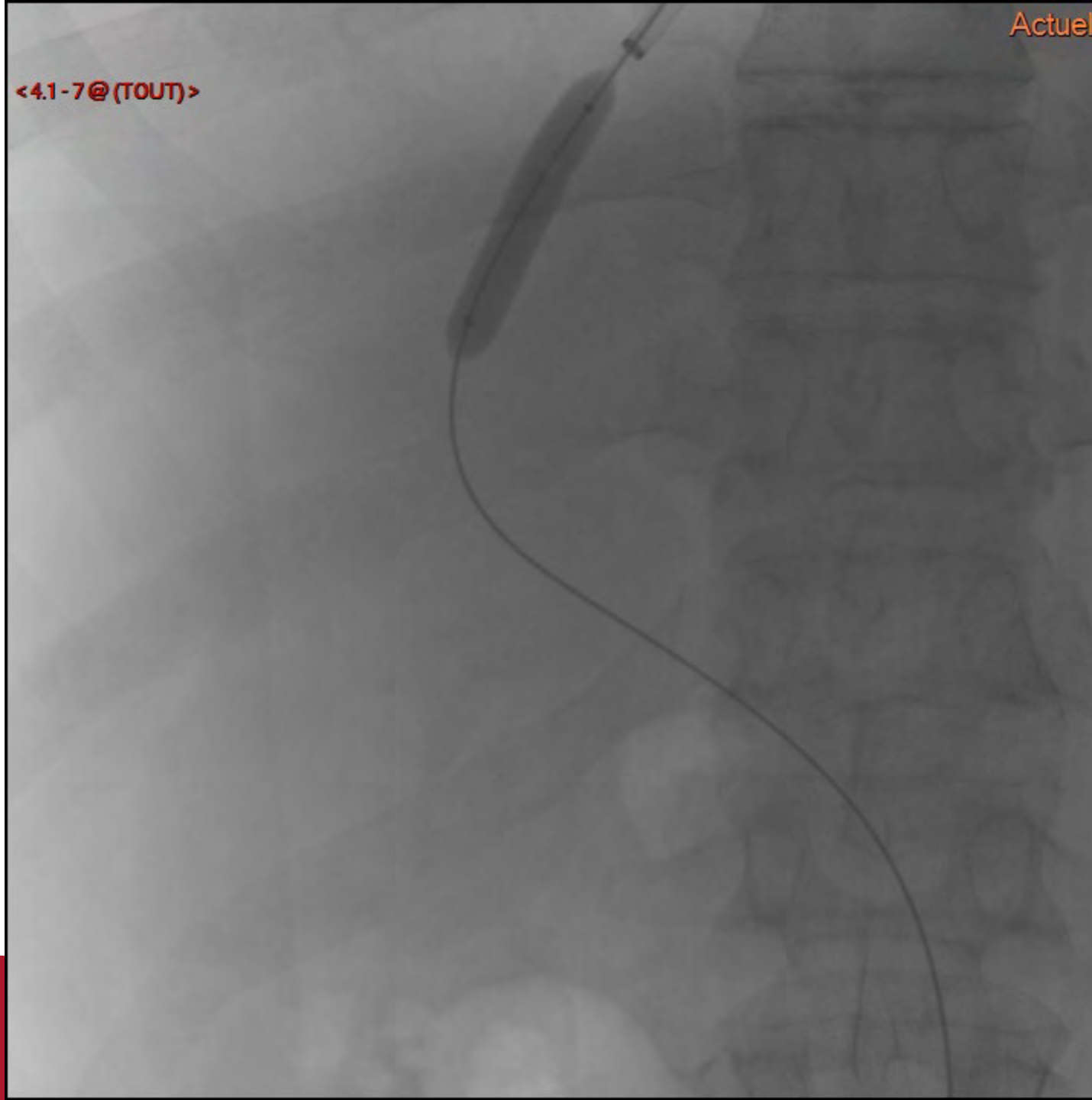
<4.1-5@ (TOUT)>



<4.1-6@ (TOUT)>

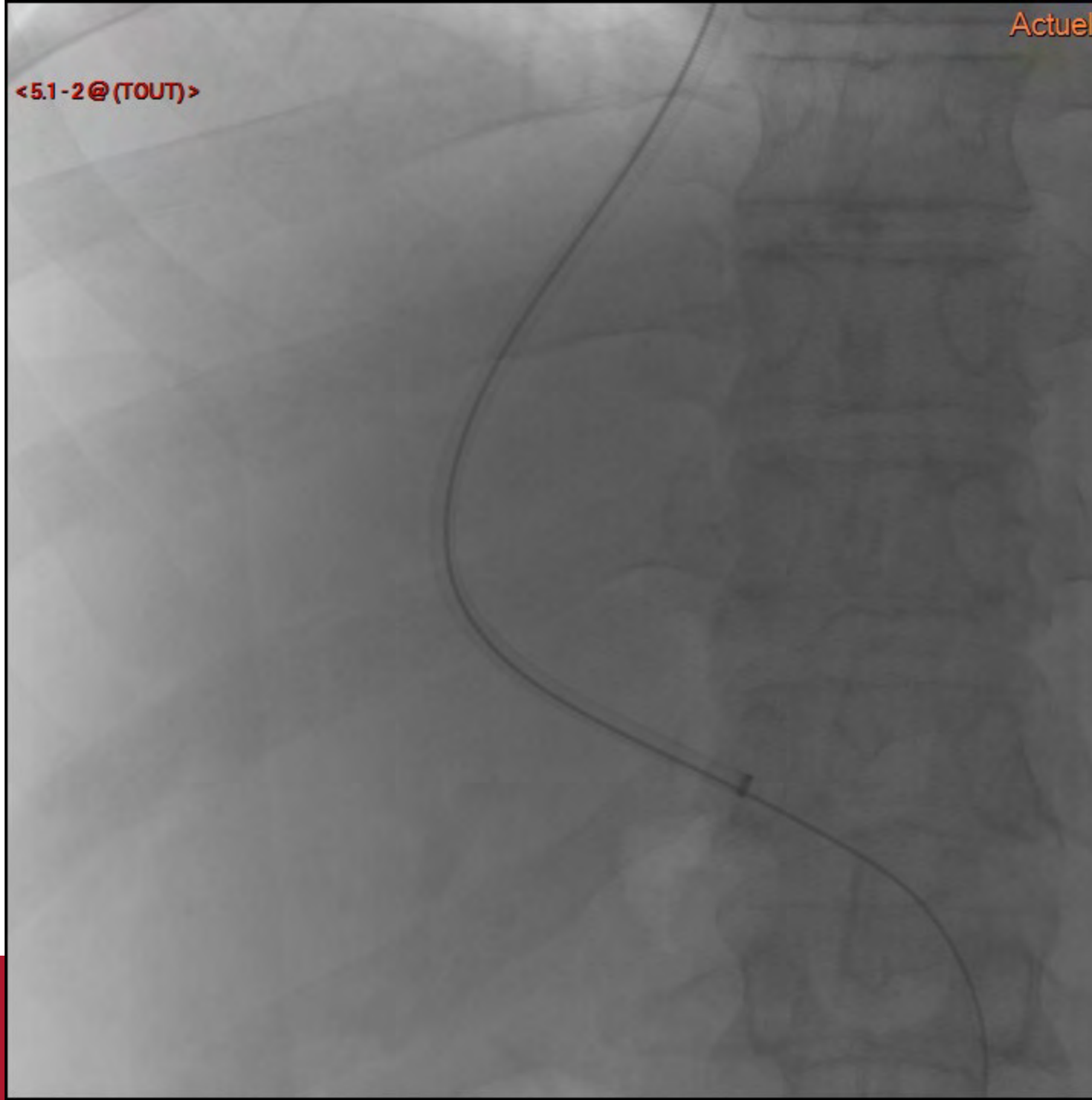


<4.1-7@ (TOUT)>

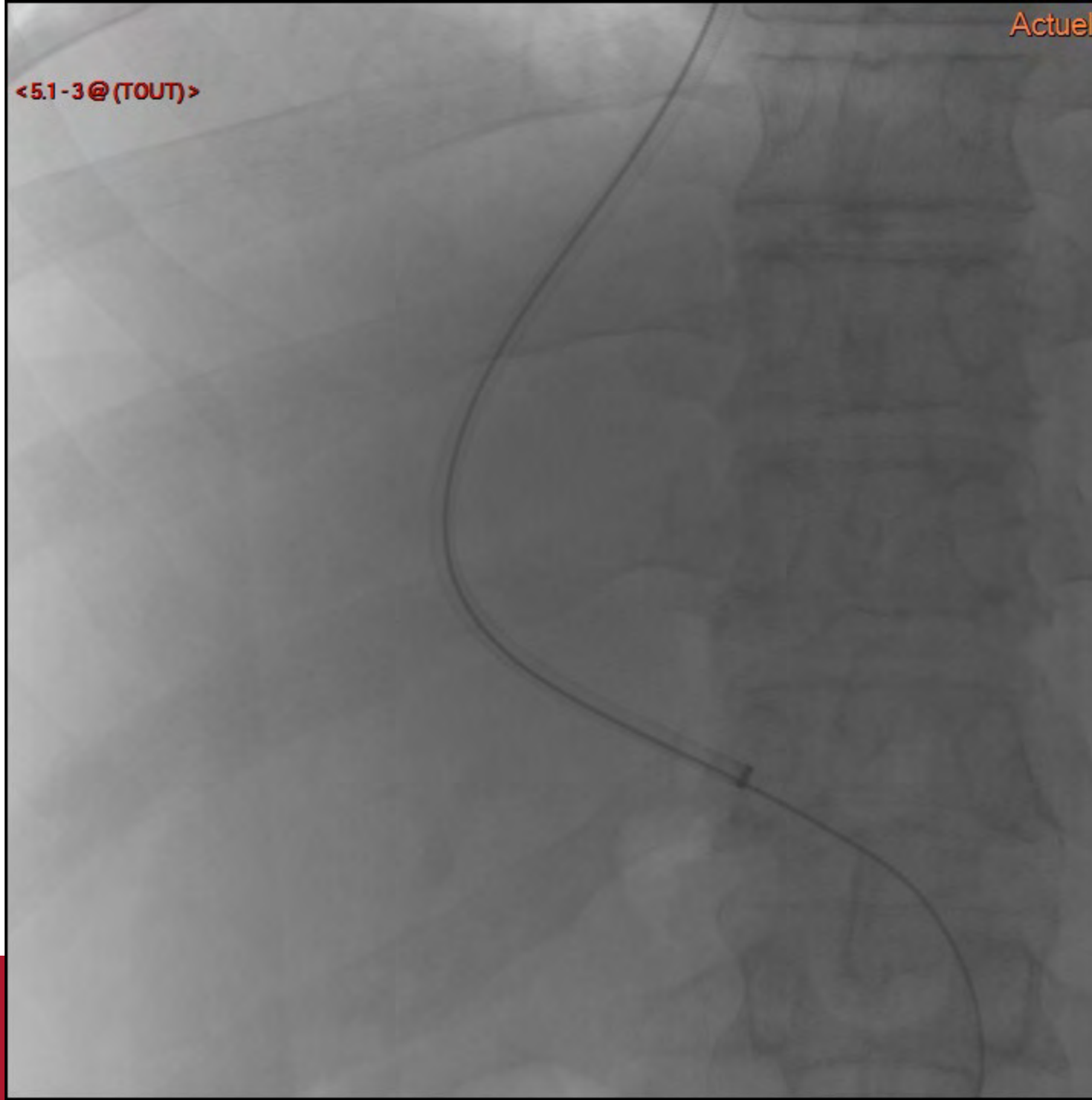


<5.1-1@TOUT>

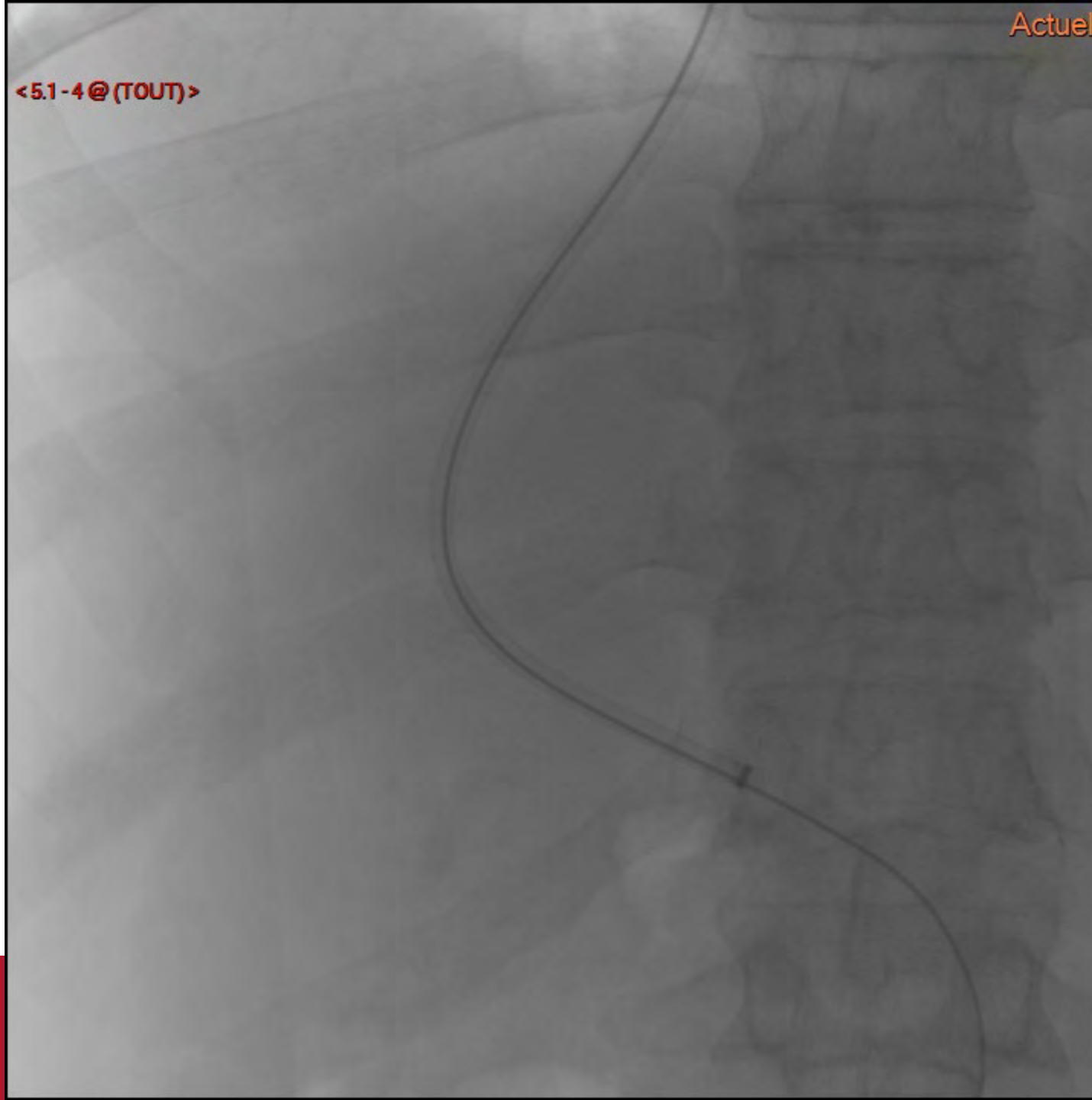
<5.1-2@ (TOUT)>



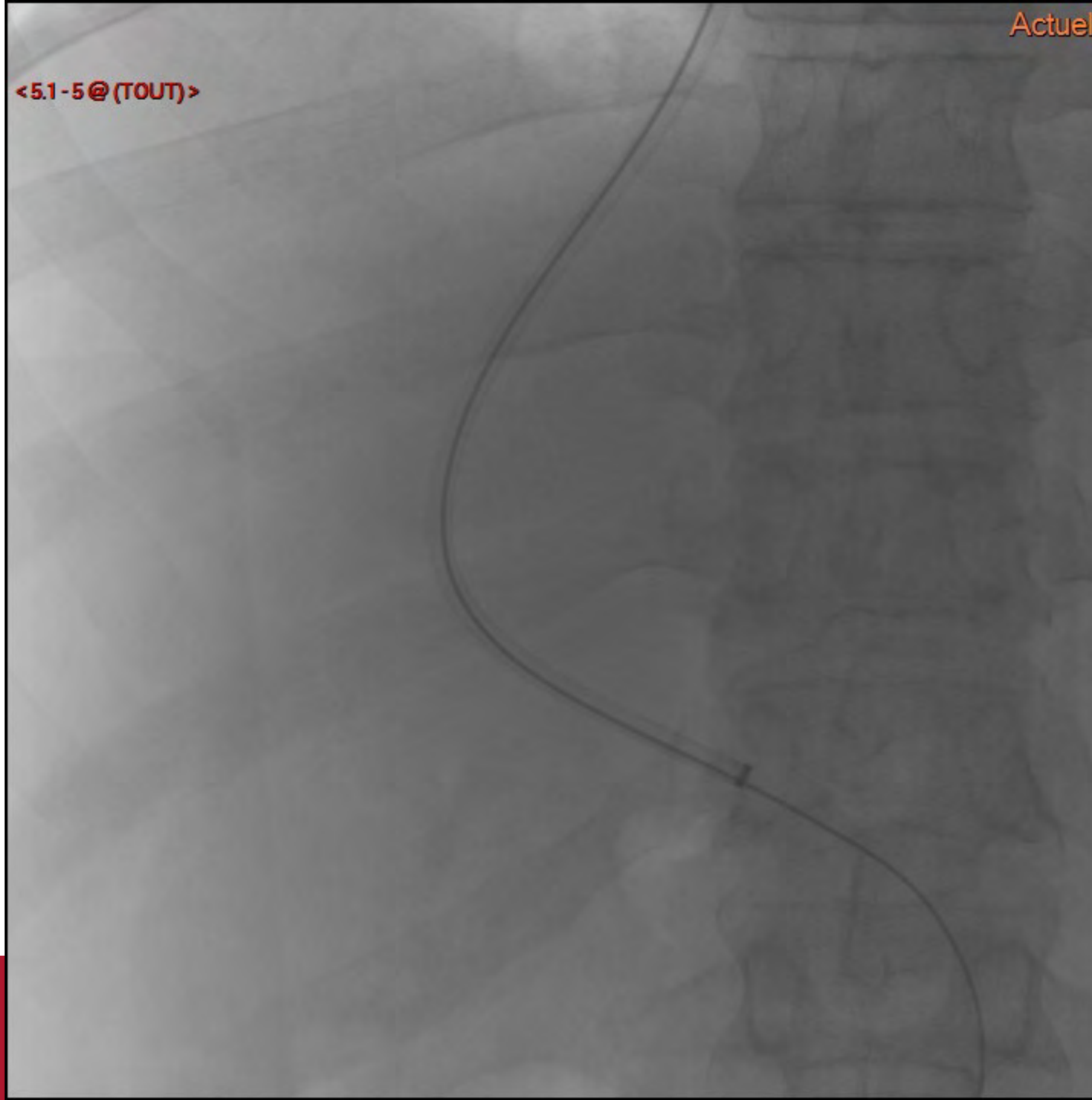
<5.1-3@TOU>



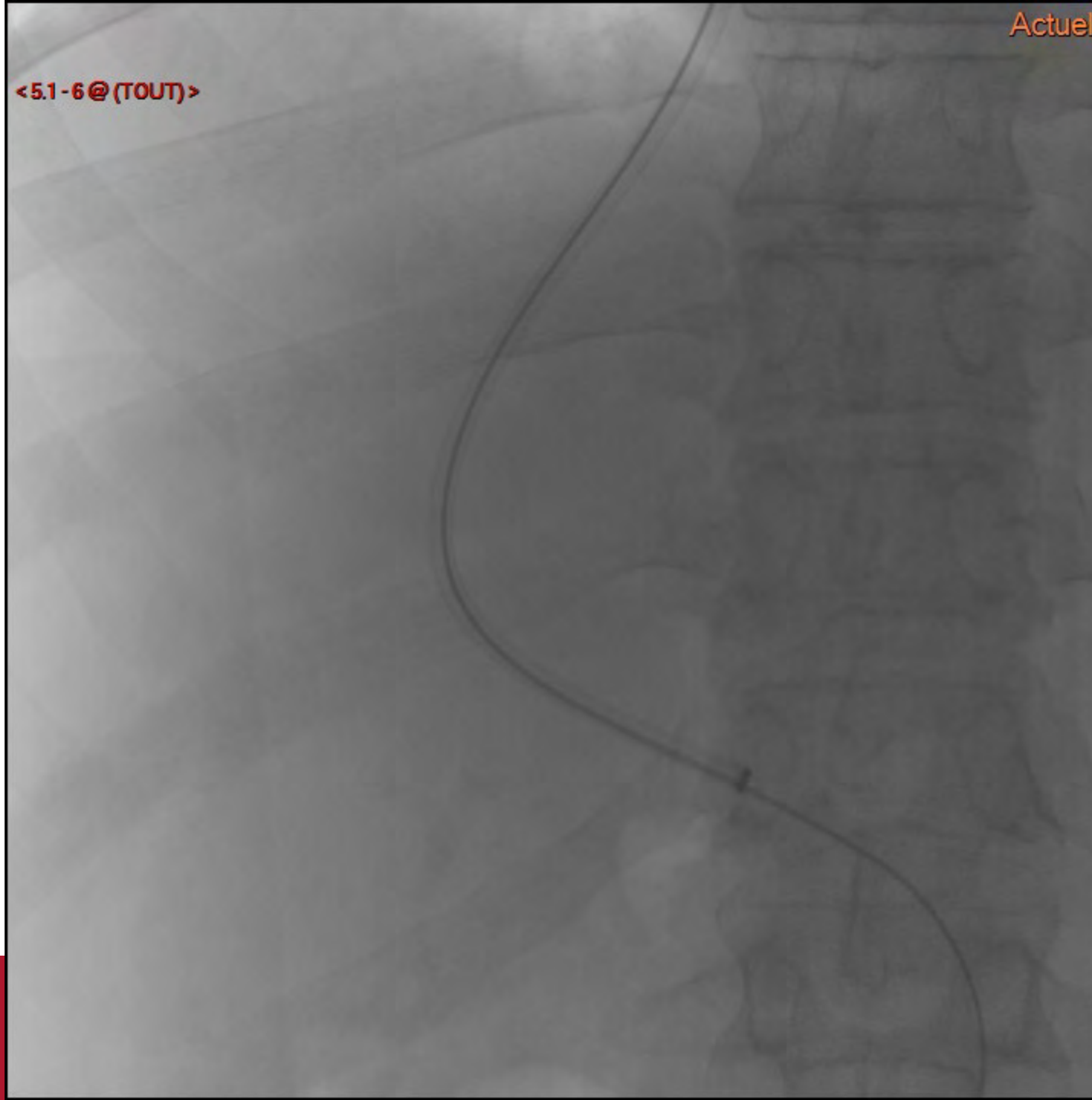
<5.1-4@TOUT>



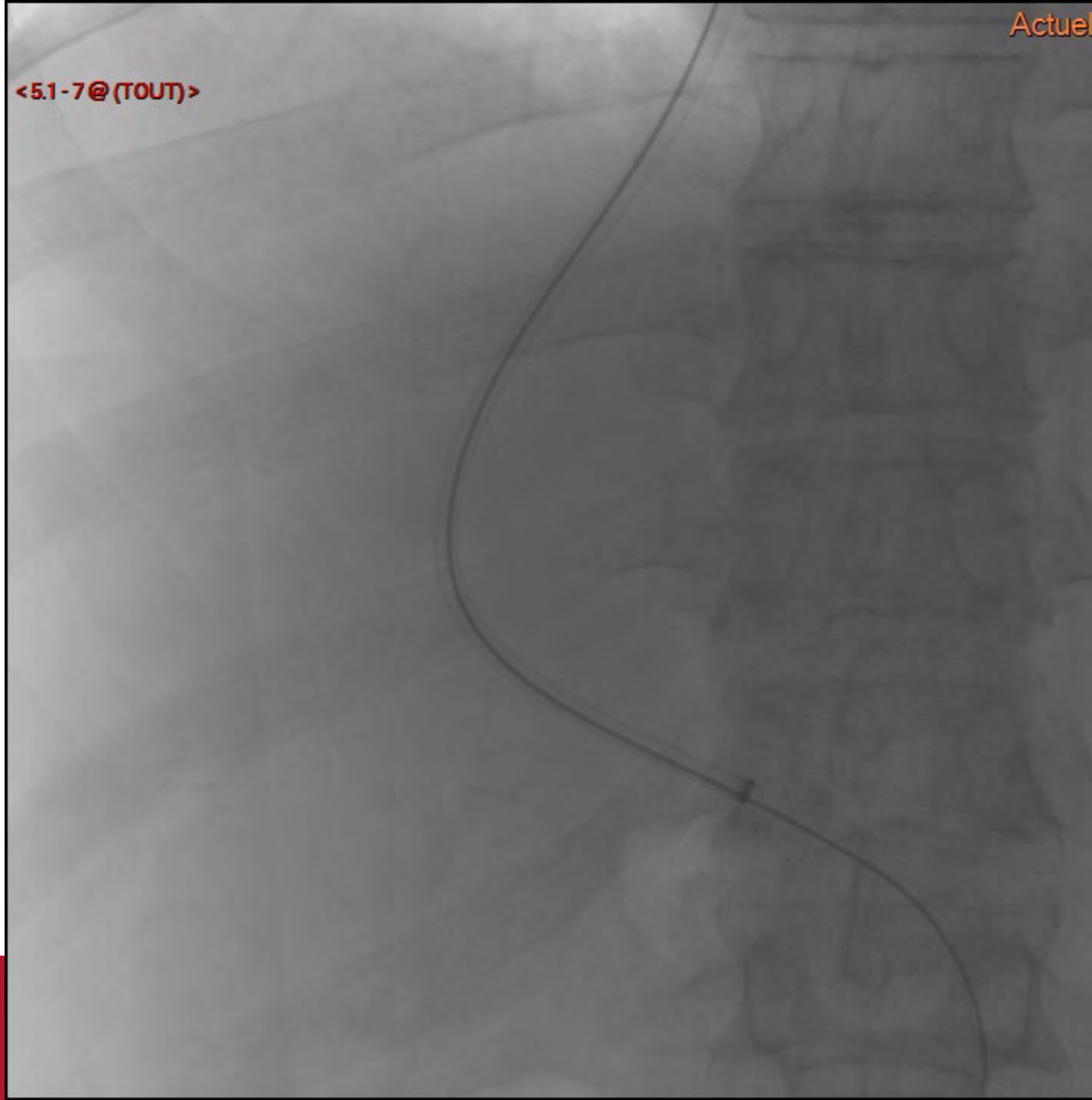
<5.1-5@TOUT>



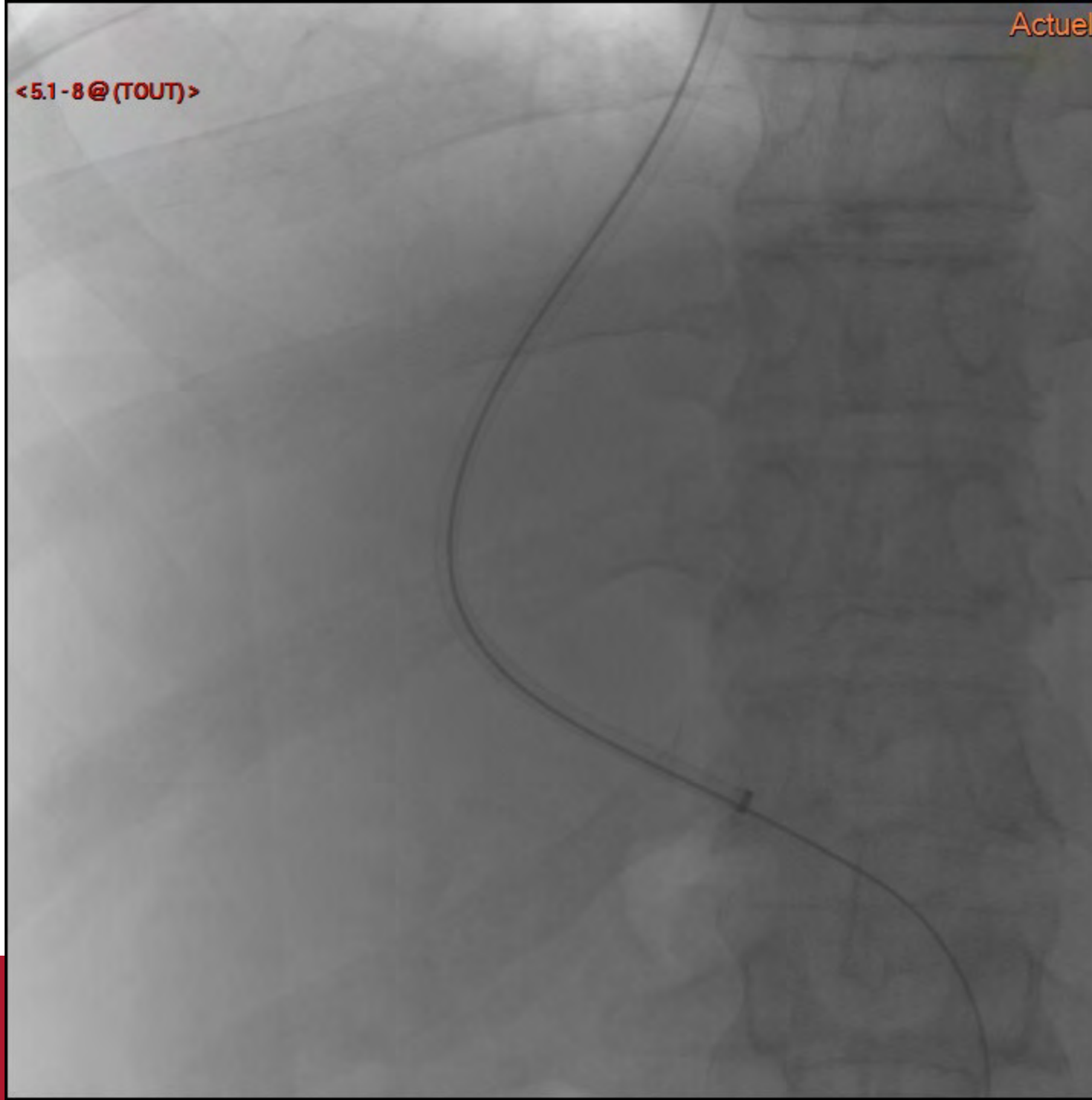
<5.1-6@TOUT>



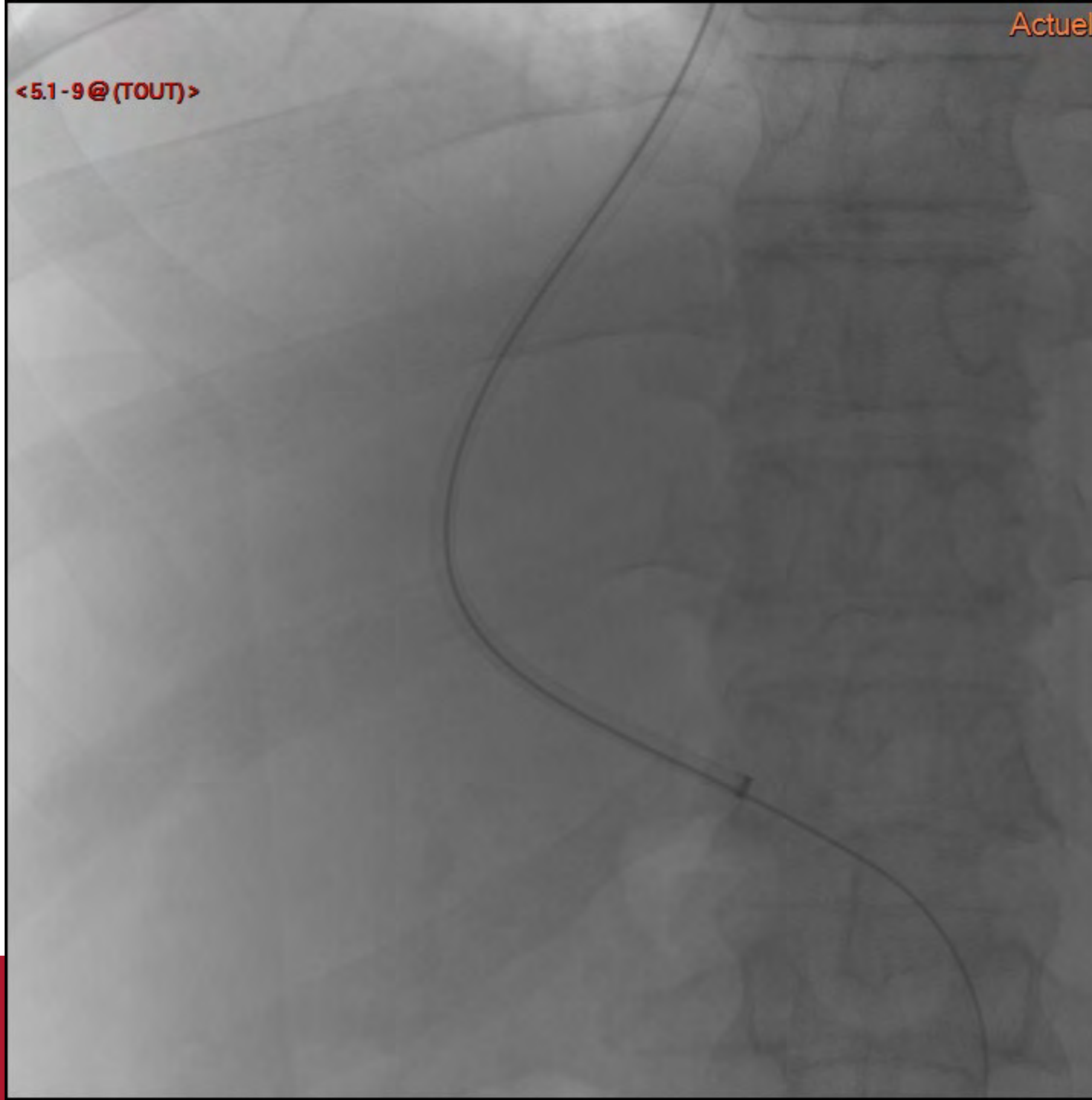
<5.1-7@TOUT>



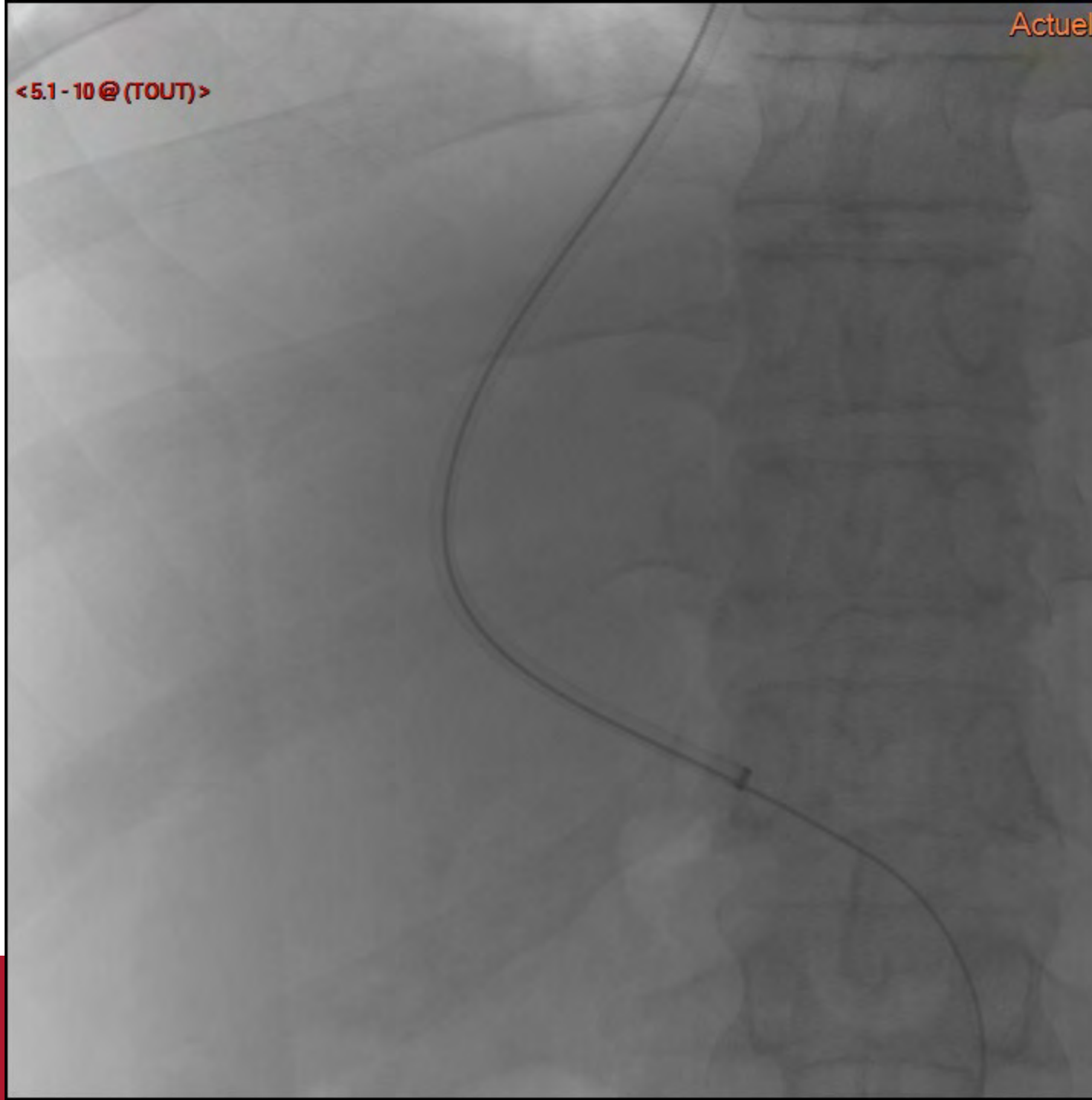
<5.1-8@TOUT>



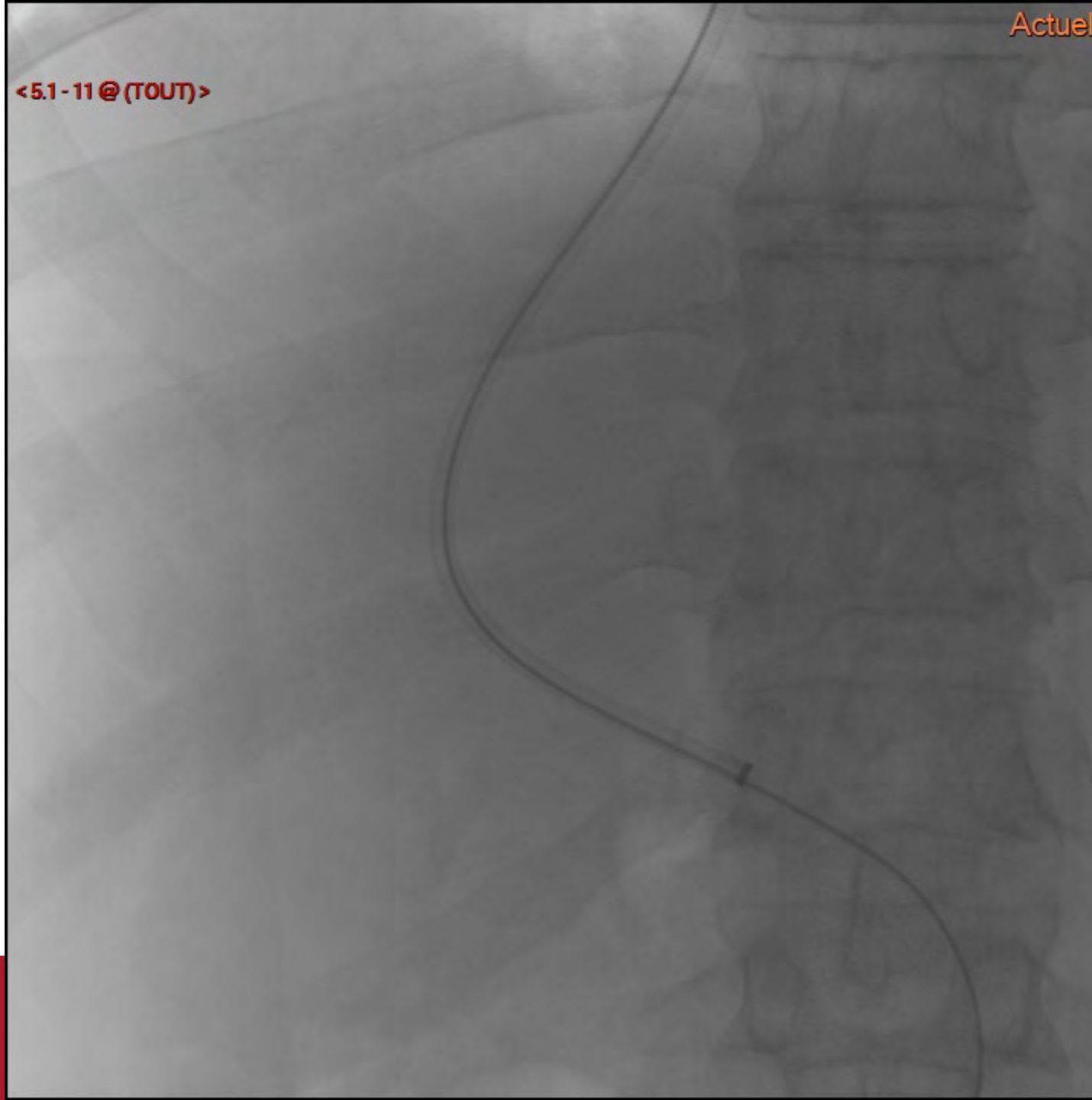
<5.1-9@TOUT>



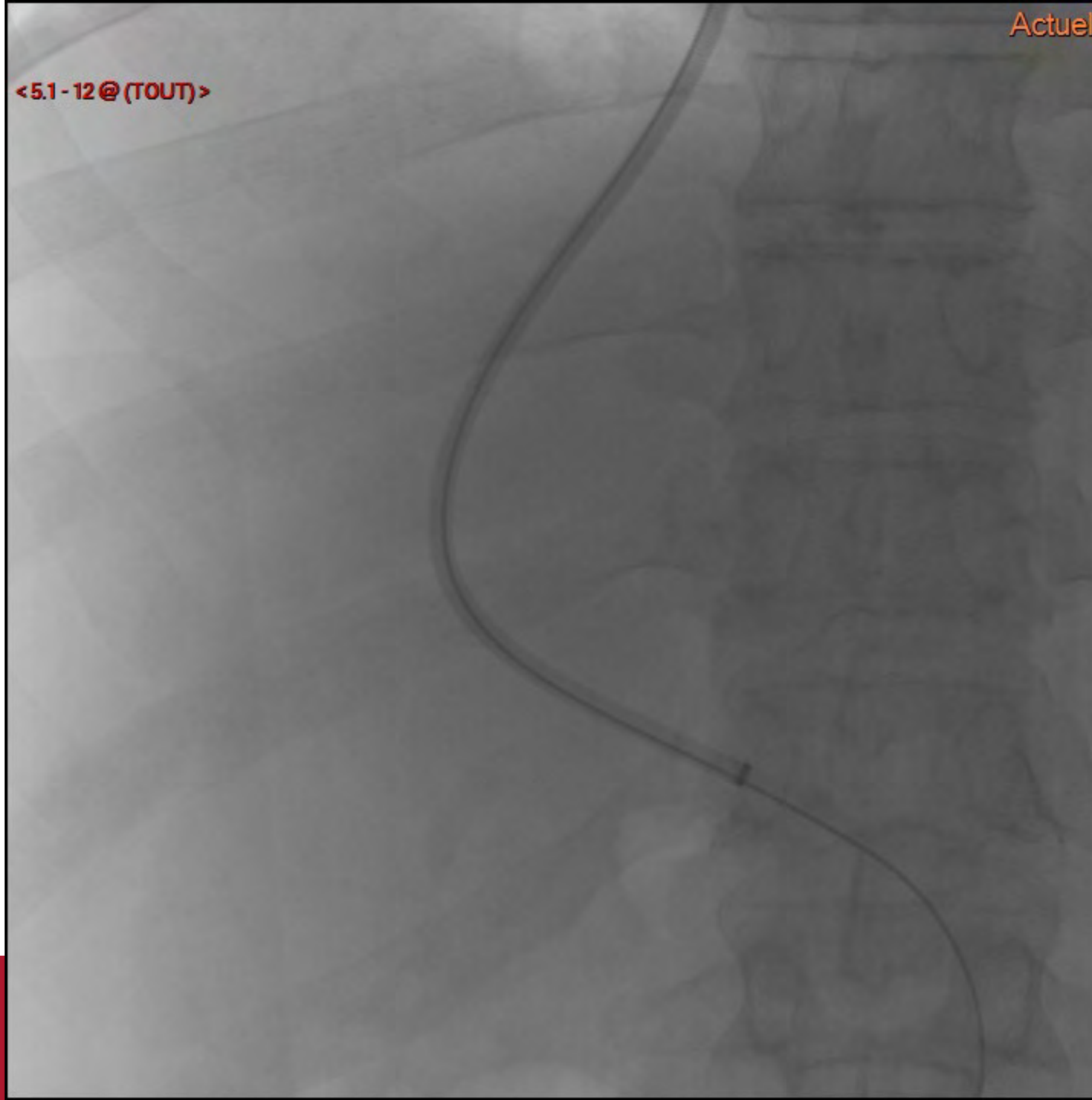
<5.1-10@ (TOUT)>



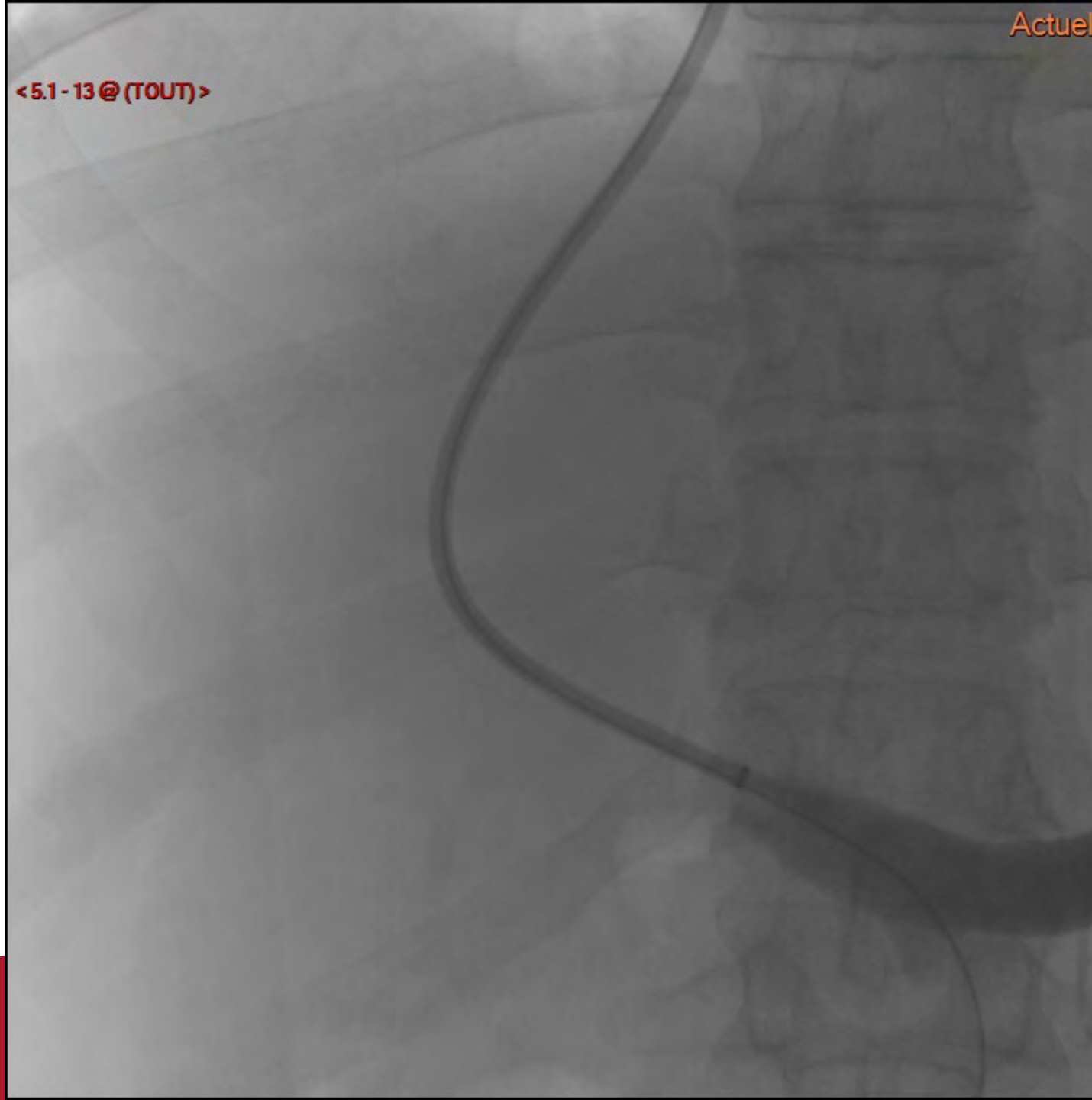
<5.1-11 @ (TOUT)>



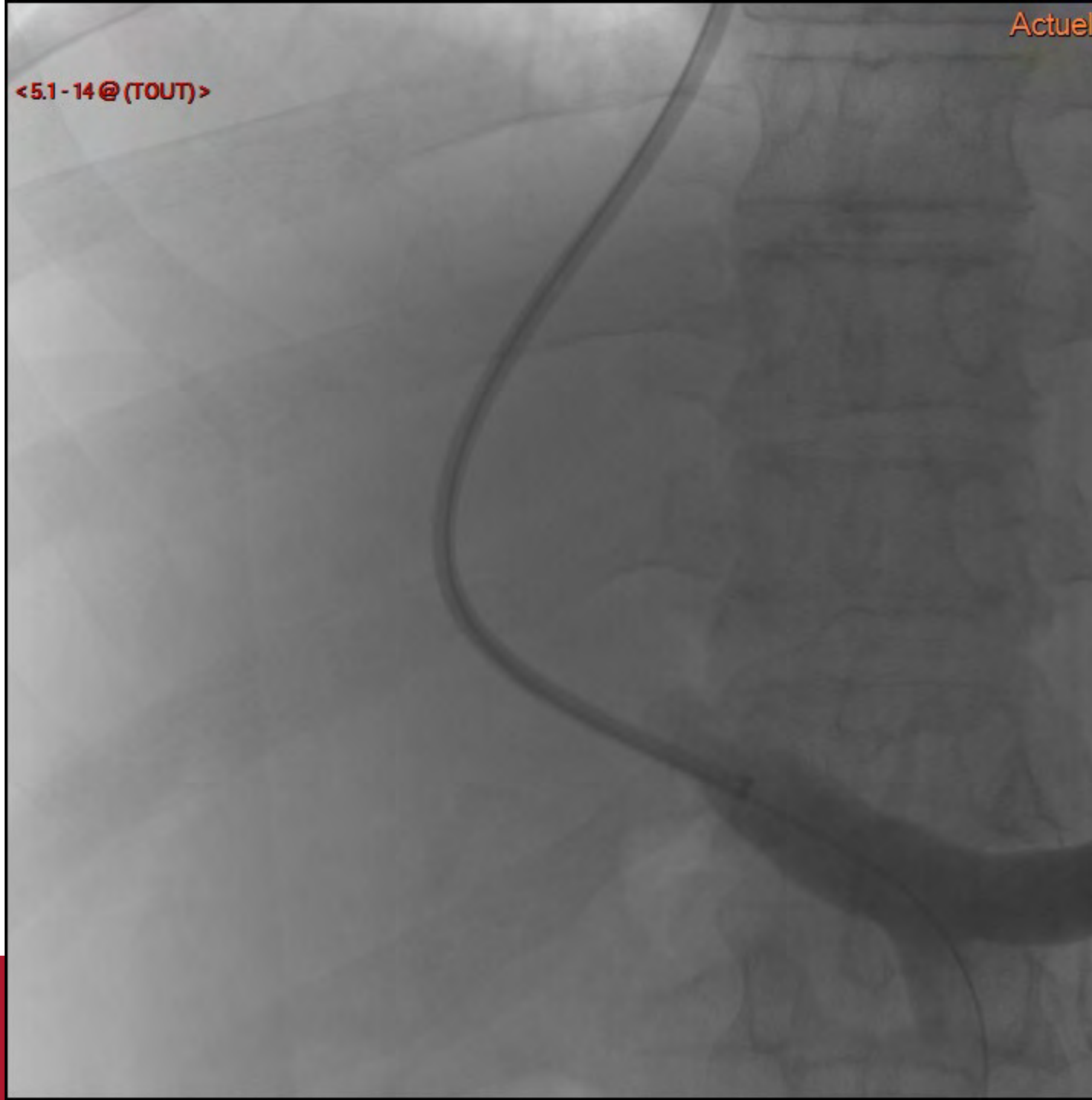
<5.1-12@ (TOUT)>



<5.1-13@TOUT>



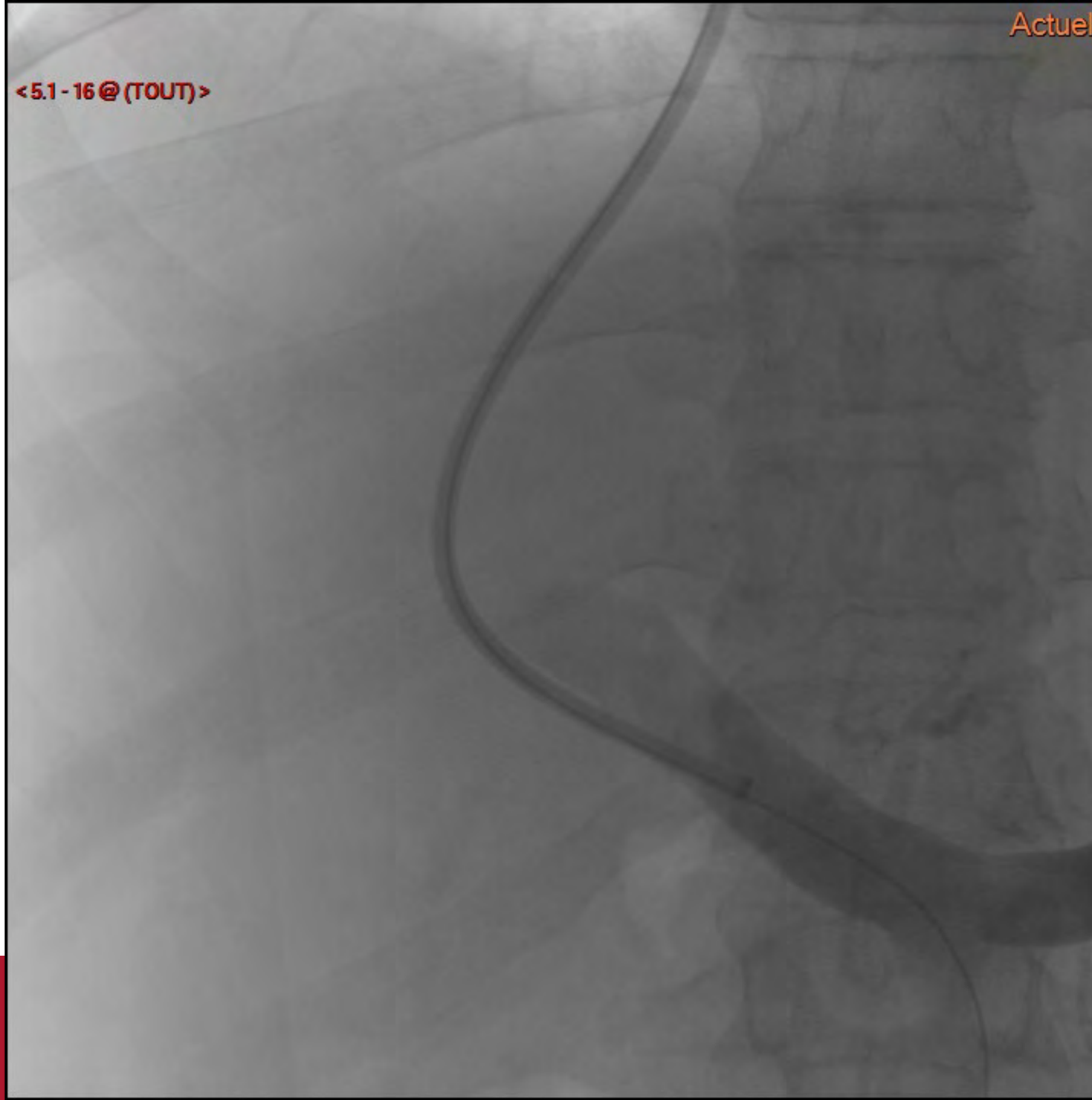
<5.1-14@ (TOUT)>



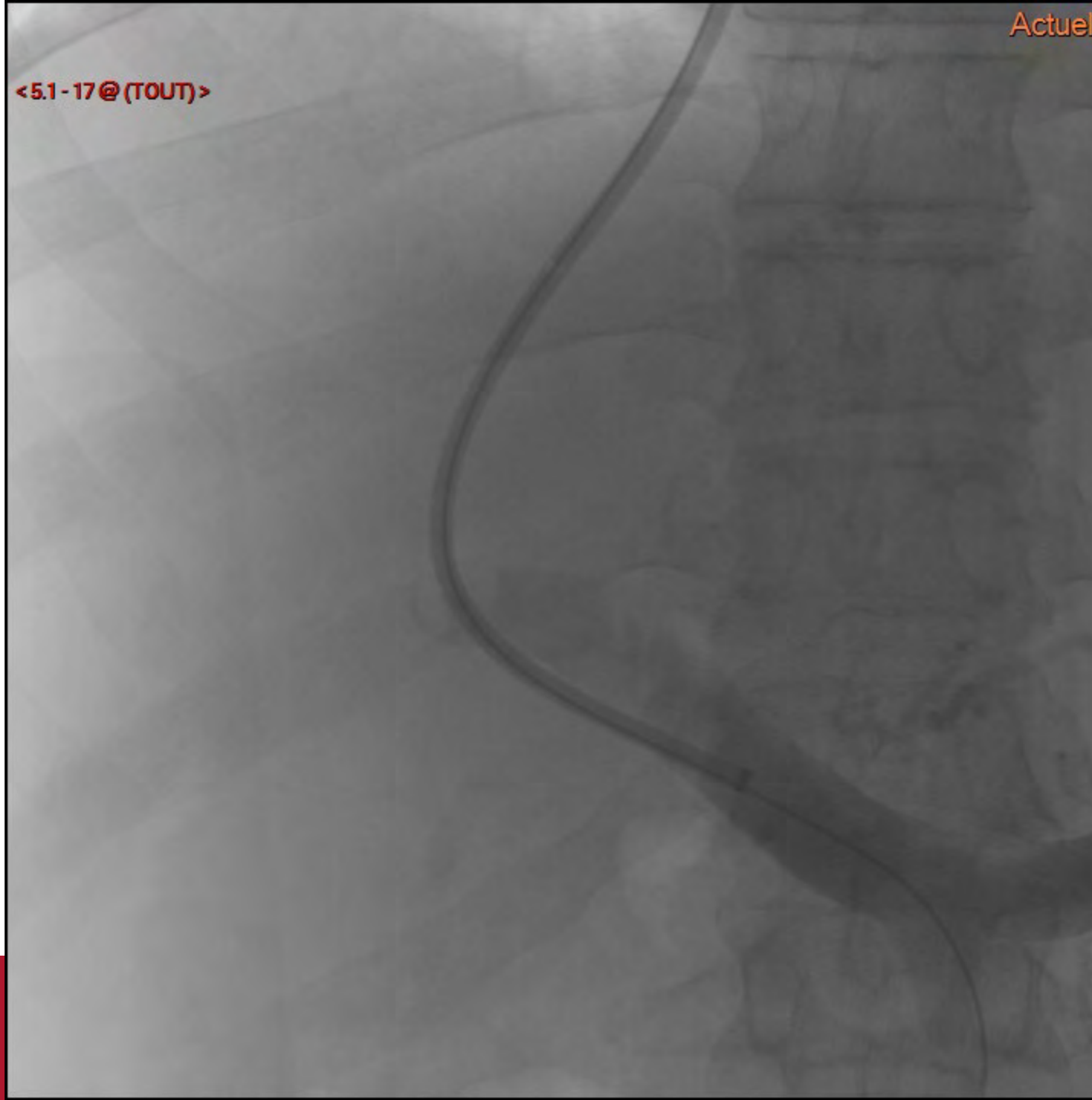
< 5.1 - 15 @ (TOUT) >

Portographie: flux hépatofuge

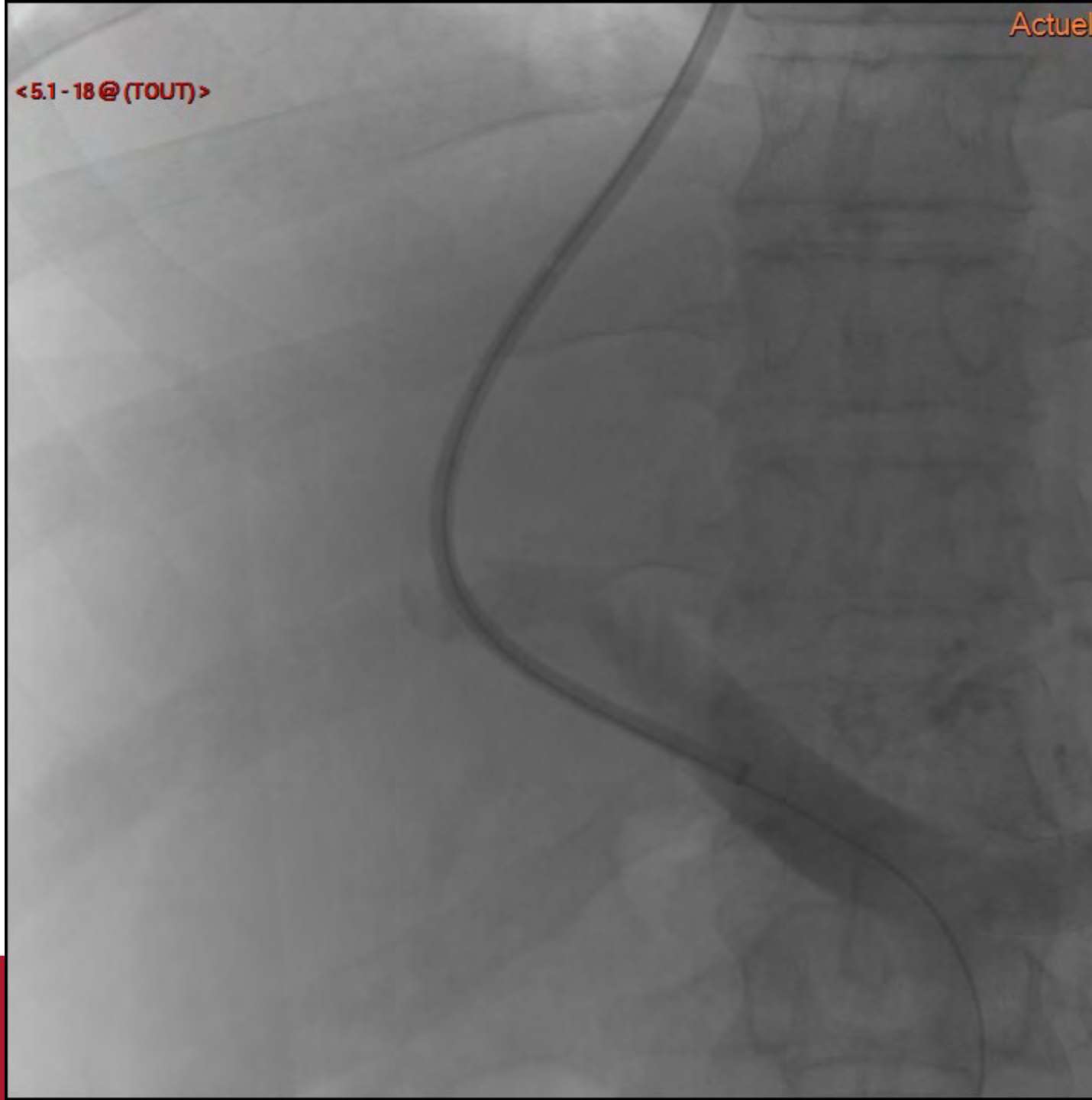
<5.1-16@ (TOUT)>



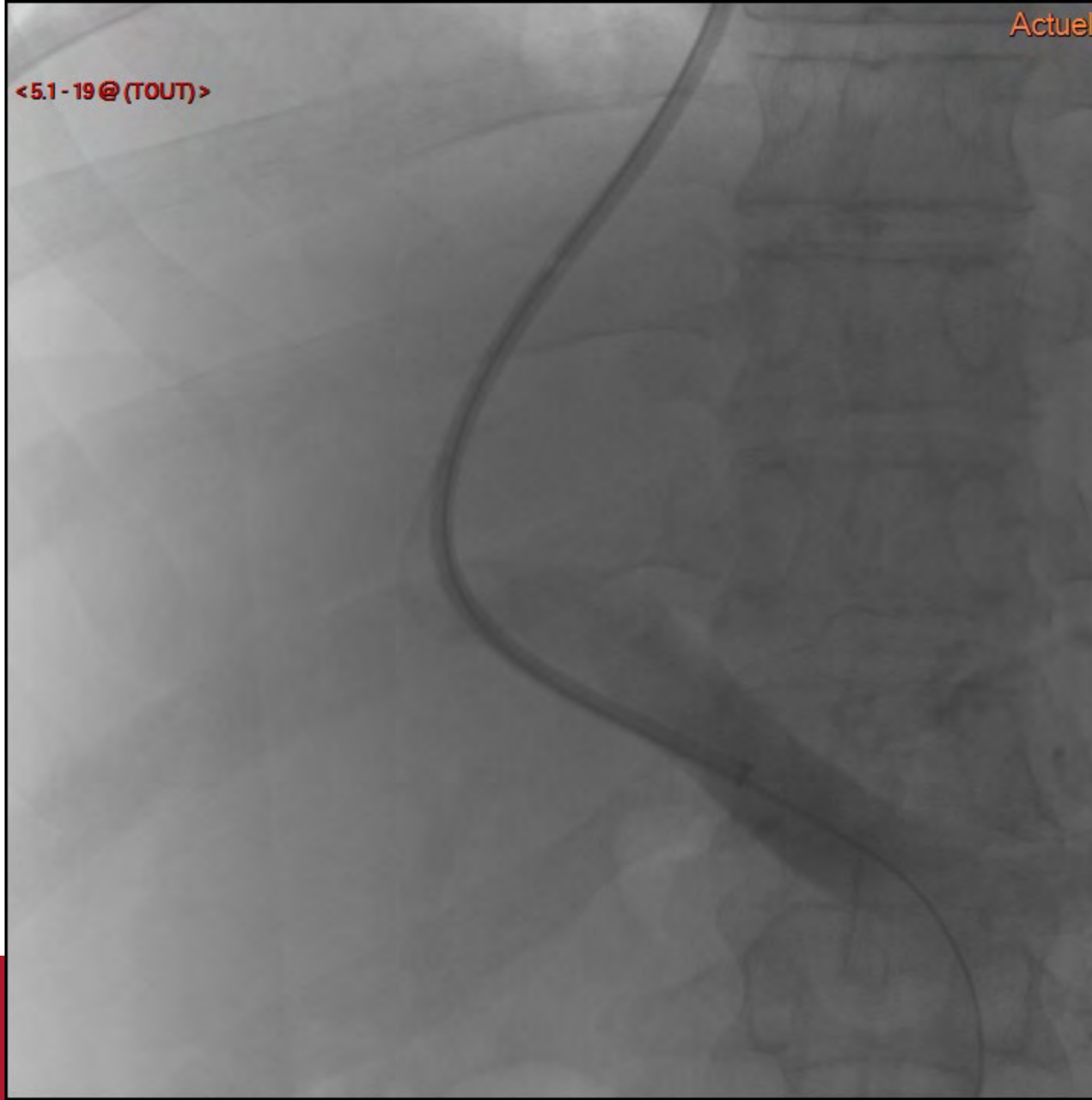
<5.1-17@TOUT>



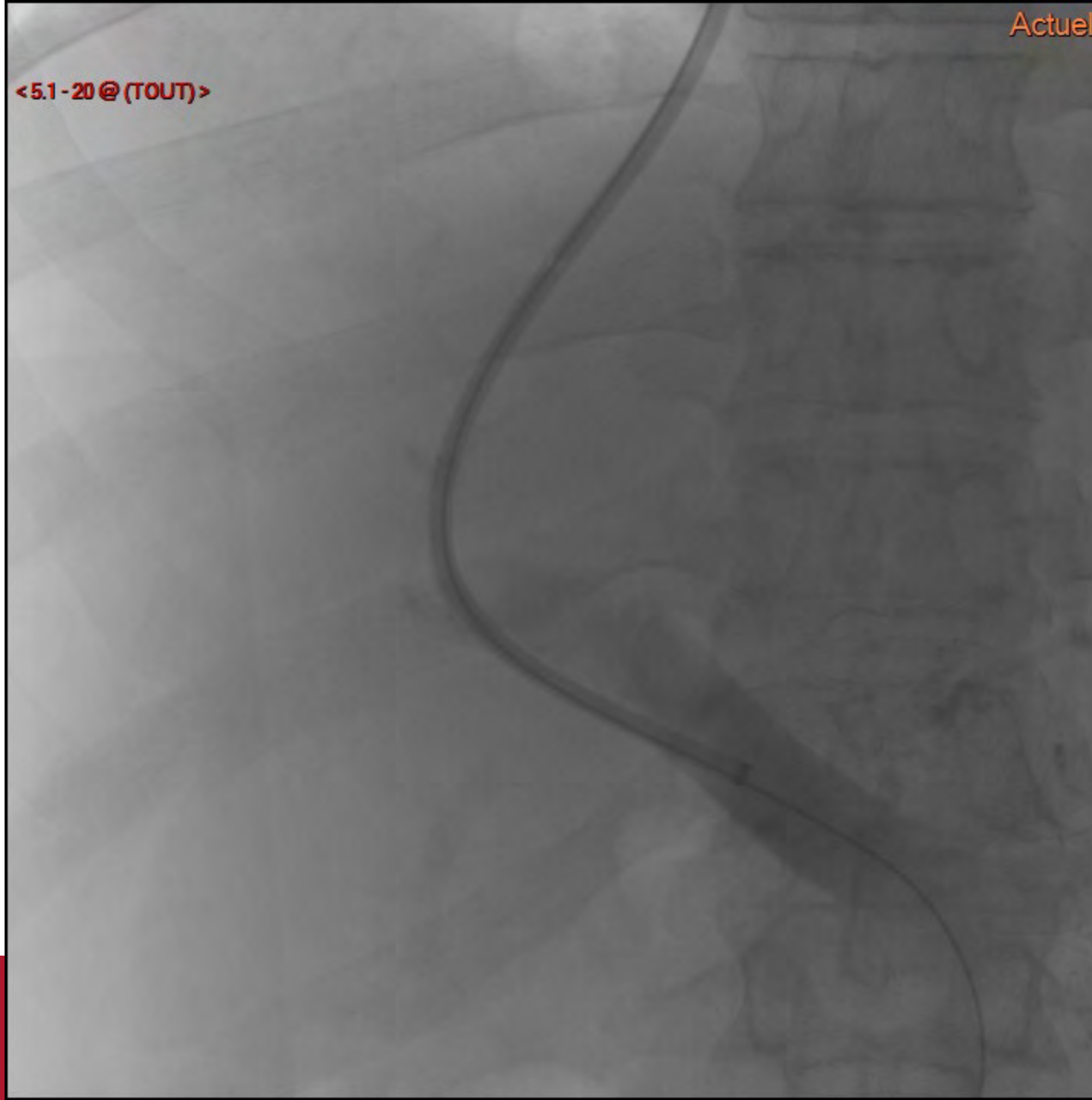
<5.1-18@ (TOUT)>



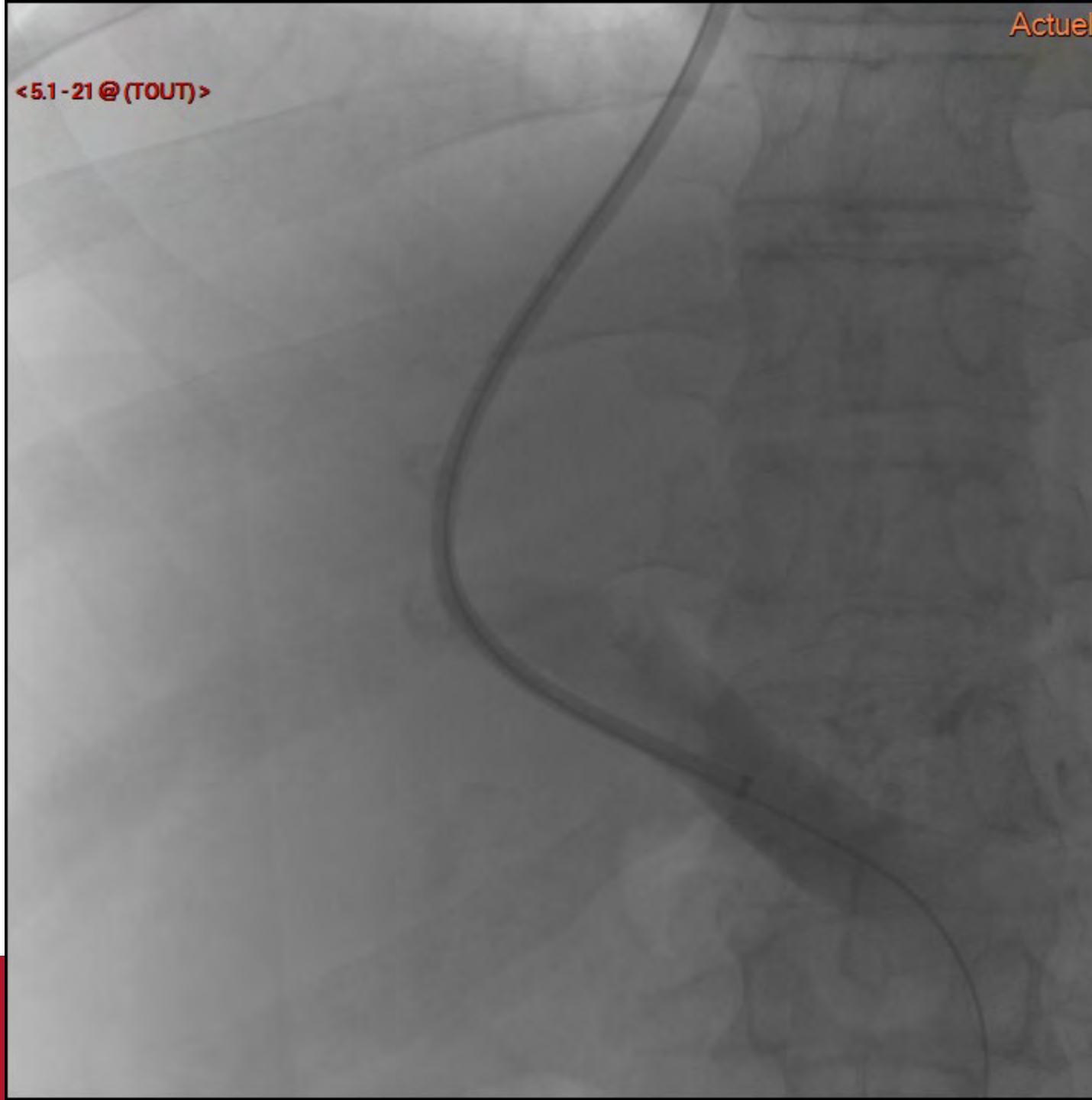
<5.1-19@ (TOUT)>



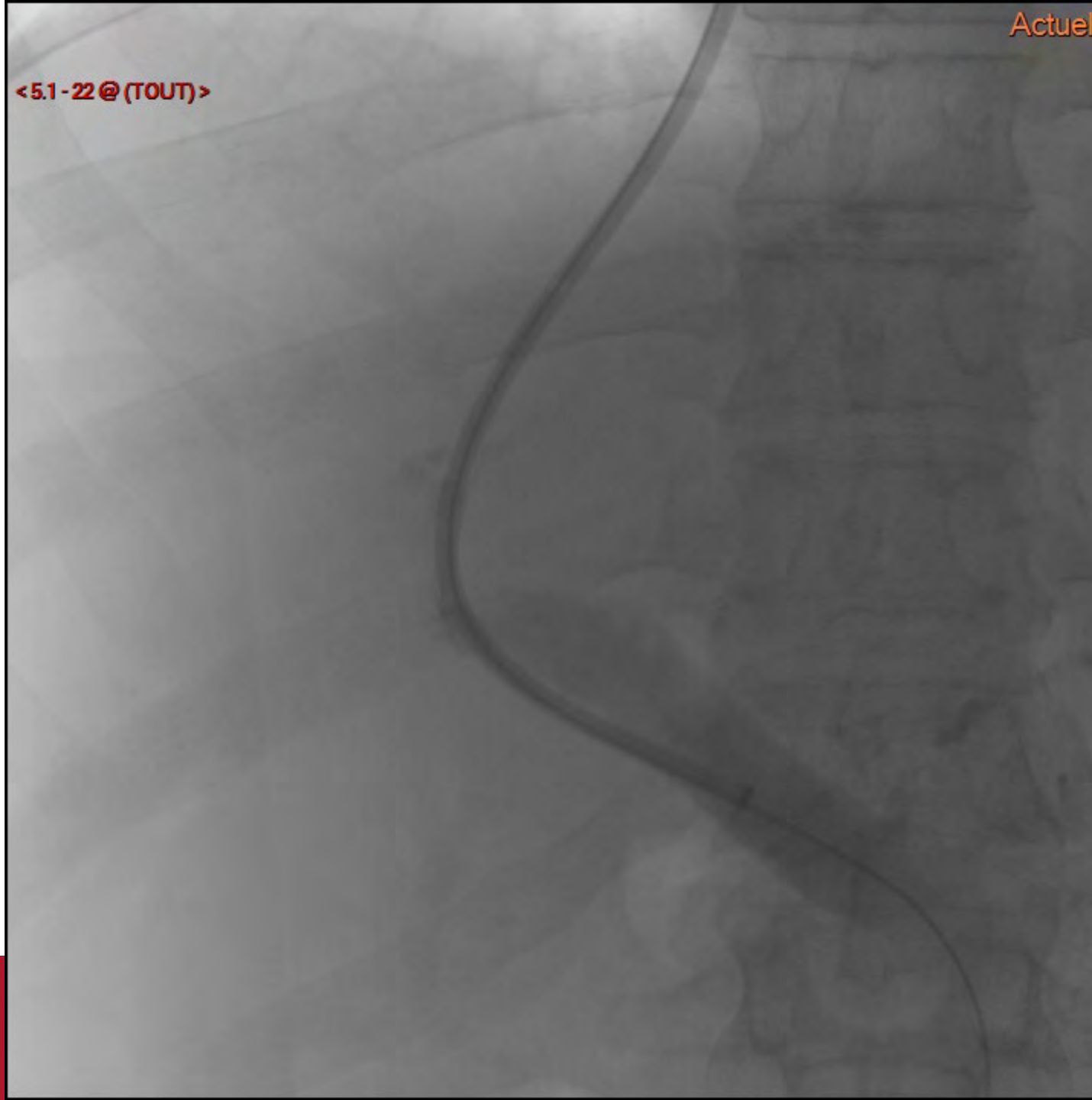
<5.1-20@TOUT>



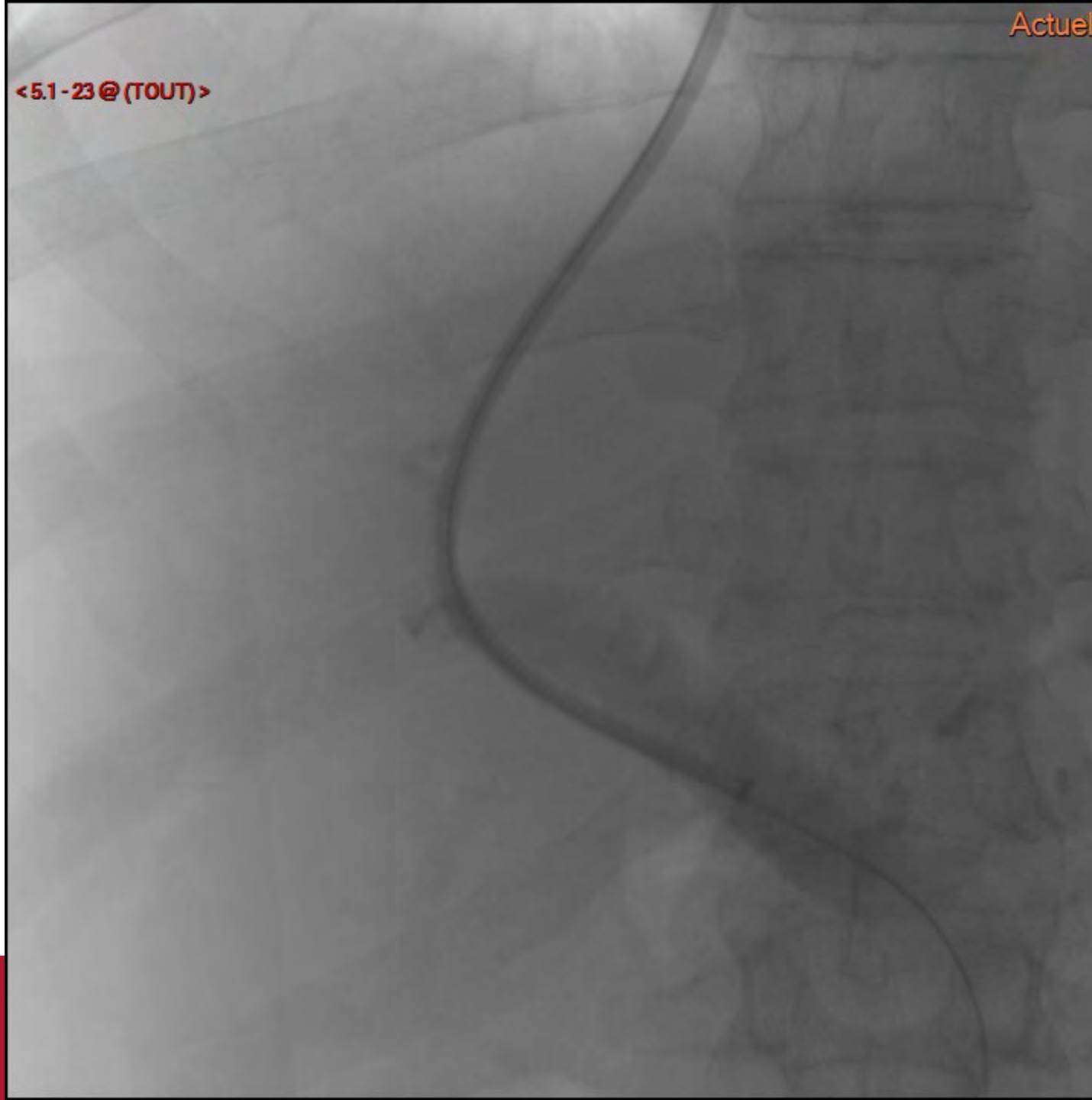
<5.1-21 @ (TOUT)>



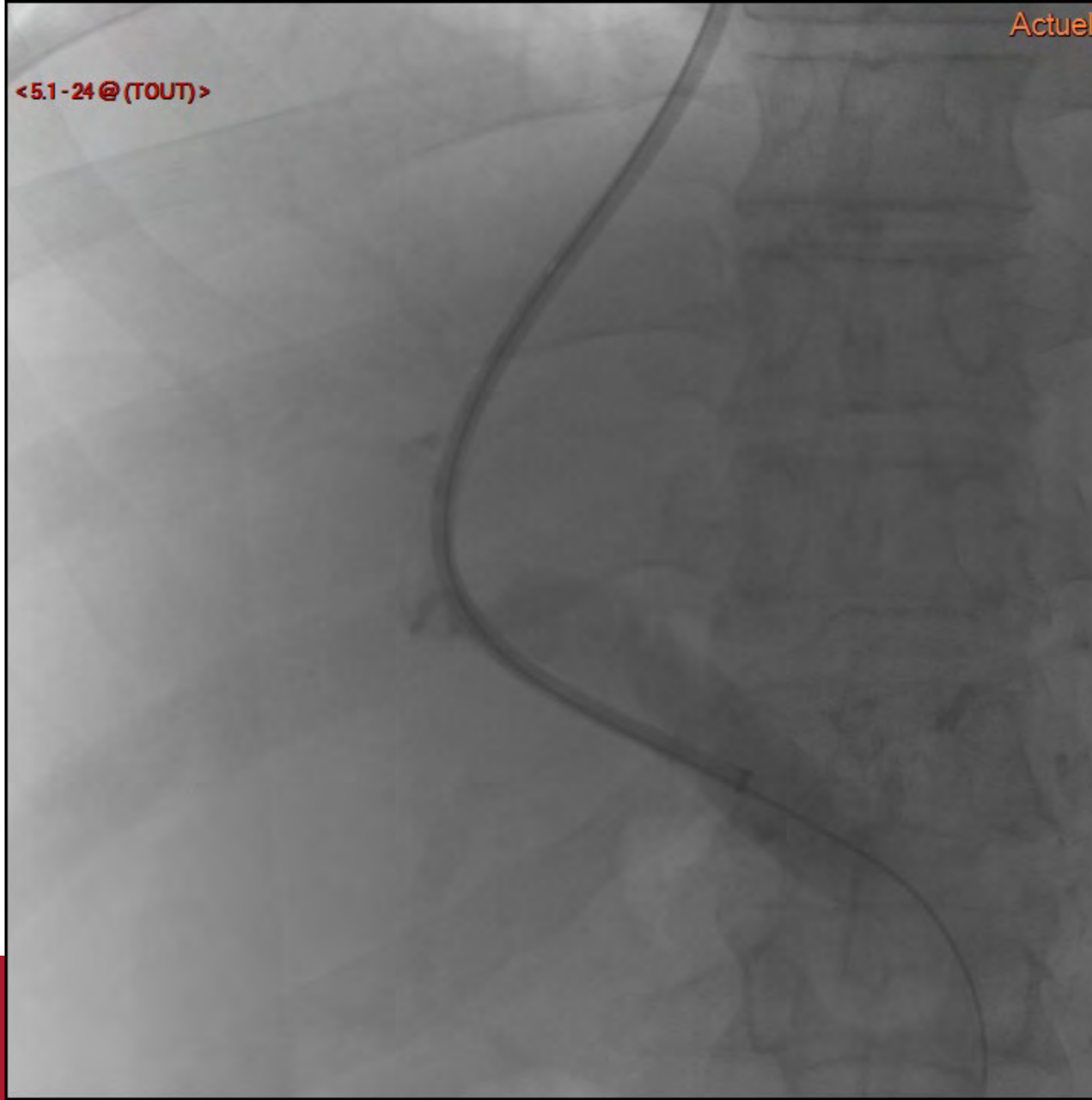
<5.1-22@ (TOUT)>



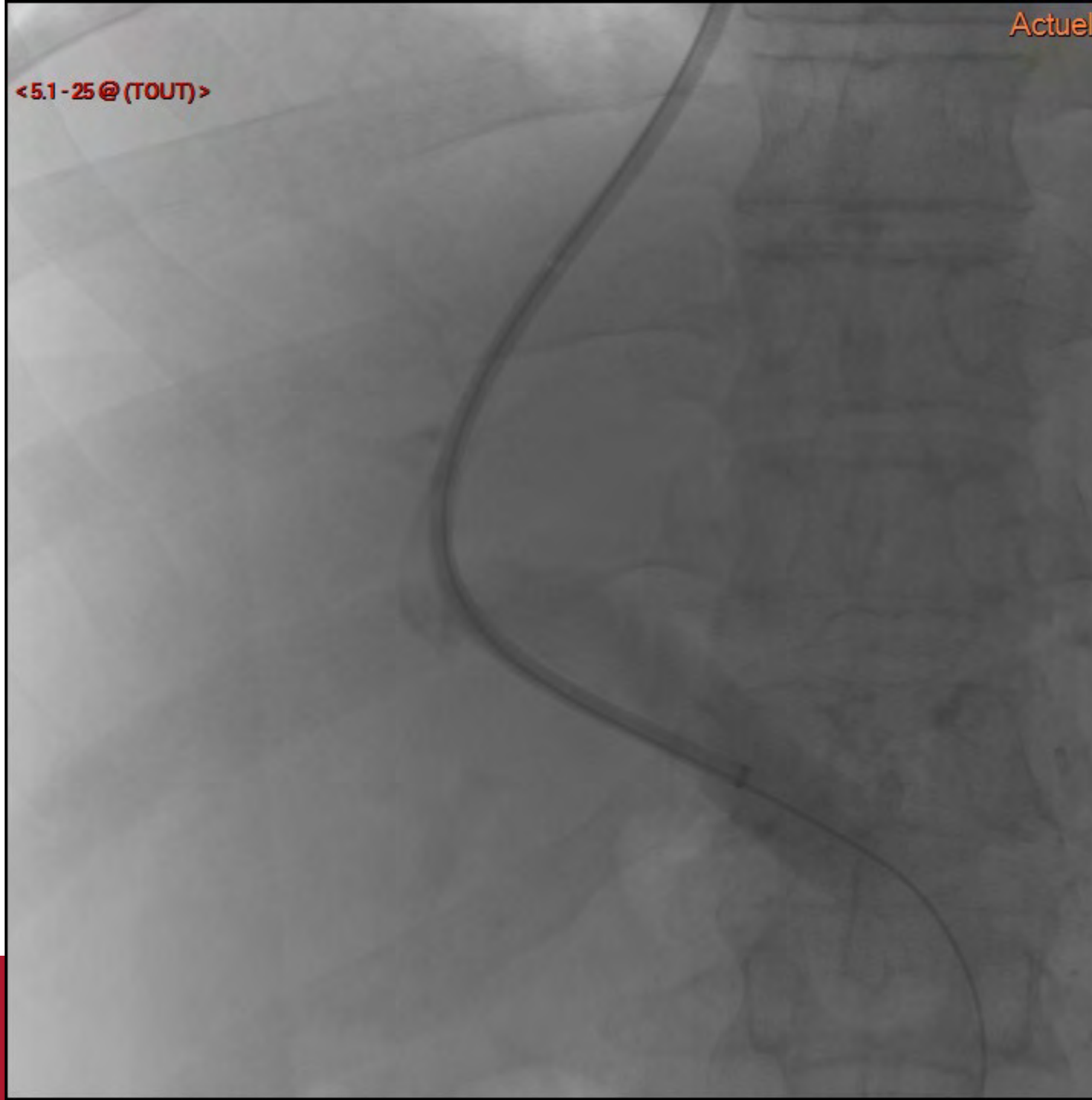
<5.1-23@TOUT>



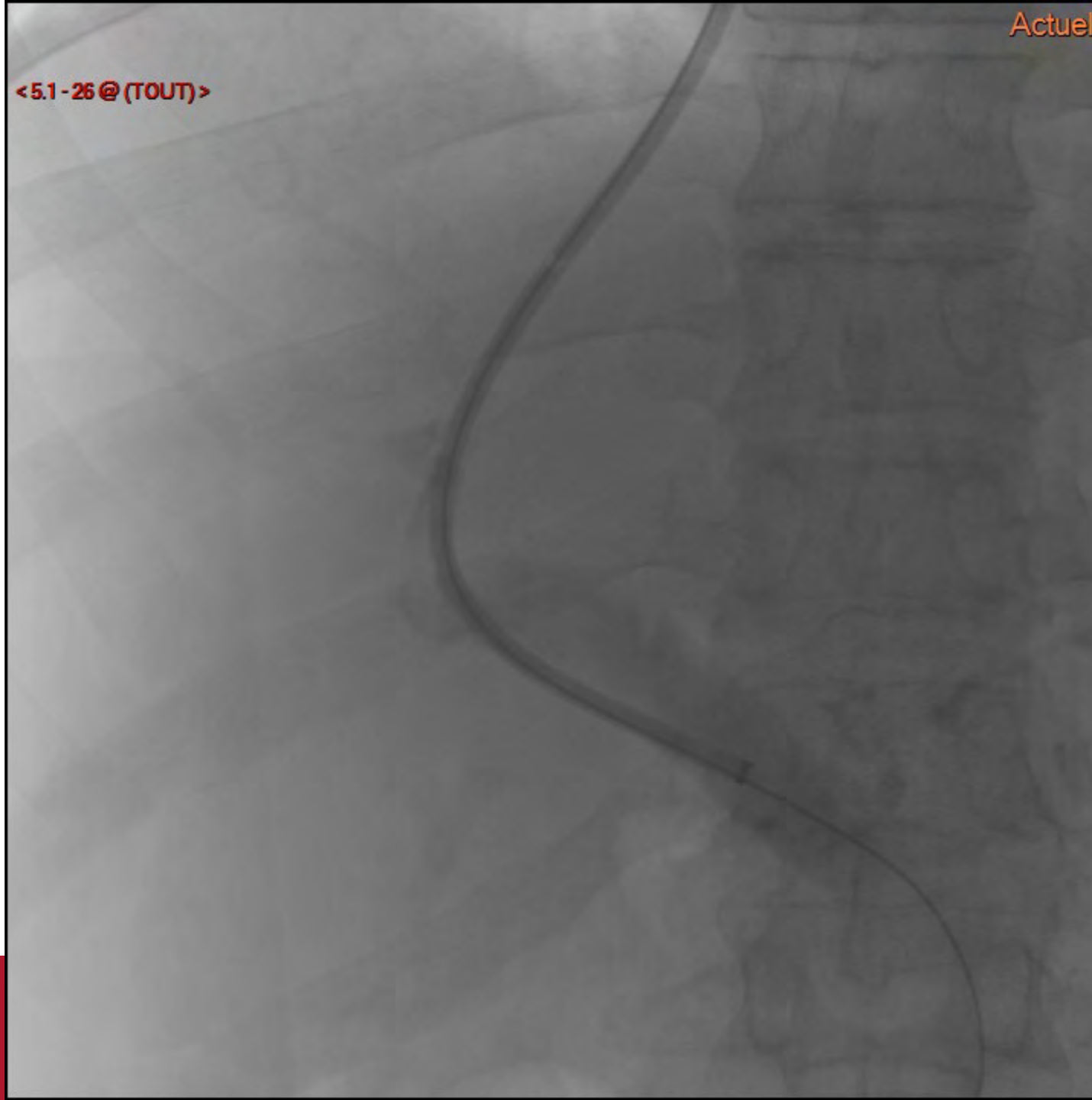
<5.1-24@ (TOUT)>



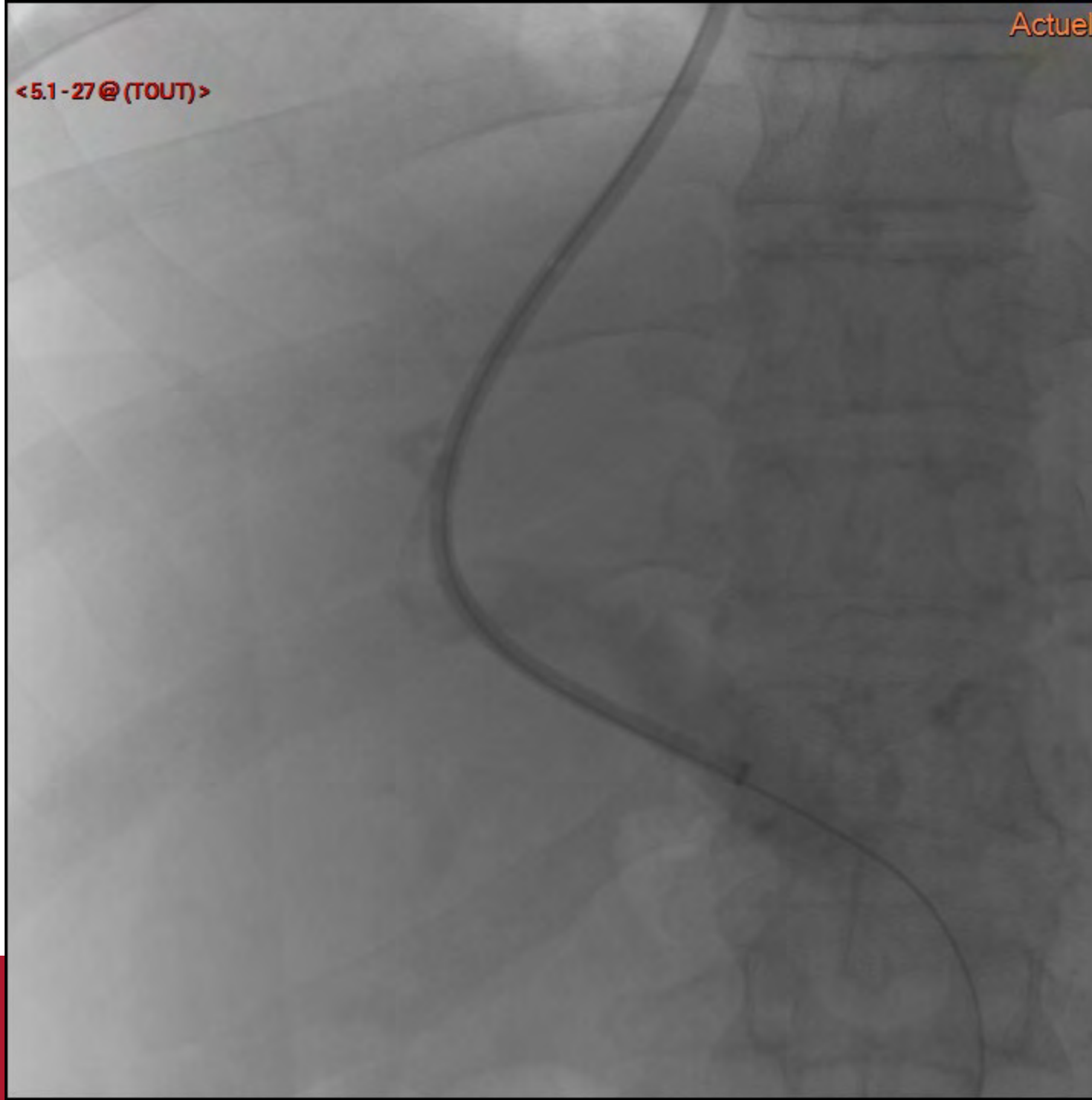
<5.1-25@ (TOUT)>



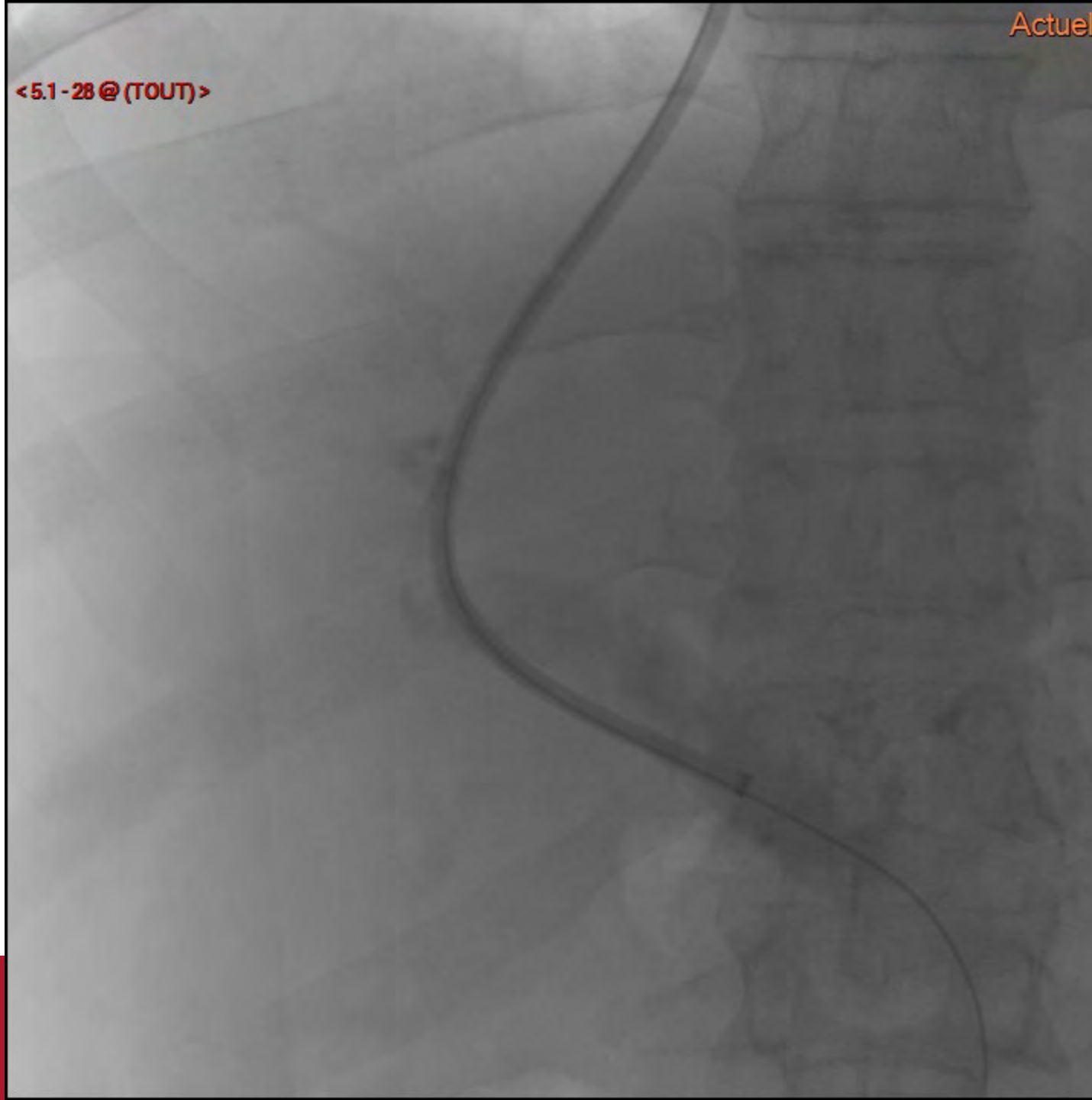
<5.1-26@ (TOUT)>



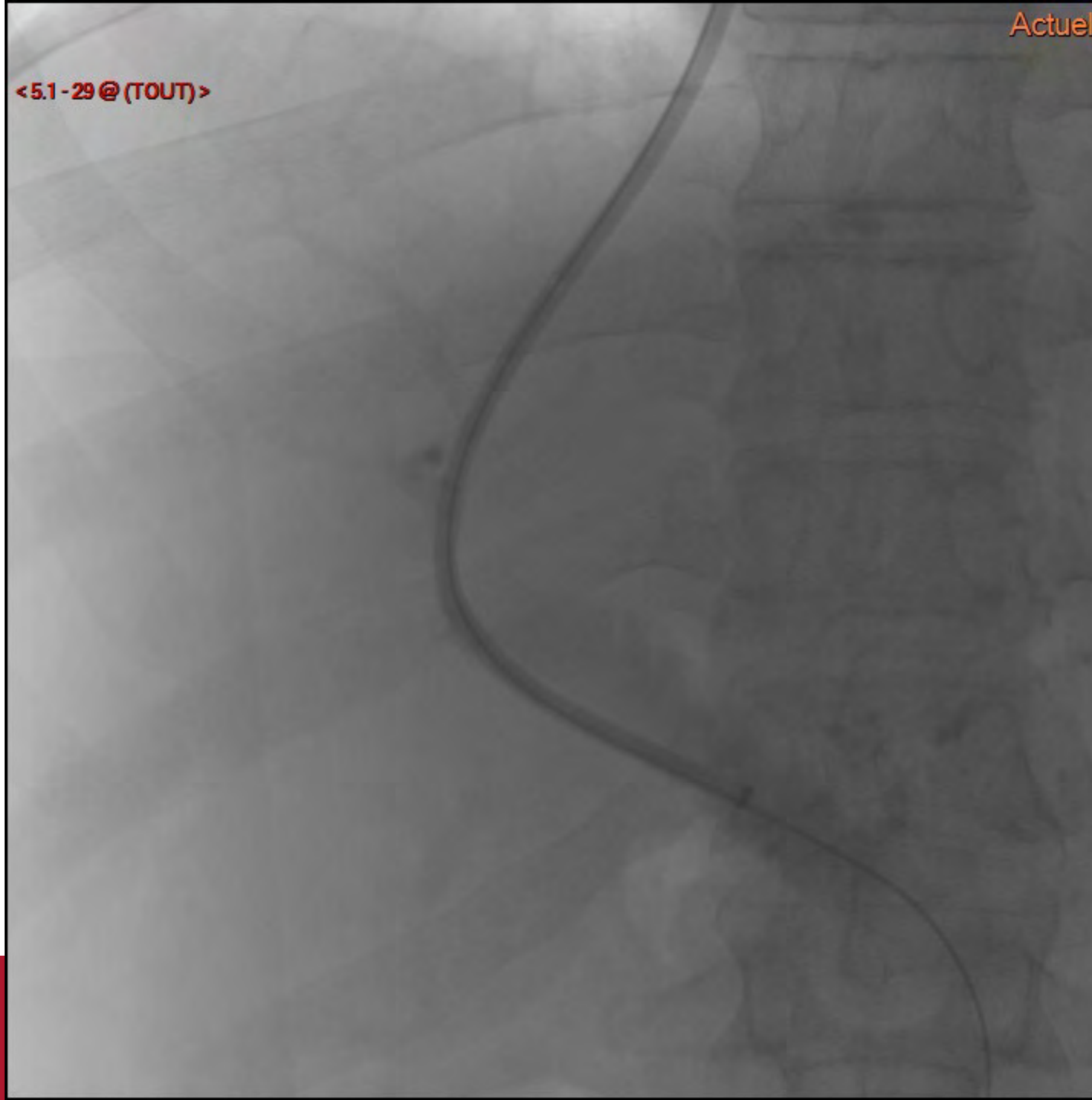
<5.1-27@TOUT>



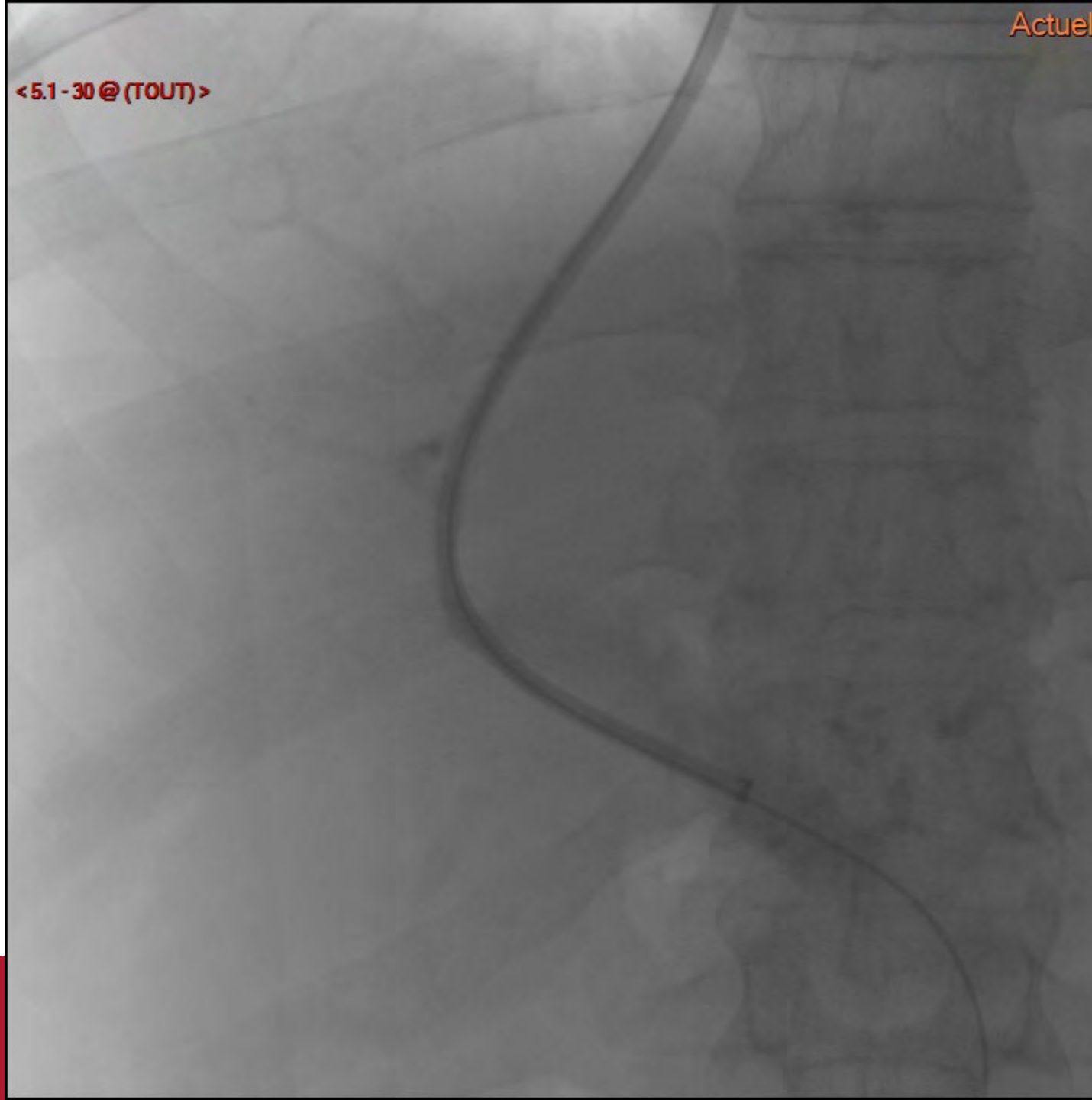
<5.1-28@TOUT>



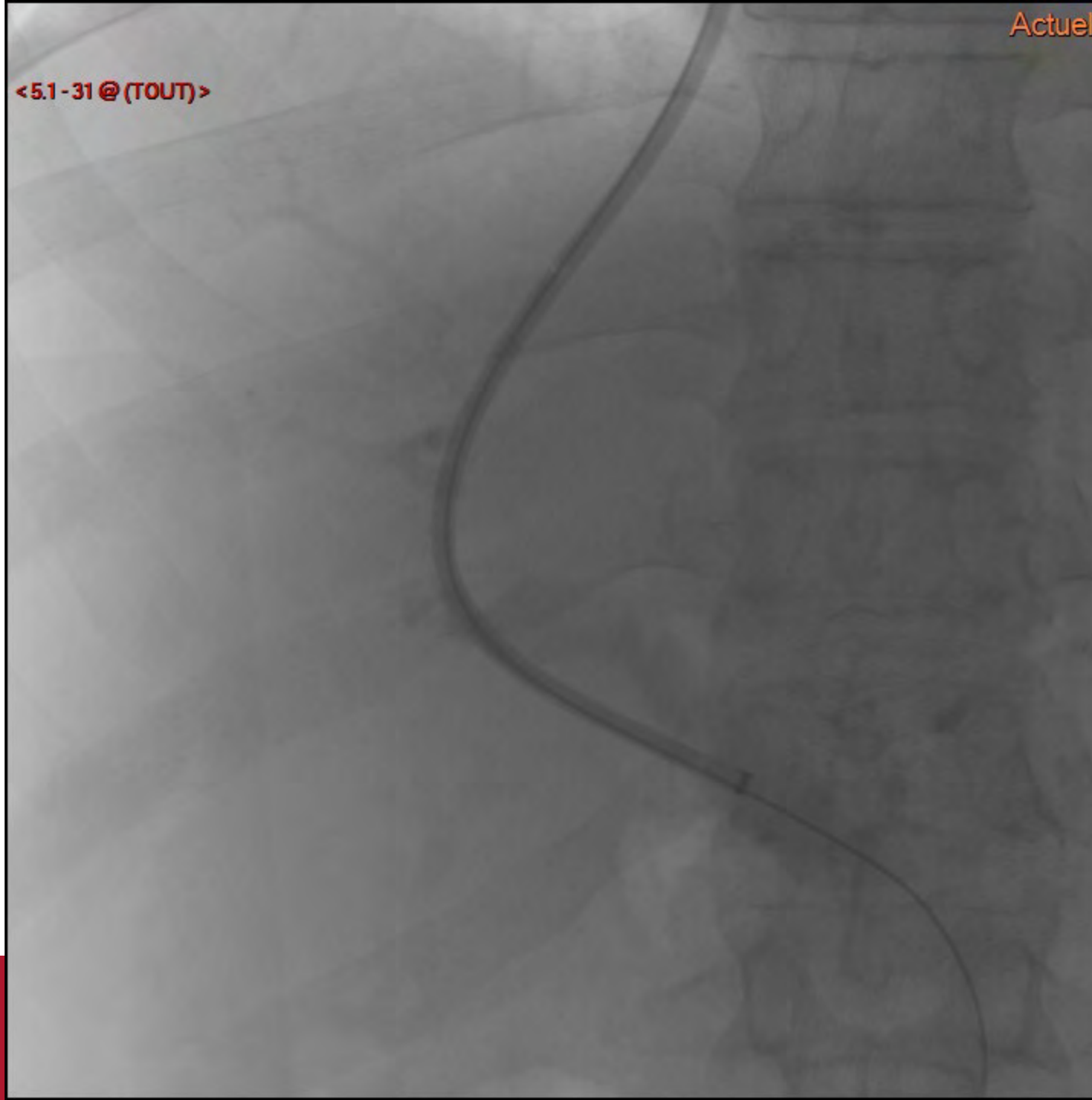
<5.1-29@ (TOUT)>



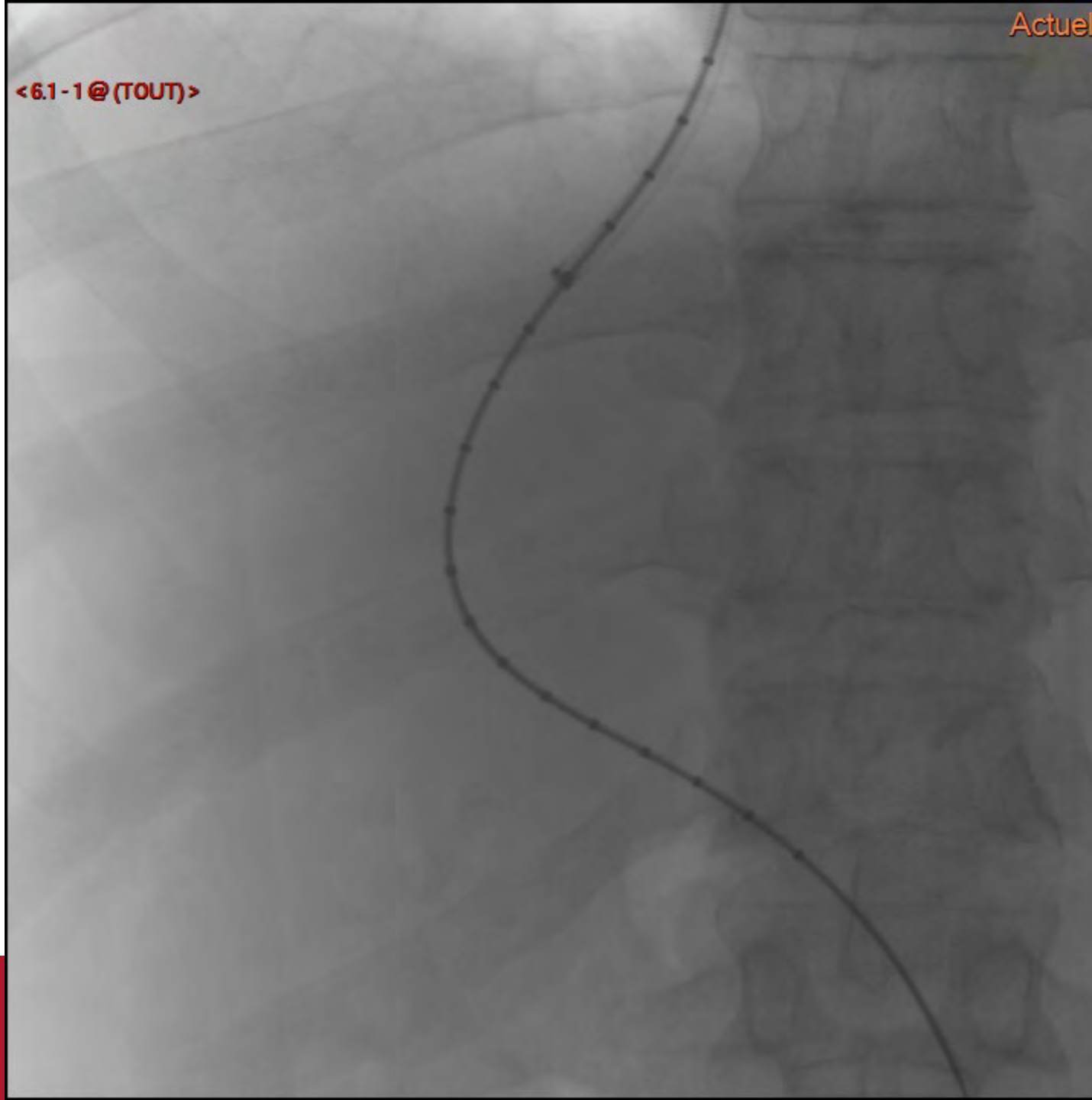
<5.1-30@ (TOUT)>



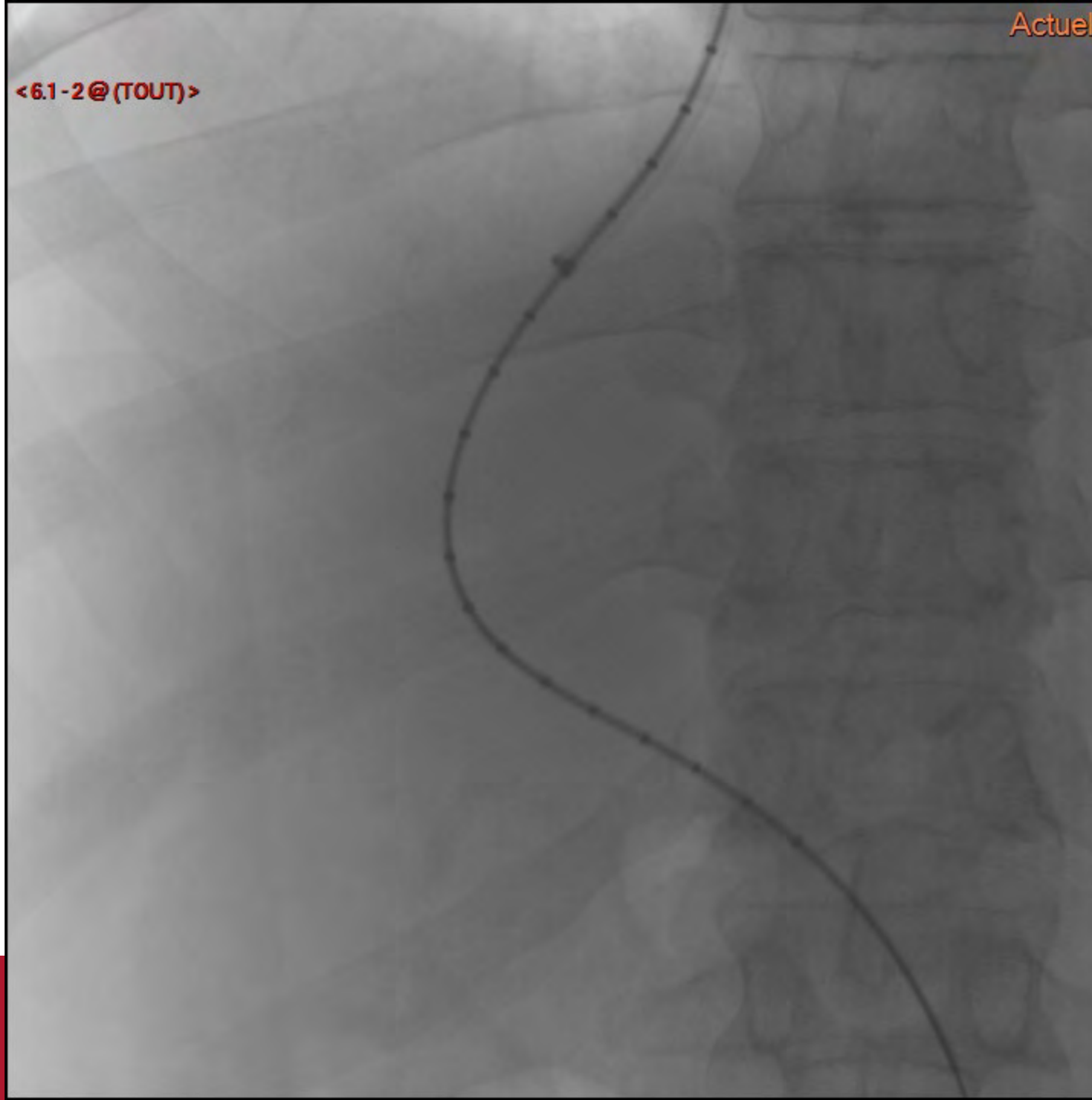
<5.1-31 @ (TOUT)>



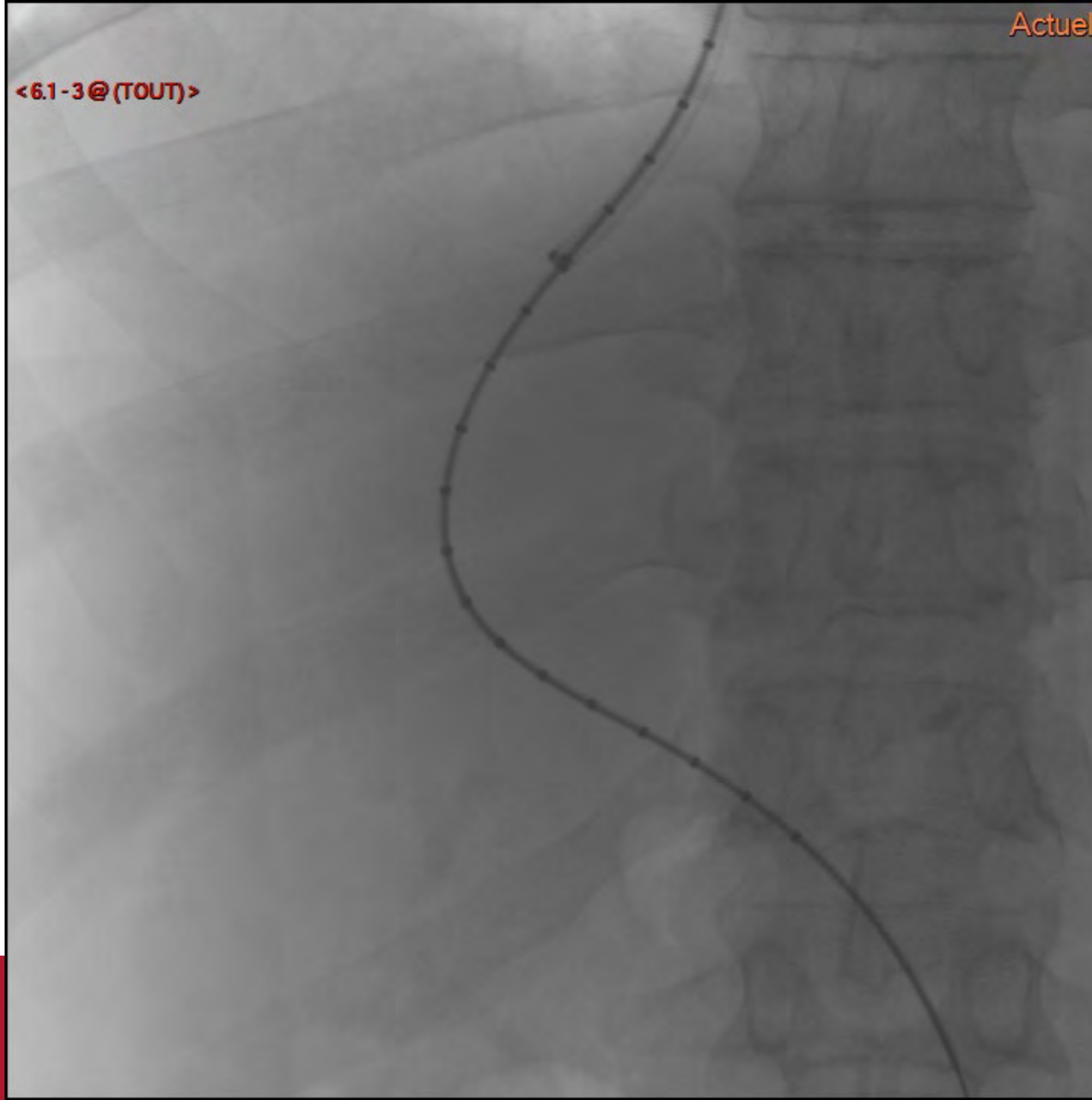
<6.1-1@TOUT>



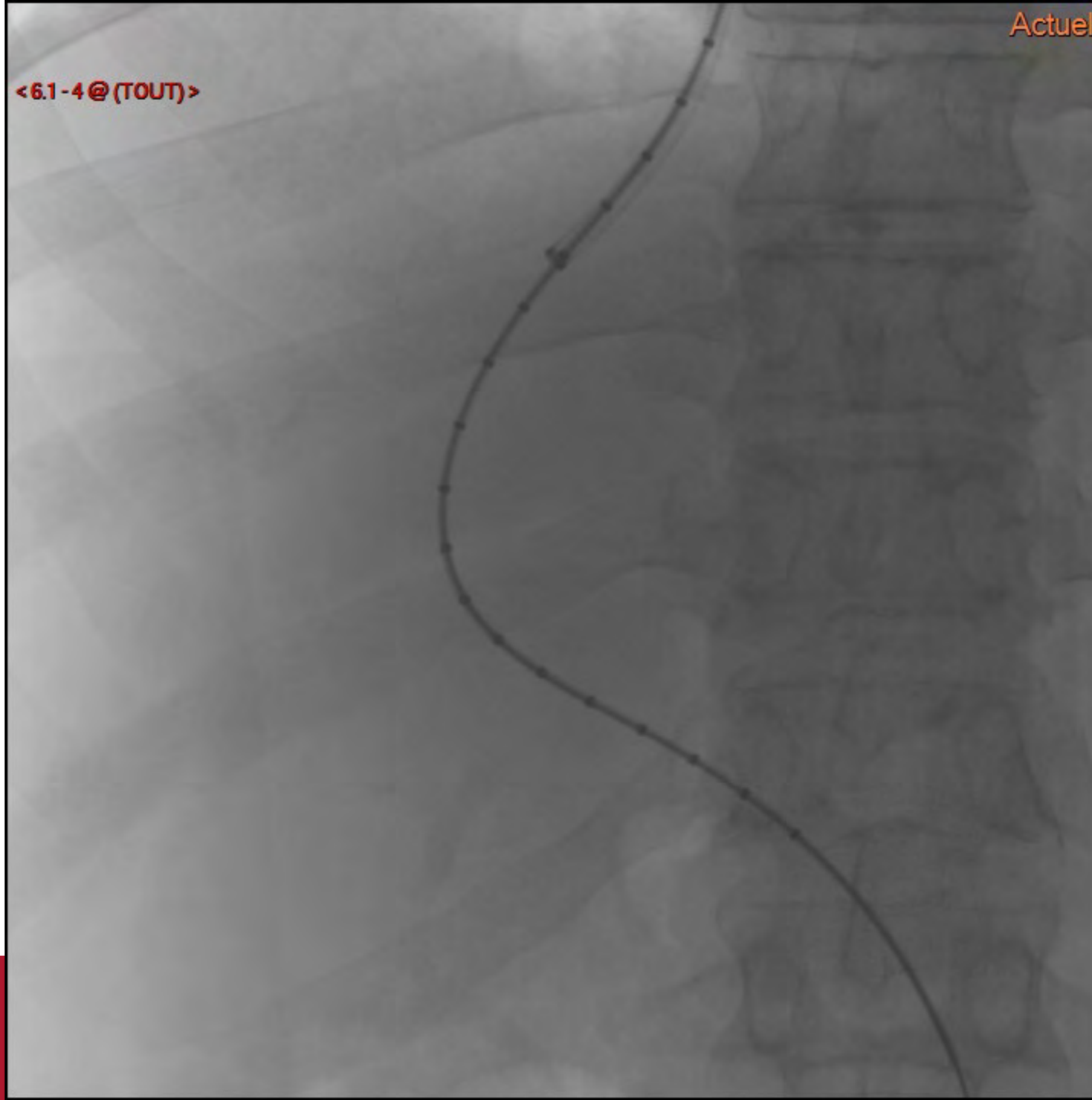
<6.1-2@ (TOUT)>



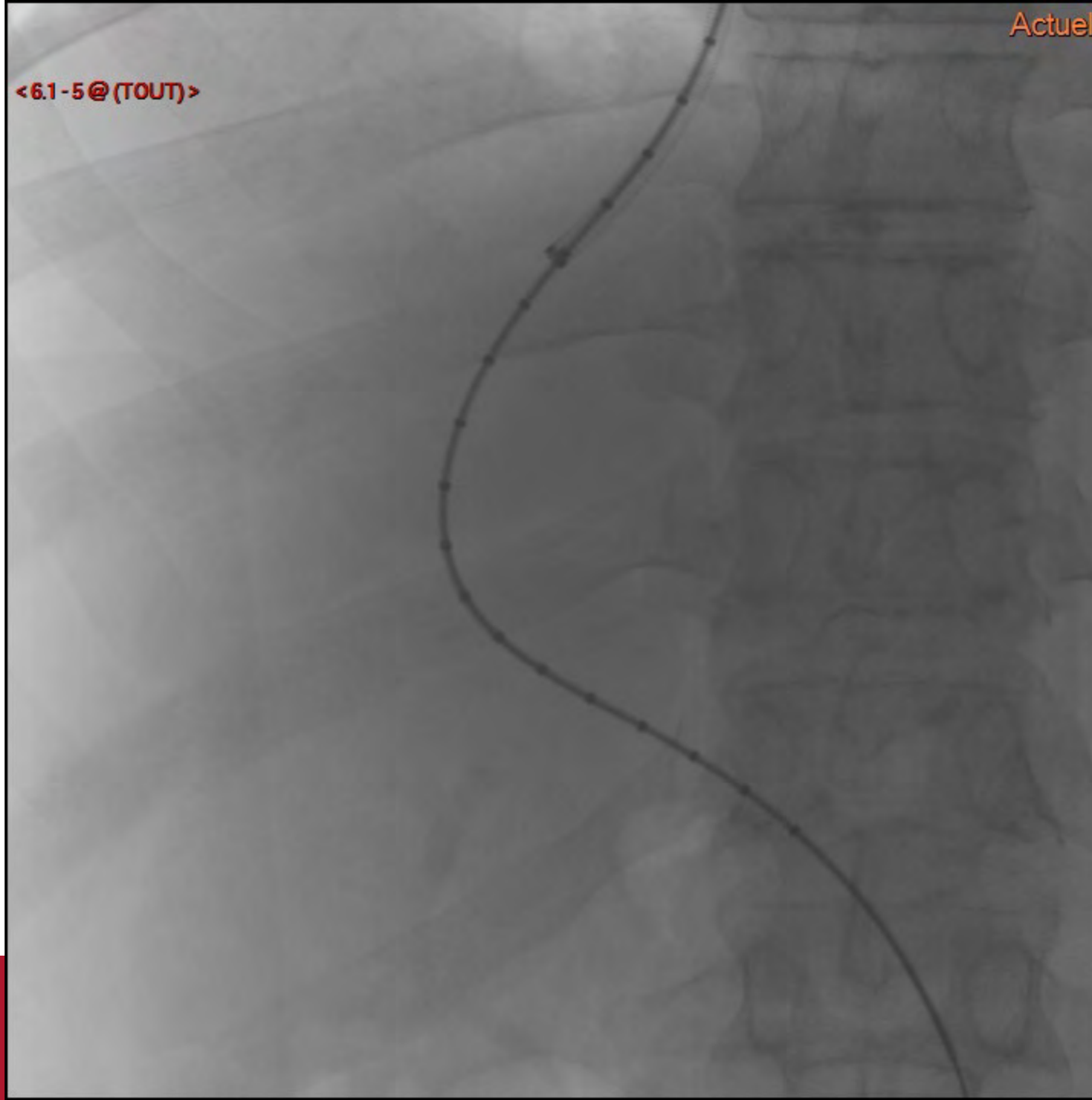
<6.1-3@ (TOUT)>



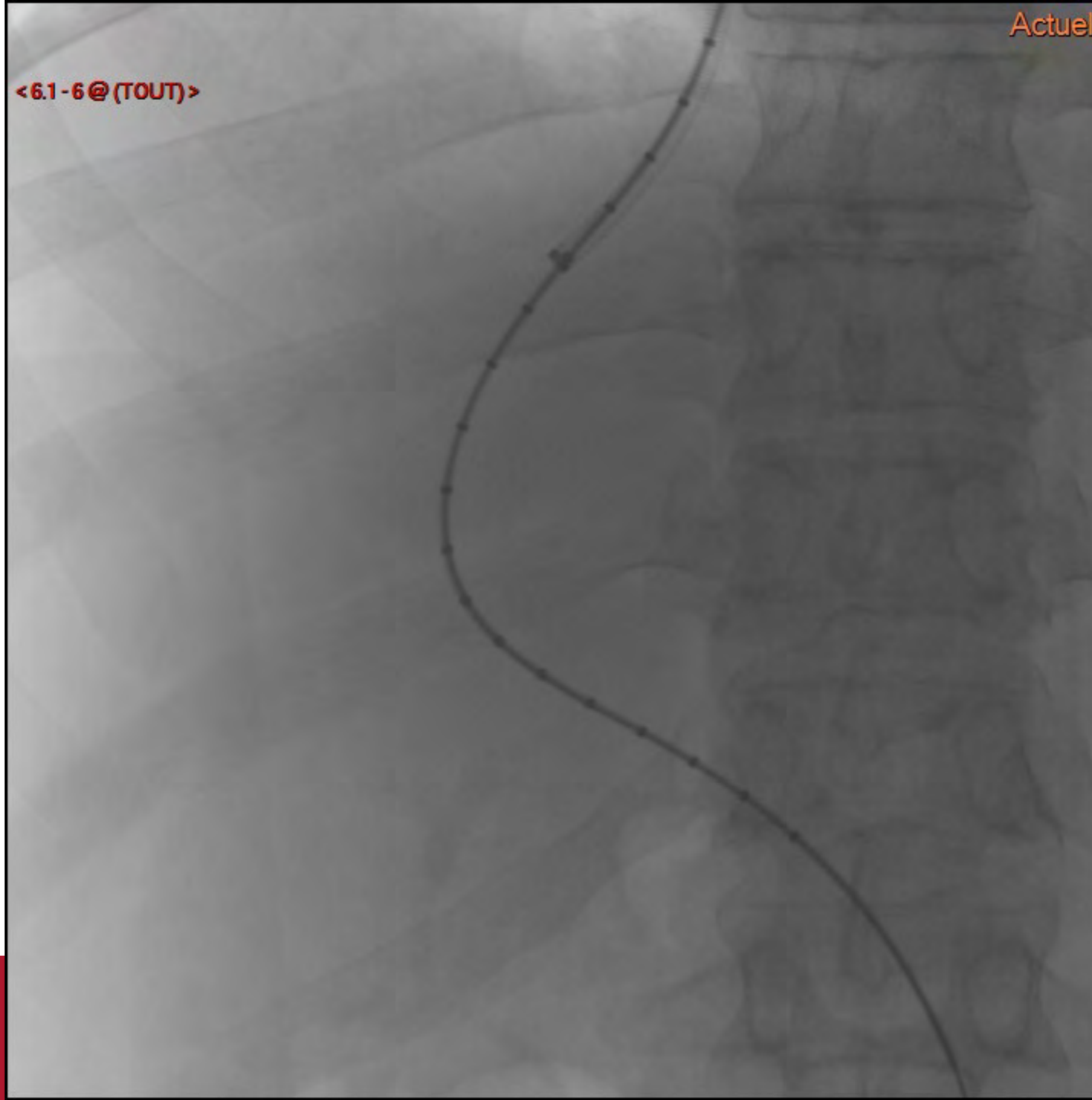
<6.1-4@ (TOUT)>



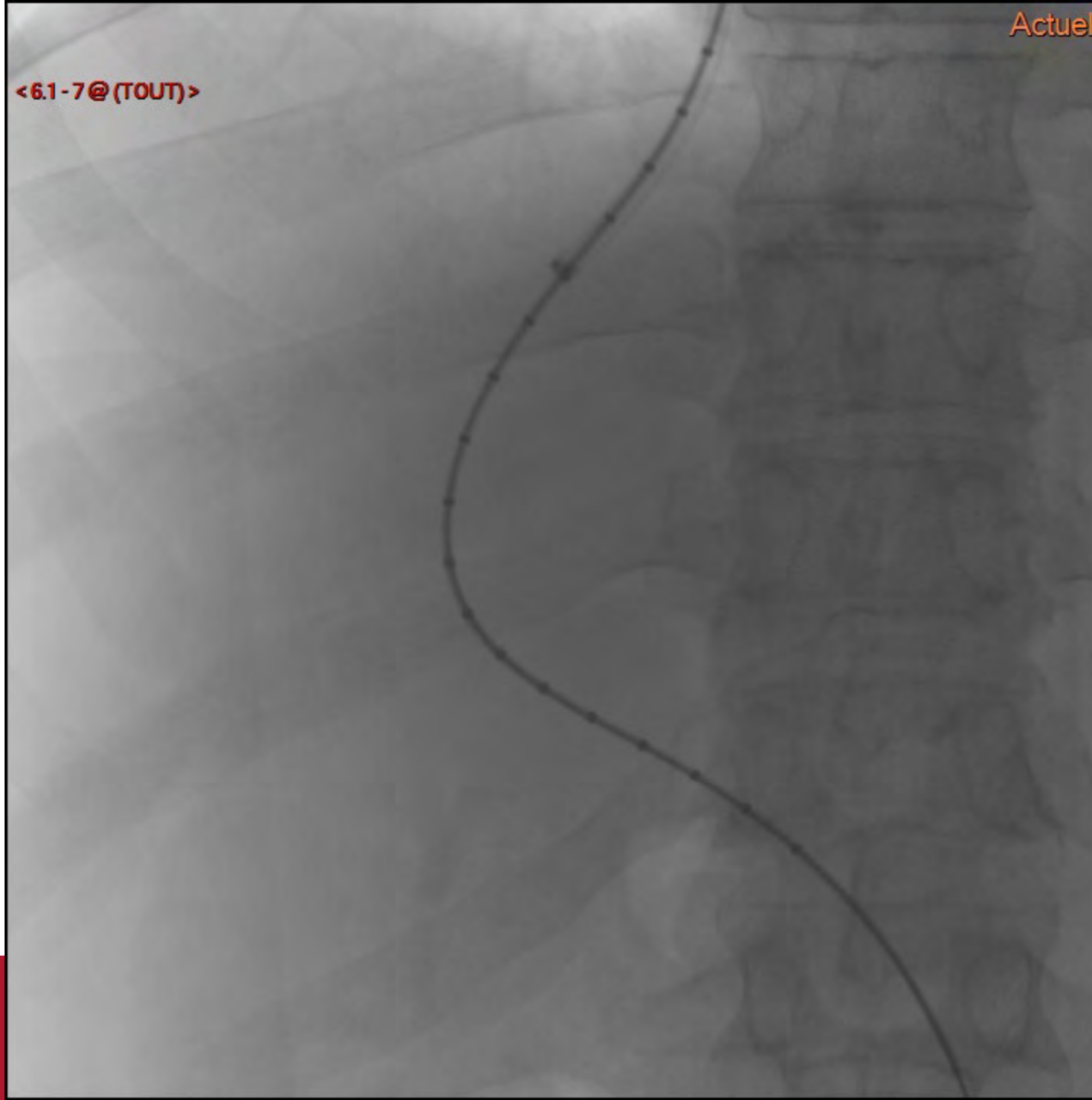
<6.1-5@ (TOUT)>



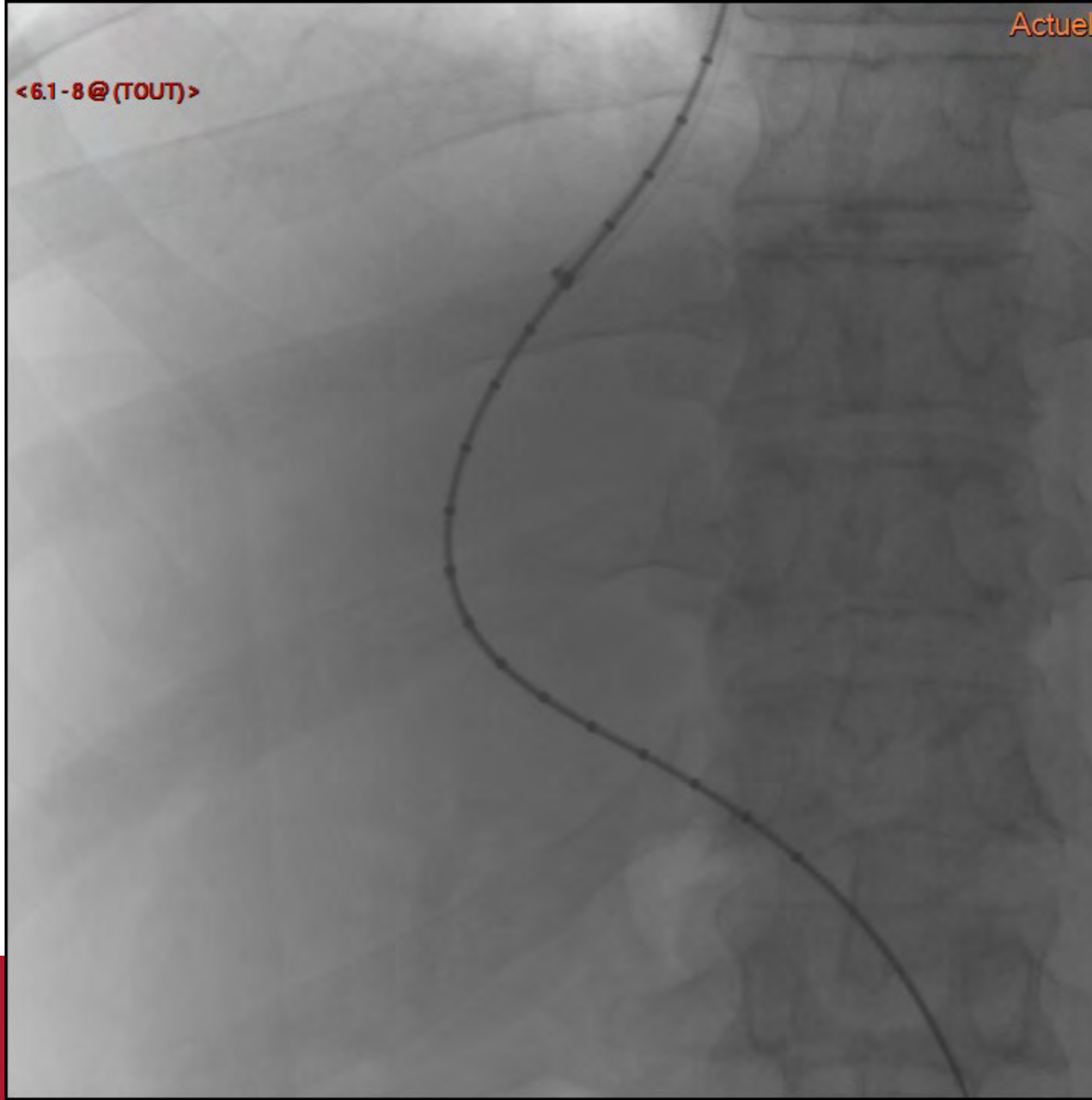
<6.1-6@ (TOUT)>



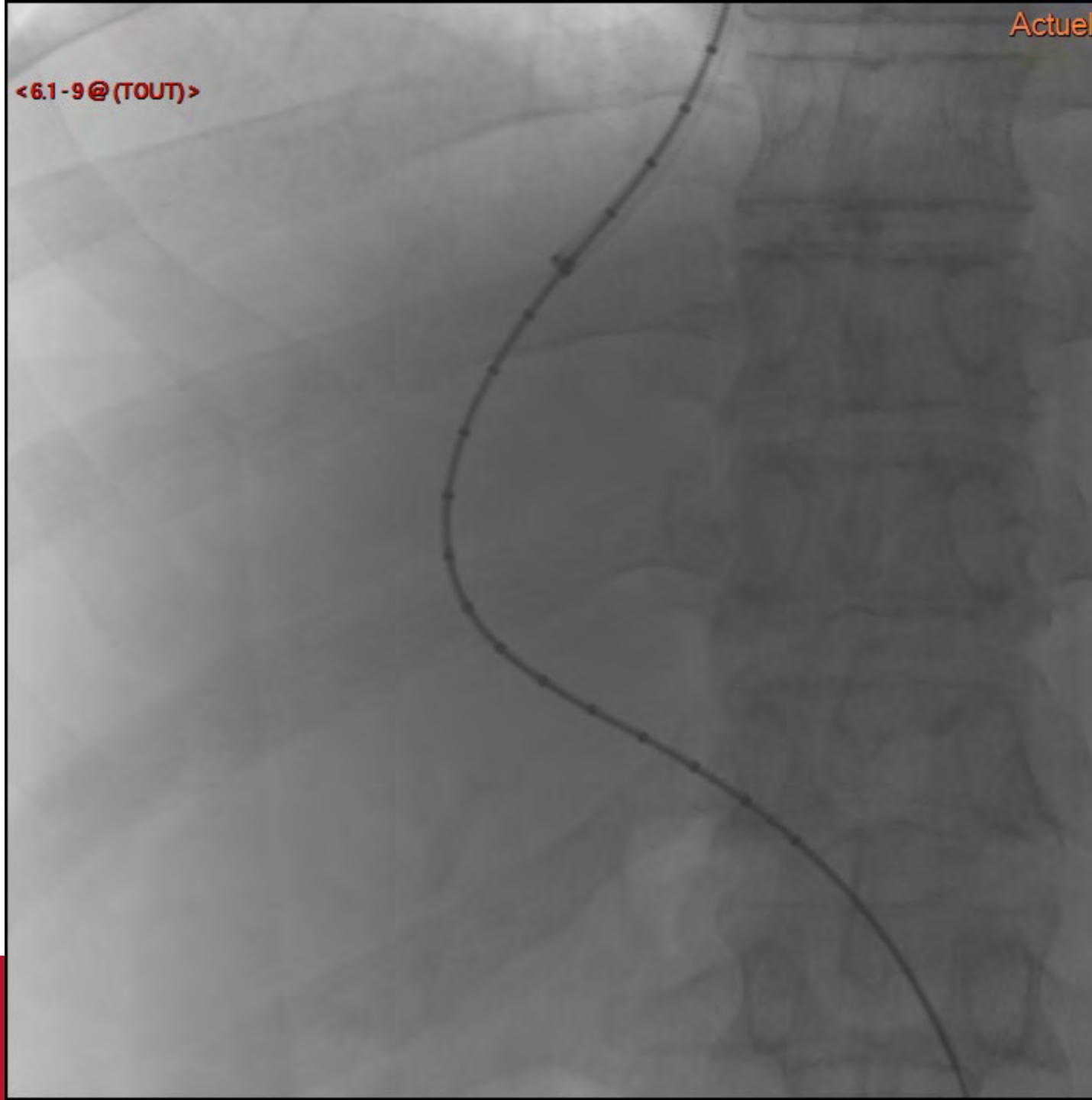
<6.1-7@ (TOUT)>



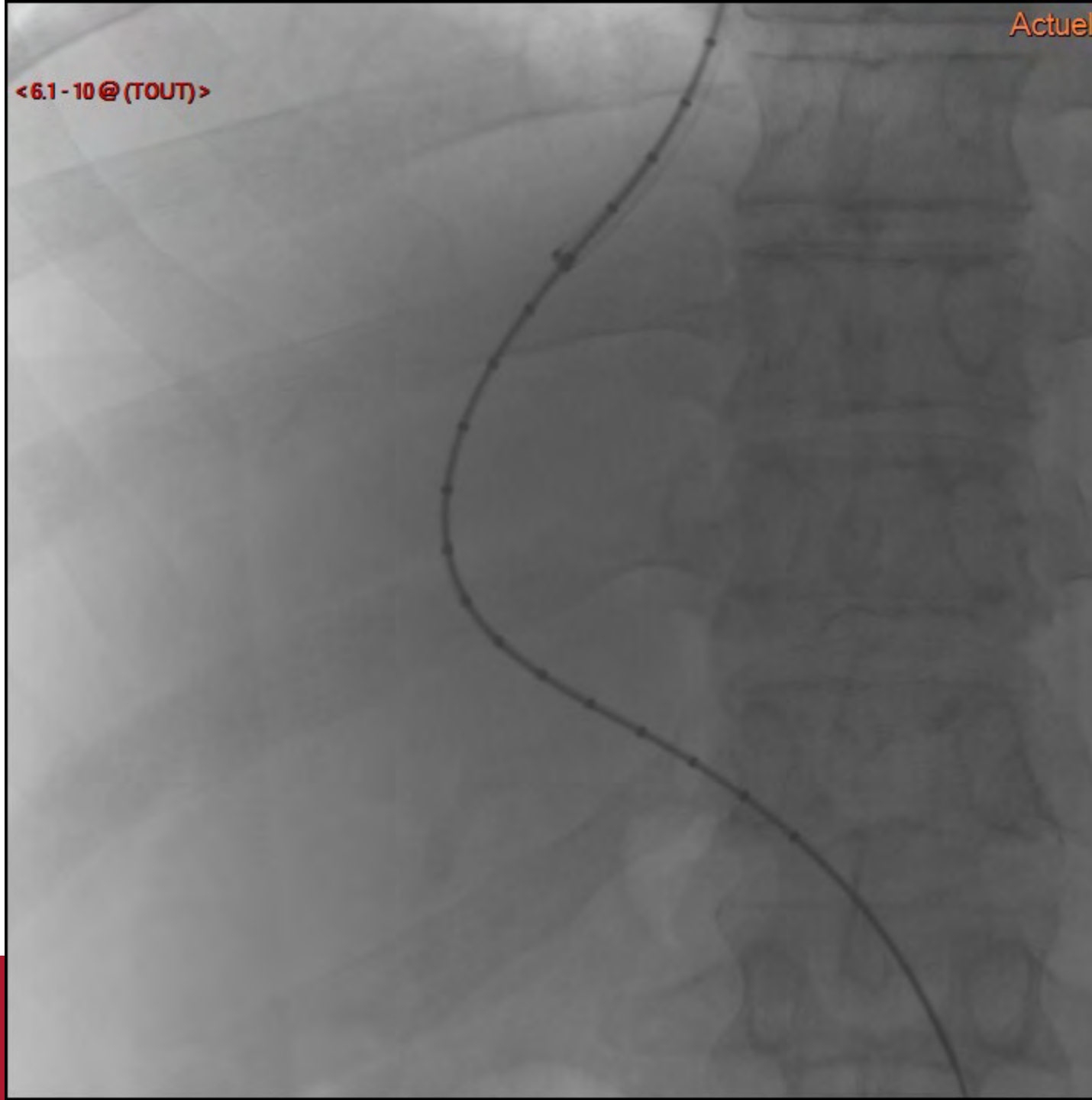
<6.1-8@ (TOUT)>



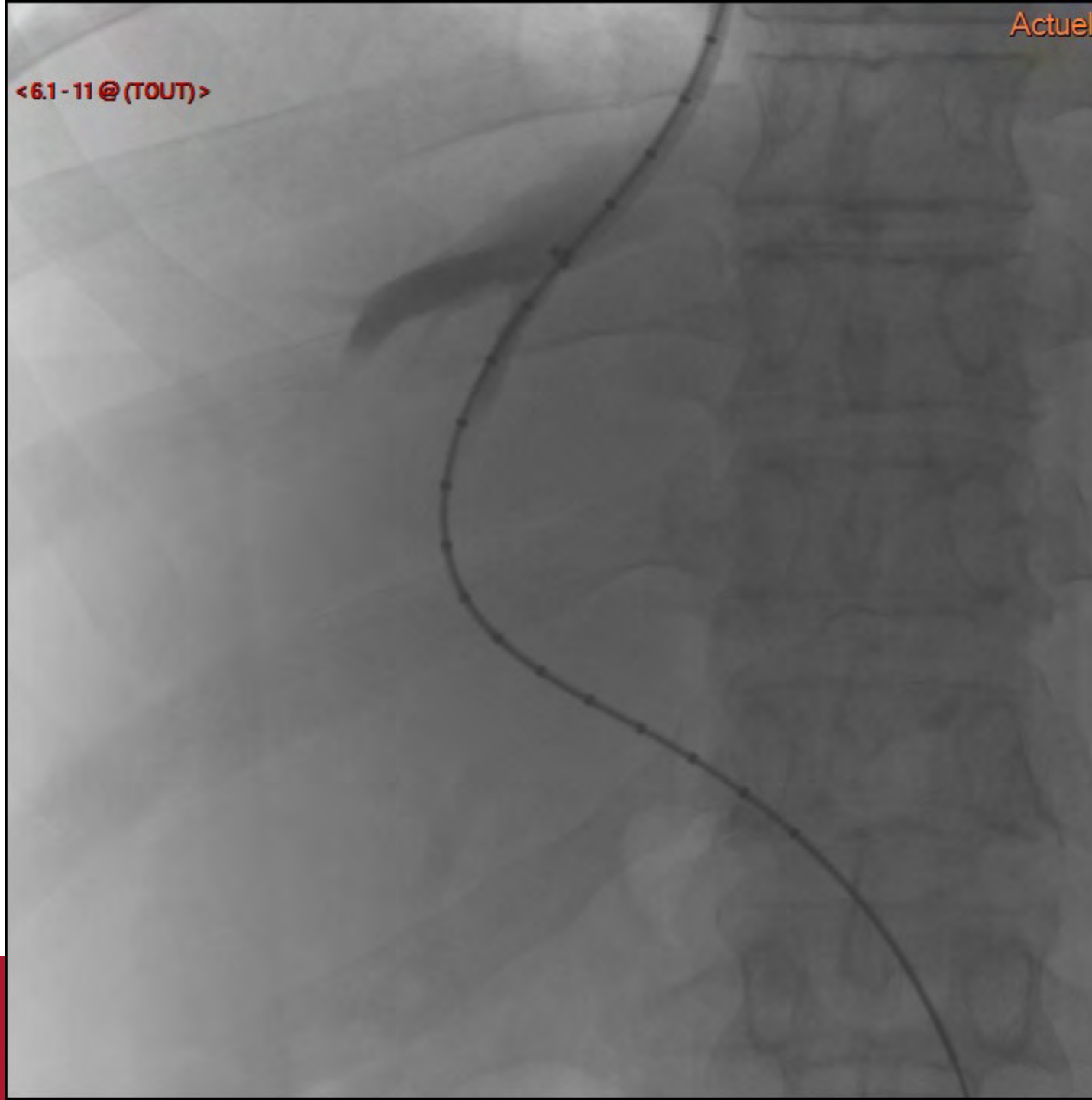
<6.1-9@ (TOUT)>



< 6.1 - 10 @ (TOUT) >



<6.1-11@TOUT>



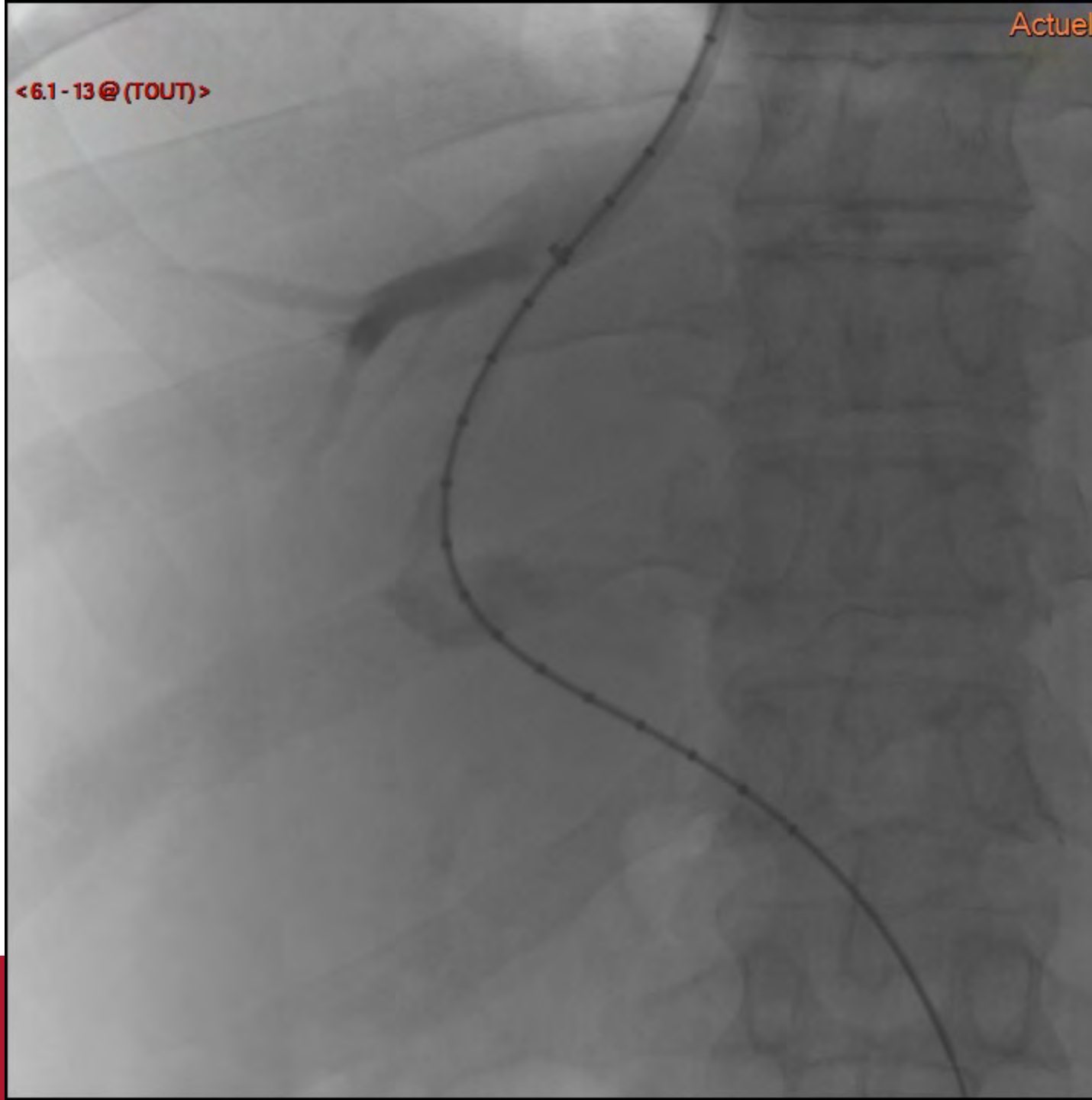
<6.1-12@ (TOUT)>

Sus-hép

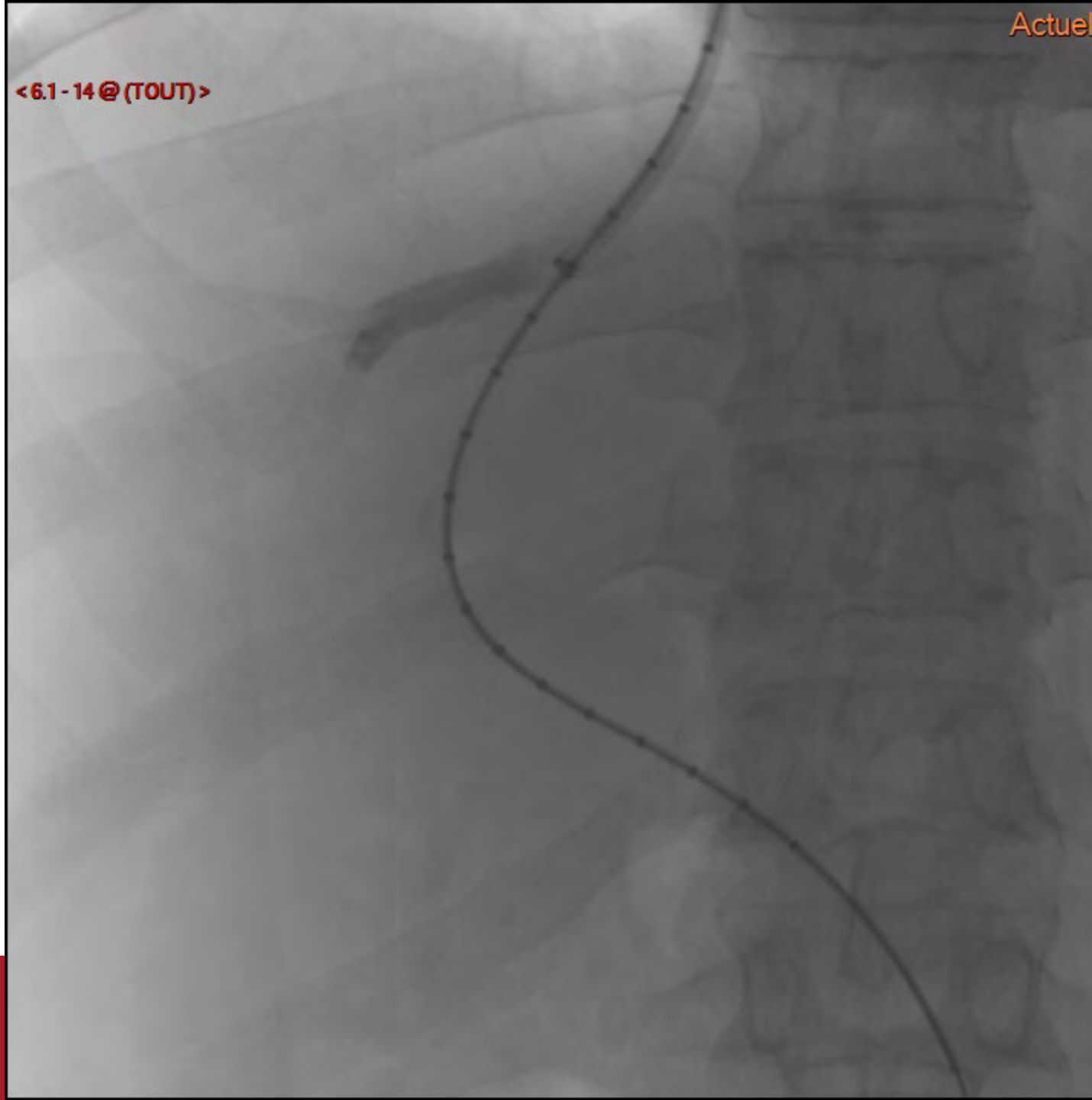
Entrée

Sortie

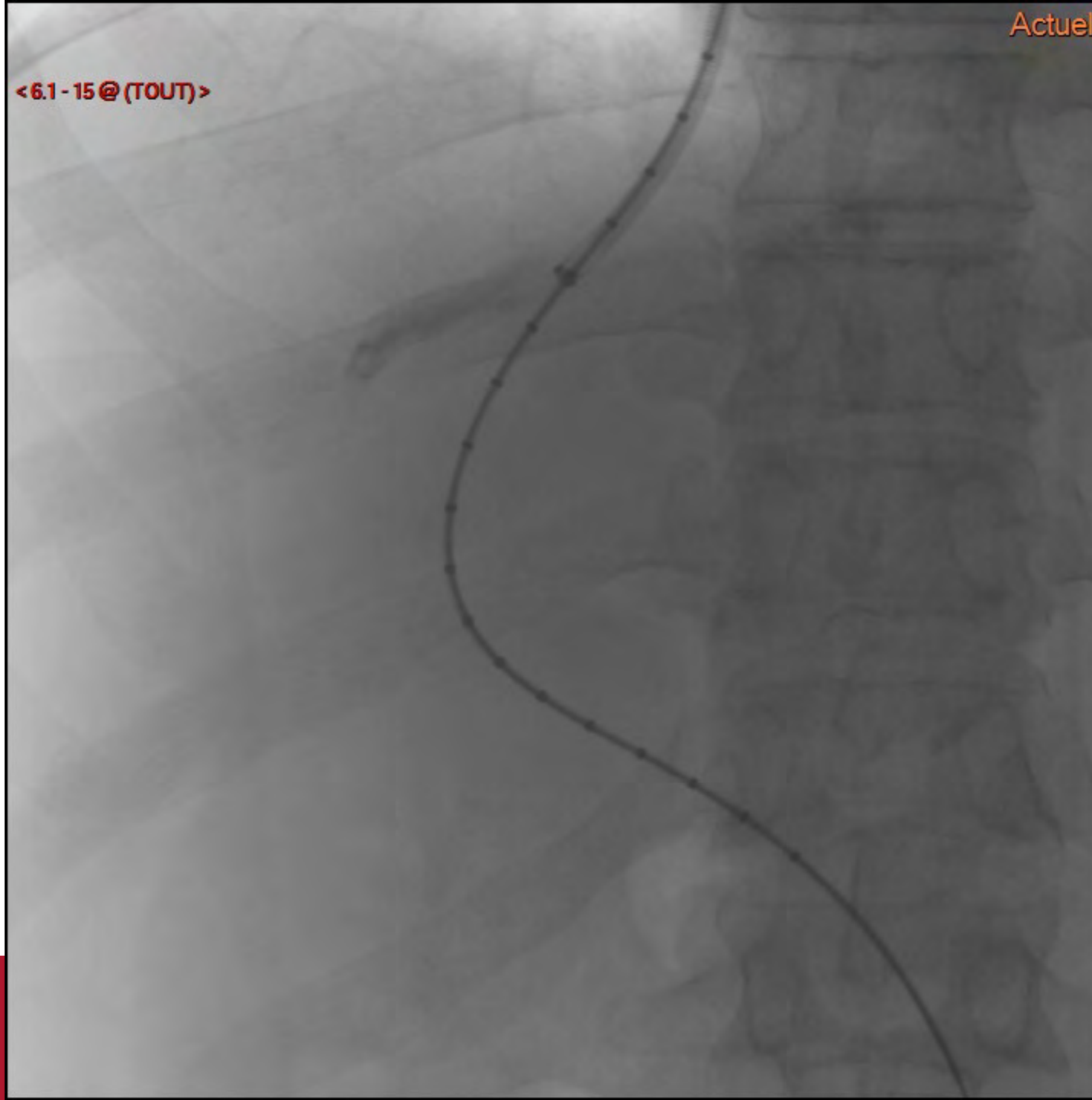
<6.1-13@ (TOUT)>



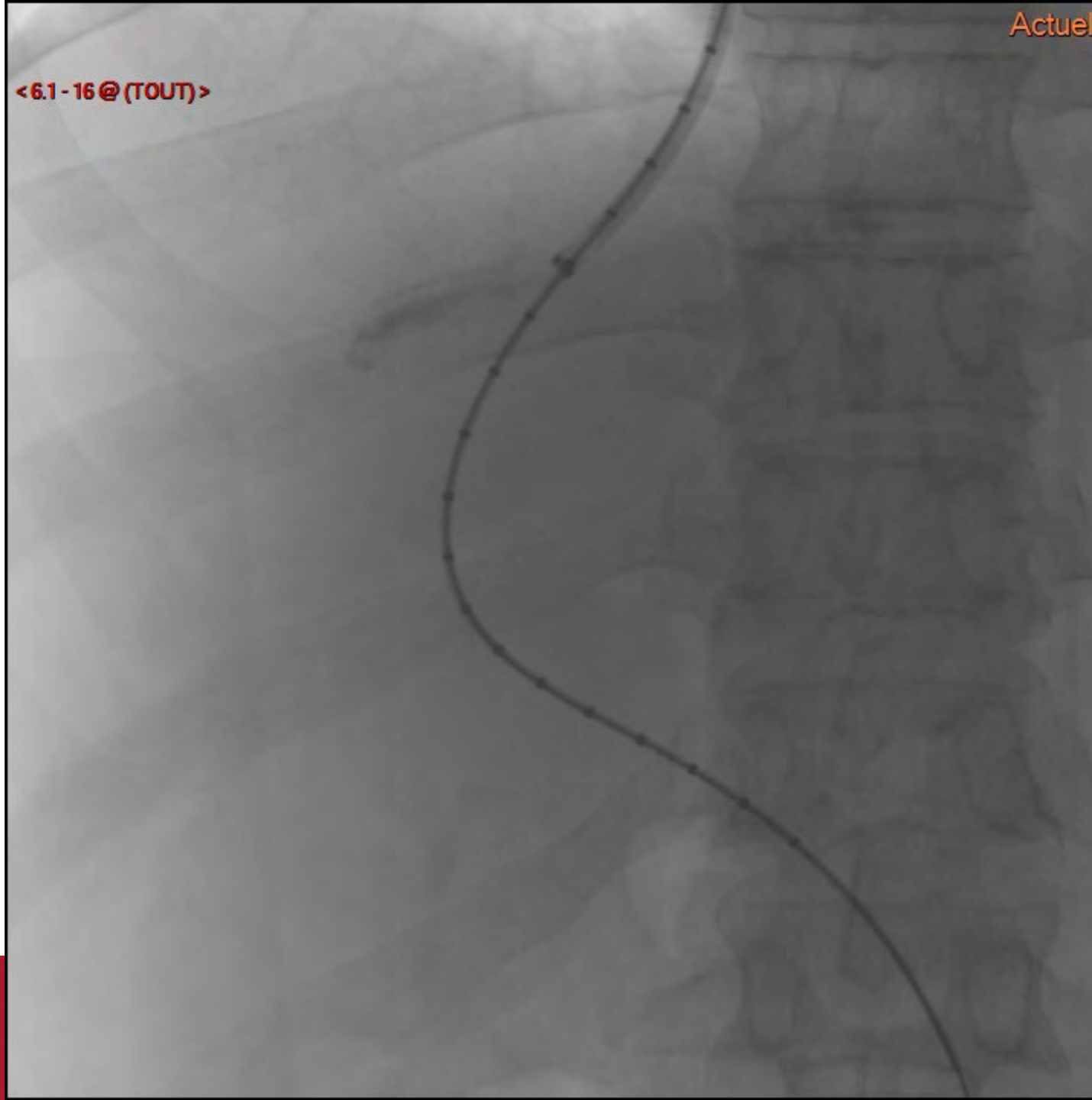
<6.1-14@ (TOUT)>



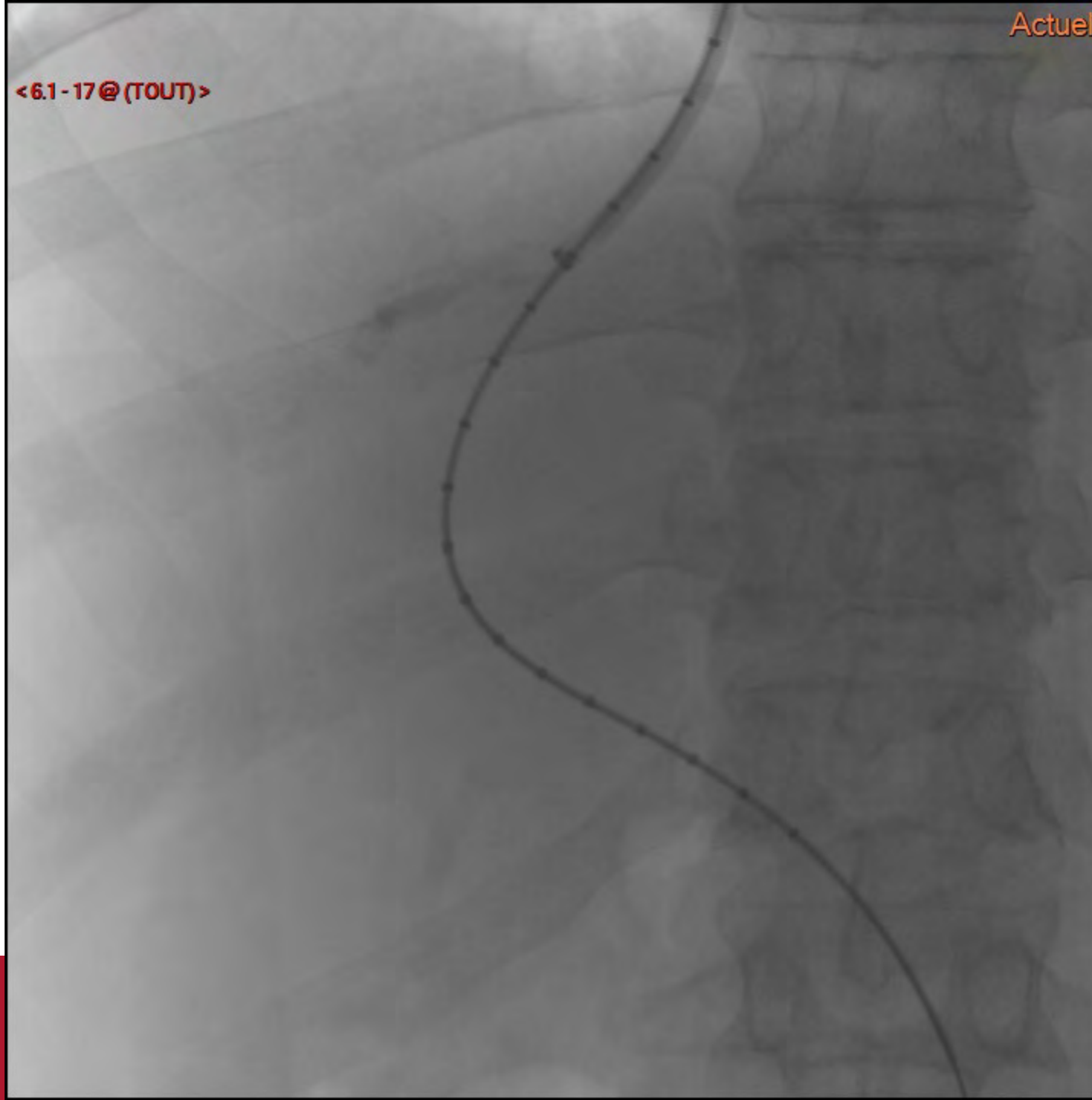
<6.1-15@ (TOUT)>



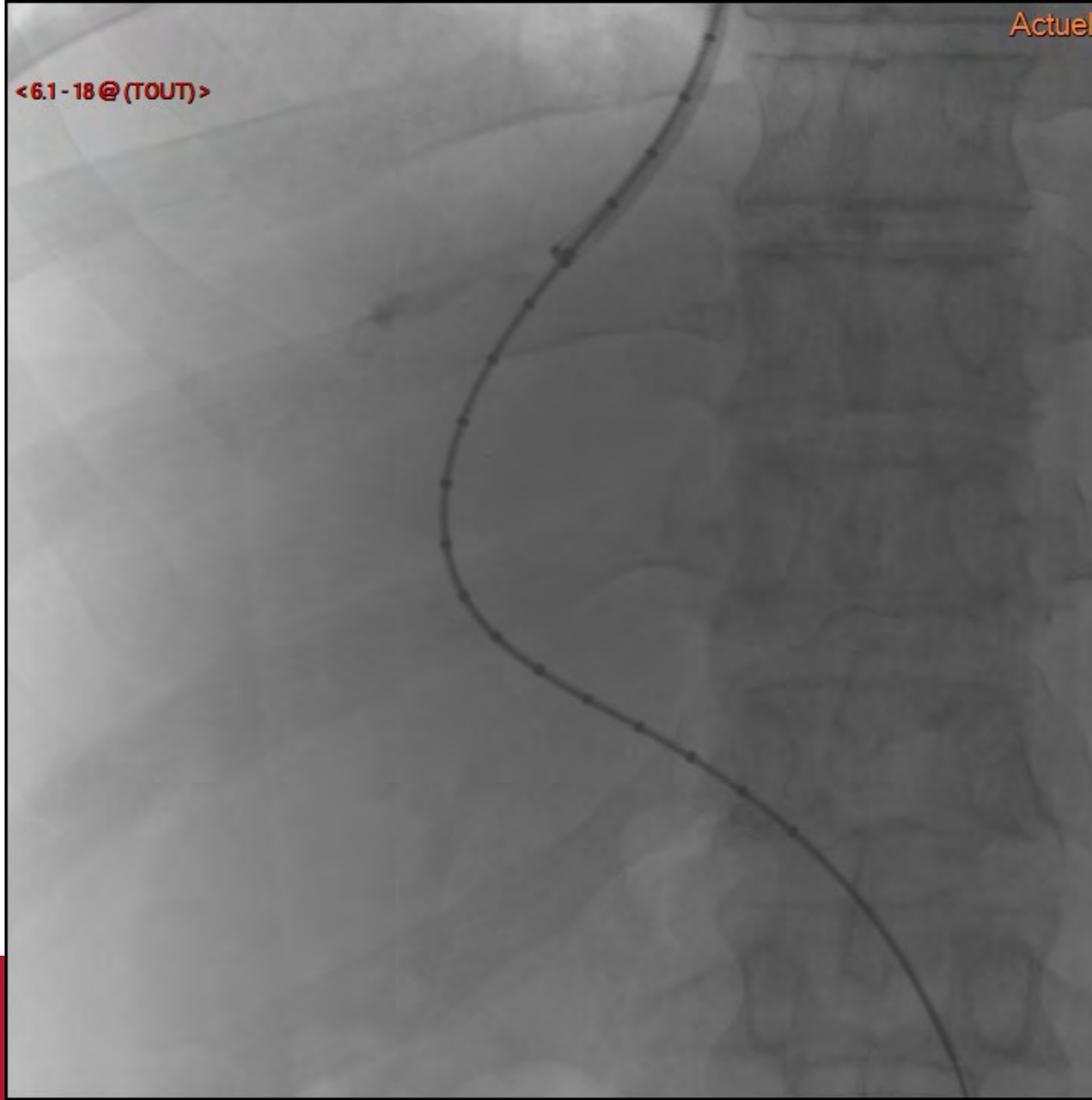
<6.1-16@ (TOUT)>



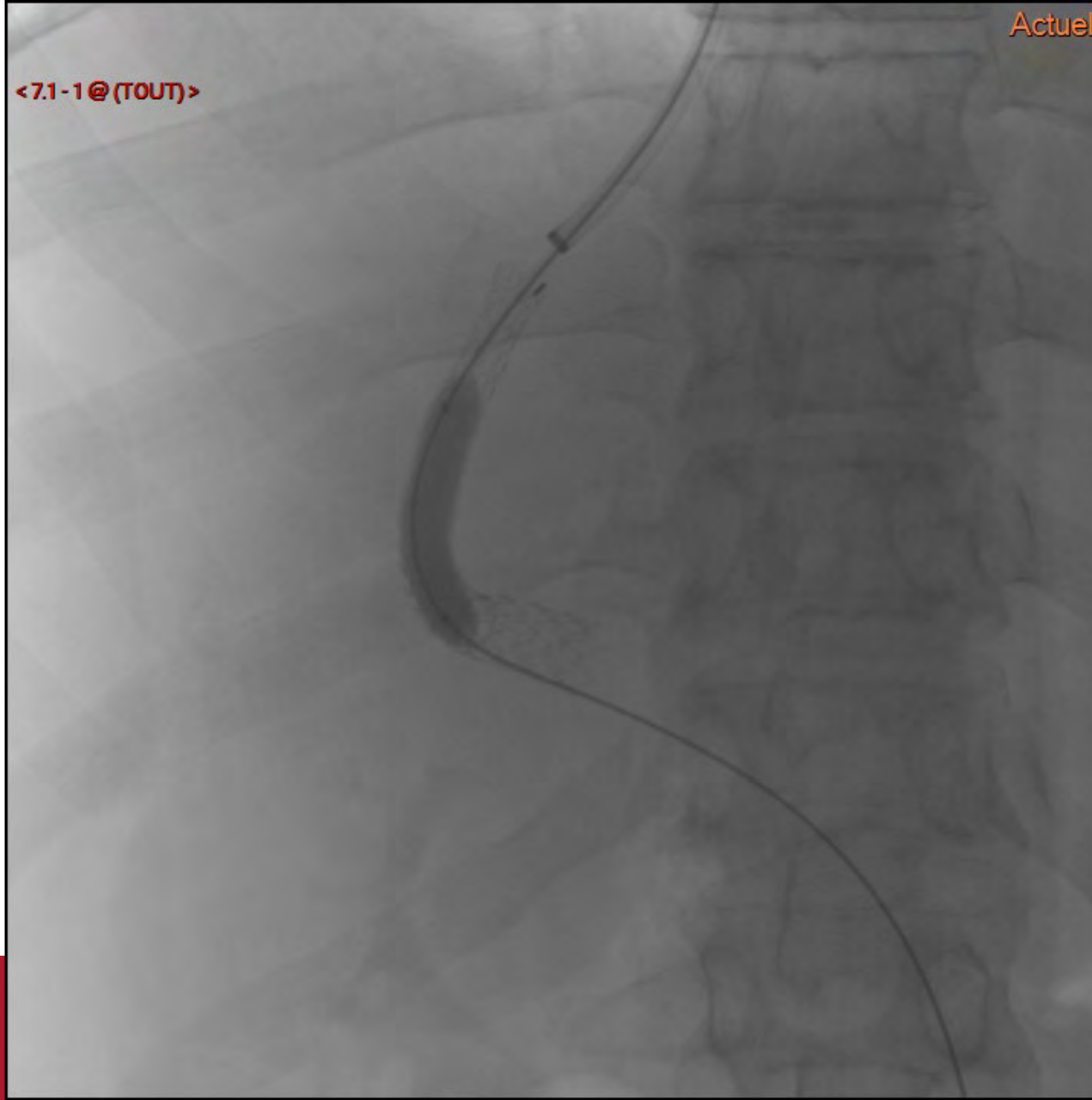
<6.1-17@ (TOUT)>



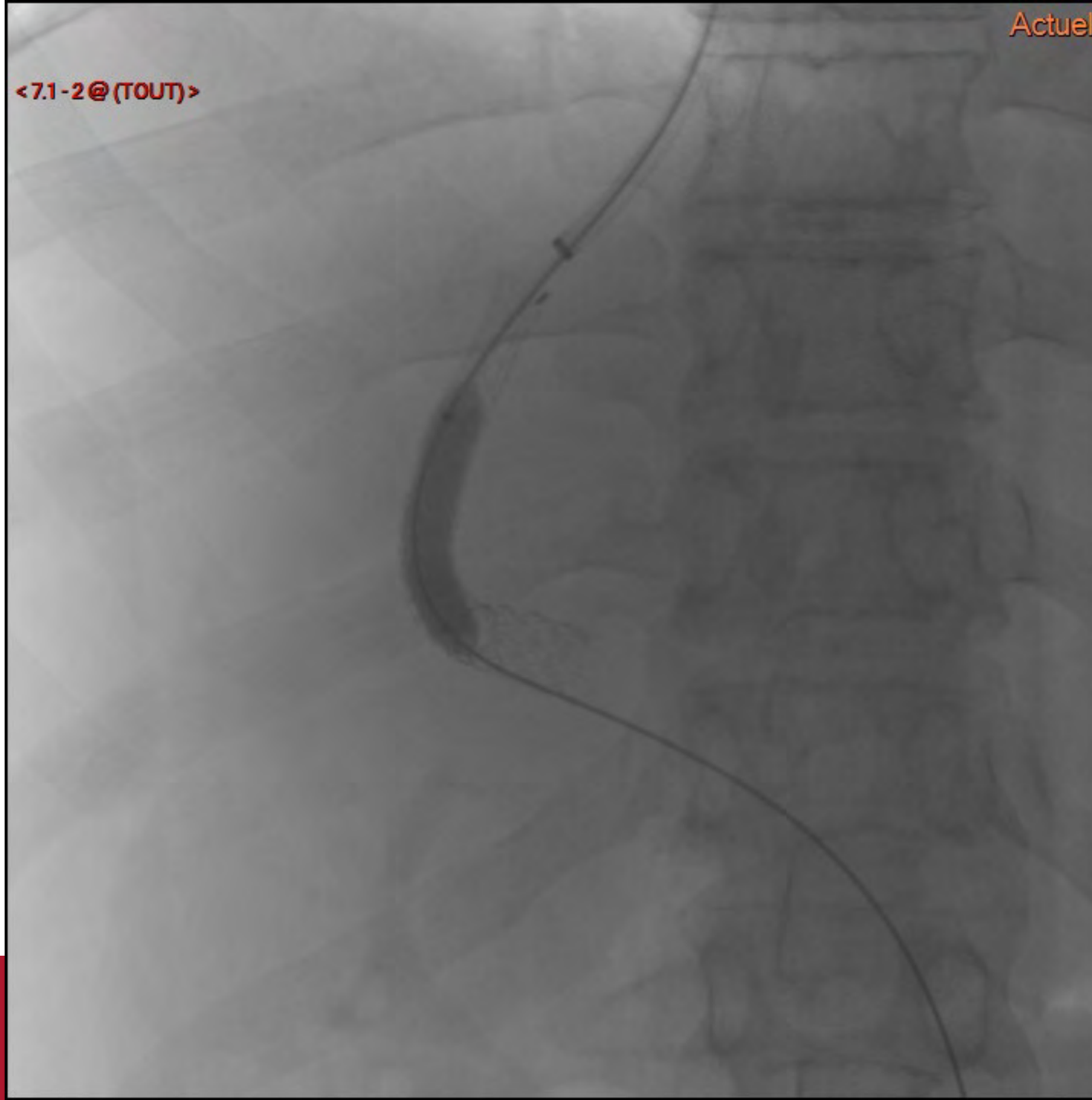
<6.1-18@ (TOUT)>



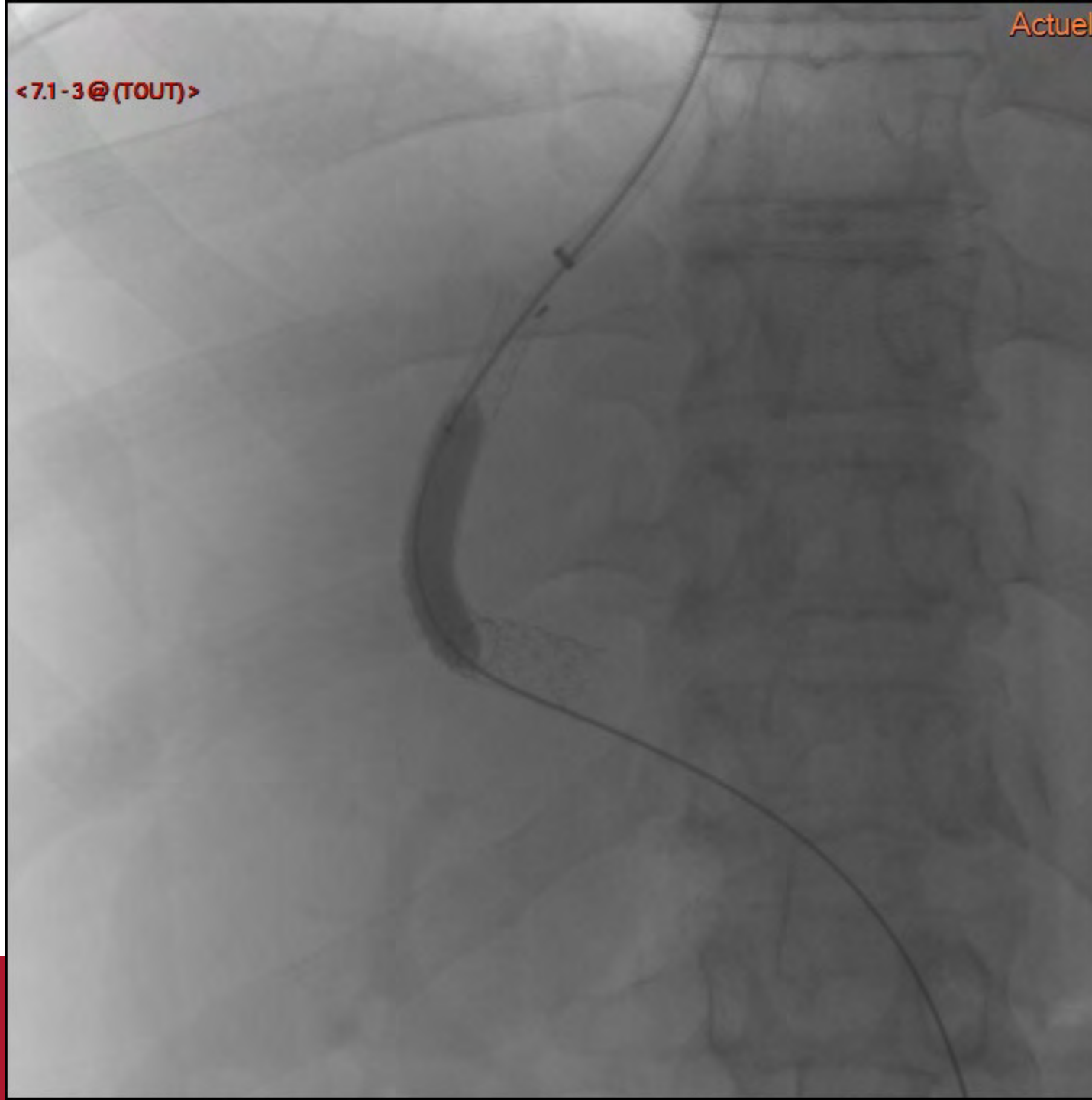
<7.1-1@ (TOUT)>



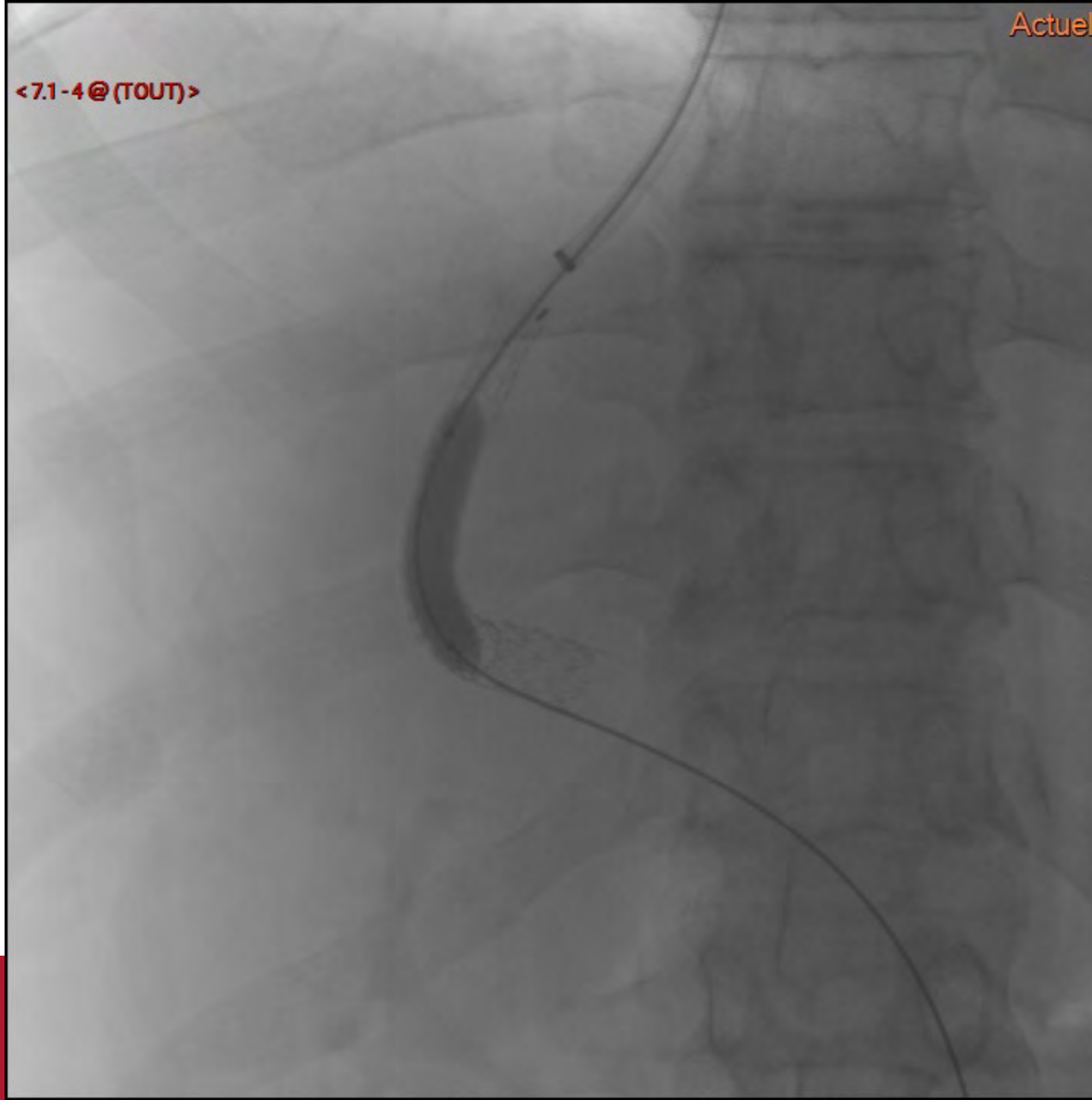
<7.1-2@(TOUT)>



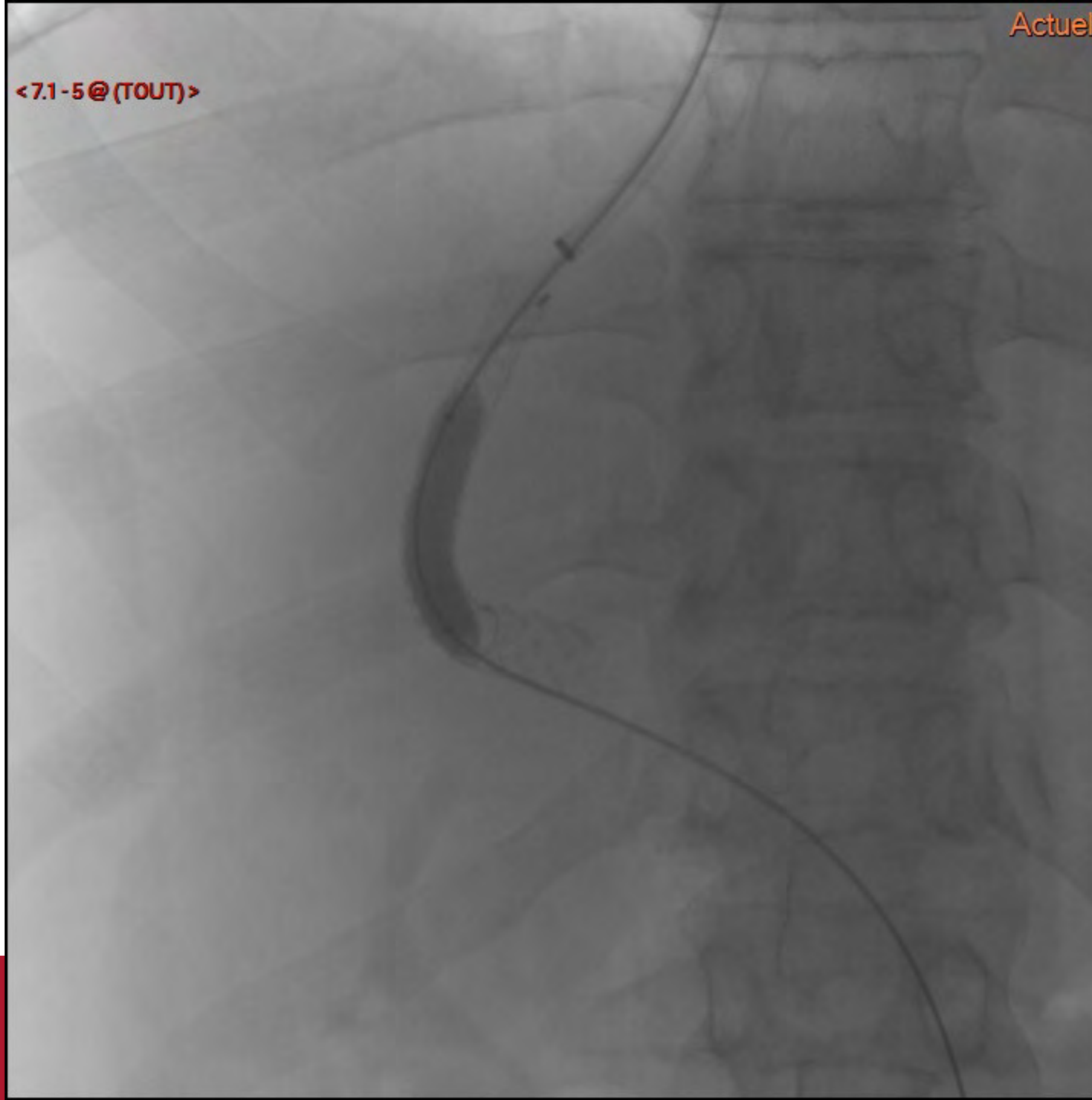
<7.1-3@ (TOU7)>



<7.1-4@ (TOUT)>



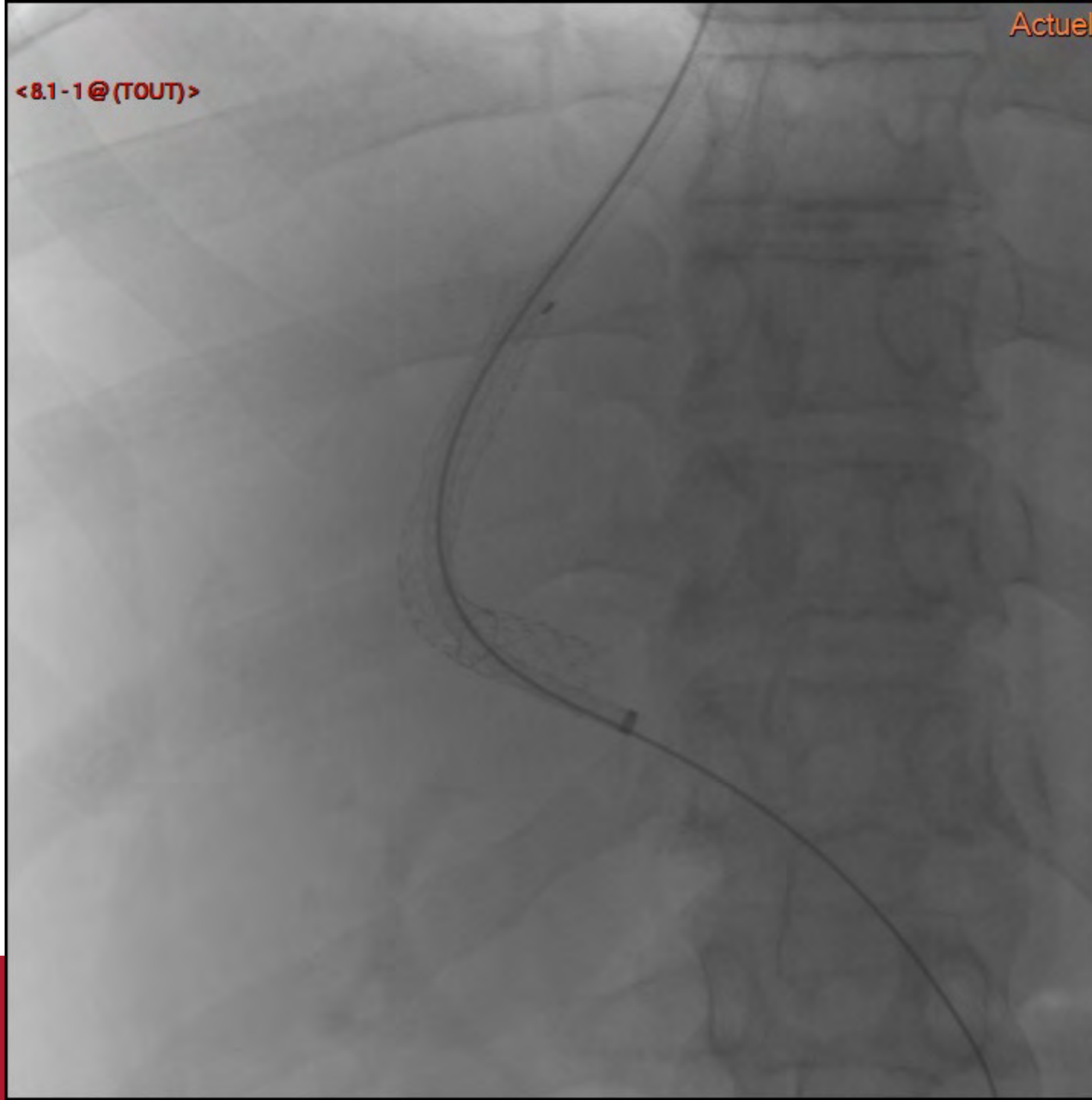
<7.1-5@ (TOUT)>



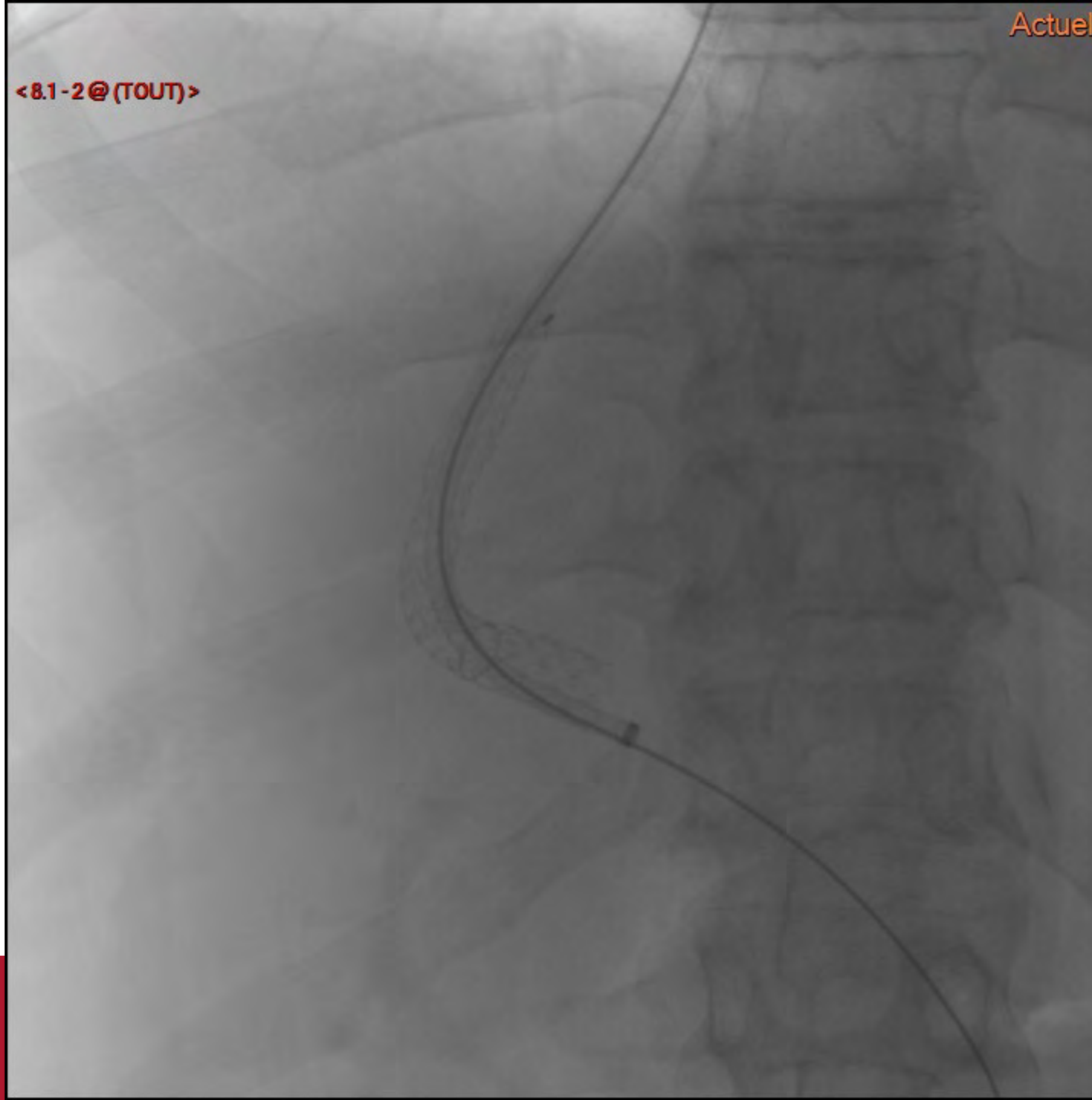
<7.1-6@(TOUT)>

Ballon de 8 mm

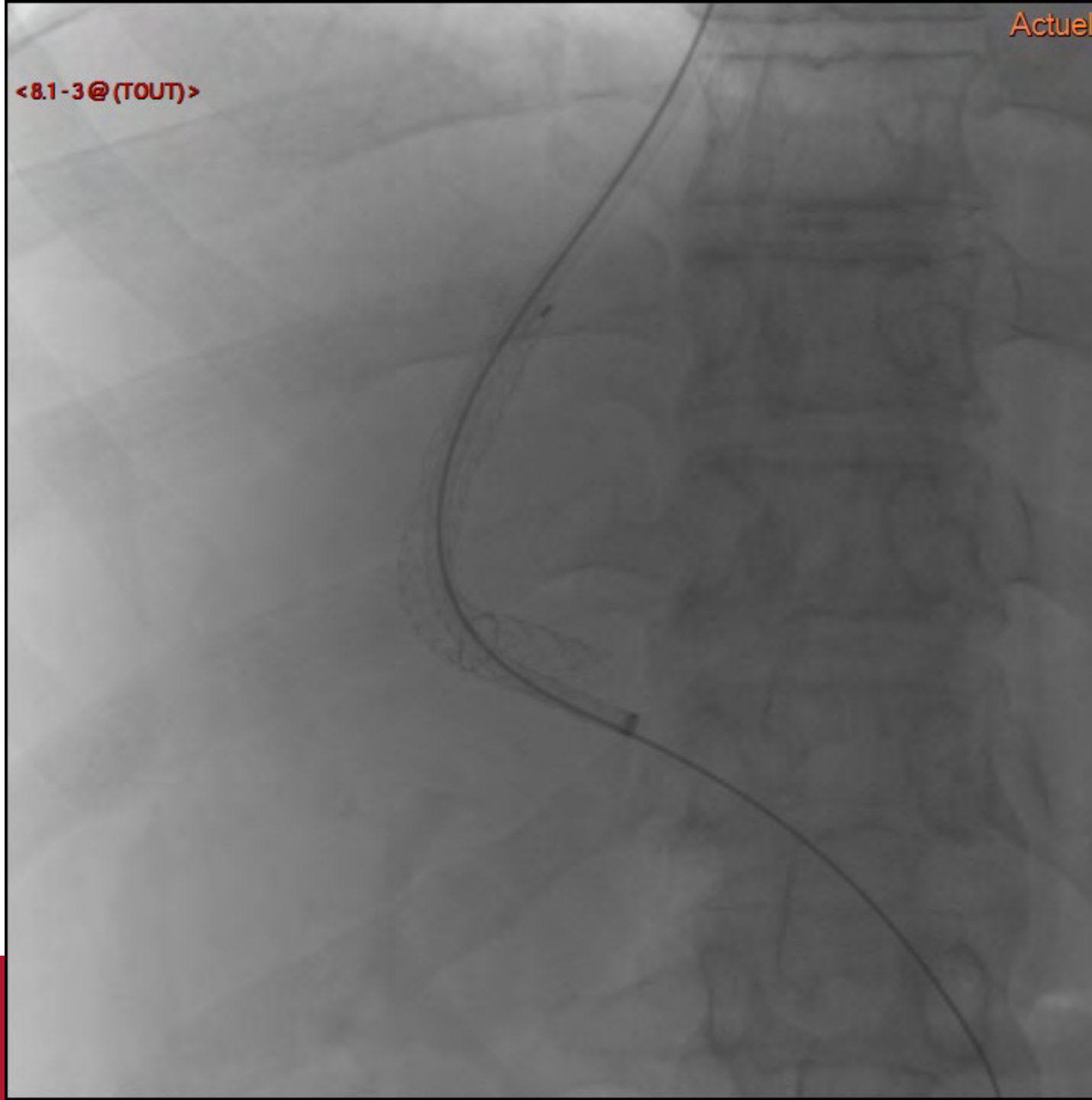
<8.1-1@ (TOUT)>



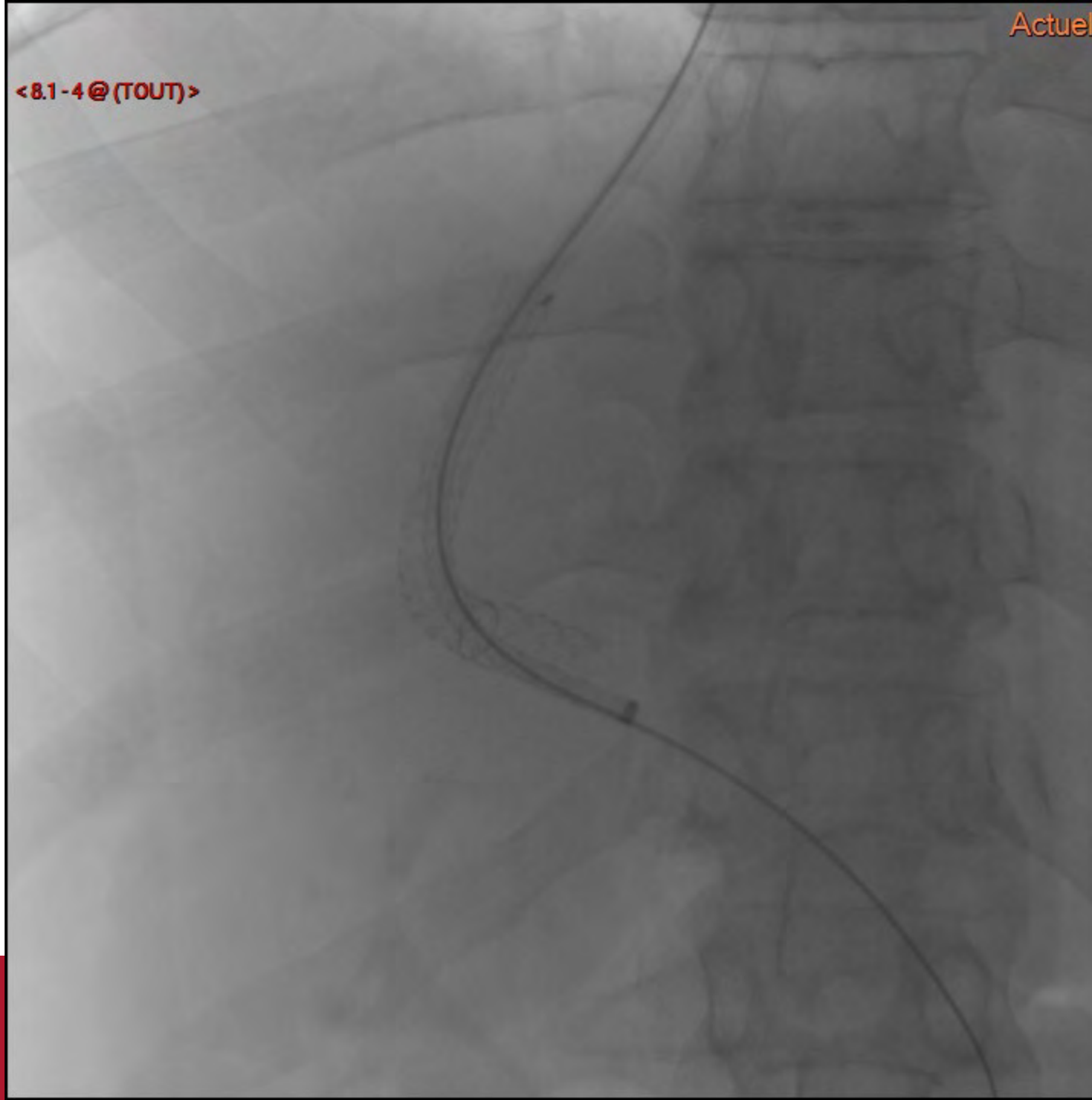
<8.1-2@ (TOUT)>



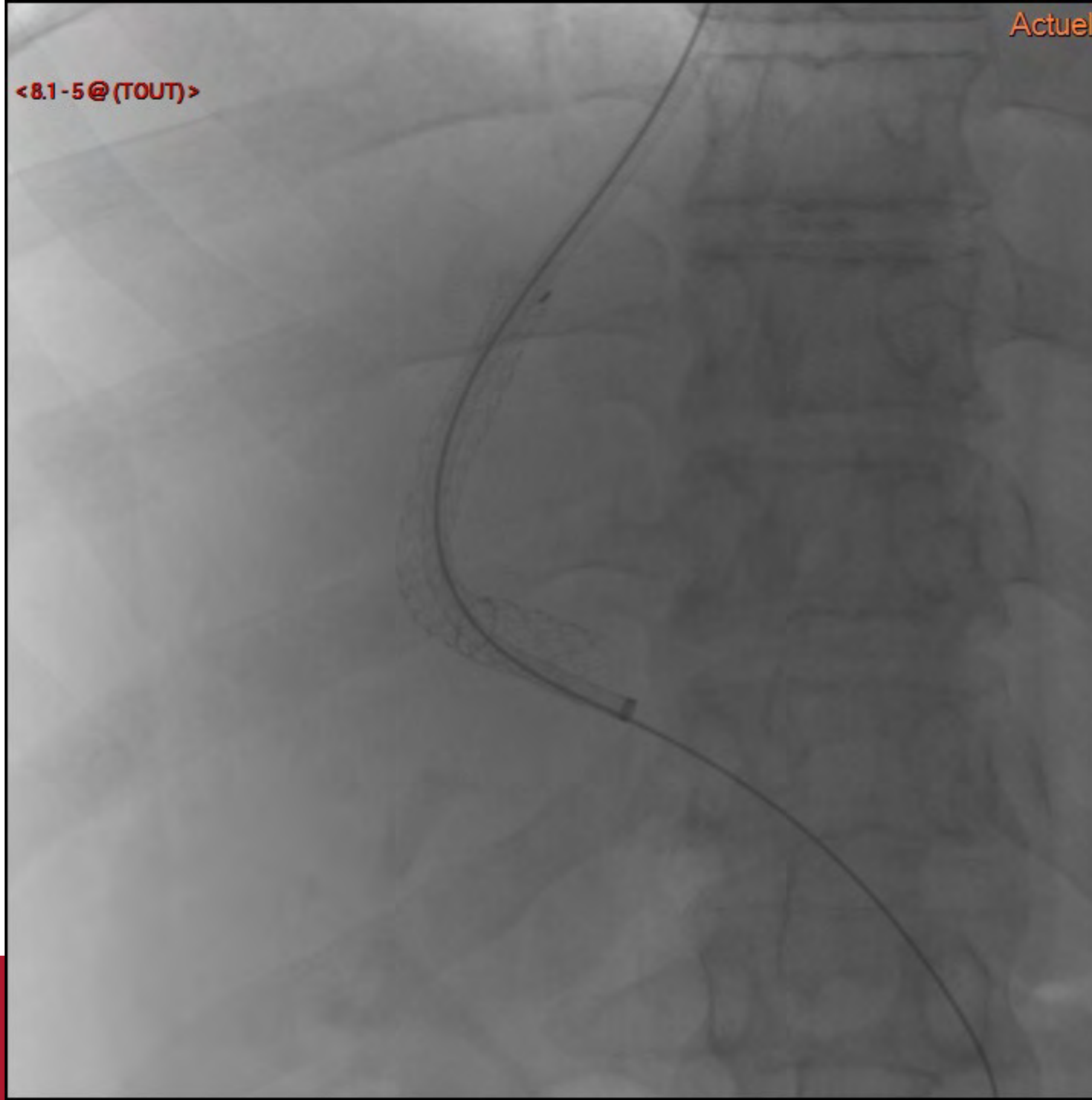
<8.1-3@ (TOU7)>



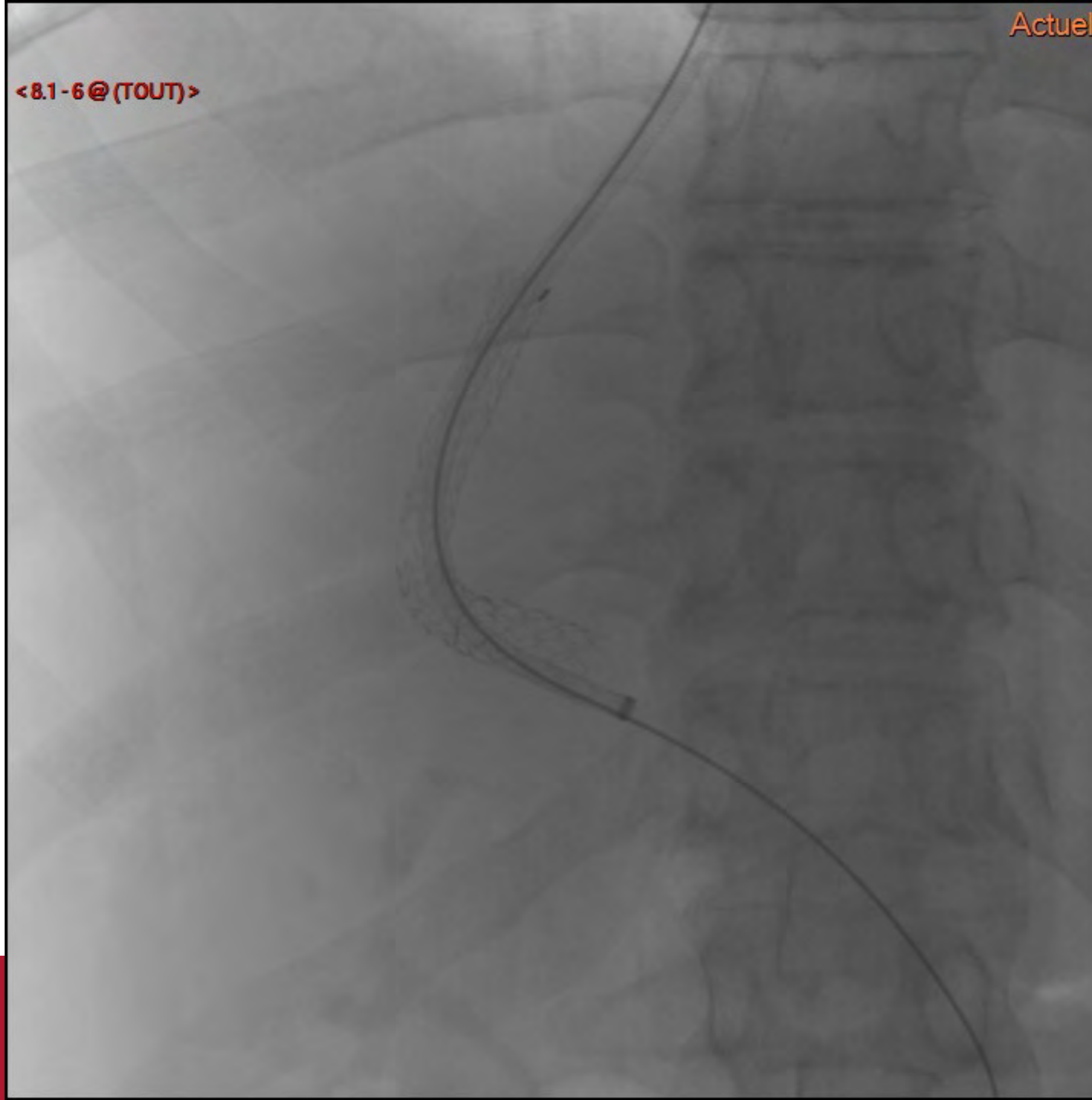
<8.1-4@ (TOUT)>



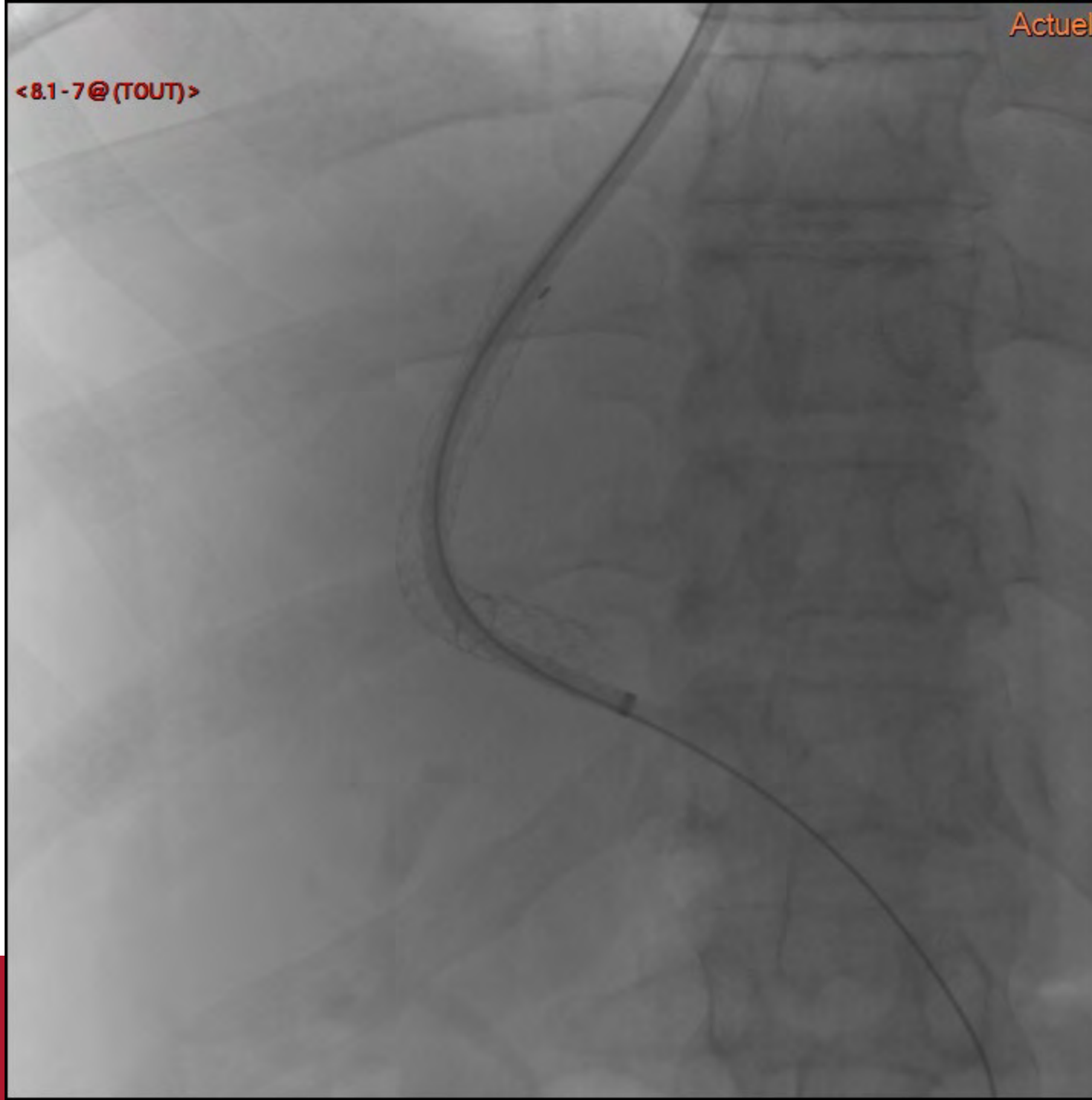
<8.1-5@ (TOUT)>



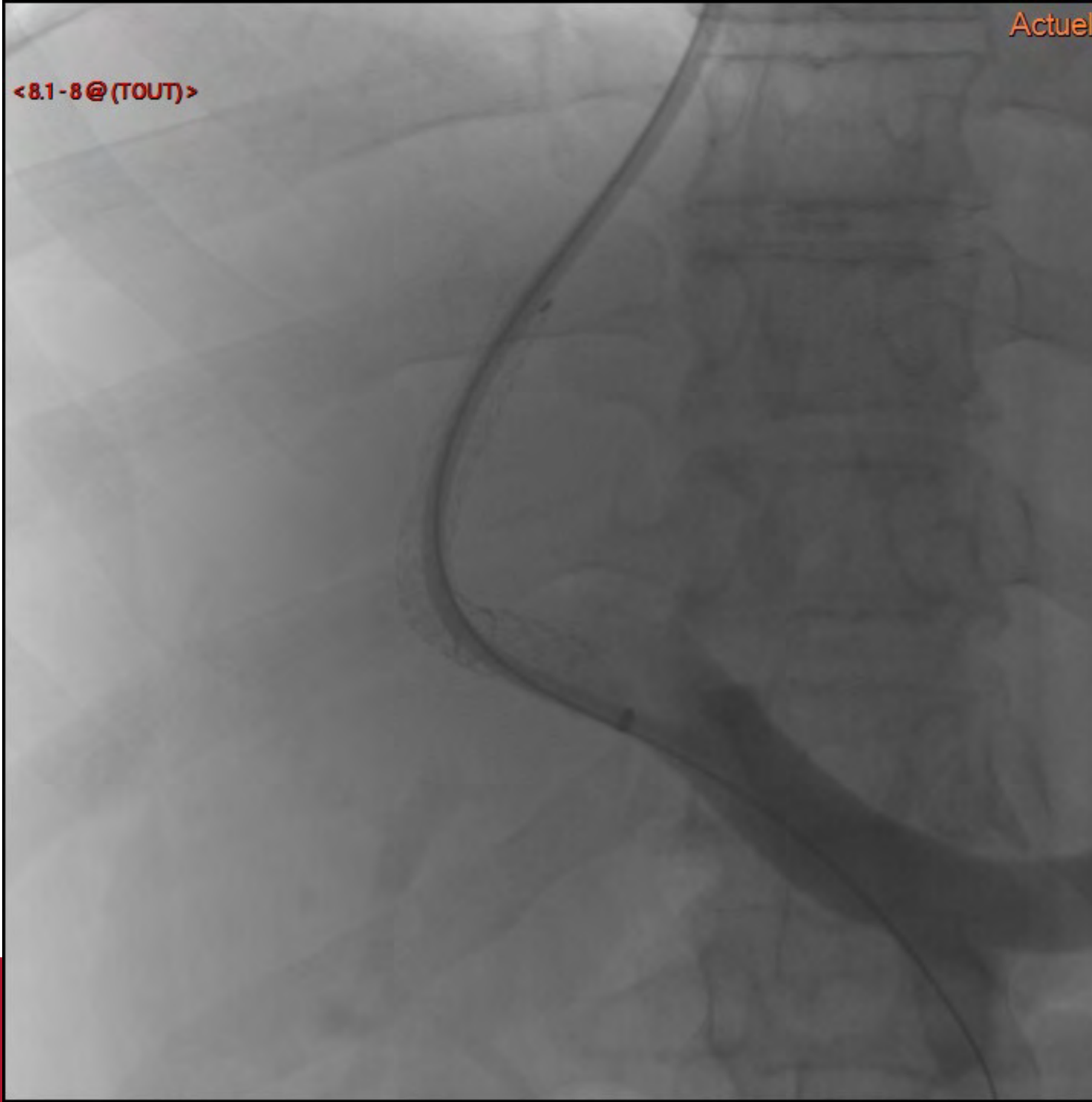<8.1-6@ (TOUT)>



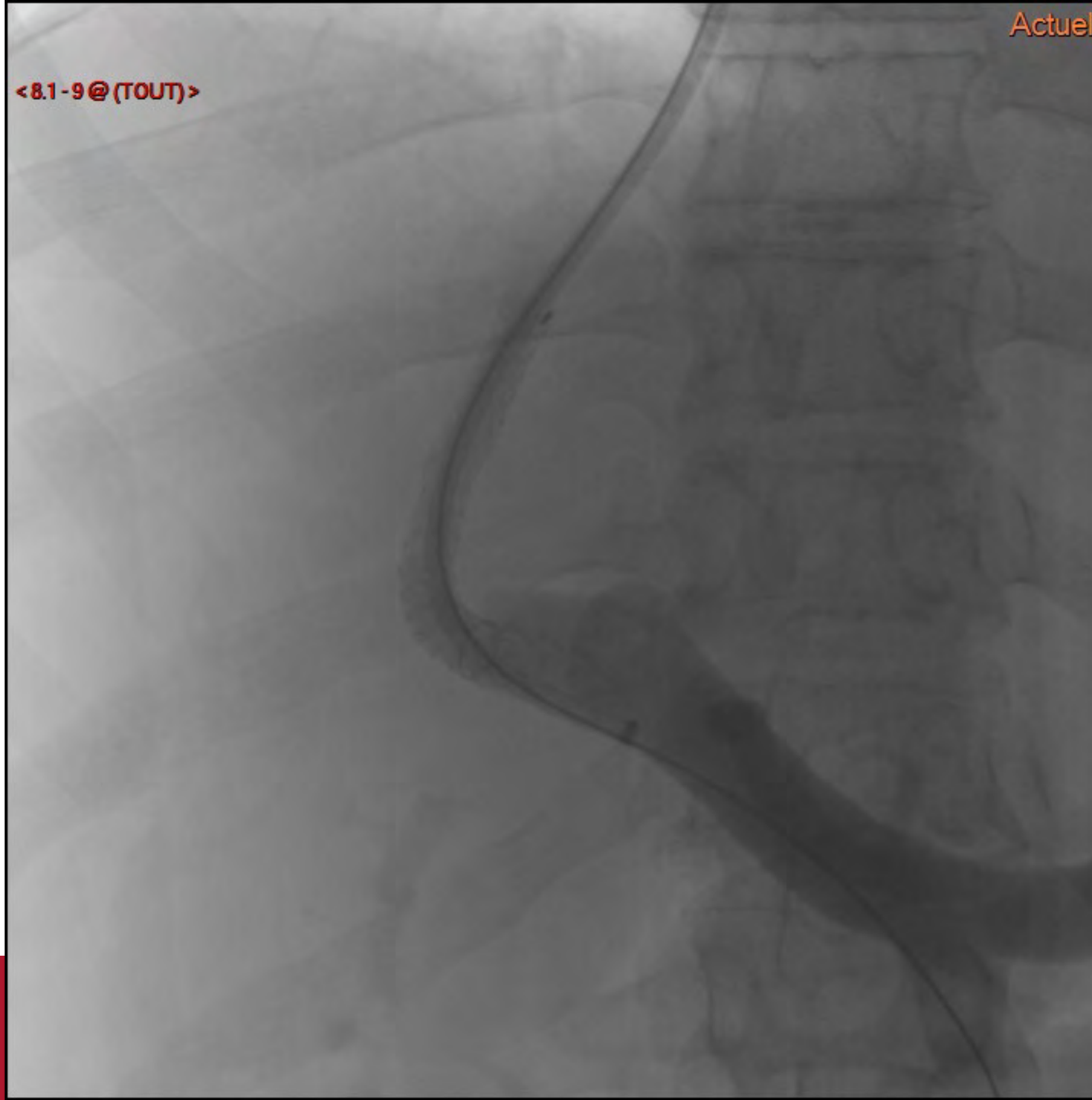
<8.1-7@ (TOUT)>



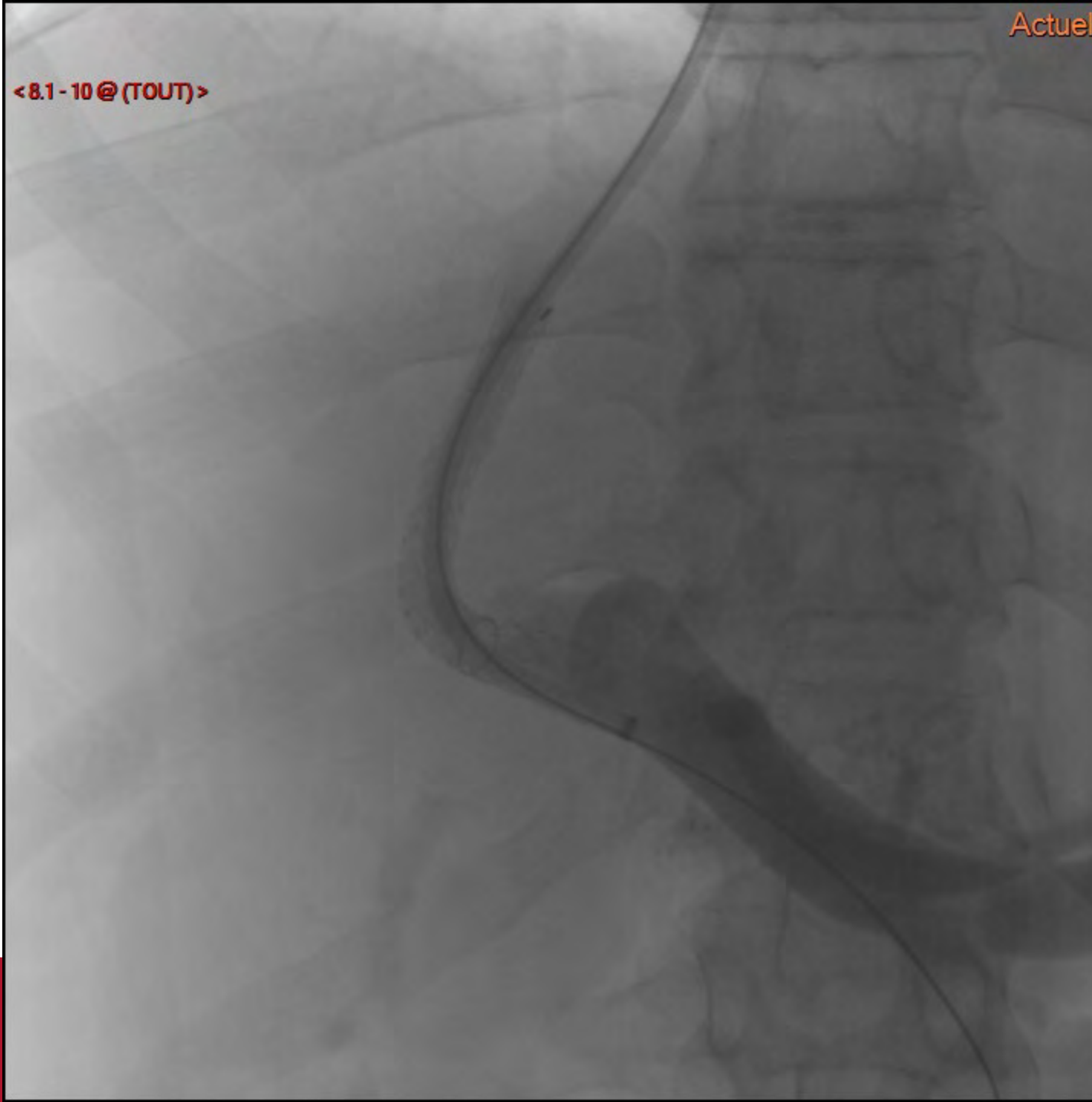
<8.1-8@TOUT>



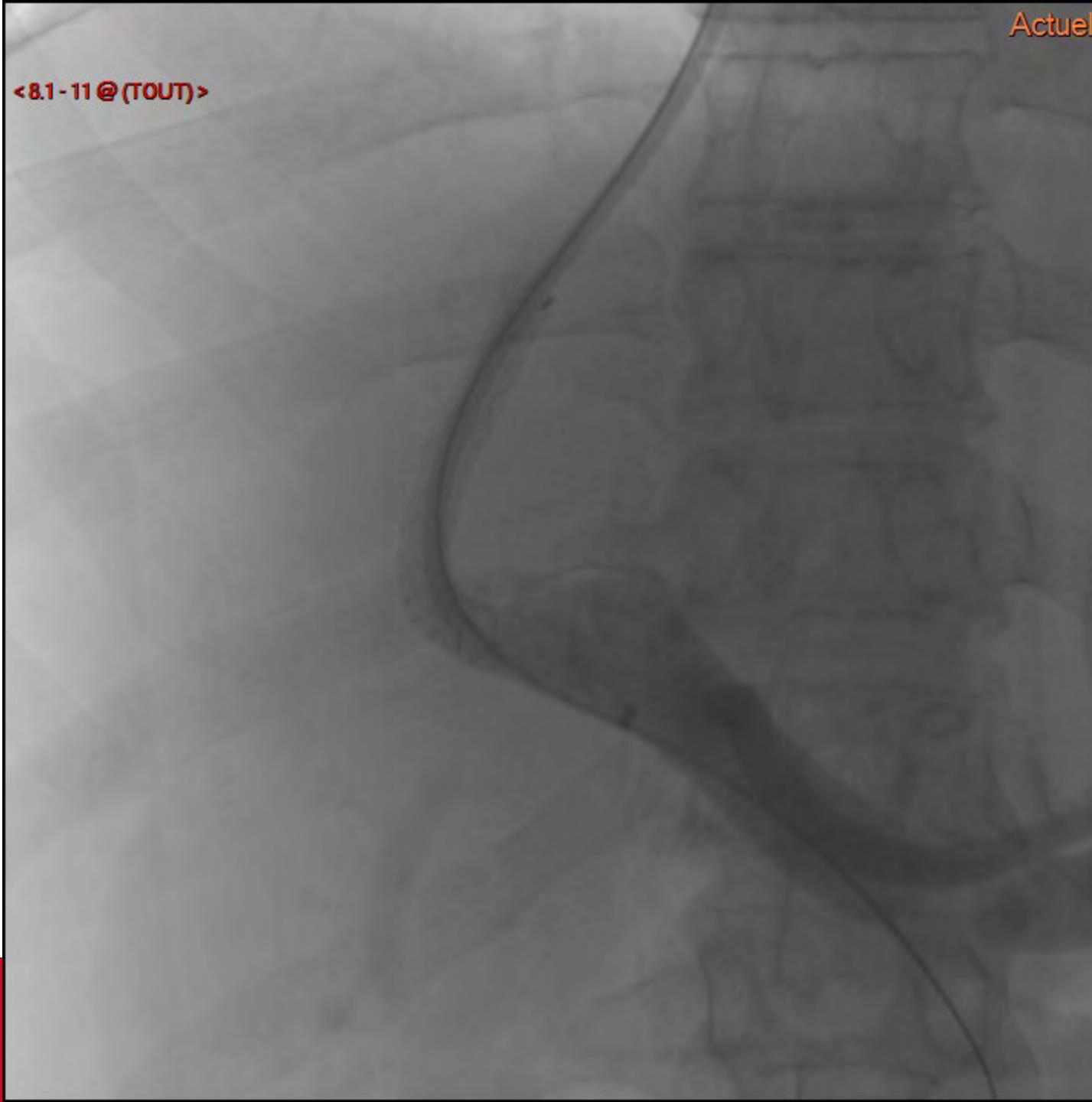<8.1-9@ (TOU) >



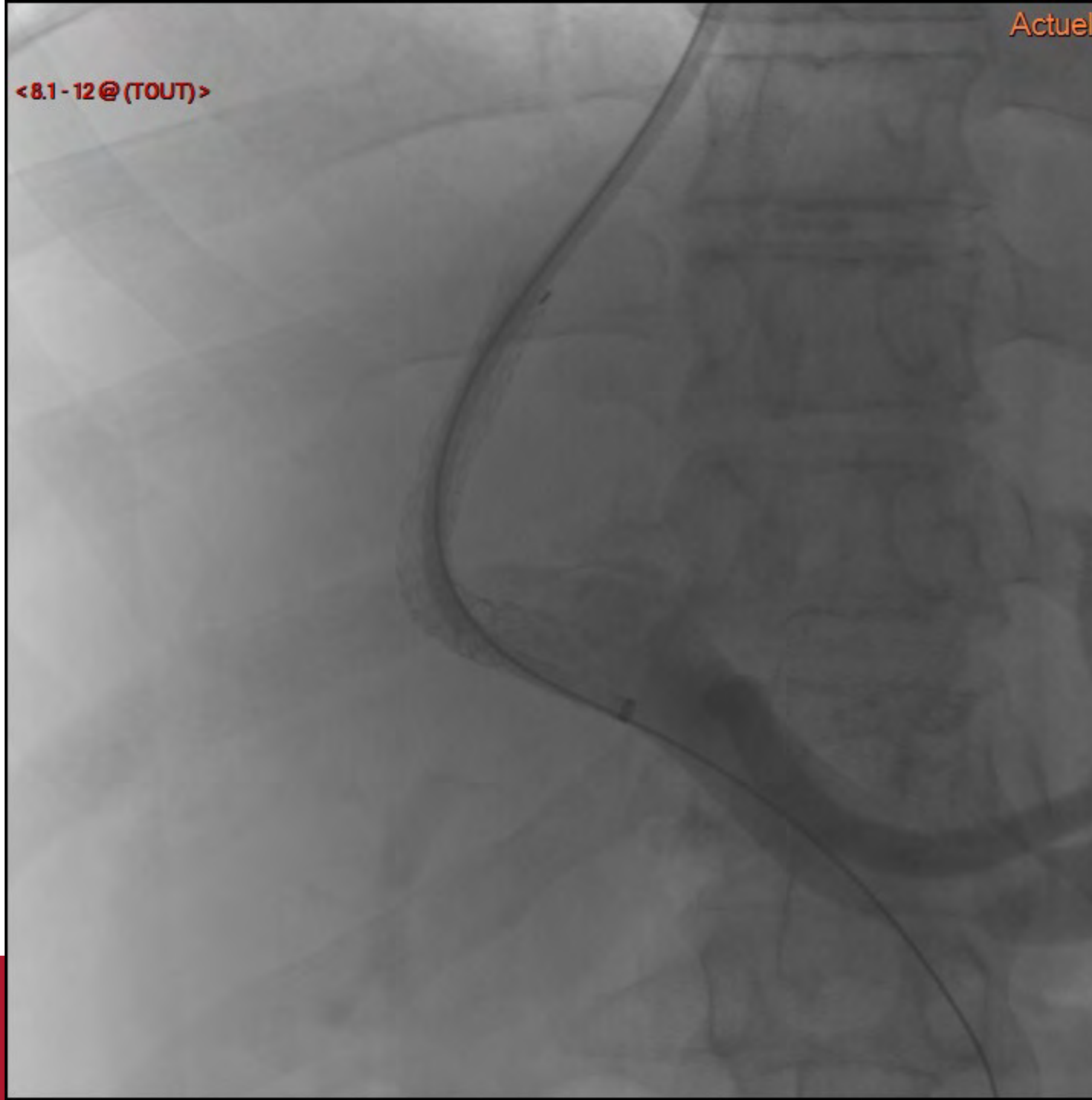
< 8.1 - 10 @ (TOUT) >



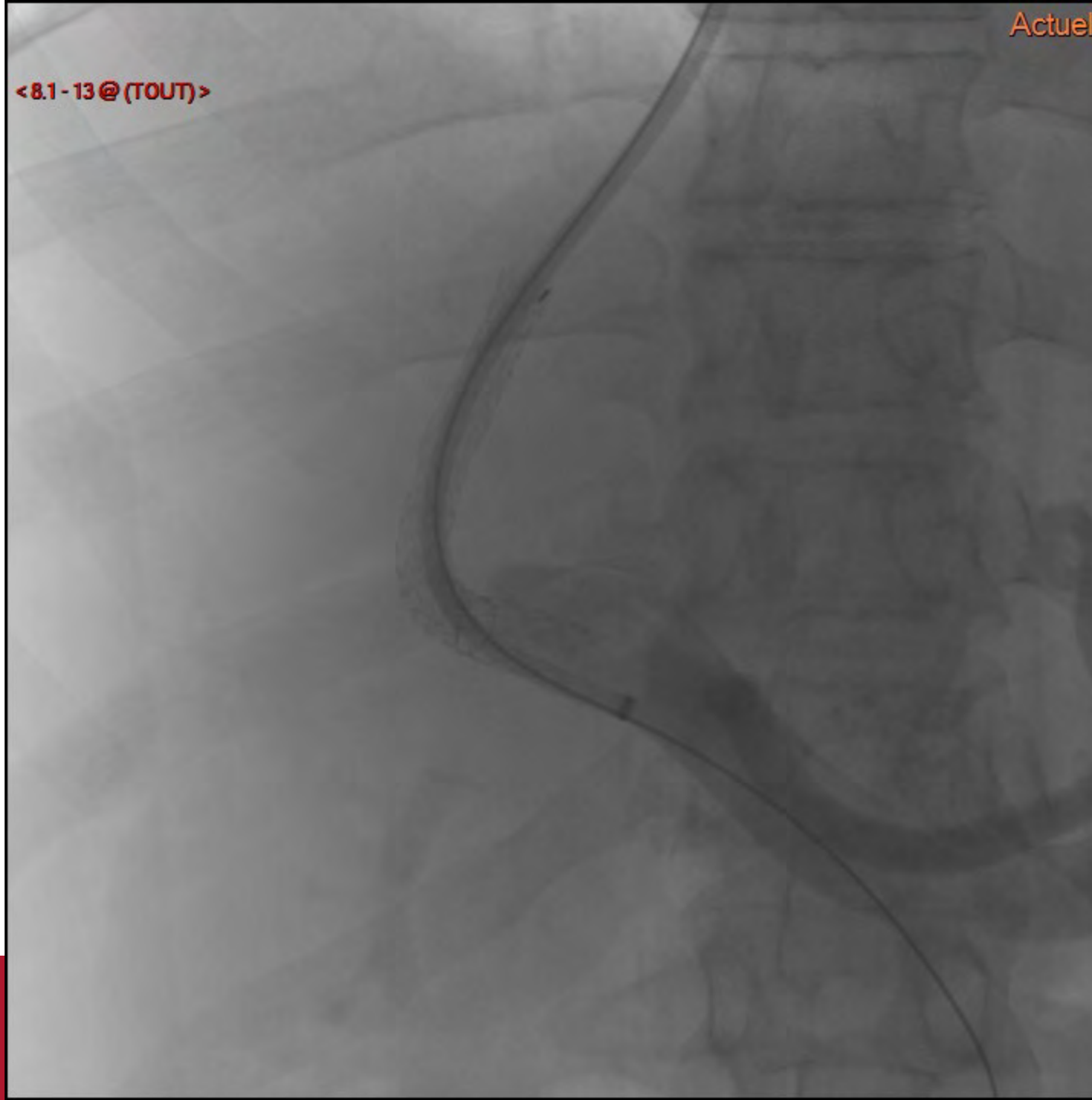
<8.1-11 @ (TOUT)>



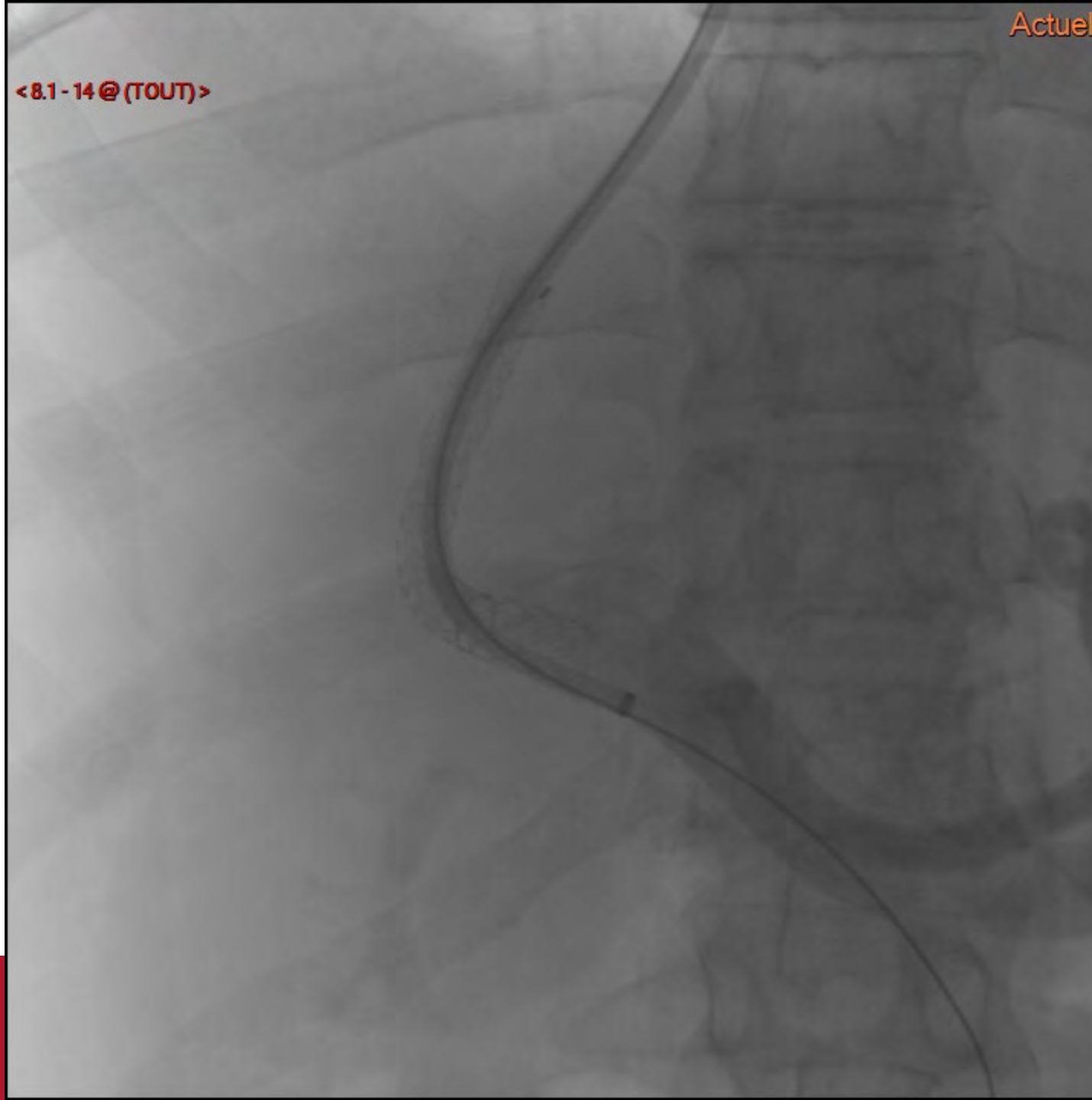
< 8.1 - 12 @ (TOUT) >



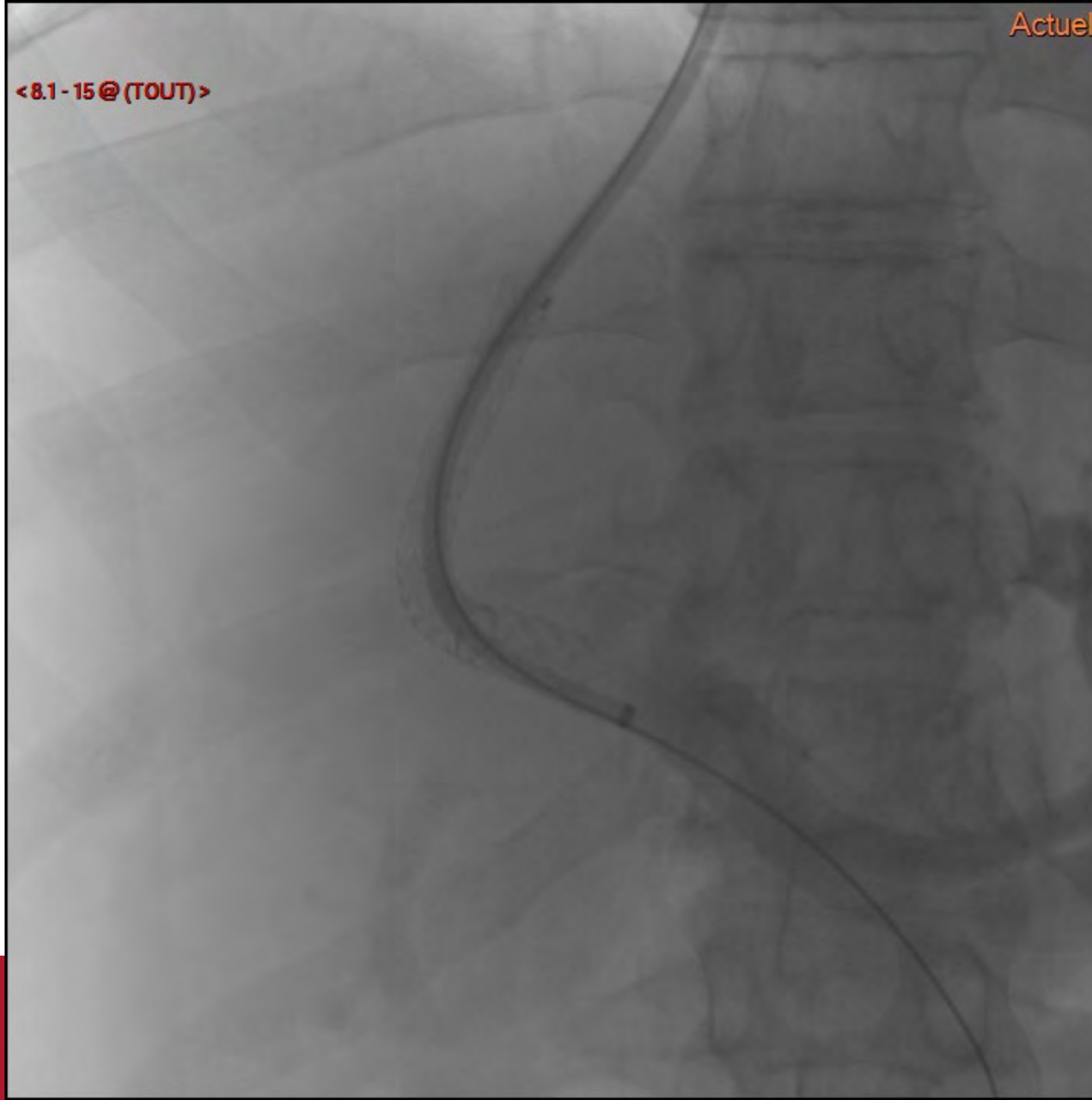
< 8.1 - 13 @ (TOUT) >



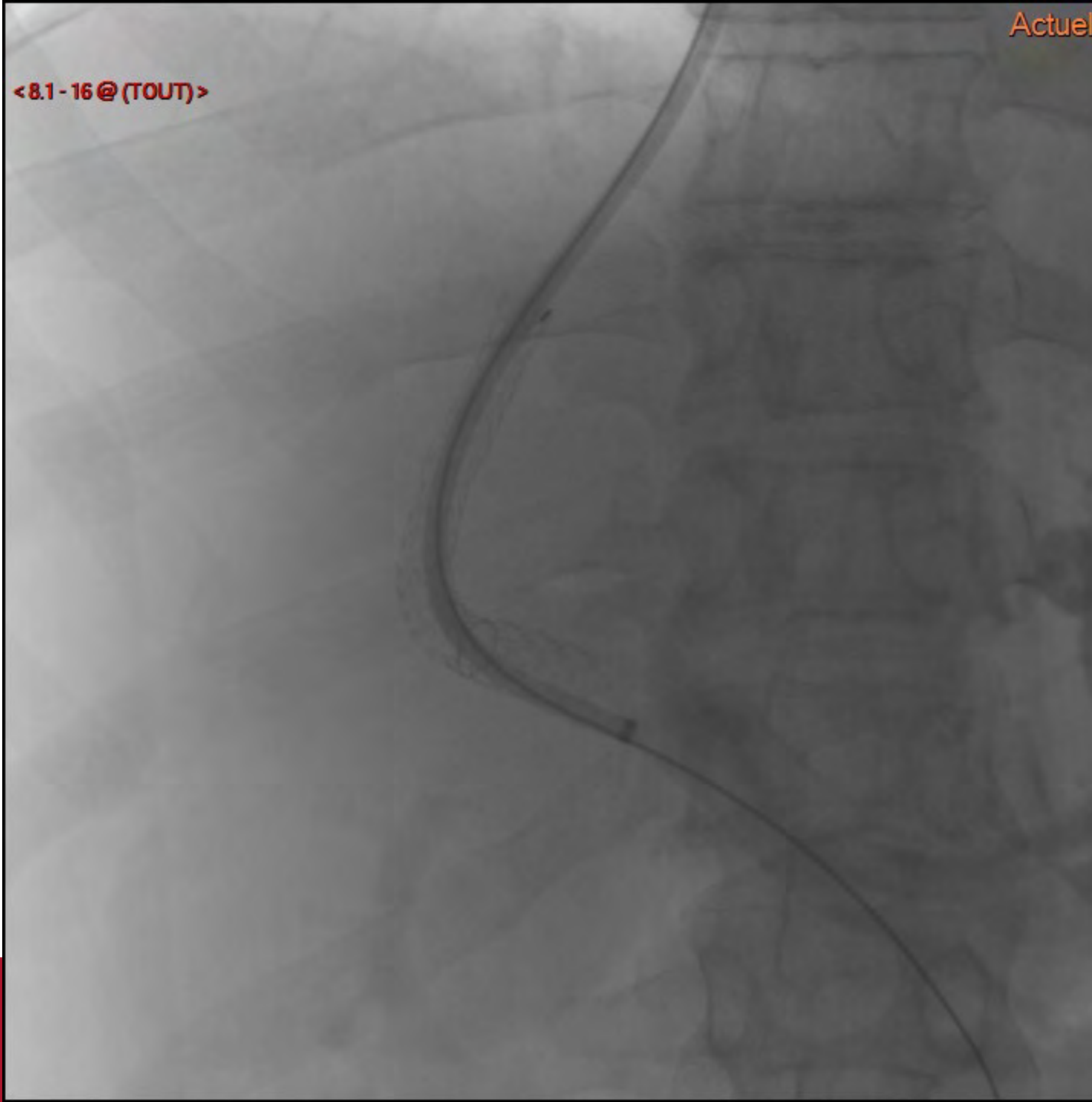
<8.1-14@ (TOUT)>



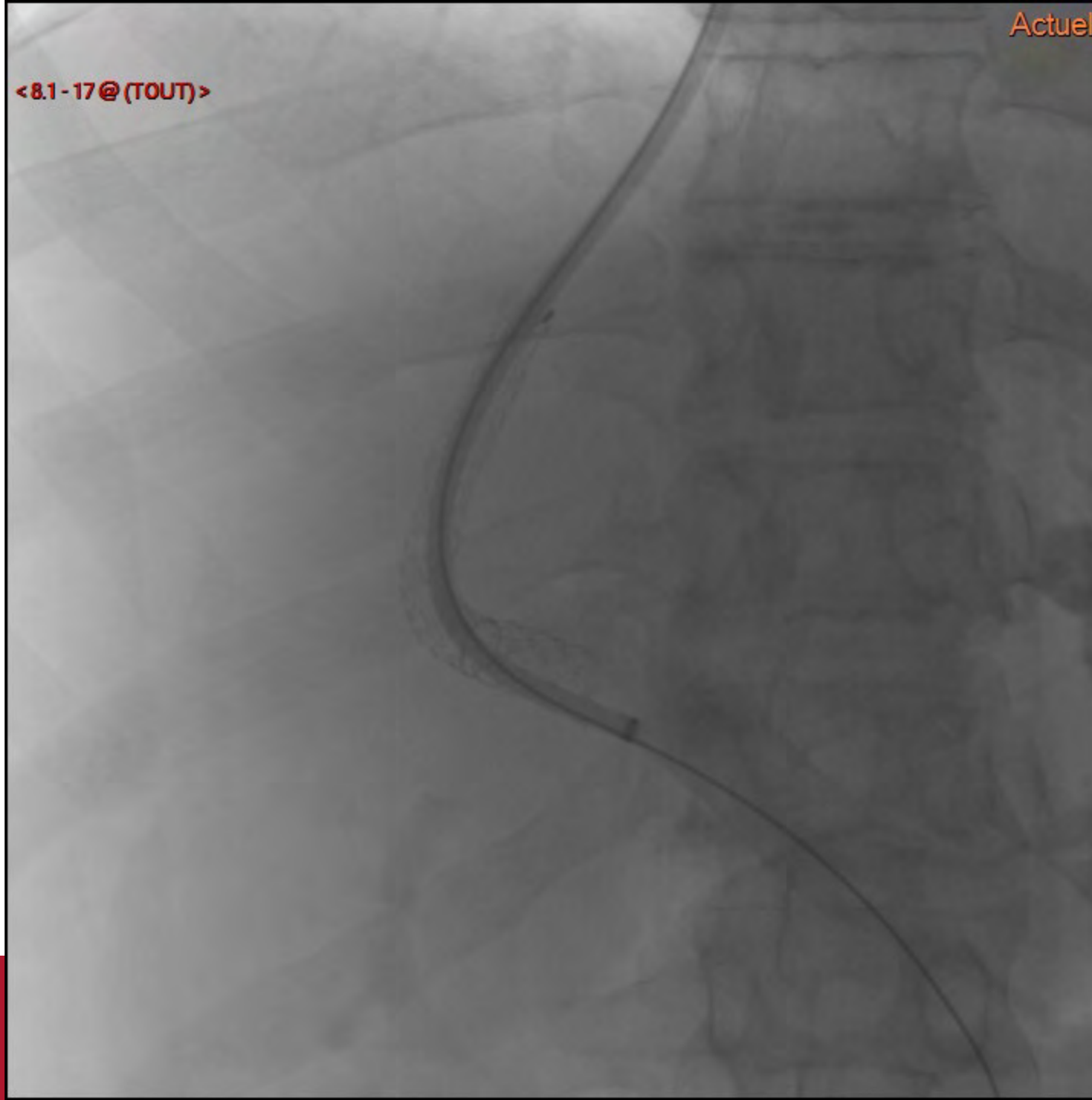
< 8.1 - 15 @ (TOUT) >



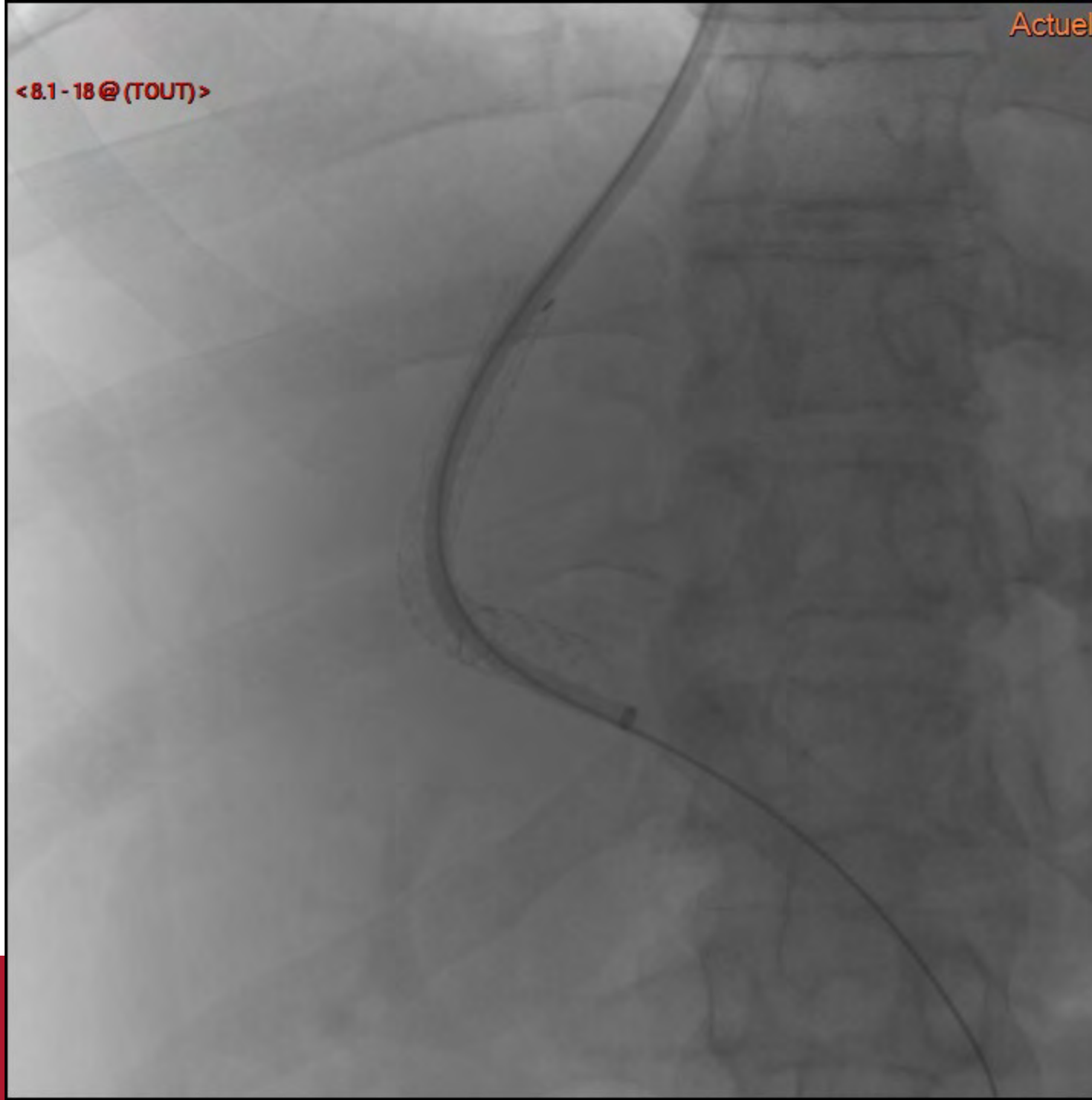<8.1-16@ (TOUT)>



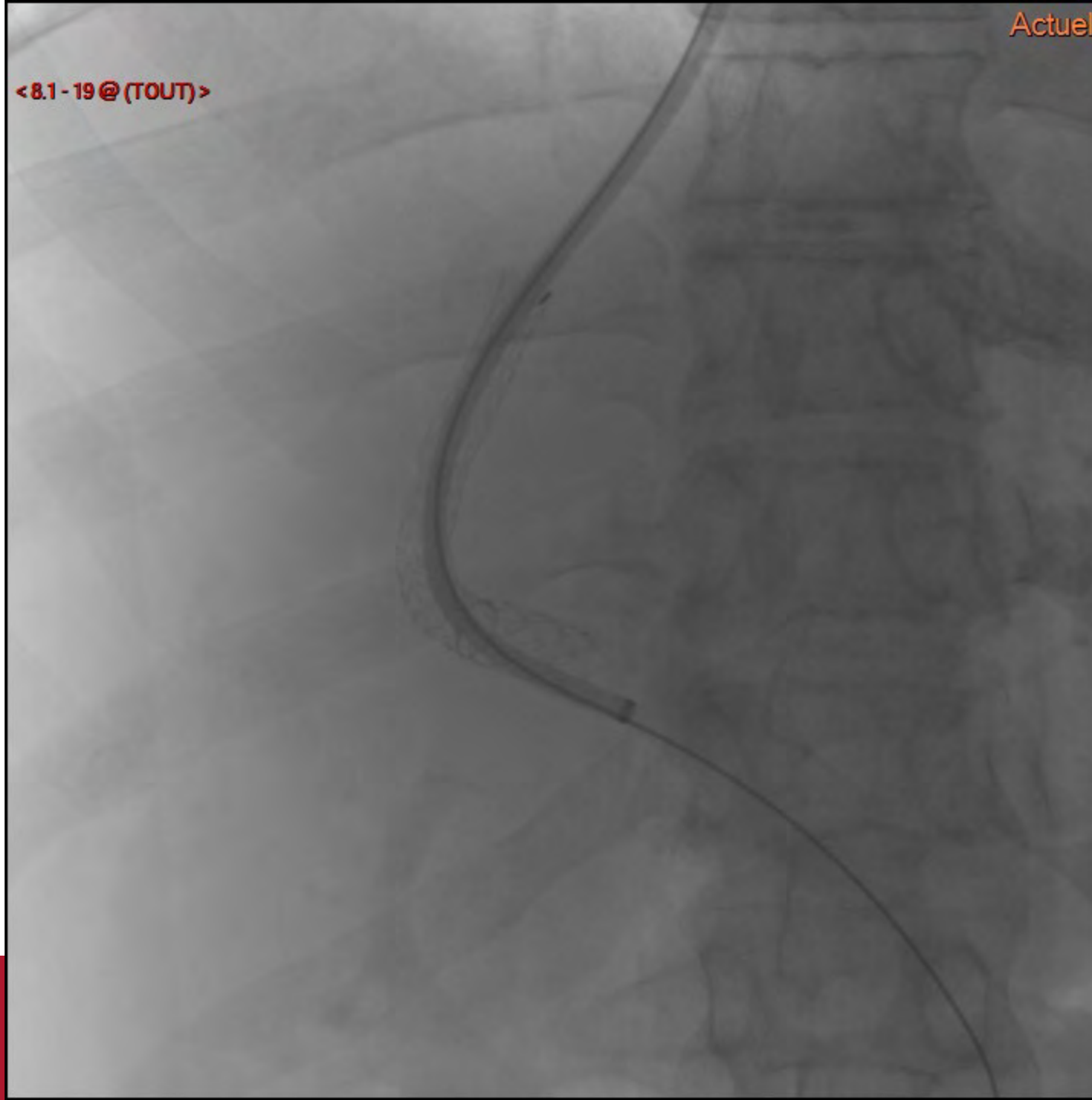
<8.1-17@ (TOUT)>



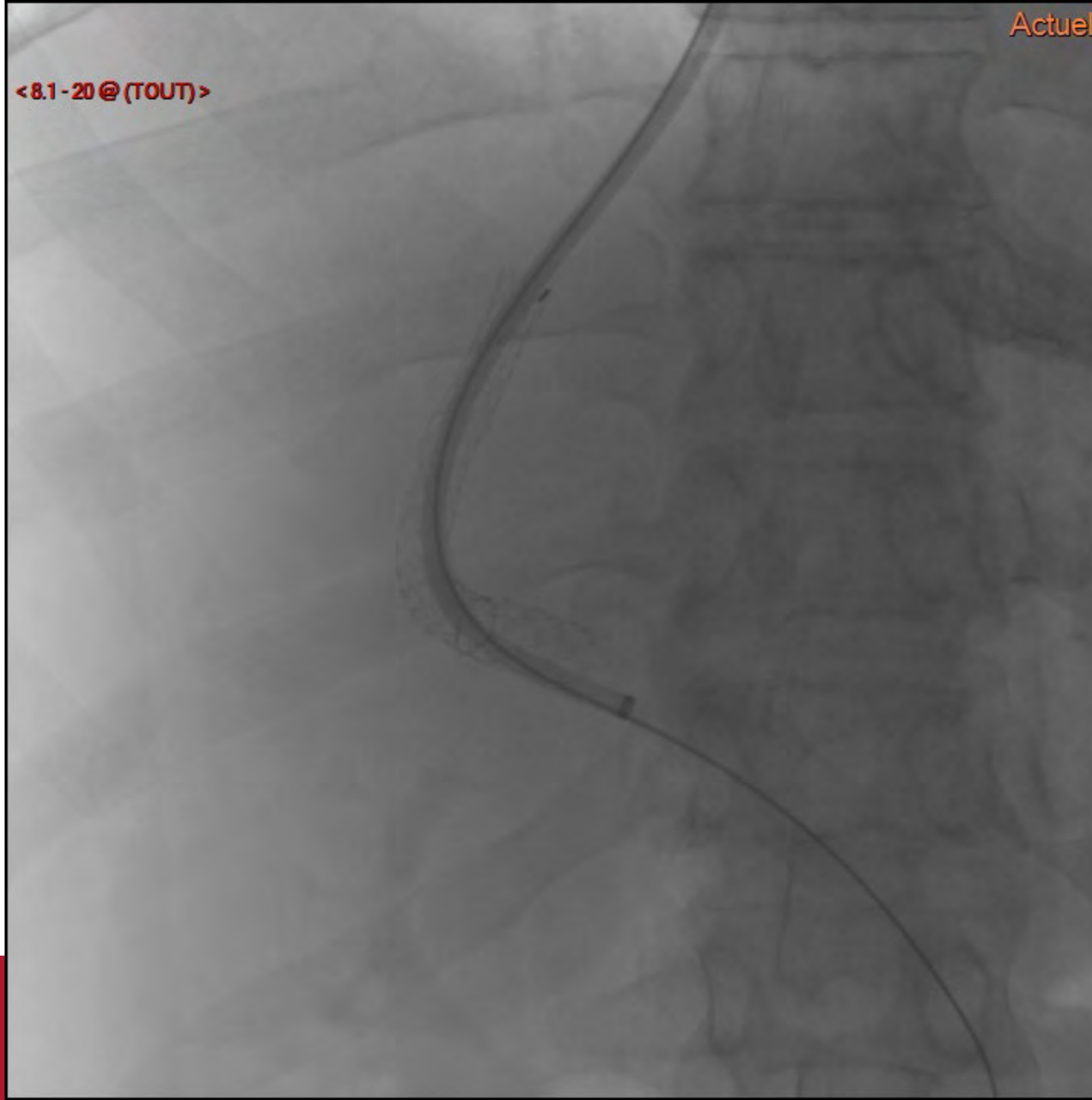
<8.1-18@TOUT>



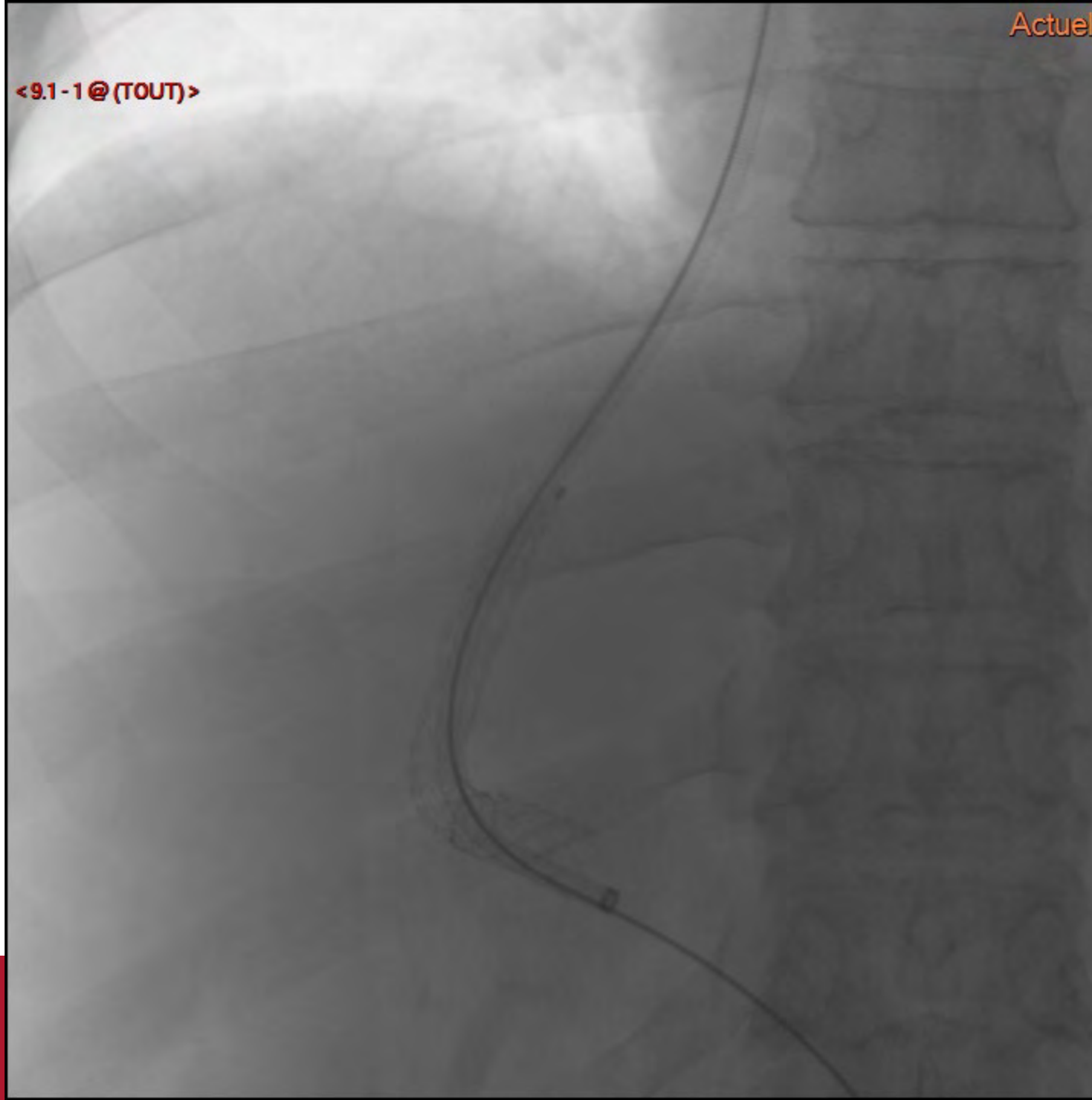
< 8.1 - 19 @ (TOUT) >



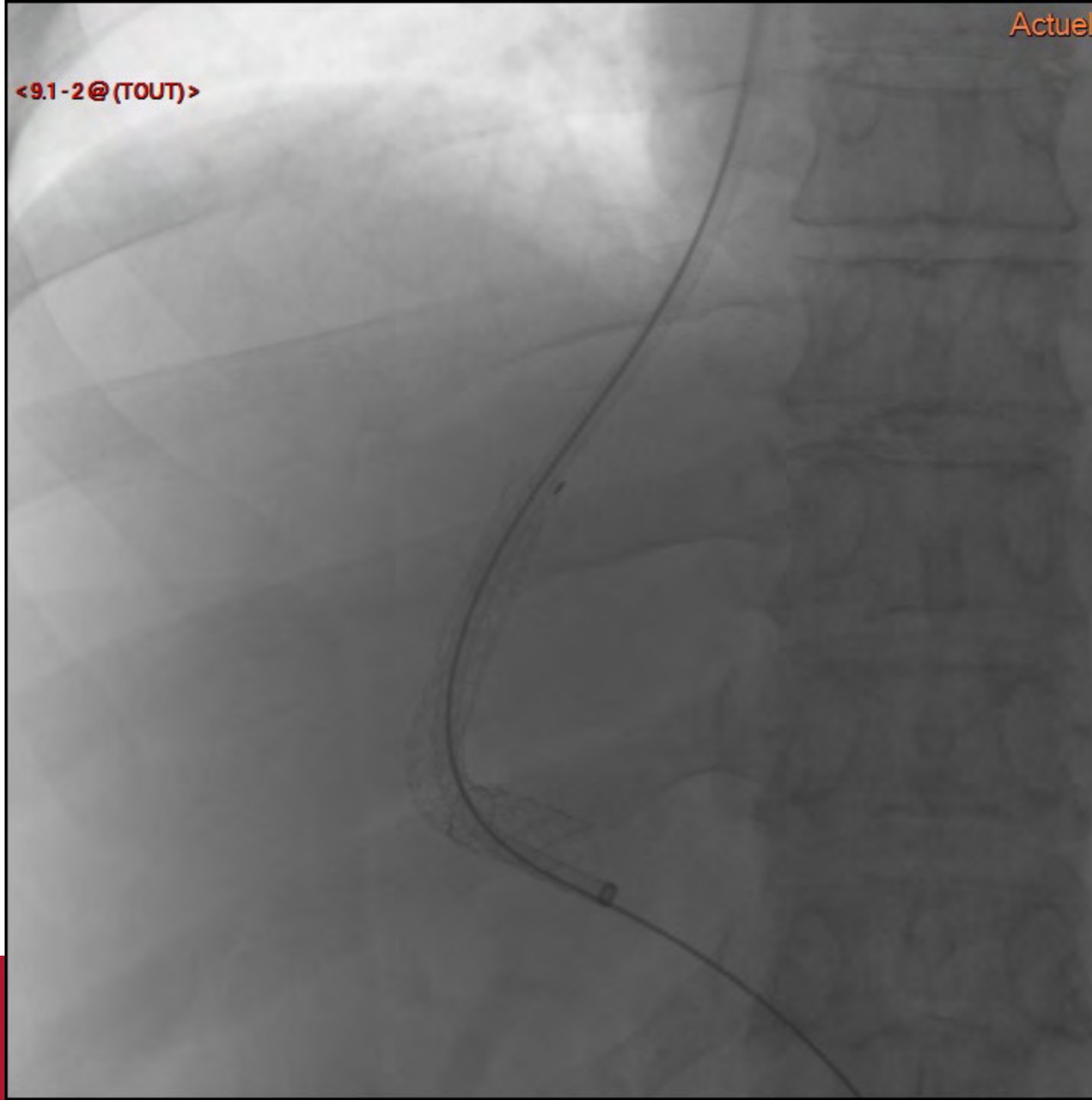
< 8.1-20@ (TOUT) >



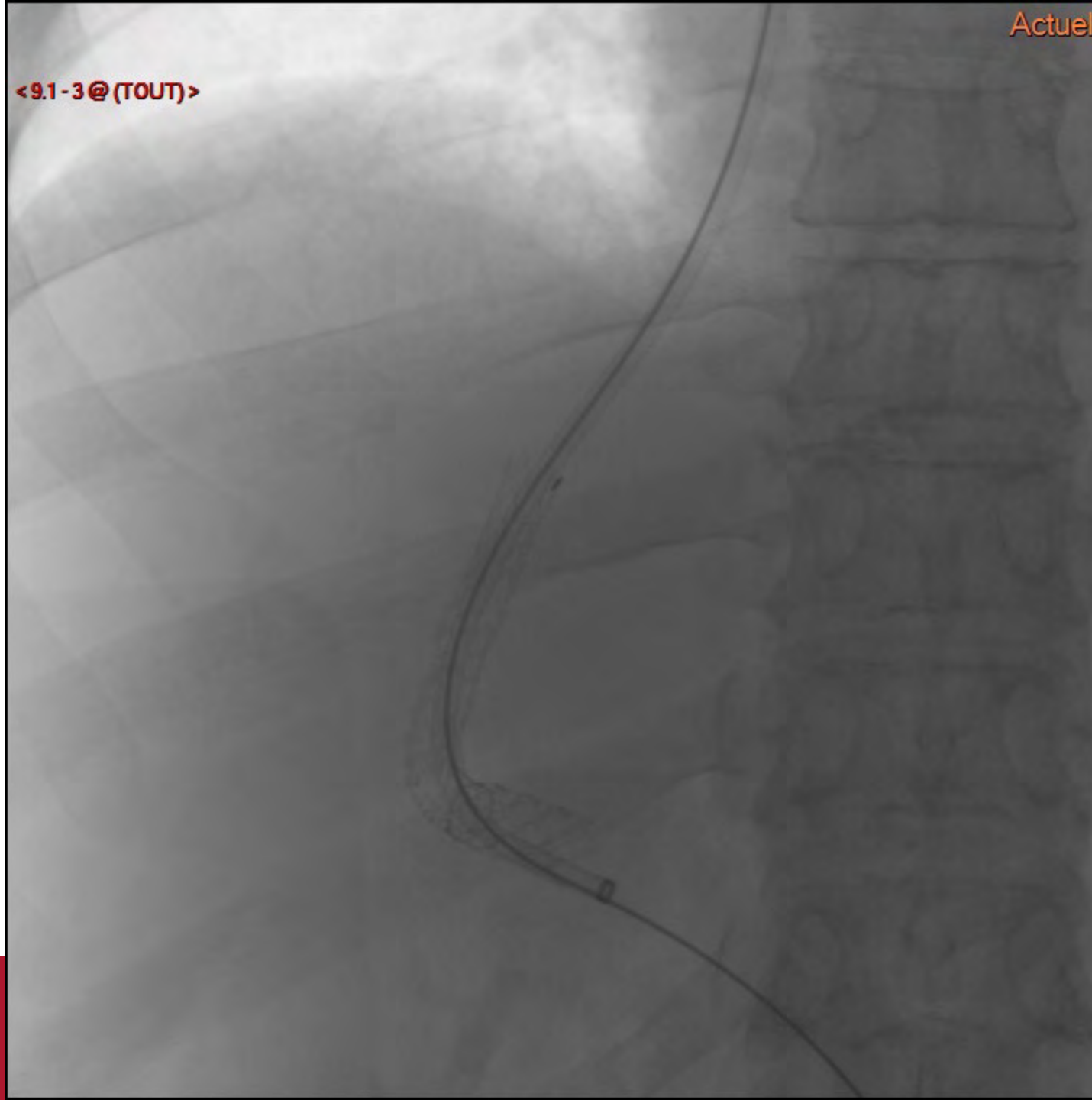
<9.1-1@TOUT>



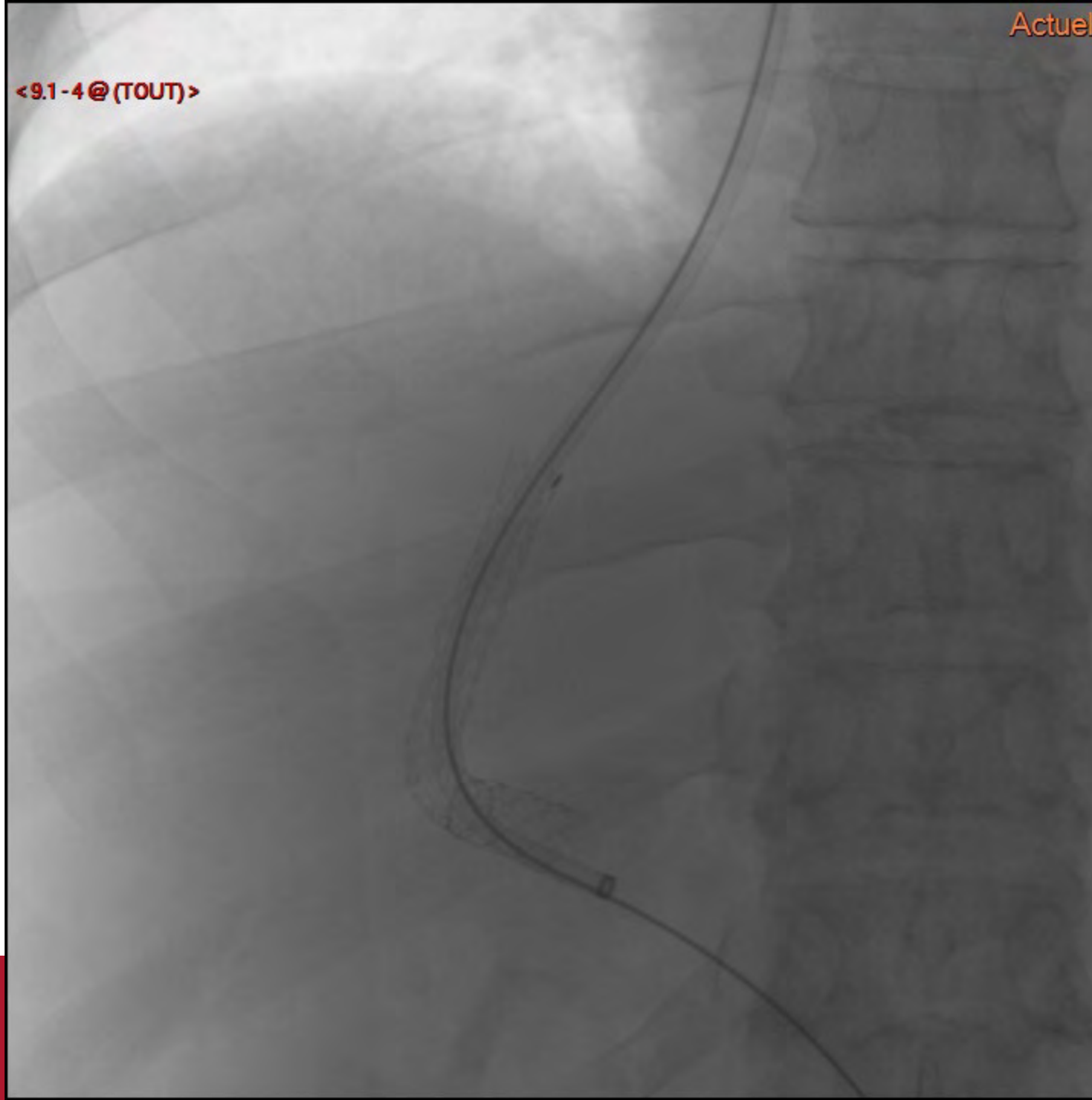
<9.1-2@ (TOUT)>



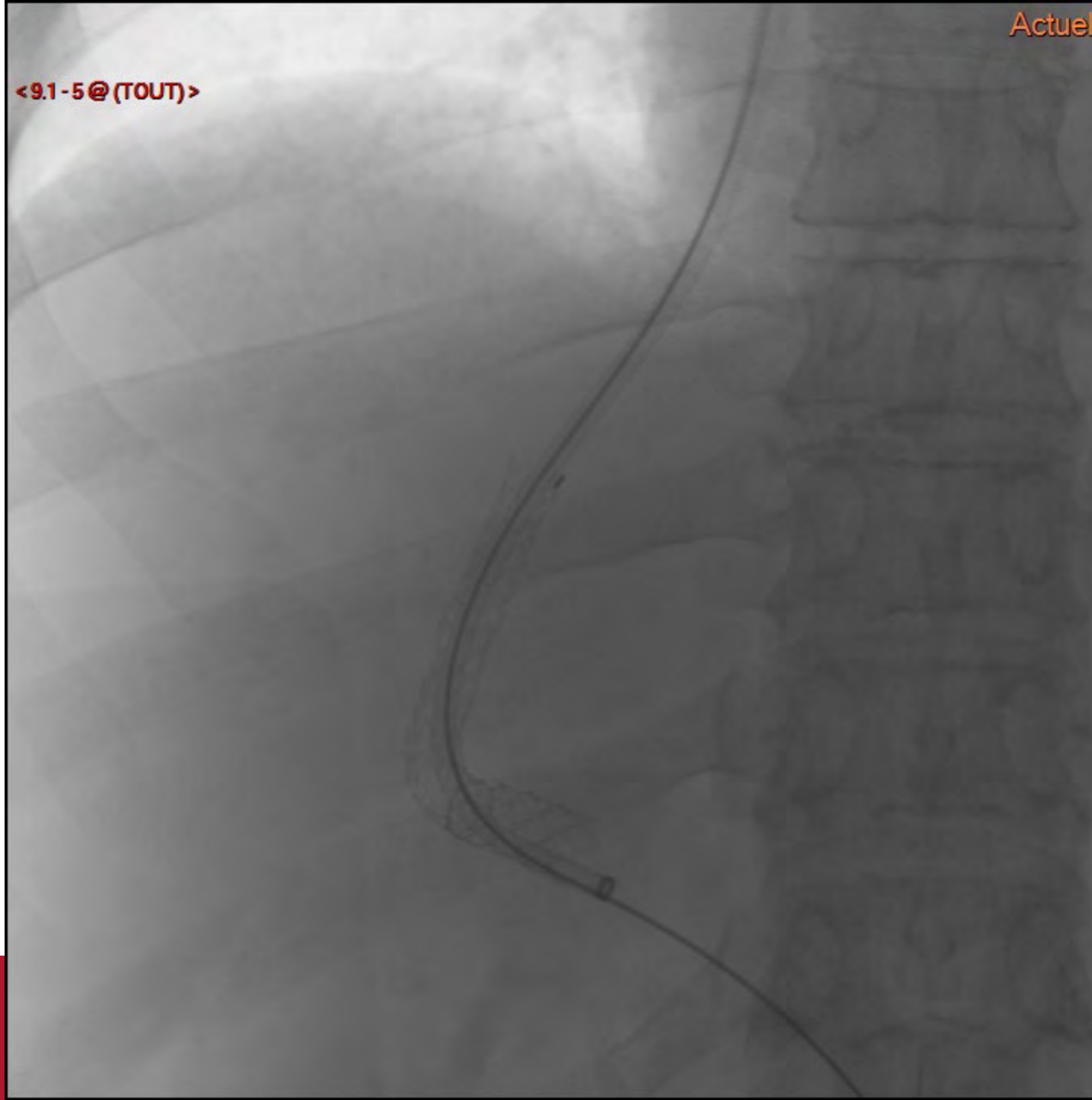
<9.1-3@TOUT>



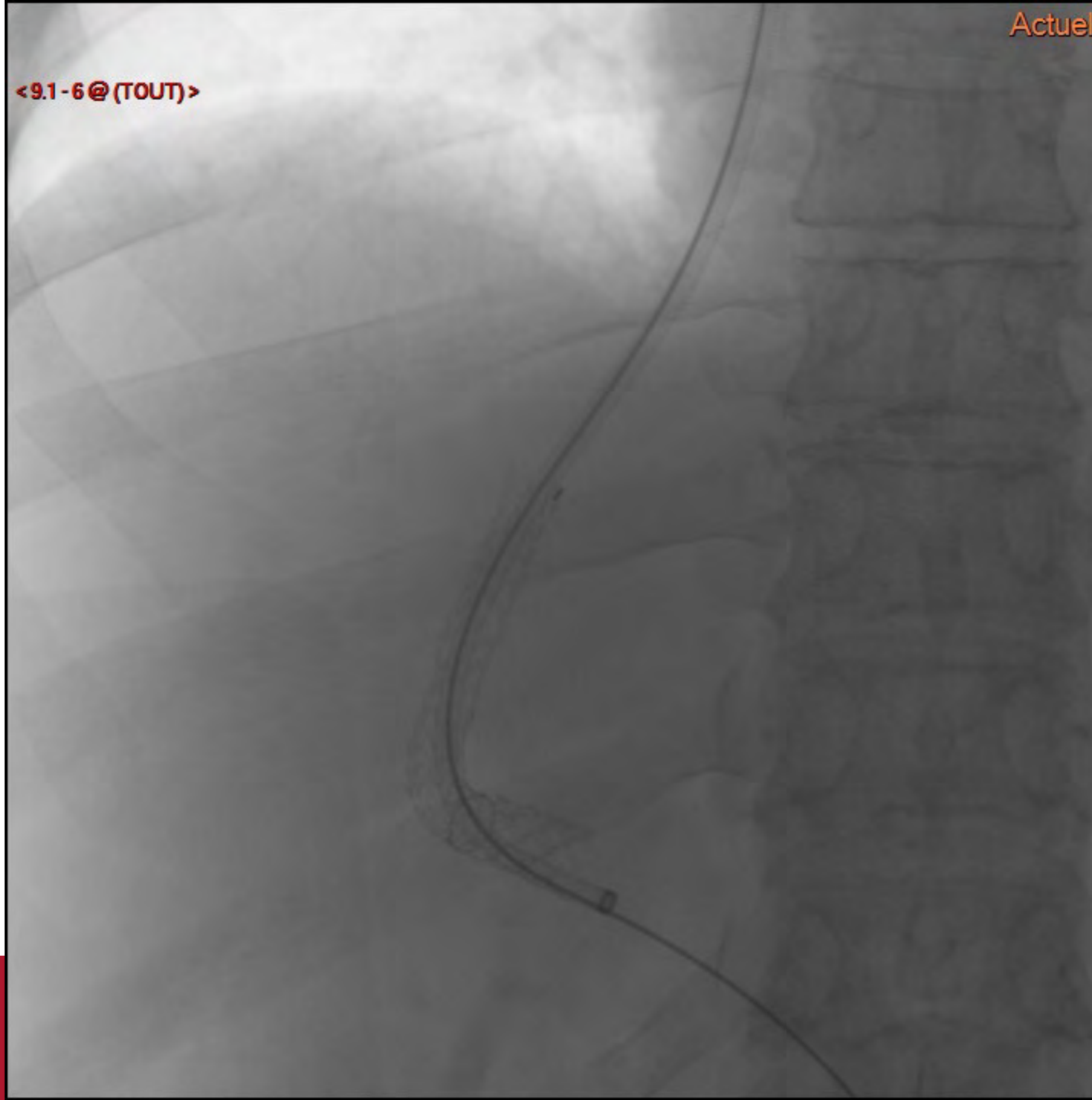
<9.1-4@ (TOUT)>



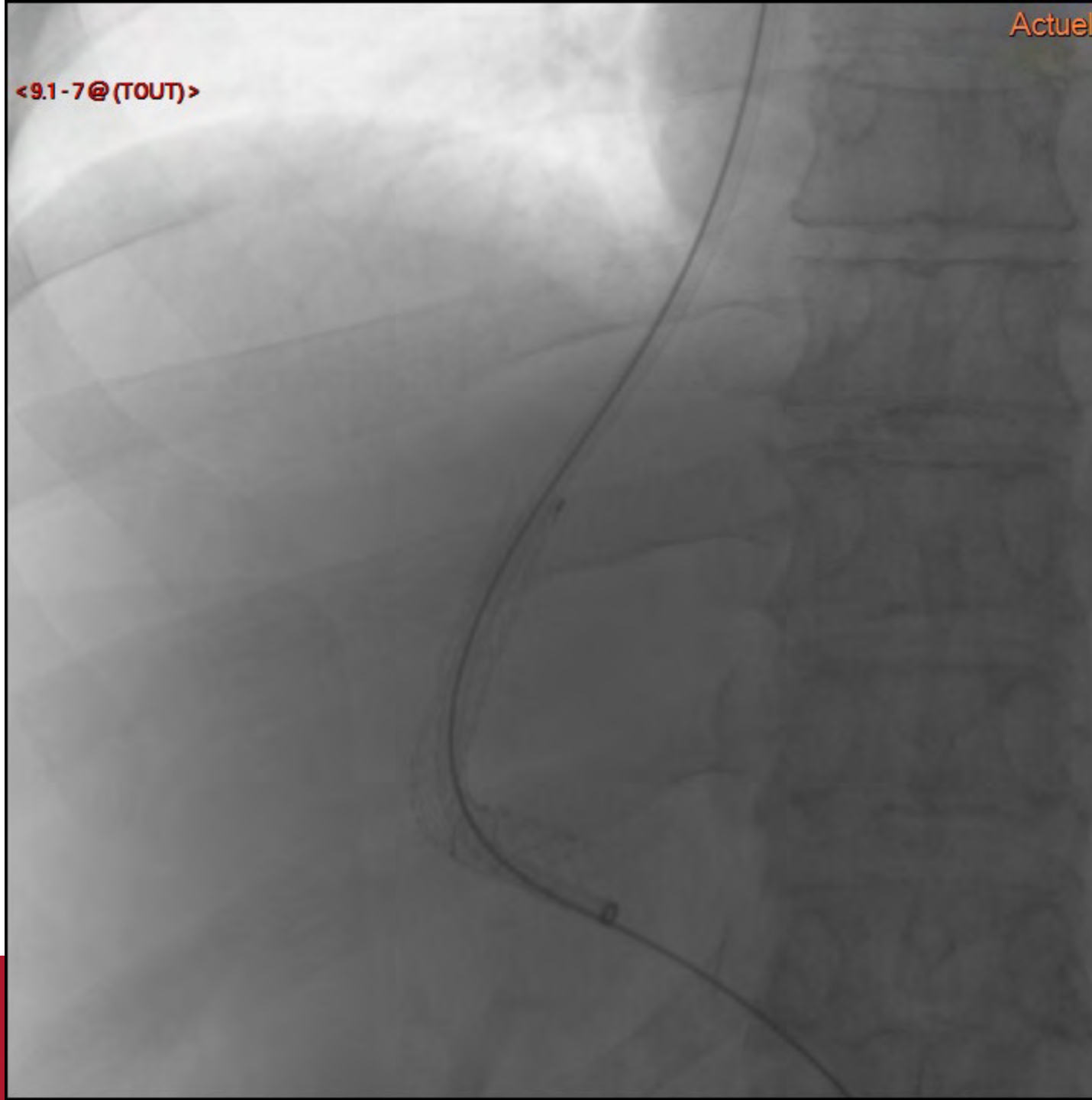
<9.1-5@TOUT>



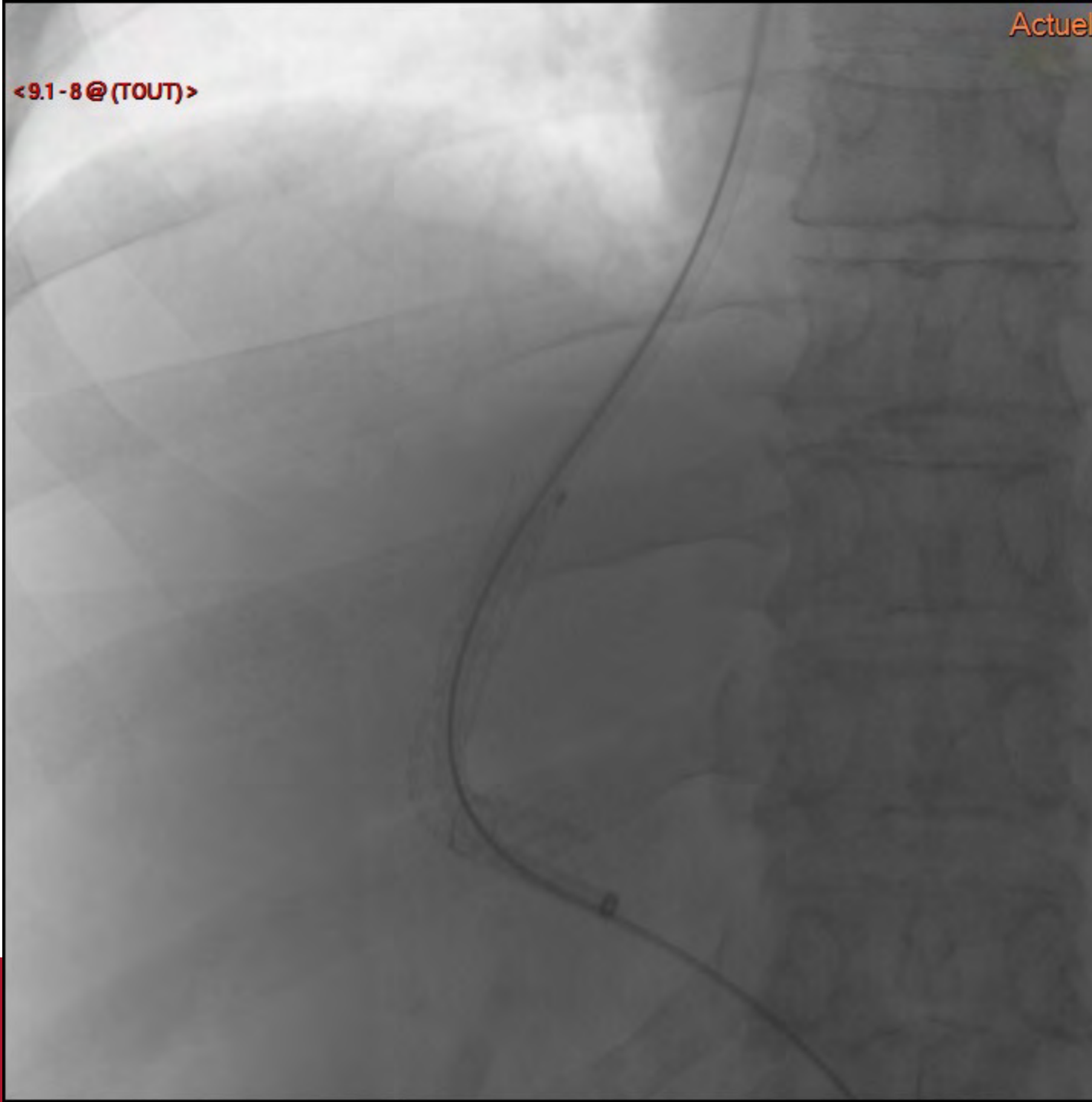
<9.1-6@ (TOUT)>



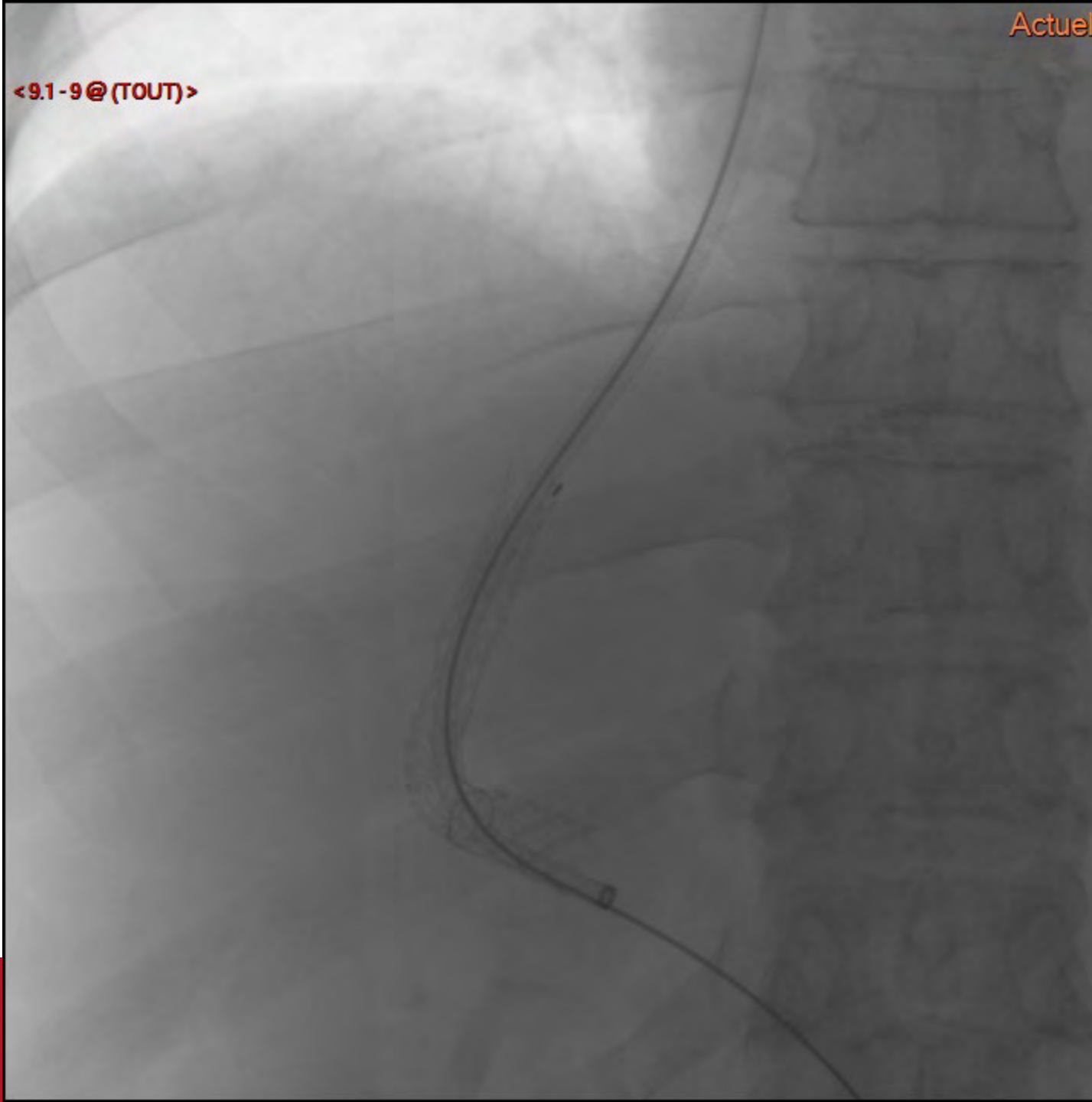<9.1-7@ (TOUT)>



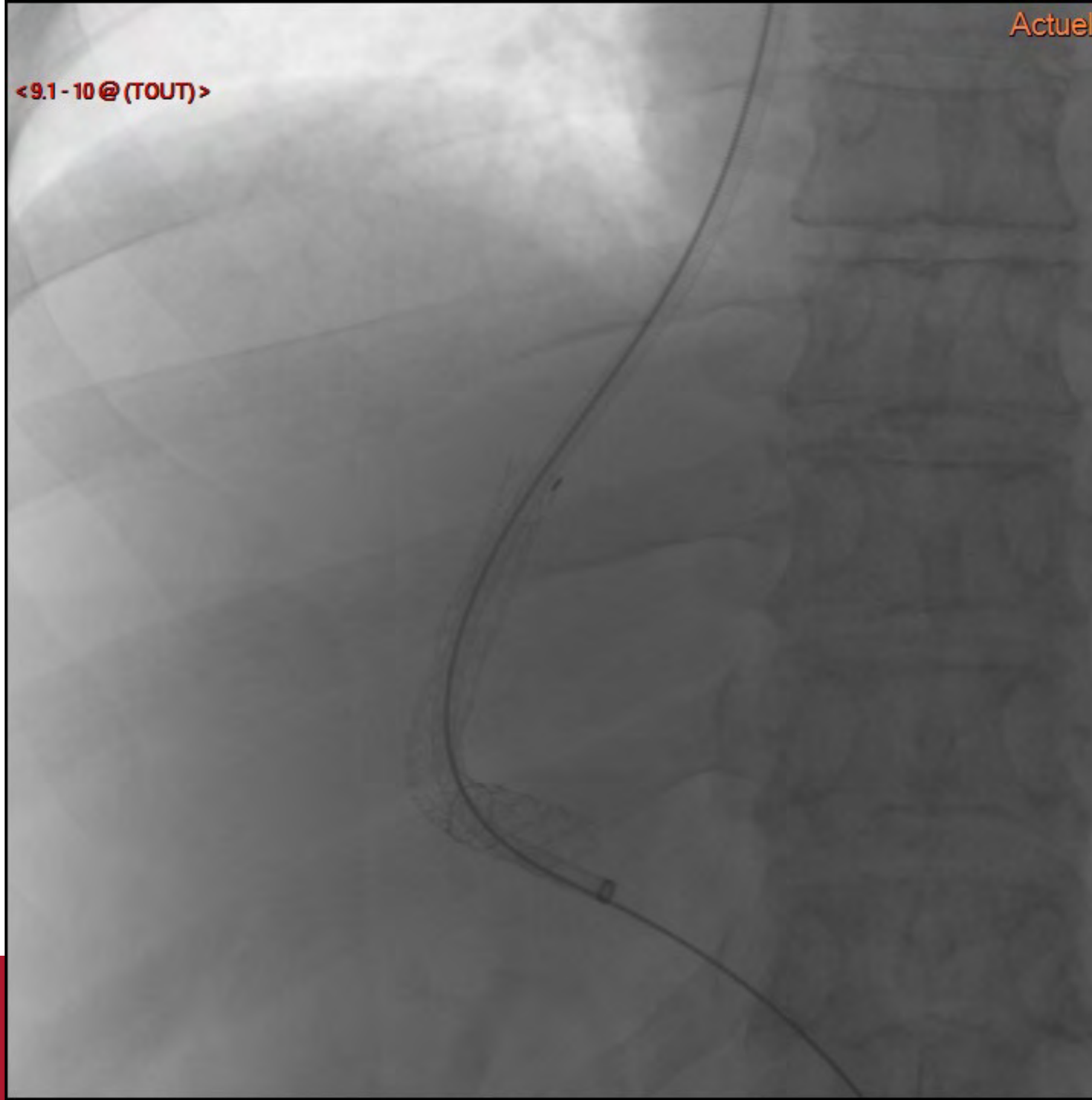
<9.1-8@TOUT>



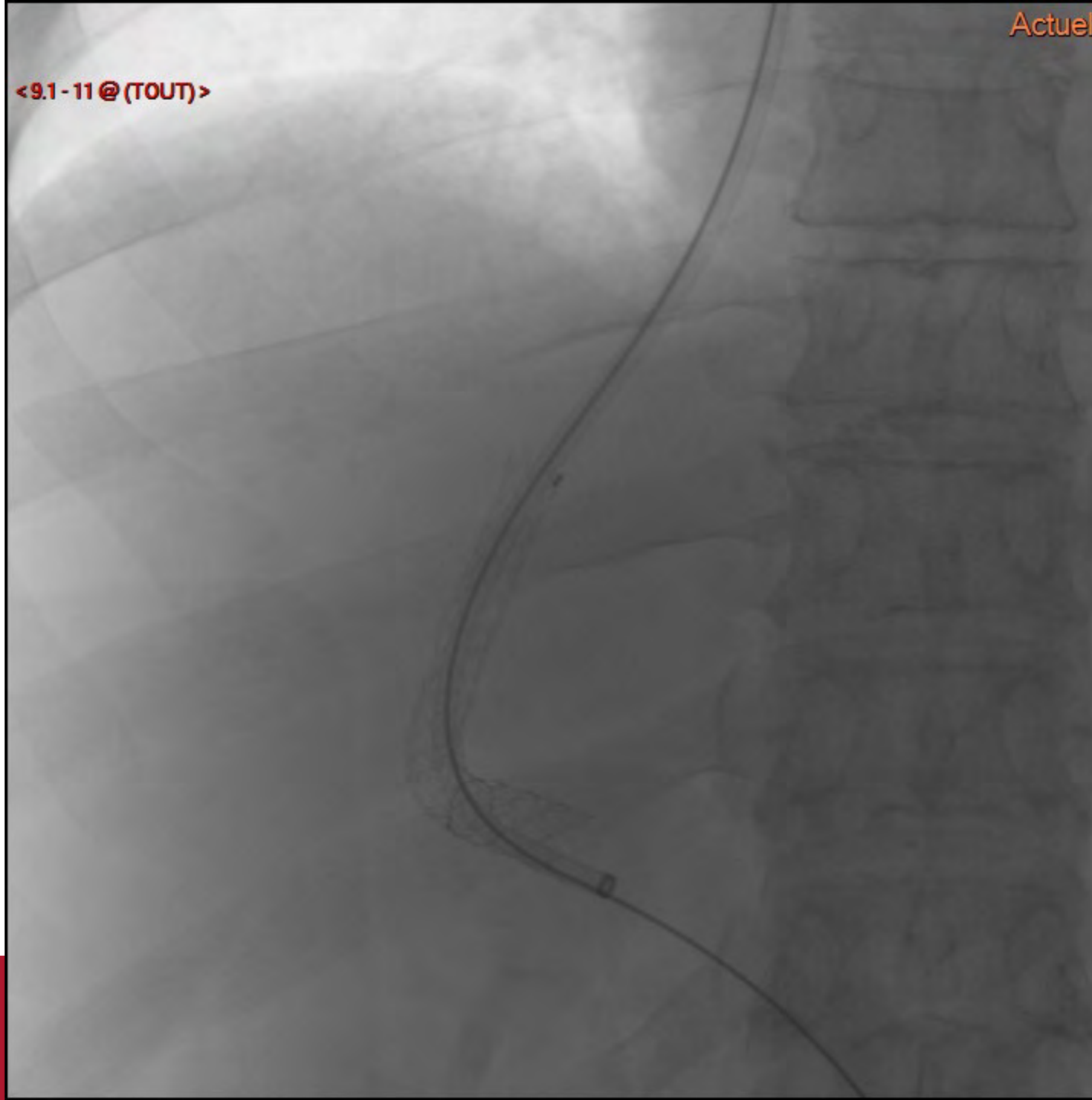
<9.1-9@TOUT>



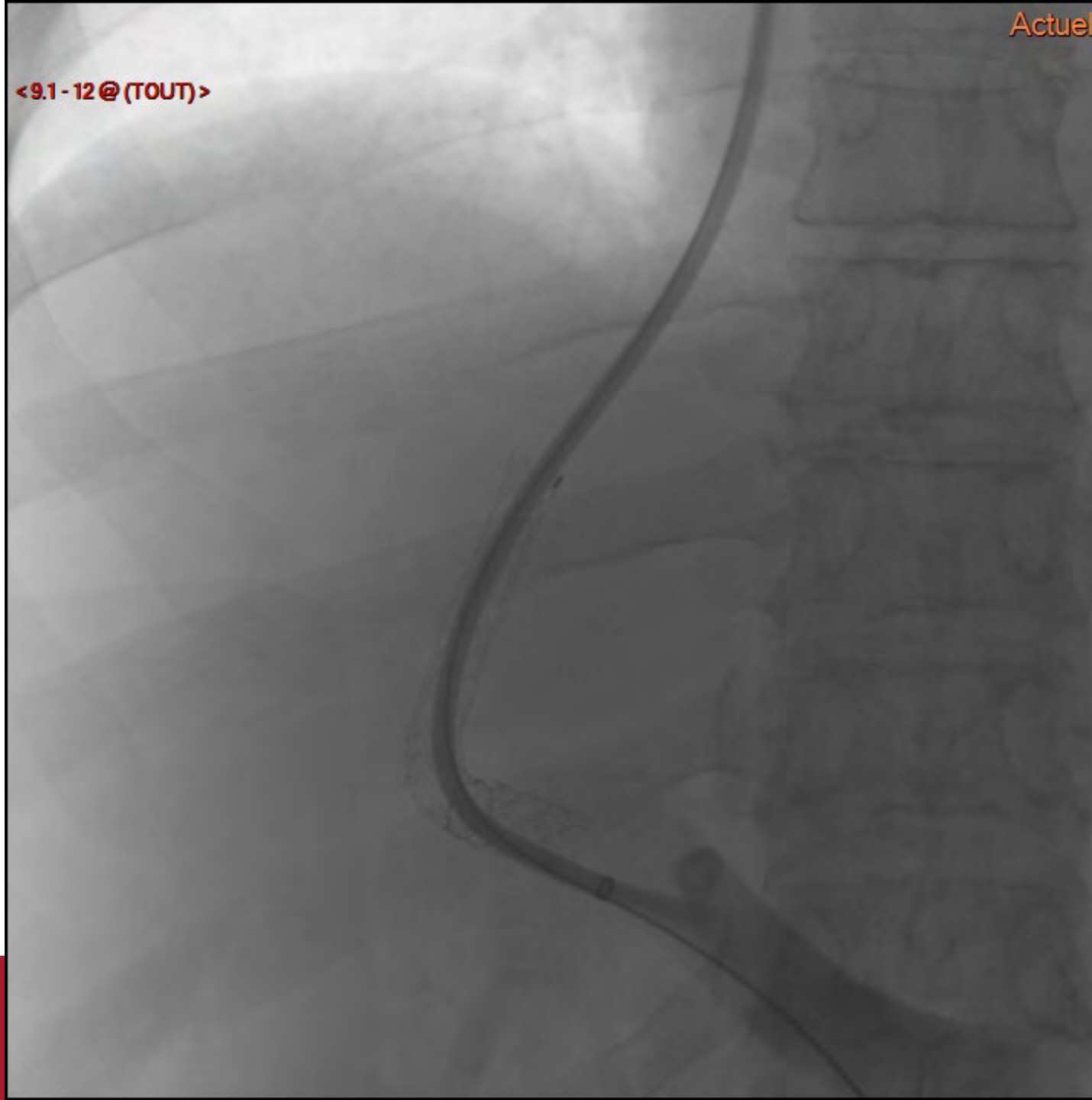
<9.1-10@ (TOUT)>



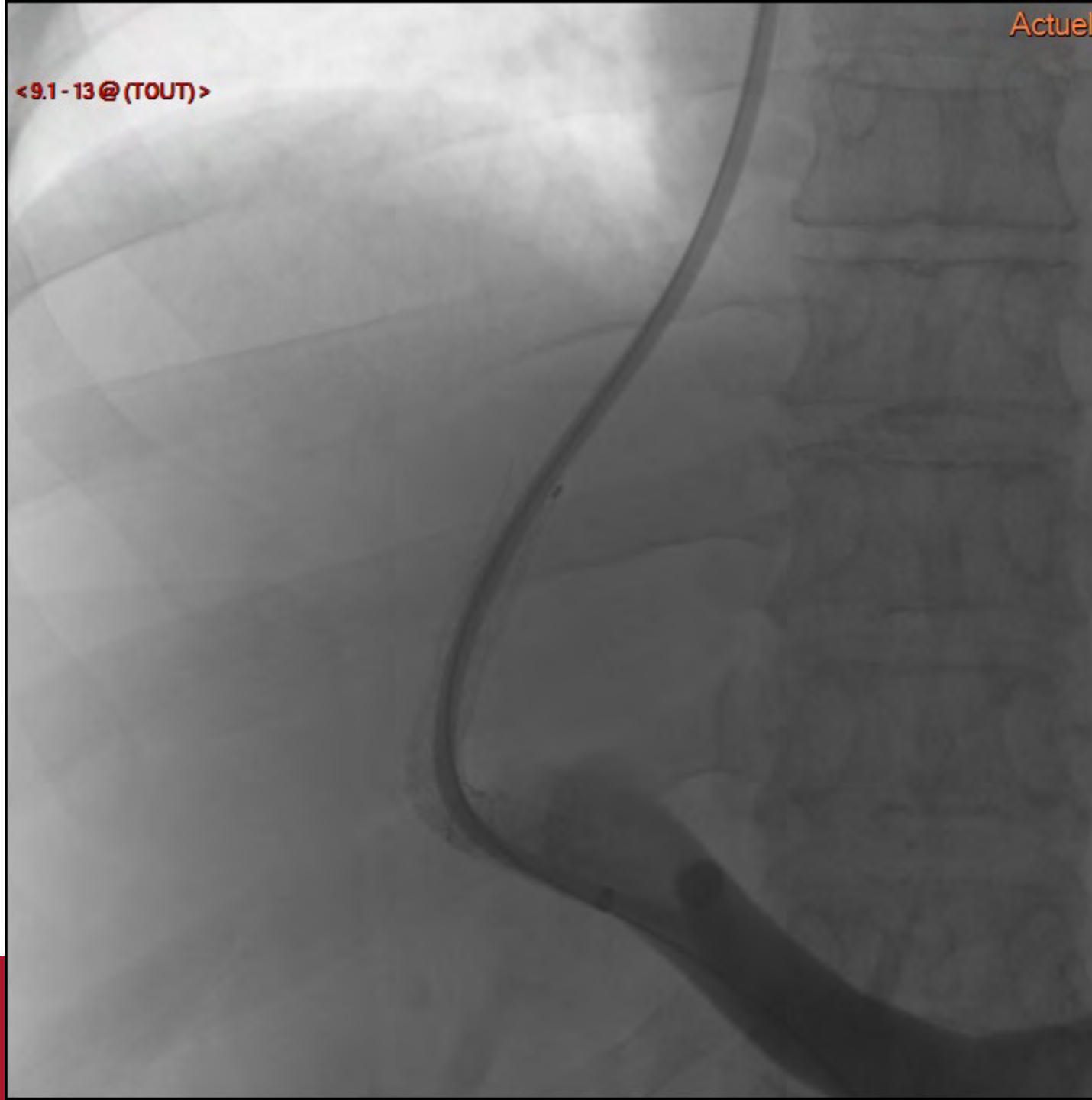
<9.1-11@TOUT>



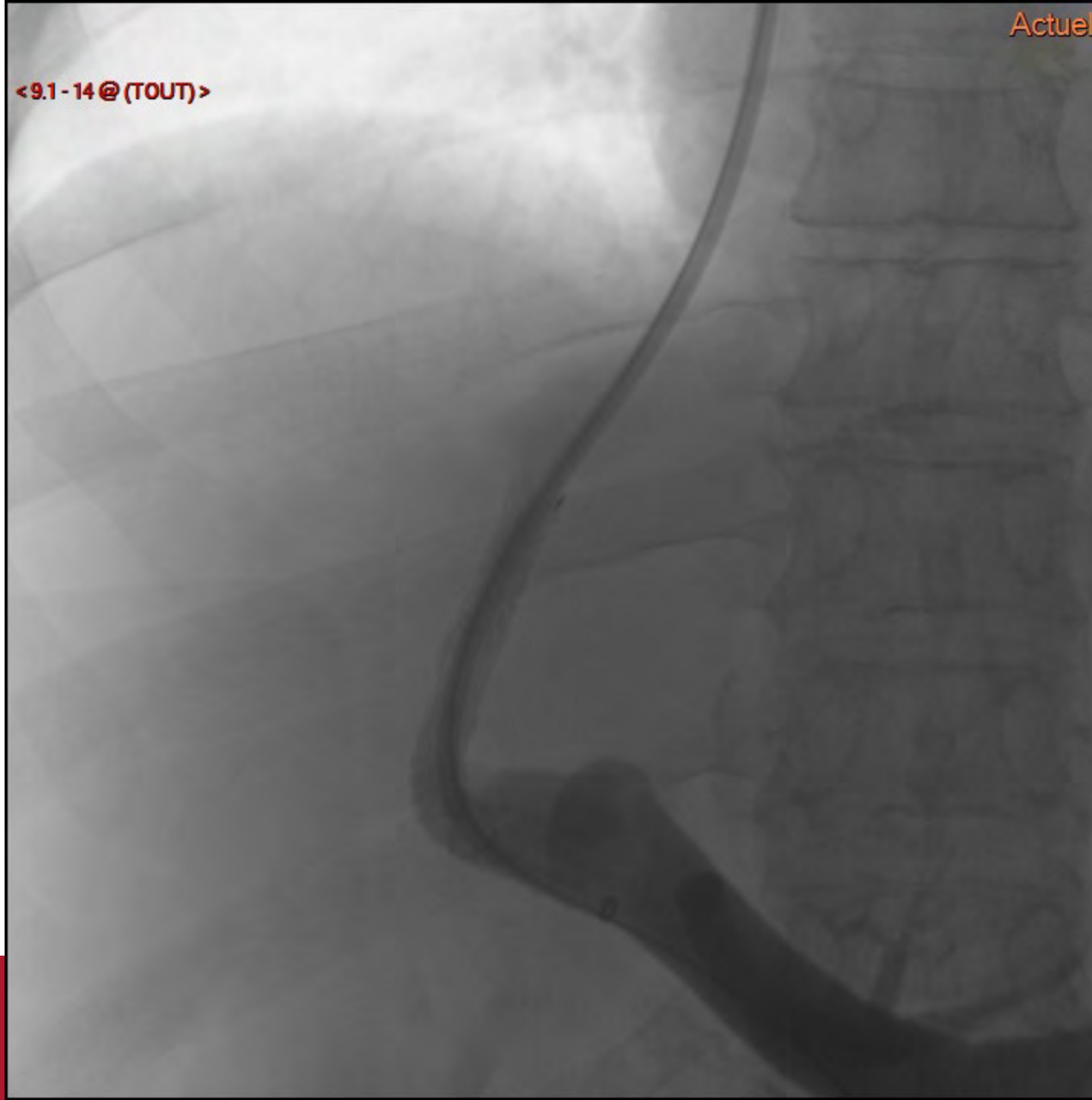
<9.1-12@ (TOUT)>



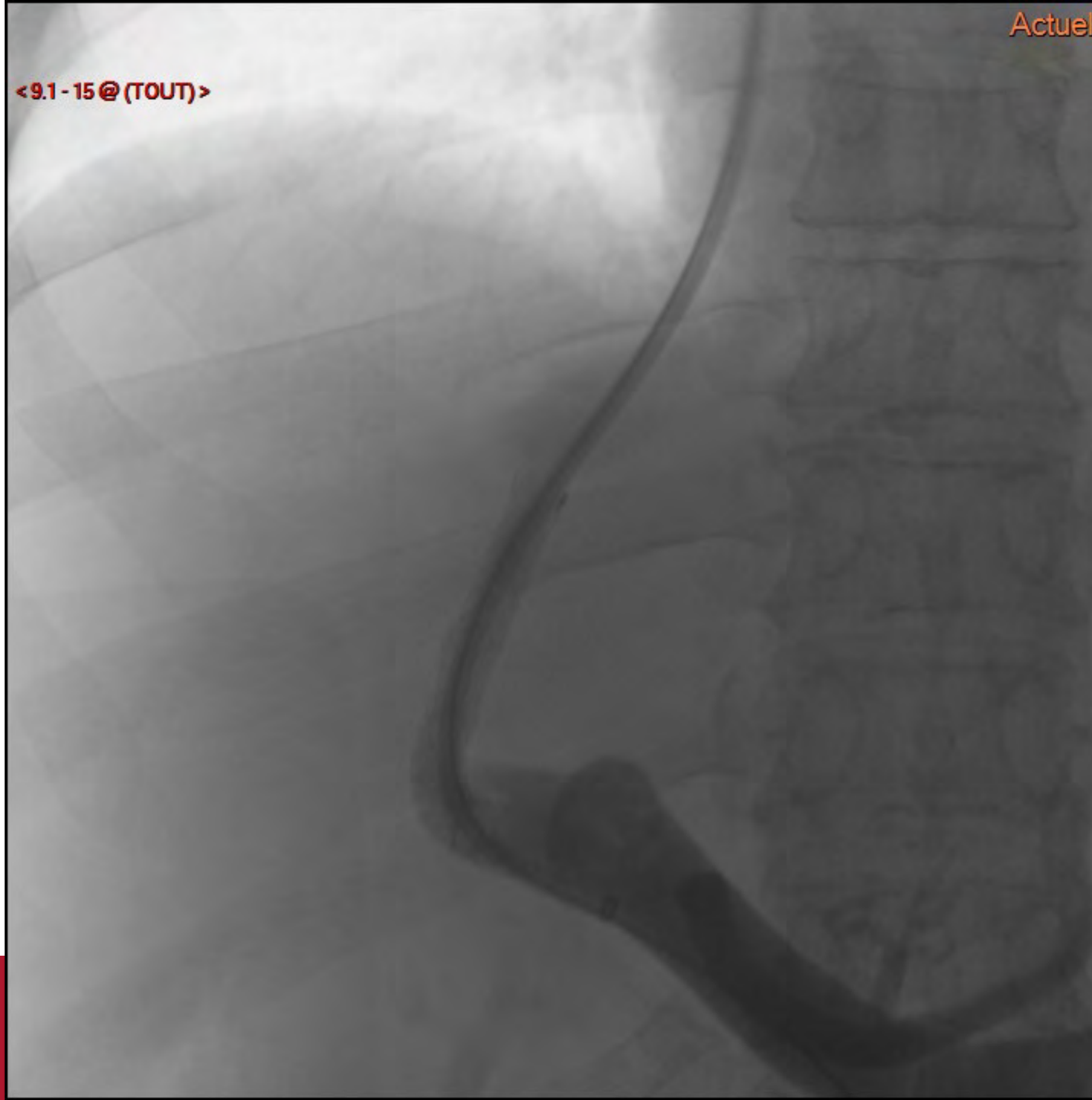
<9.1-13@ (TOUT)>



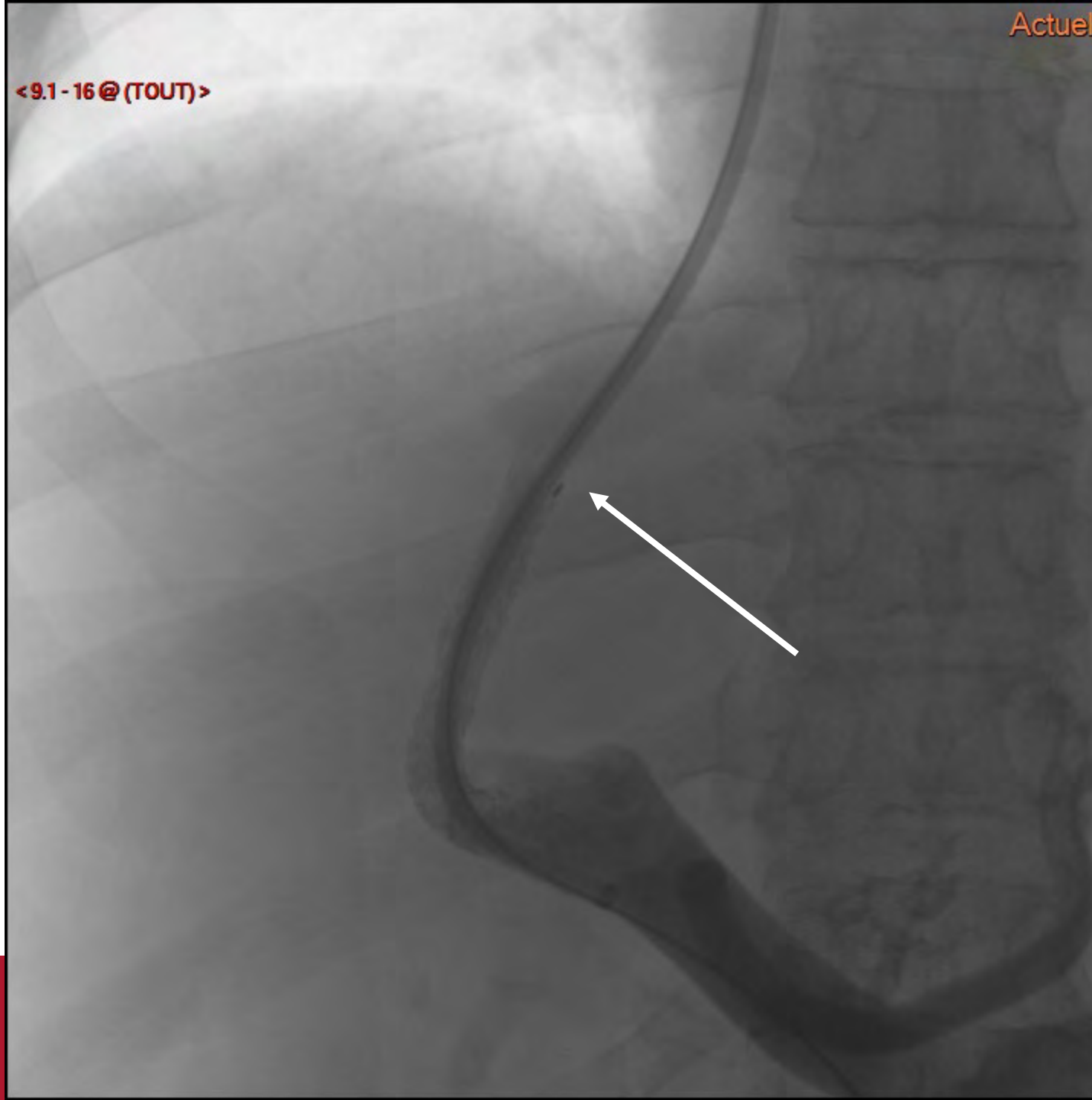
<9.1-14@ (TOUT)>



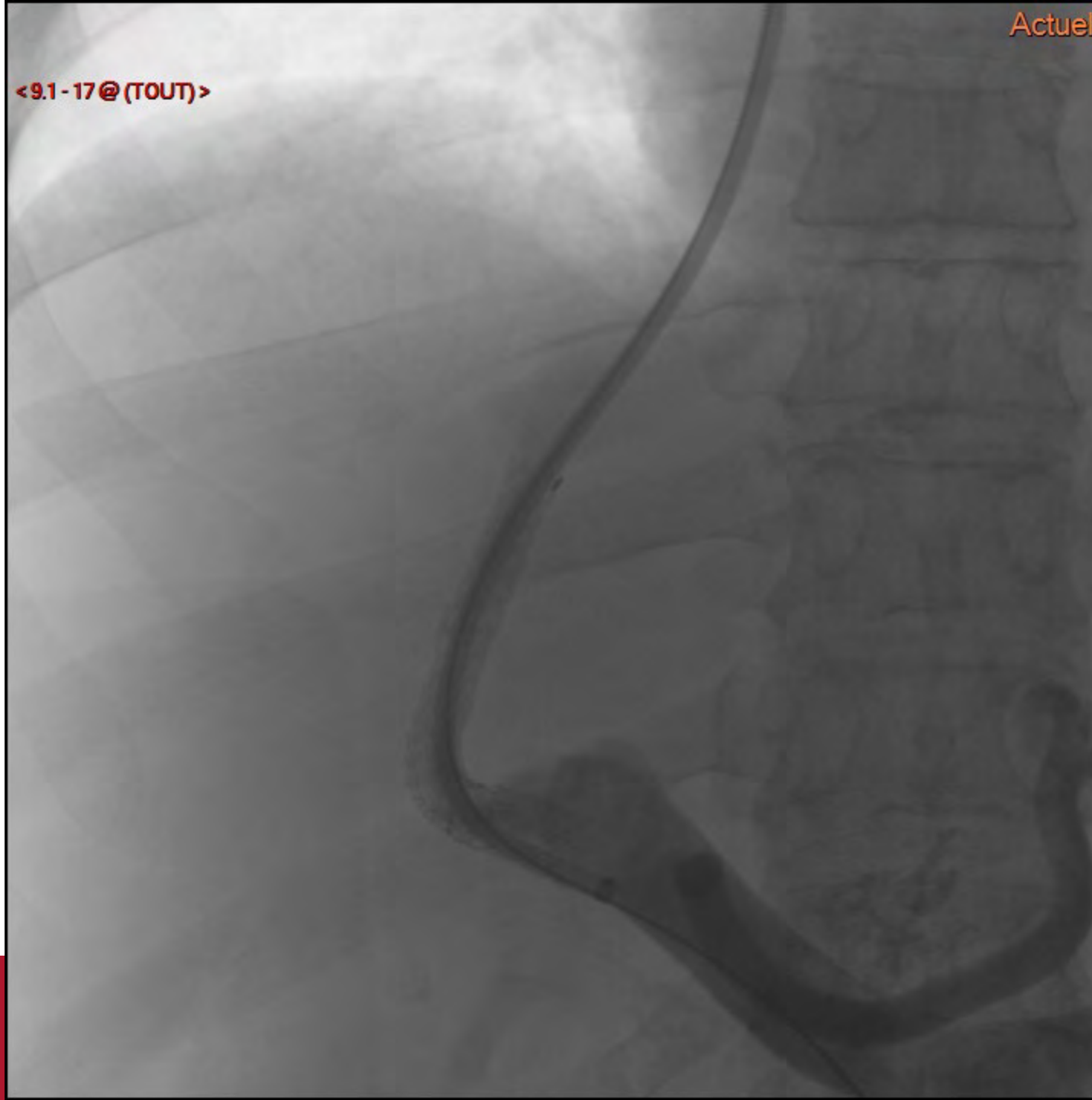
<9.1-15@ (TOUT)>



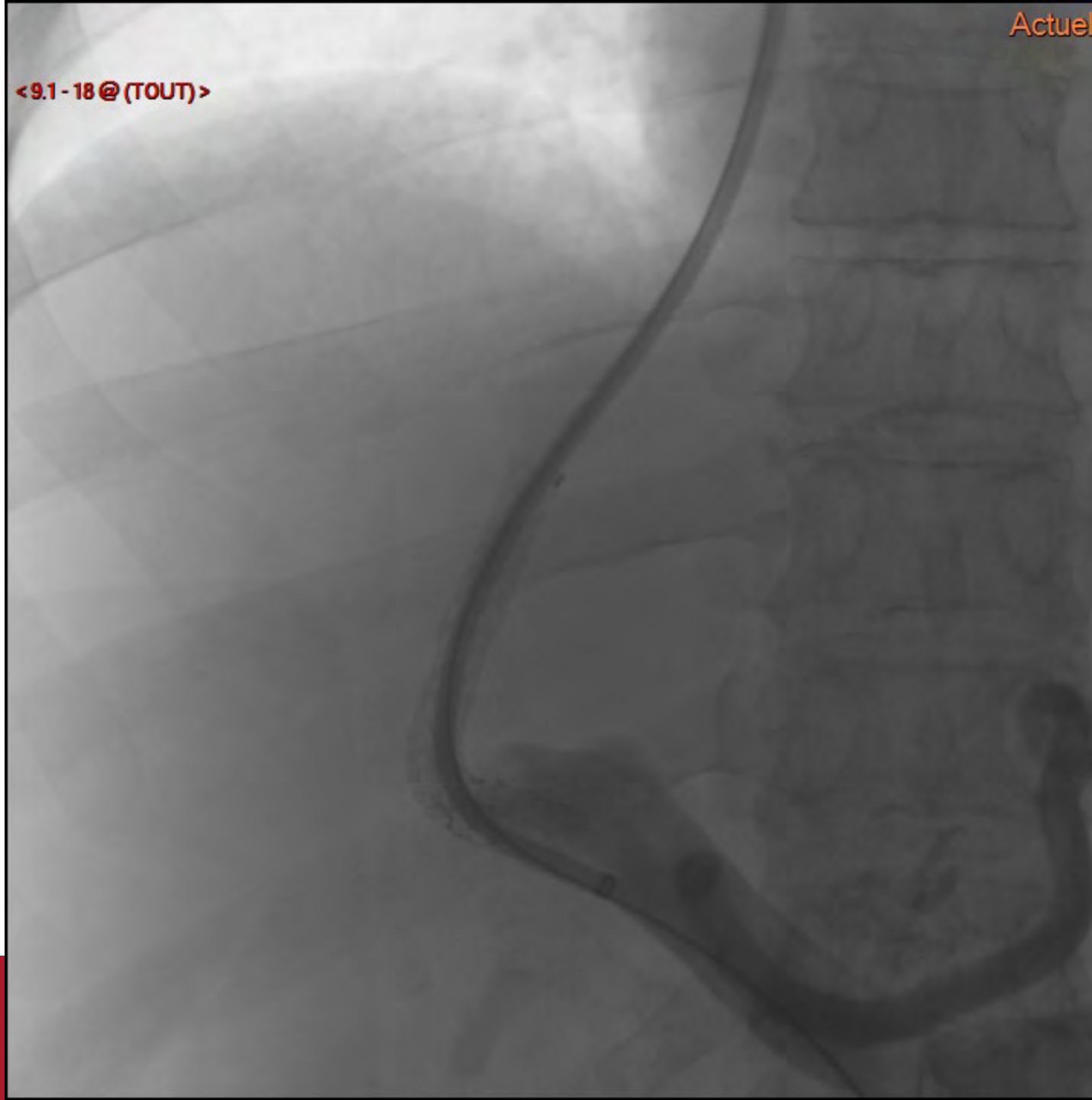
<9.1-16@ (TOUT)>



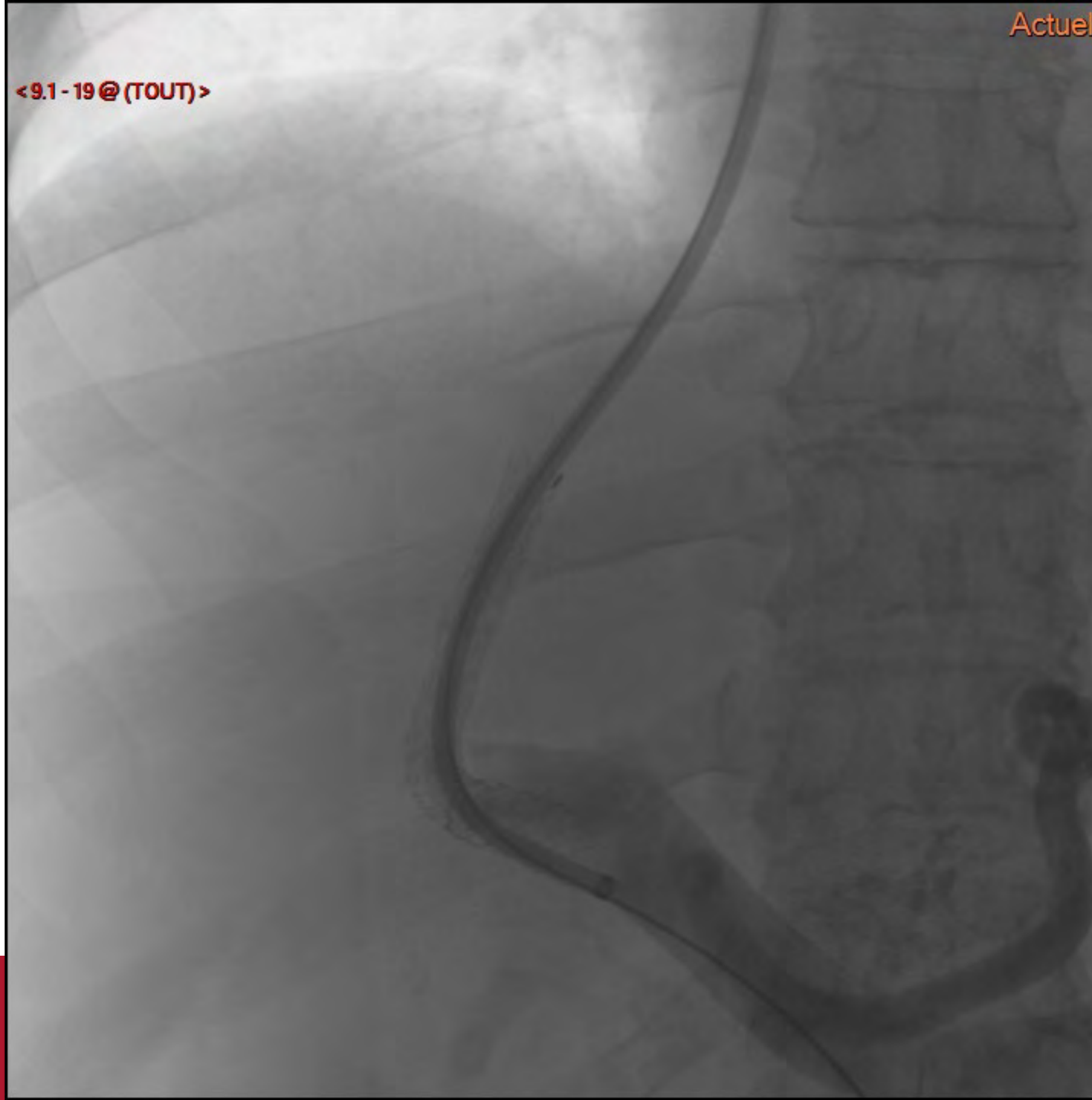
<9.1-17@ (TOUT)>



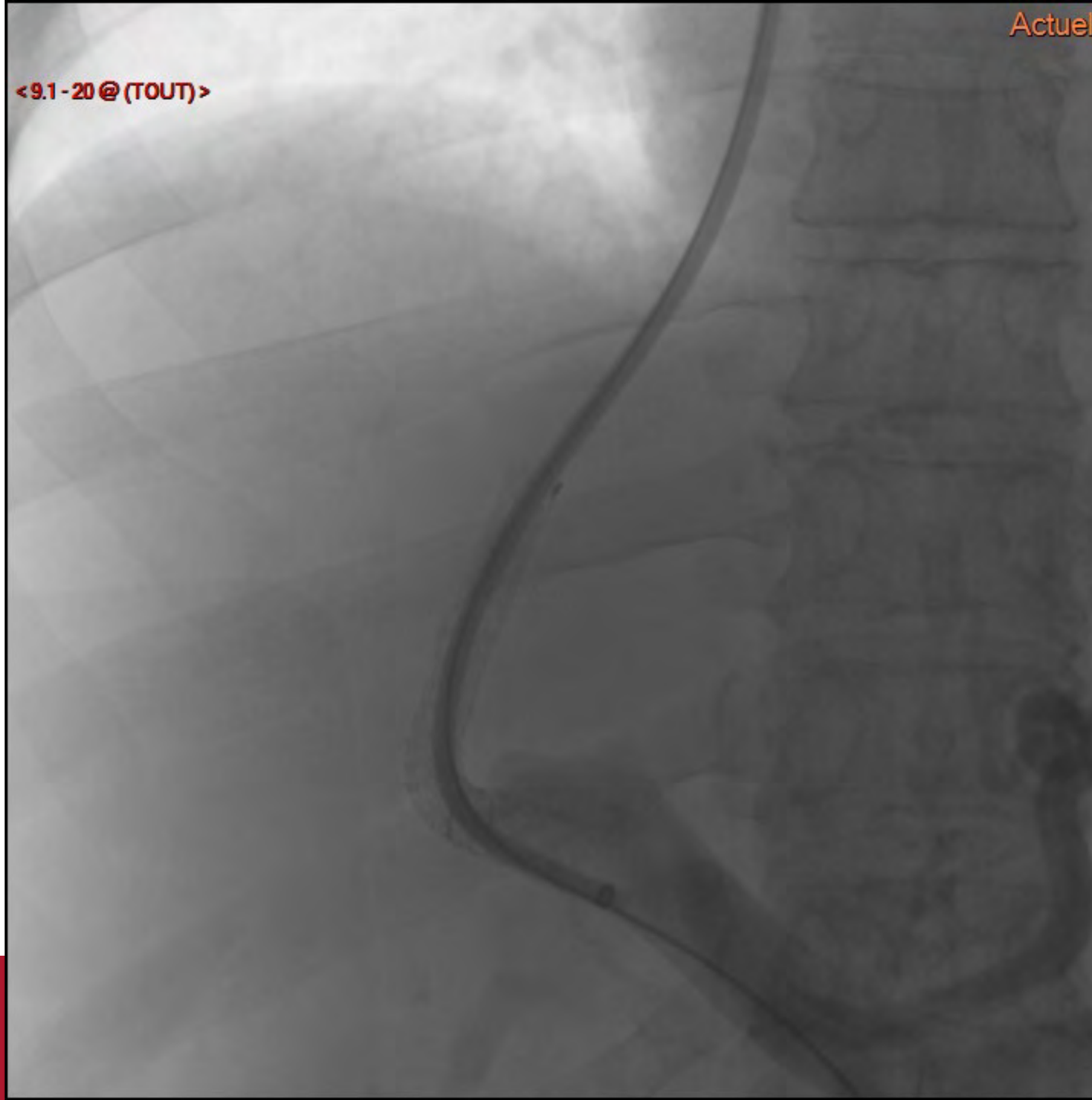
<9.1-18@ (TOUT)>



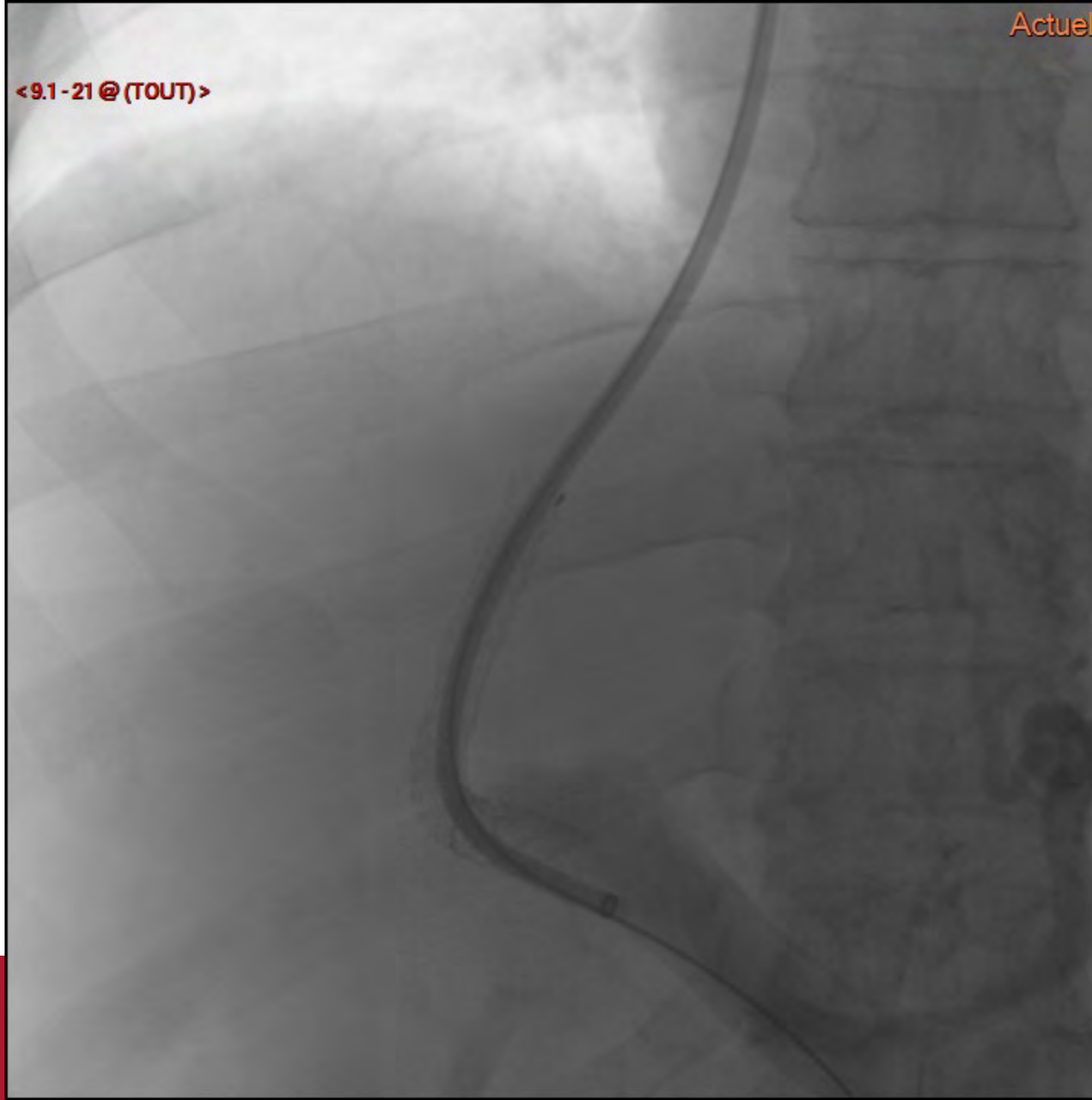
<9.1-19@ (TOUT)>



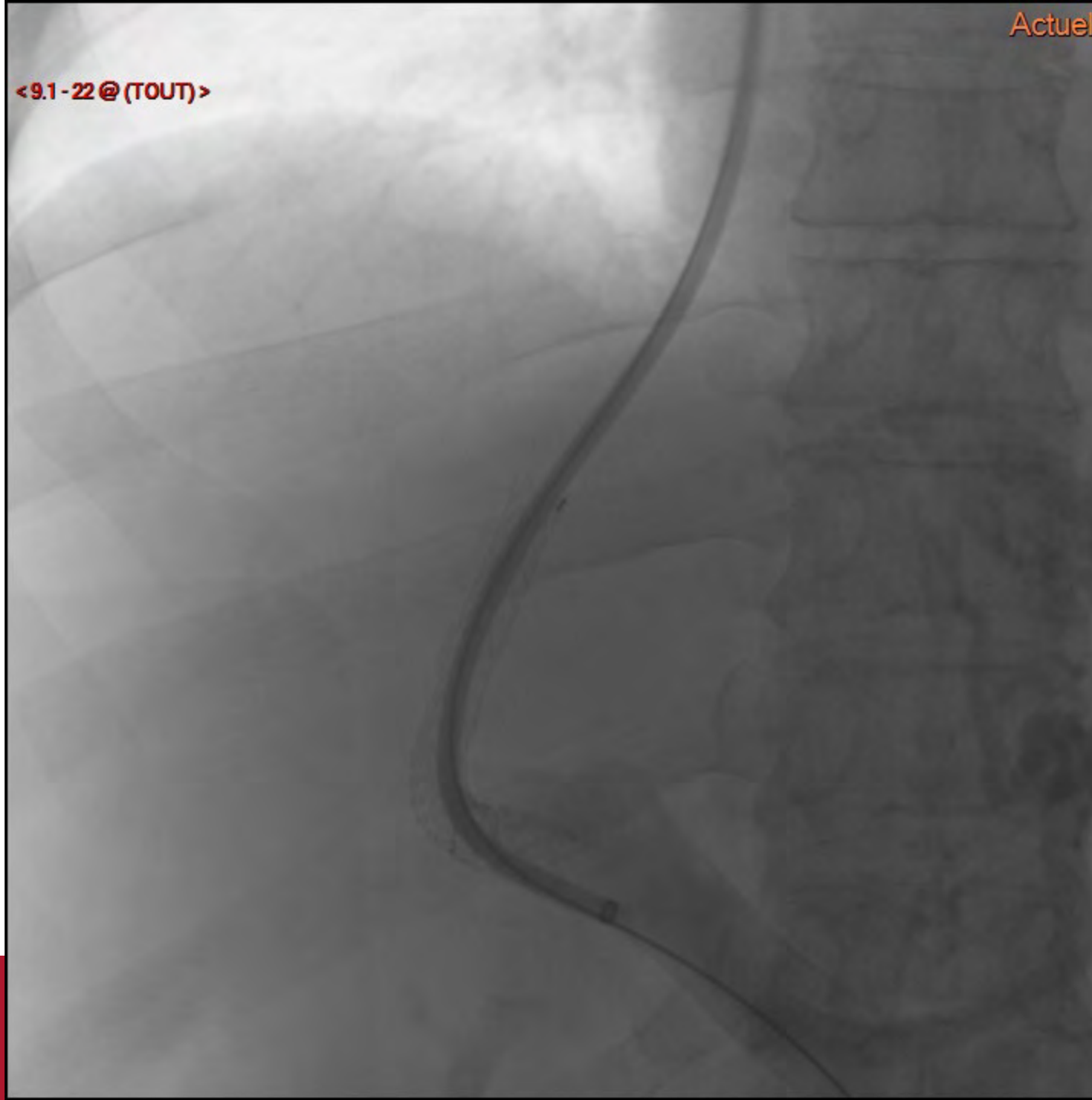
<9.1-20@ (TOUT)>



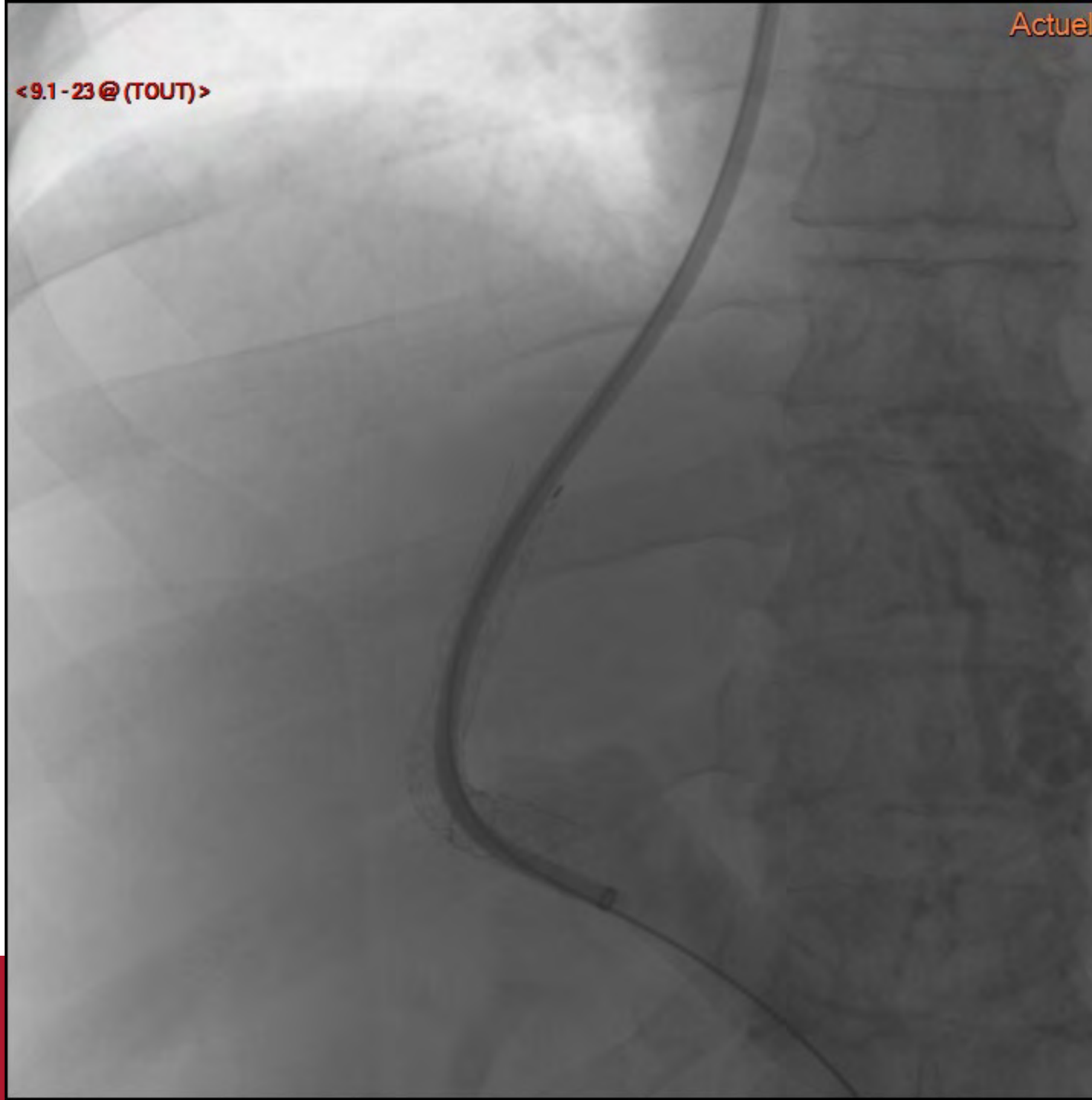
<9.1-21@TOUT>



<9.1-22@ (TOUT)>



<9.1-23@TOUT>



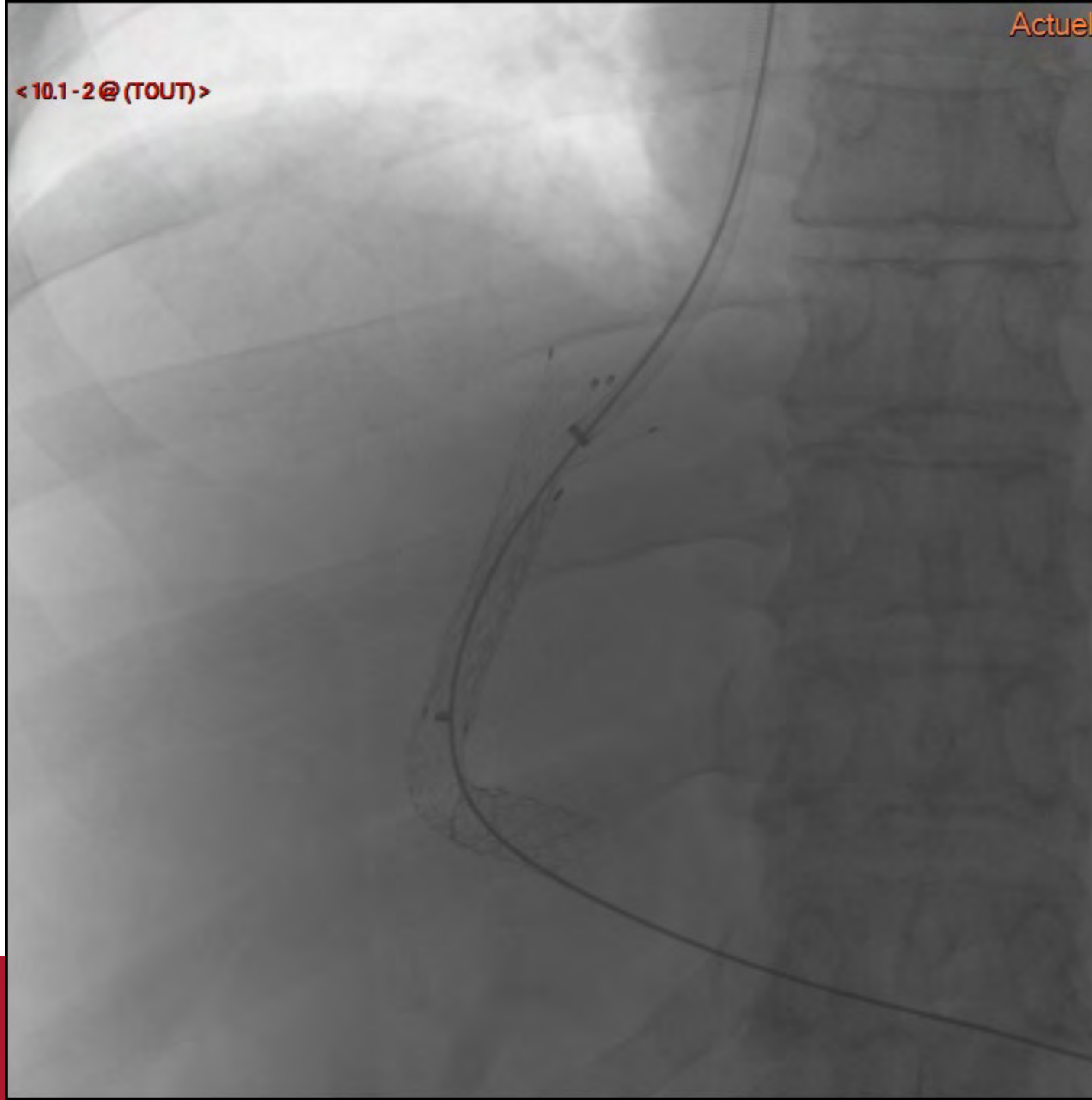
<9.1-24@ (TOUT)>

Prothèse trop courte

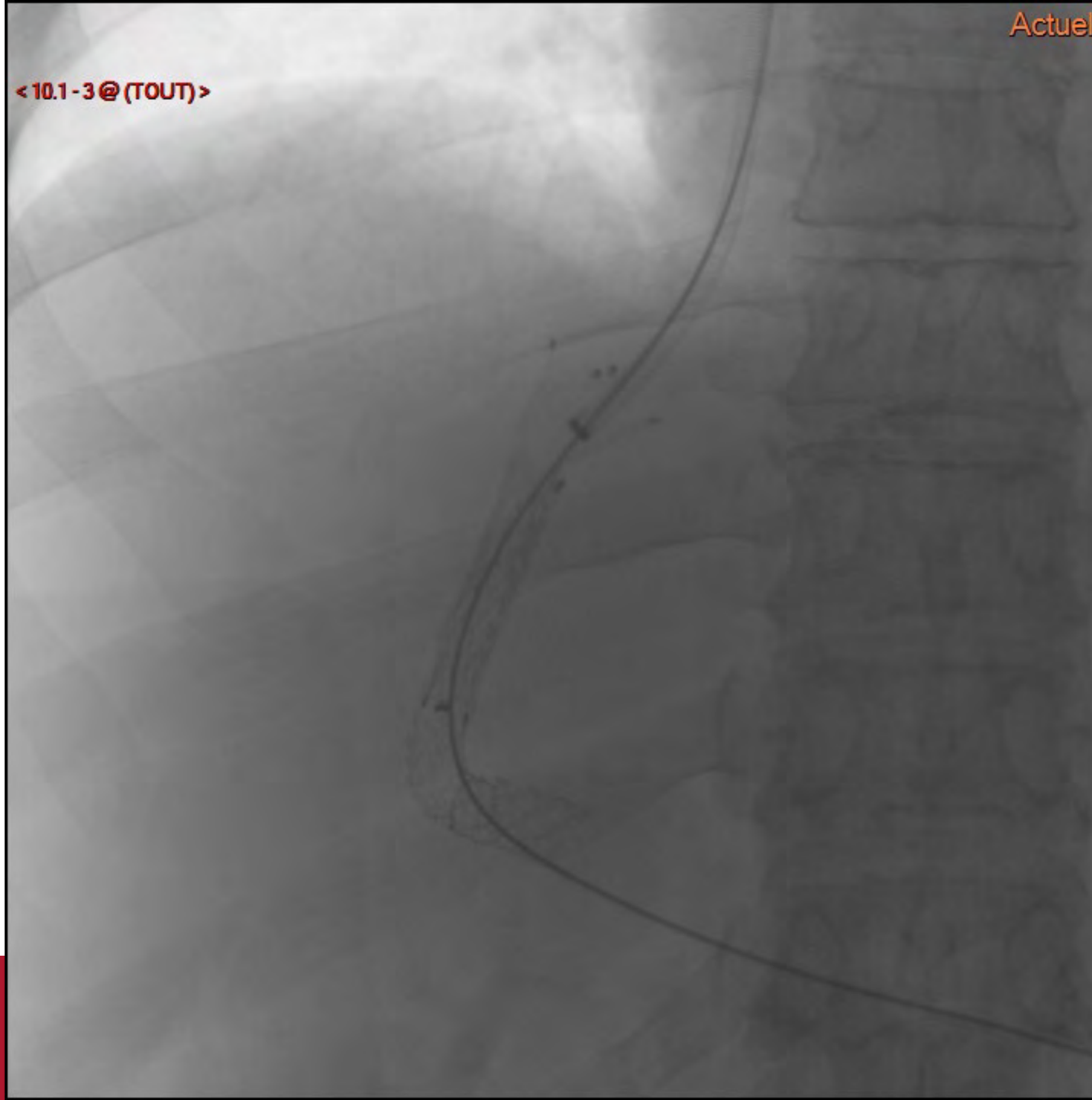
<10.1-1@(TOUT)>

Prolongation (13.5 x 60 mm)

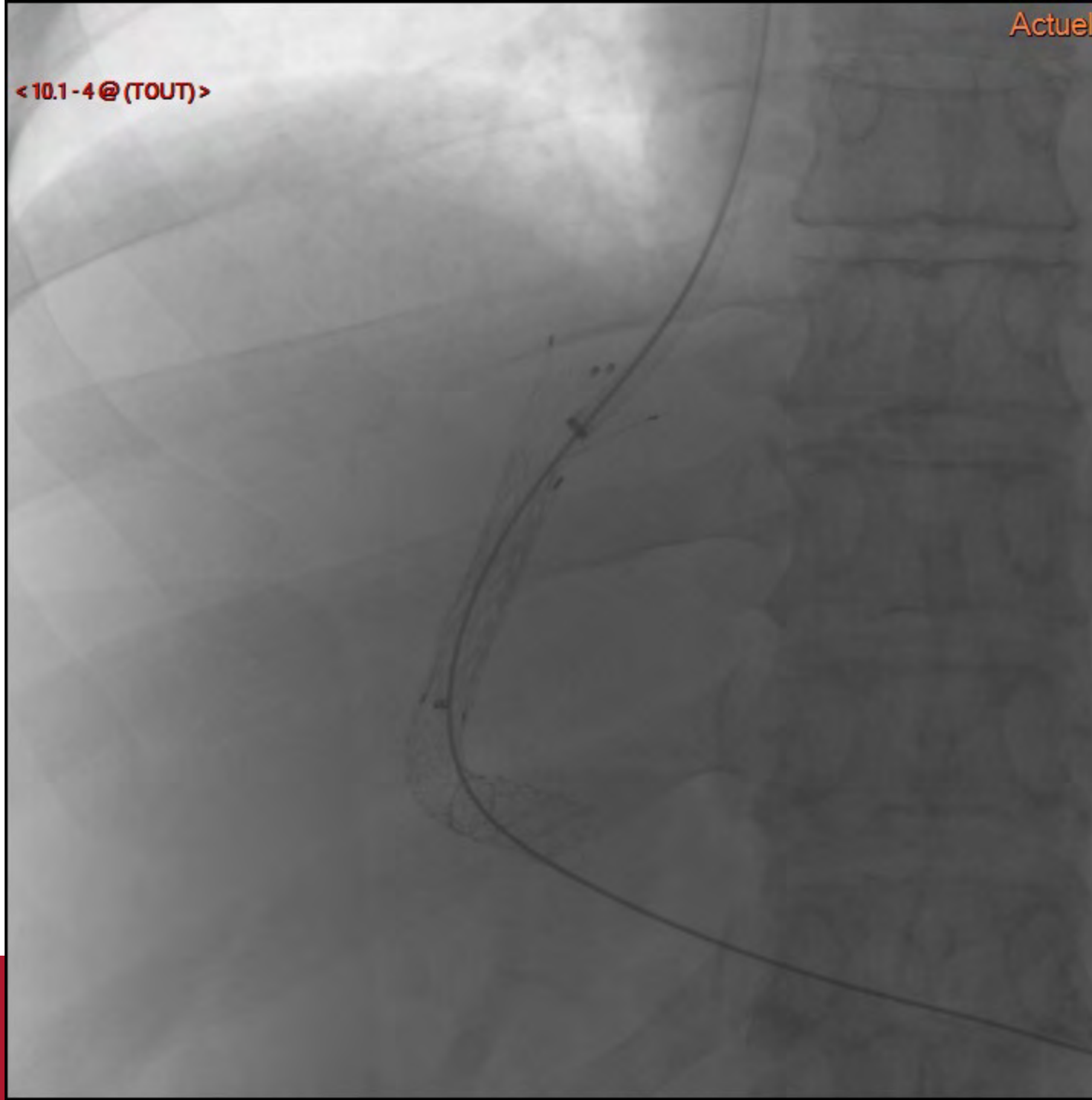
<10.1-2@(TOUT)>



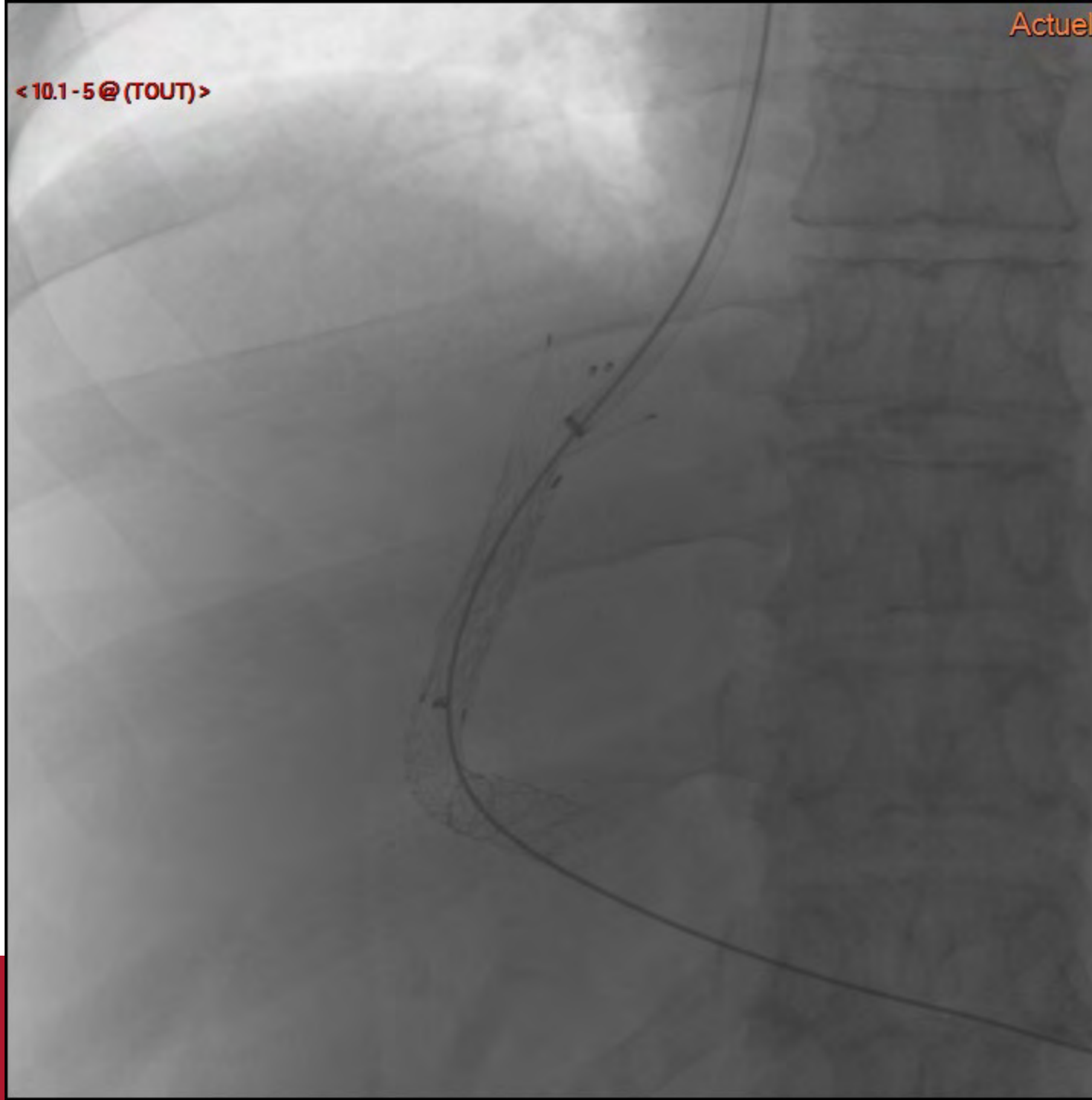
<10.1-3@ (TOUT)>



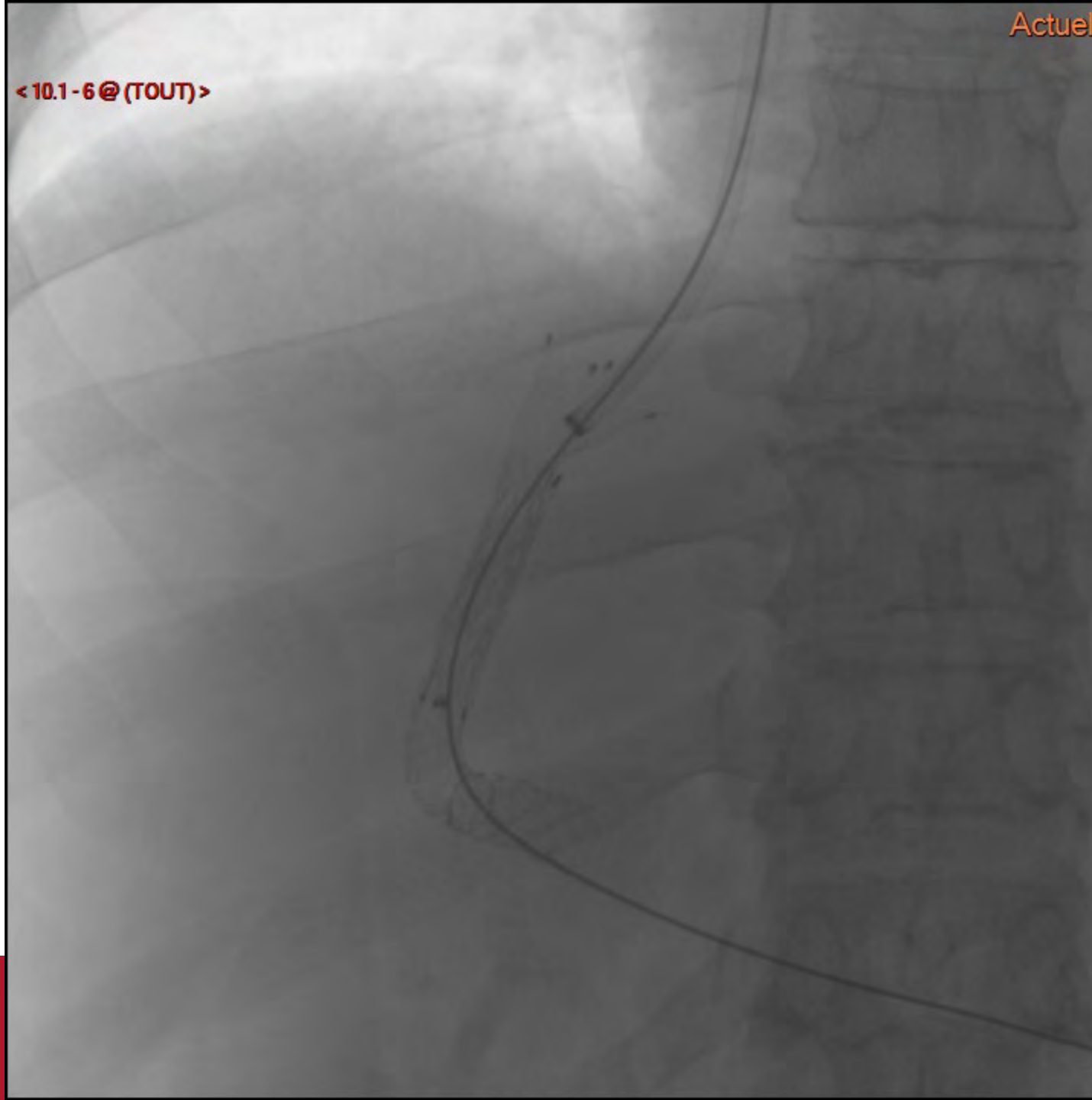
<10.1-4@ (TOUT)>



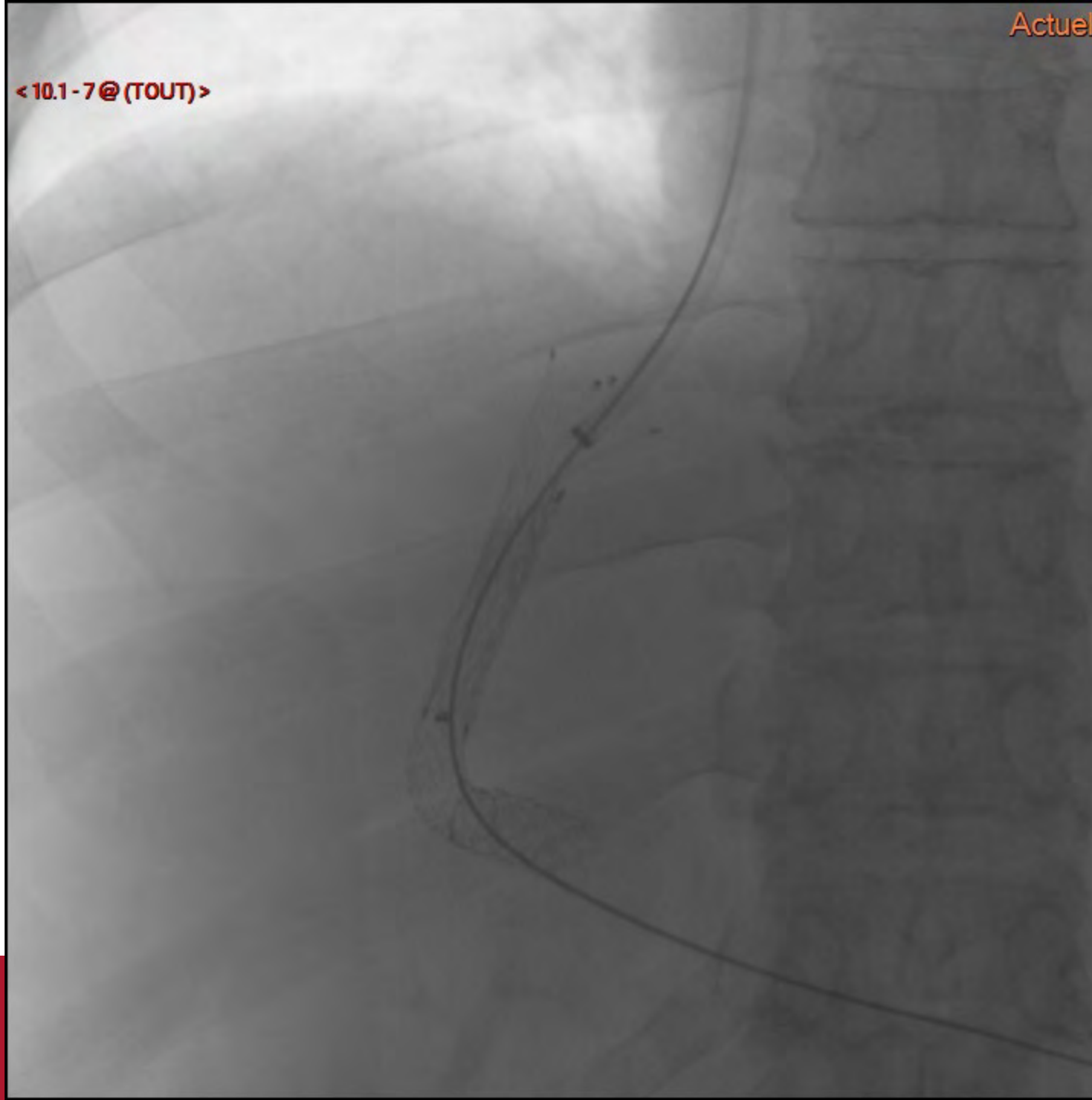
<10.1-5@(TOUT)>



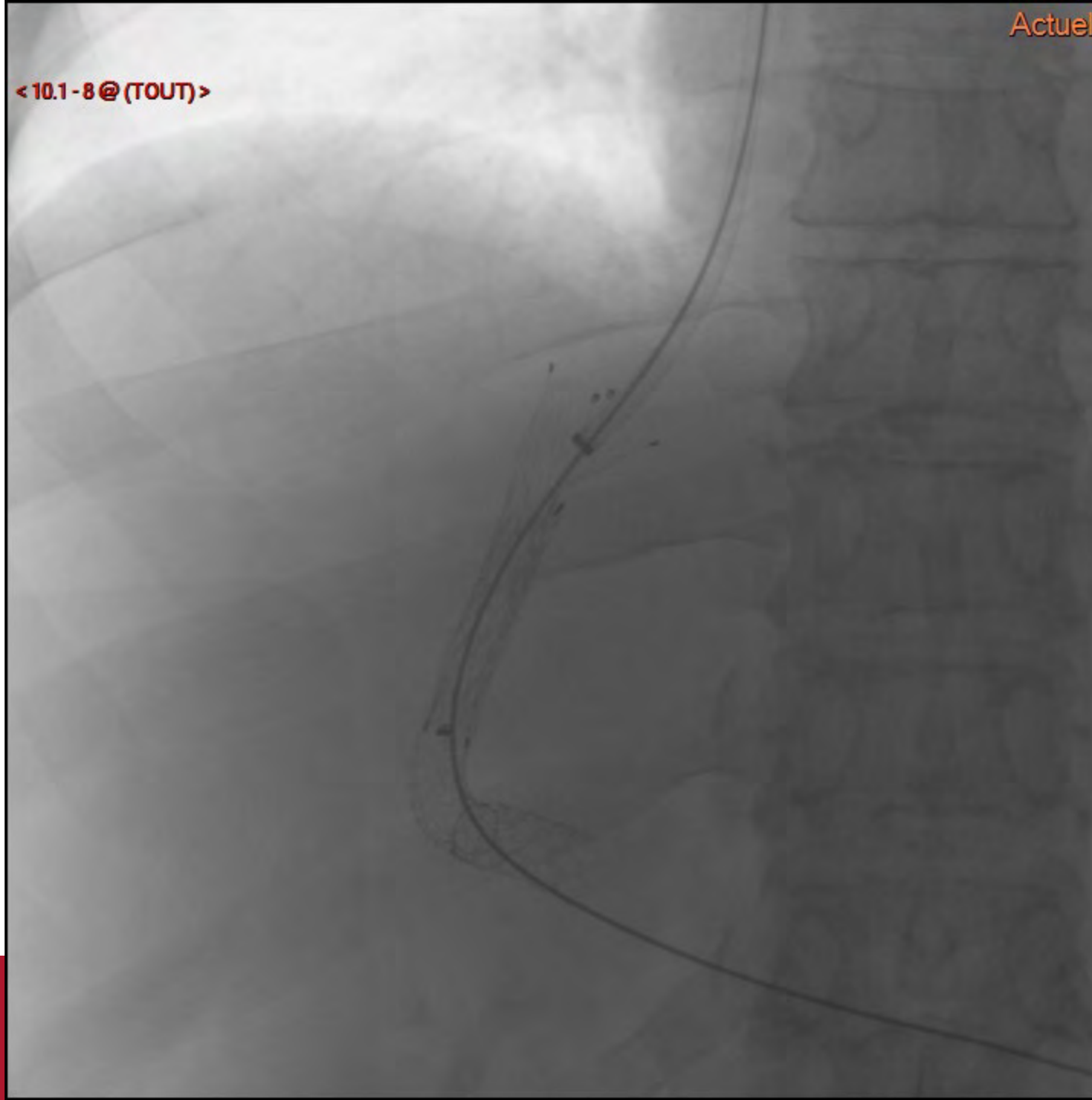
<10.1-6@(TOUT)>



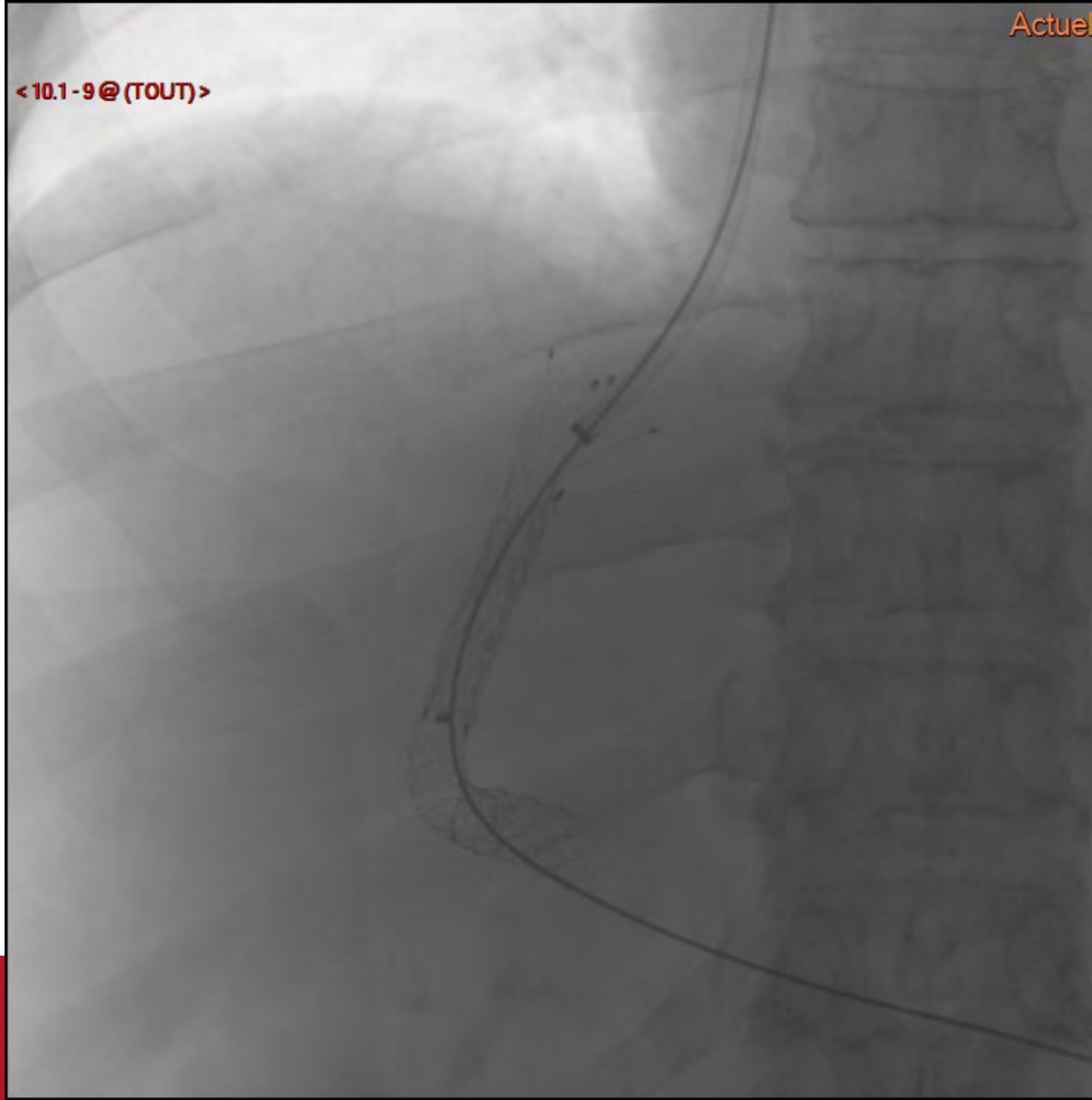
<10.1-7@(TOUT)>



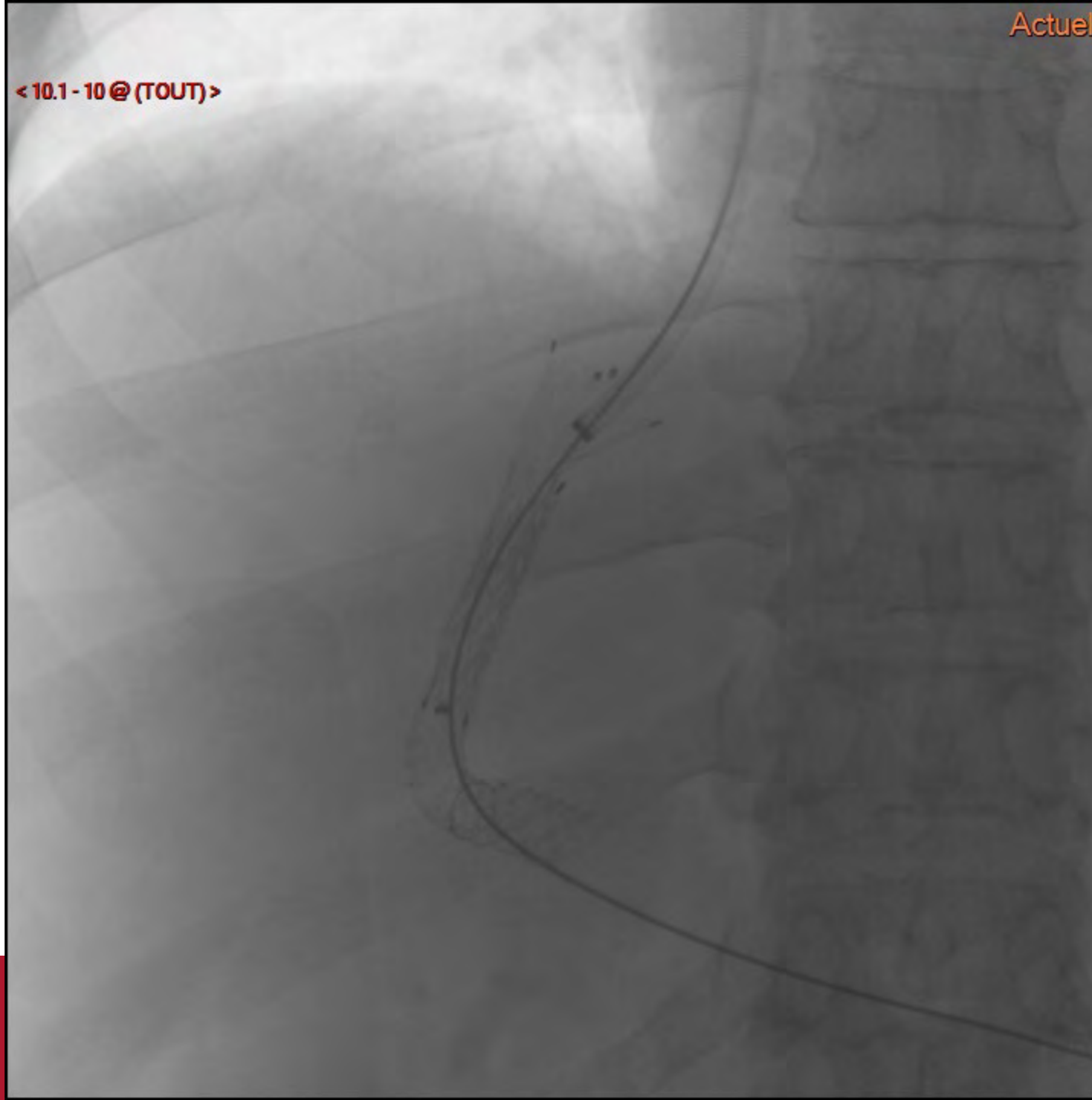
<10.1-8@(TOUT)>



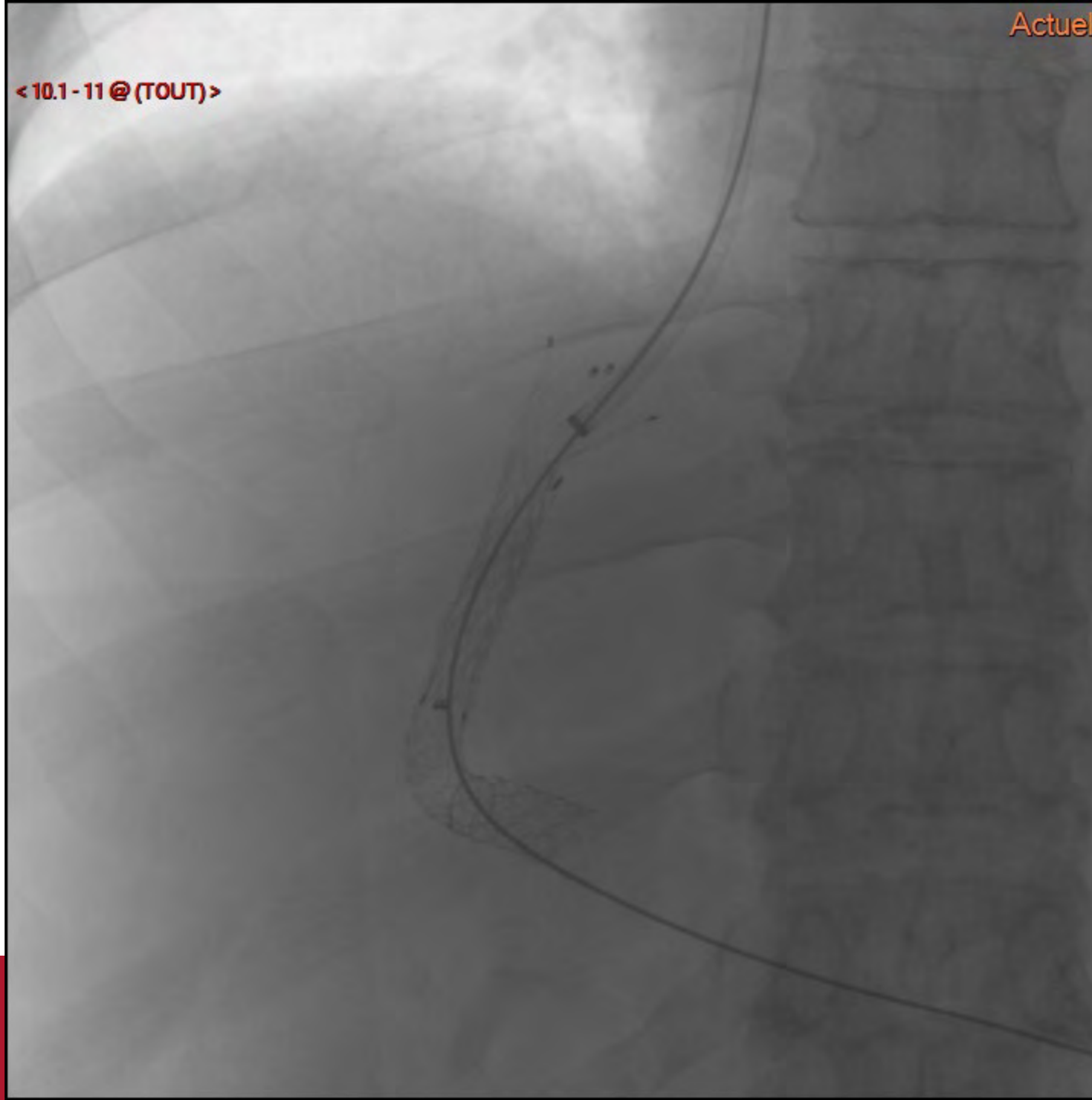
<10.1-9@ (TOUT)>



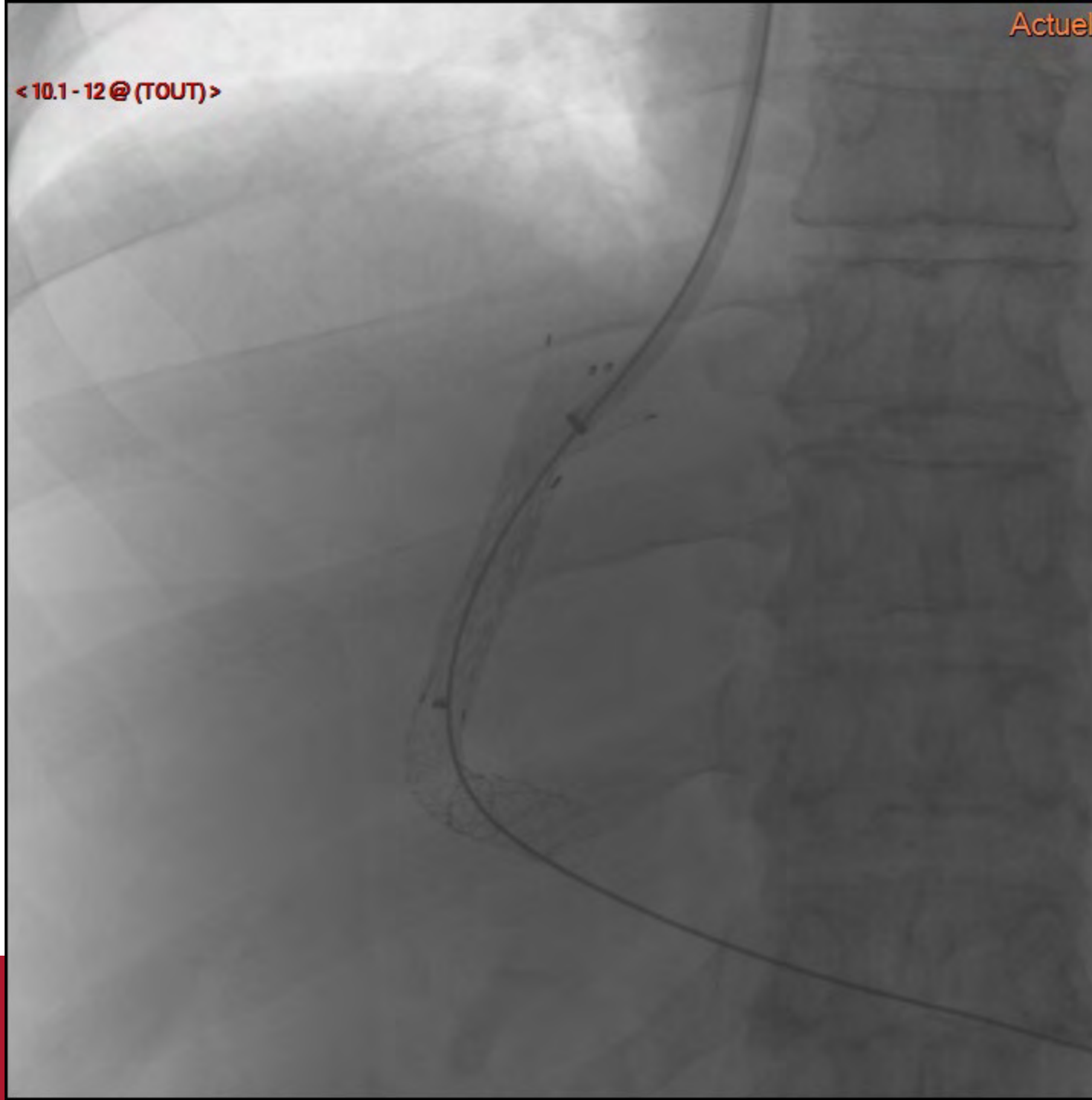
< 10.1 - 10 @ (TOUT) >



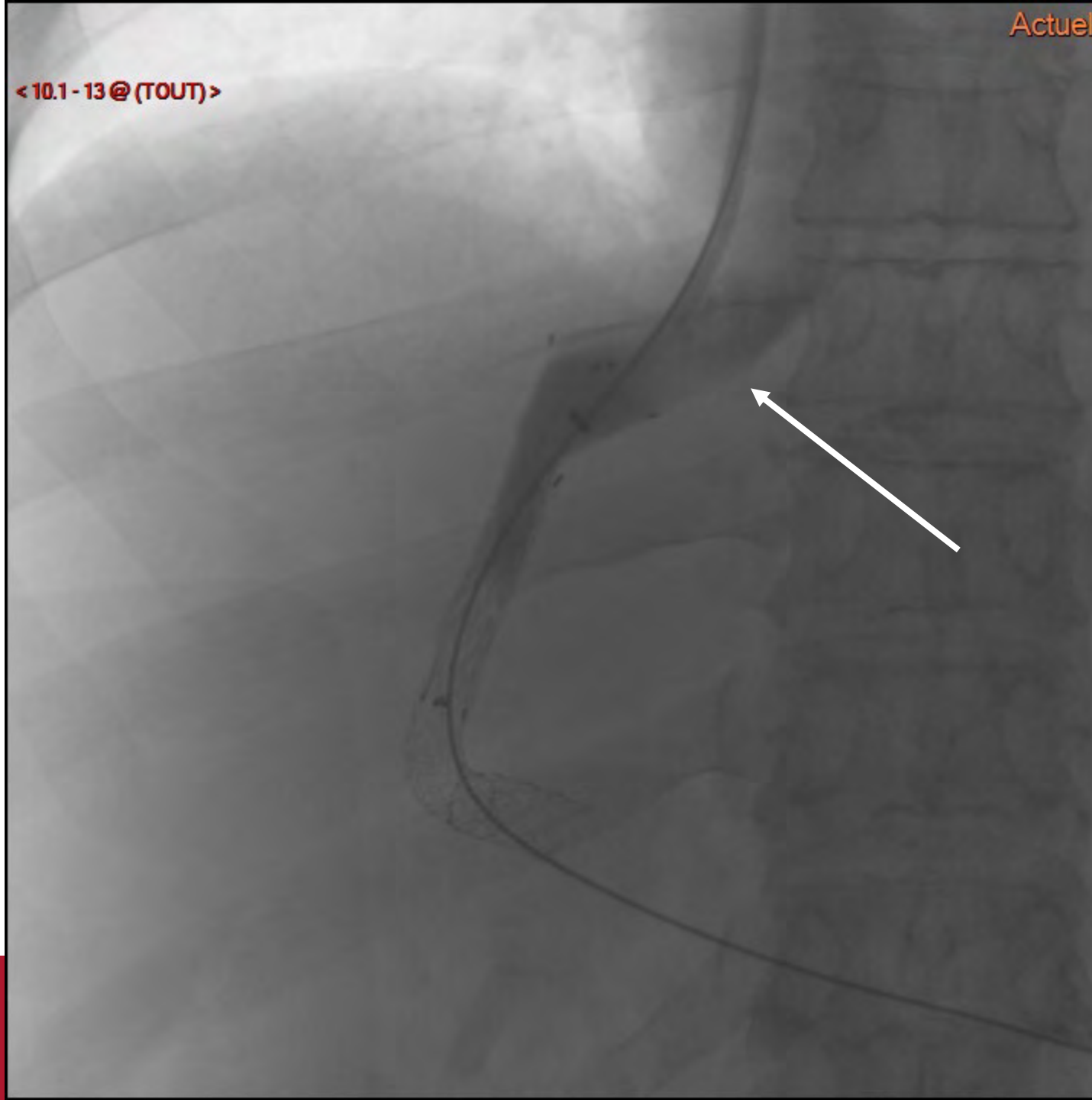
<10.1-11@ (TOUT)>



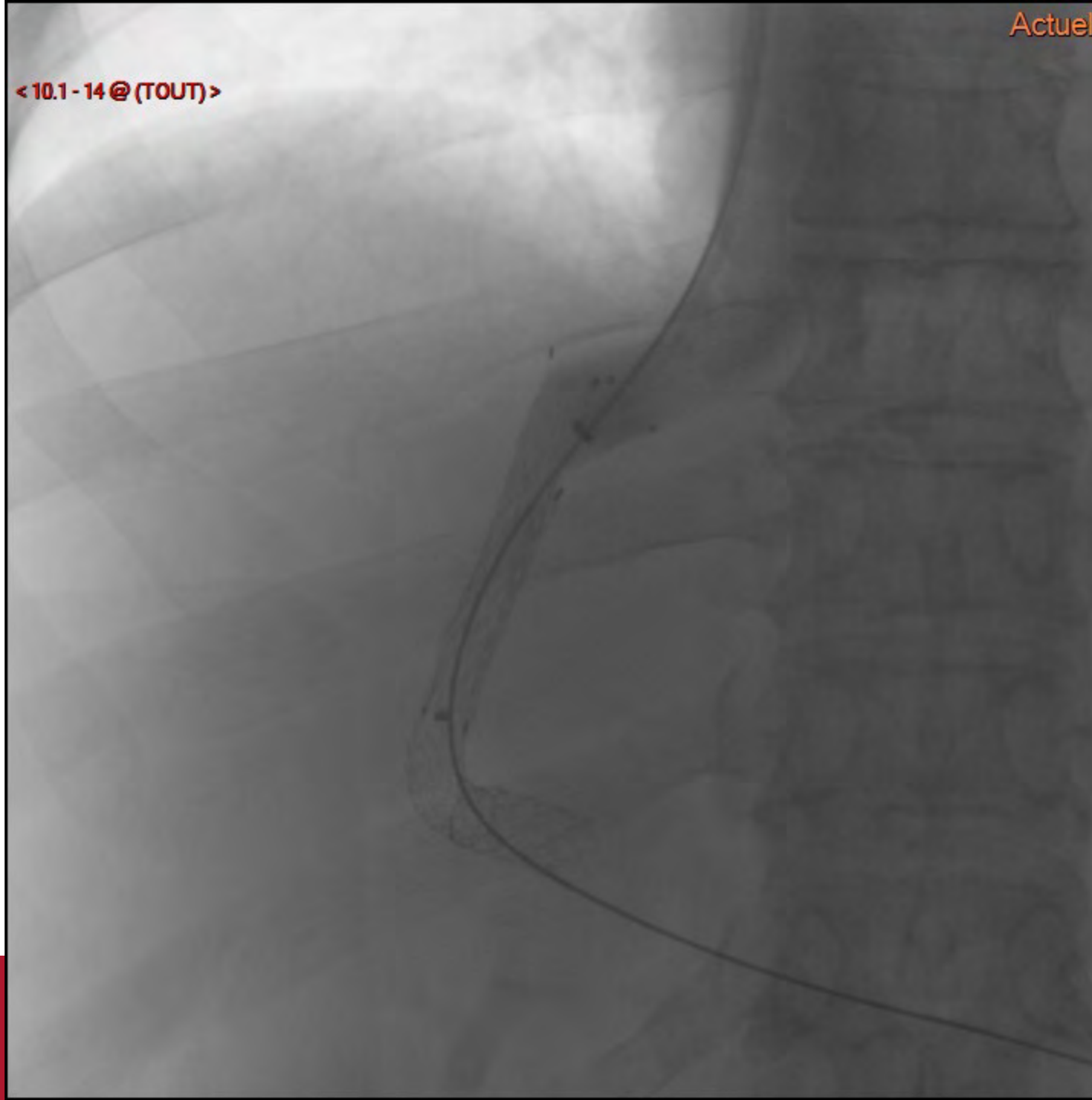
< 10.1 - 12 @ (TOUT) >



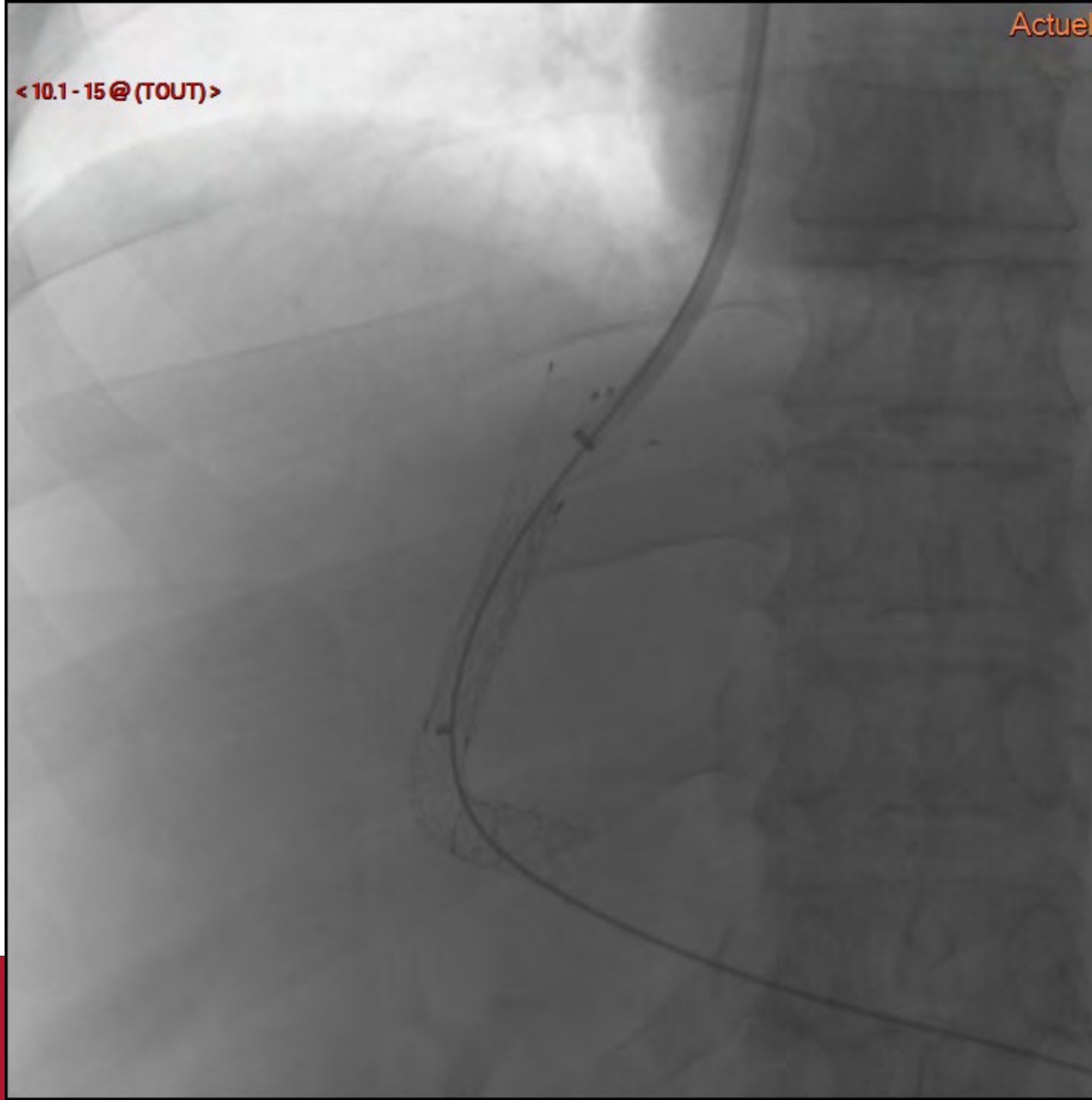
<10.1-13@ (TOUT)>



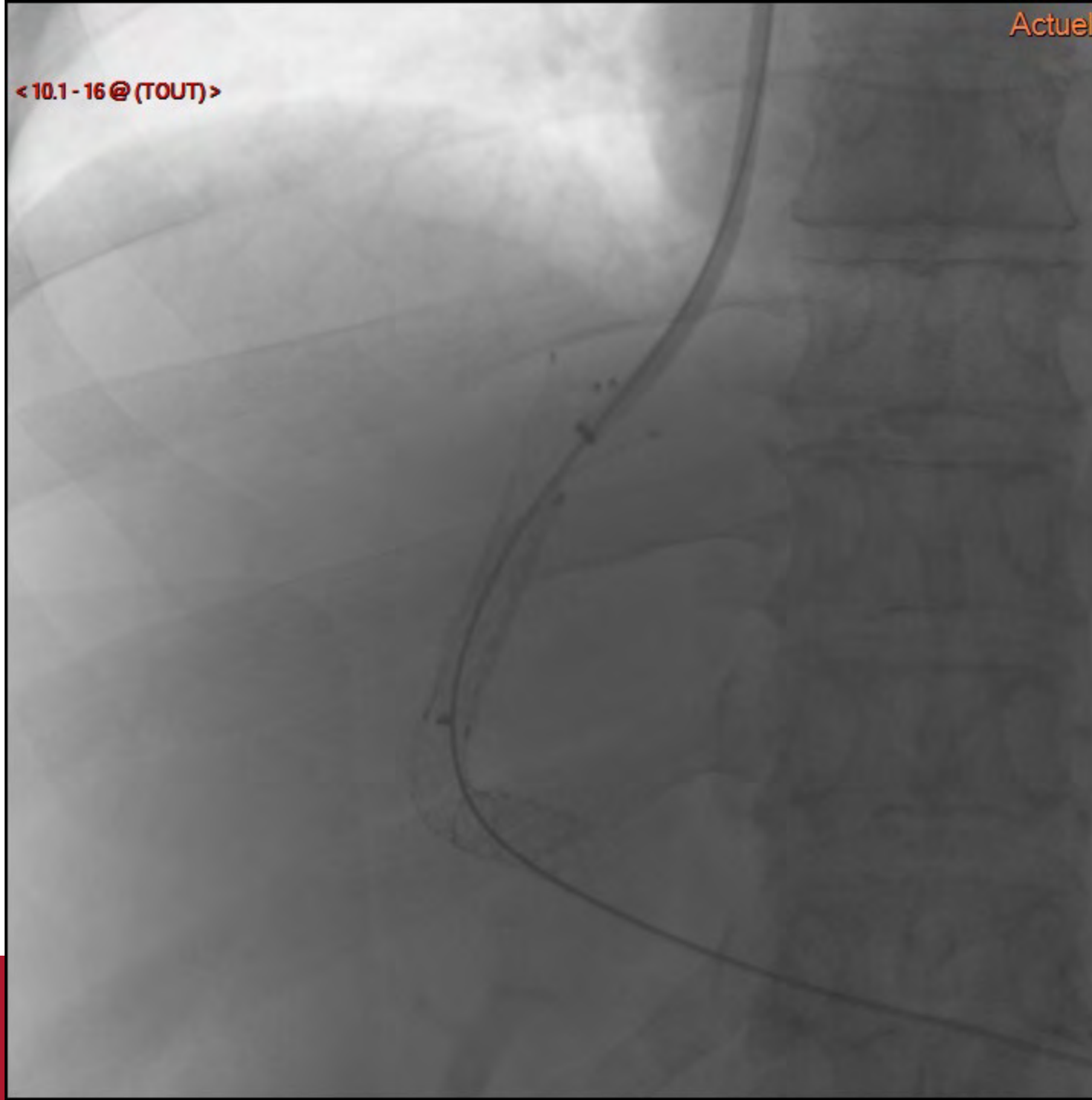
< 10.1 - 14 @ (TOUT) >



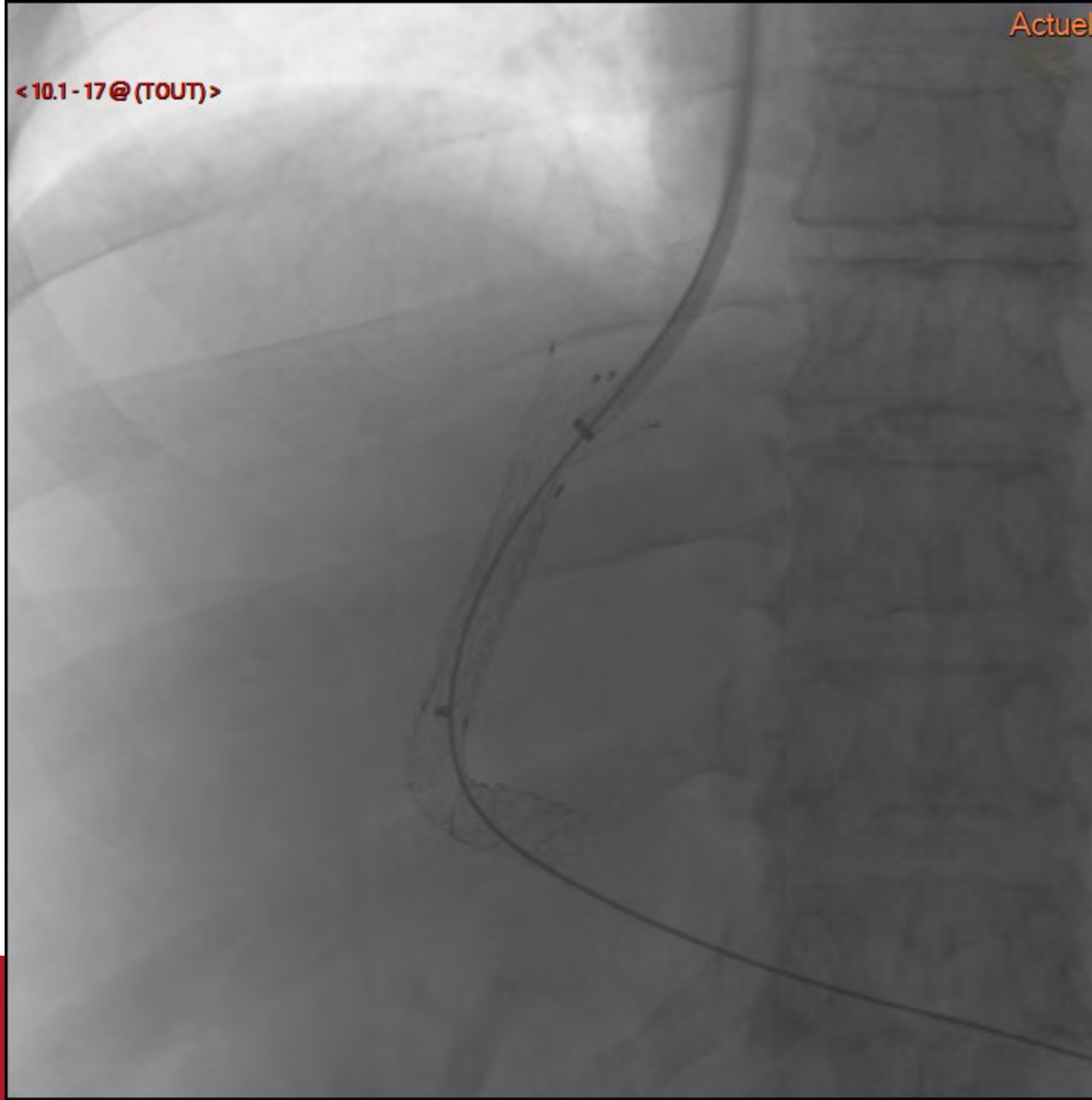
< 10.1 - 15 @ (TOUT) >



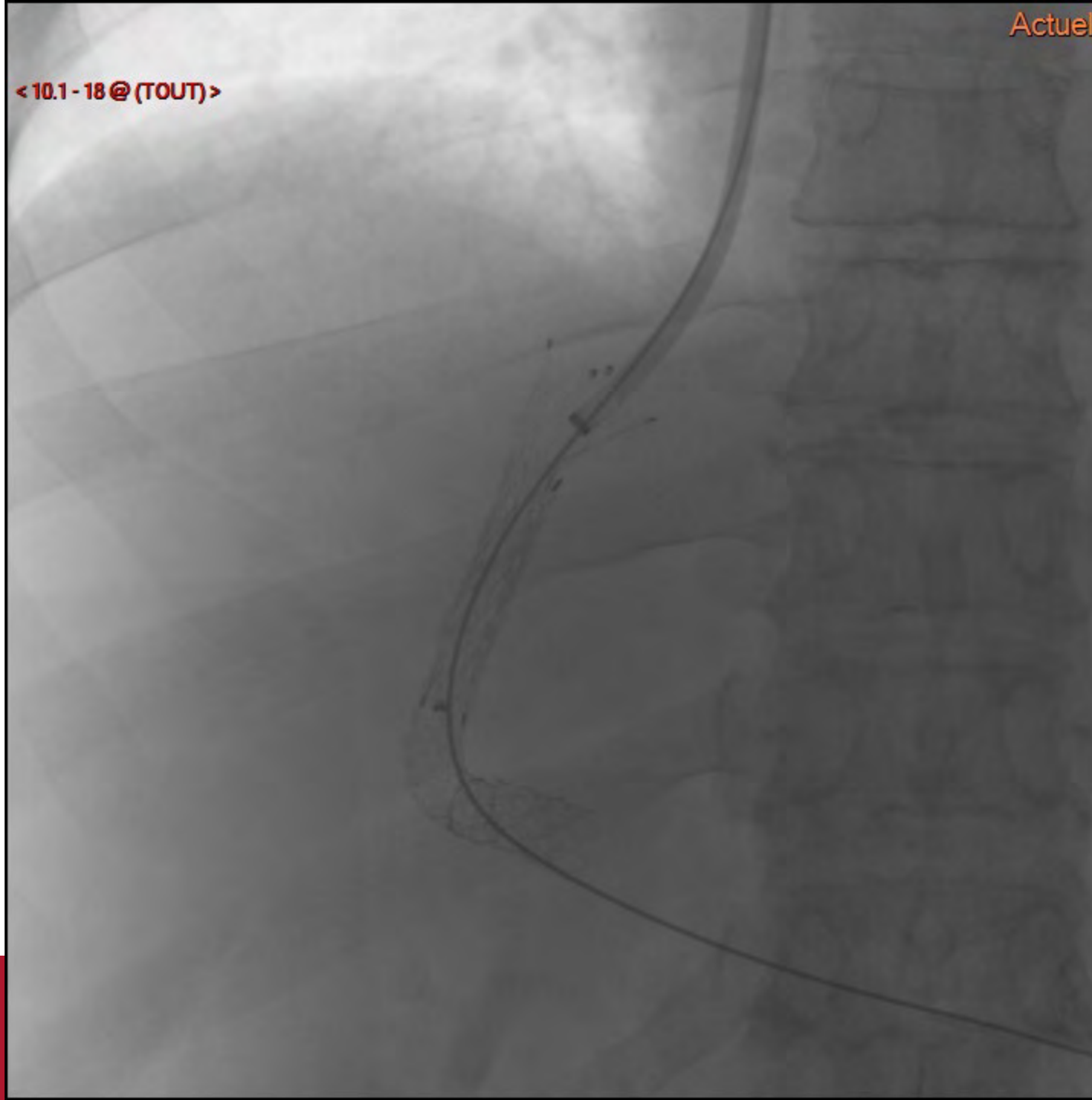
< 10.1 - 16 @ (TOUT) >



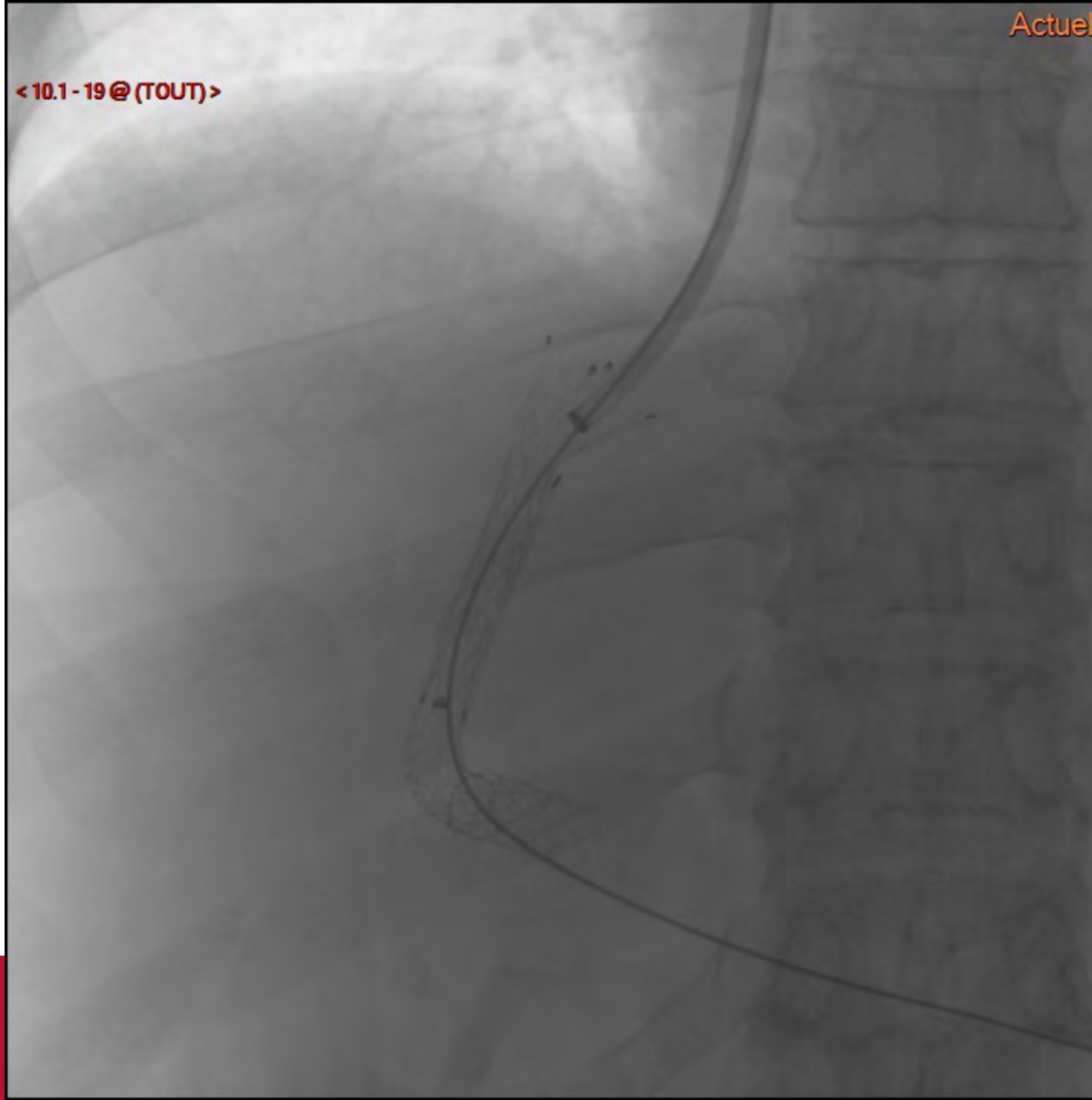
<10.1-17@ (TOUT)>



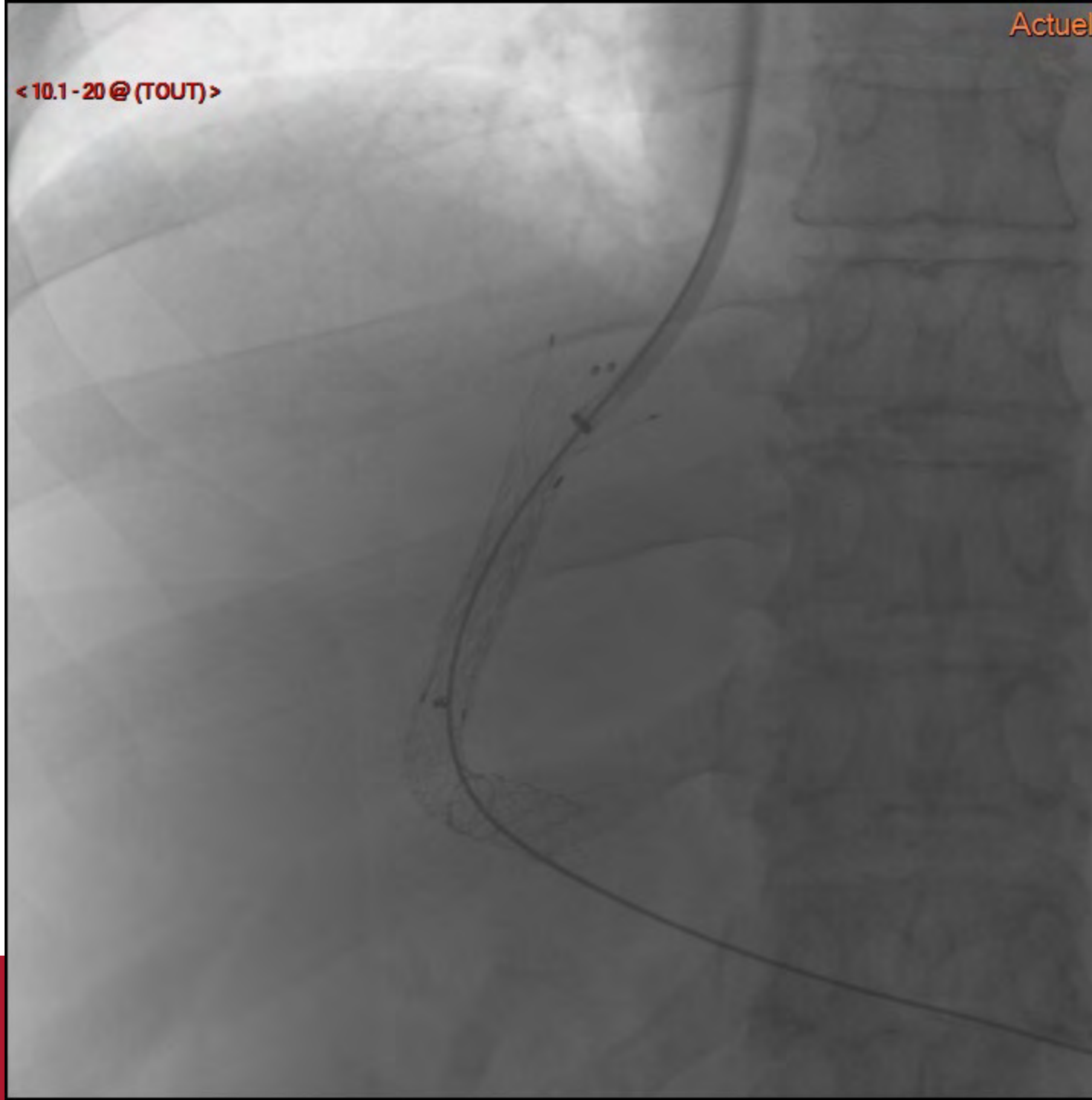
< 10.1 - 18 @ (TOUT) >



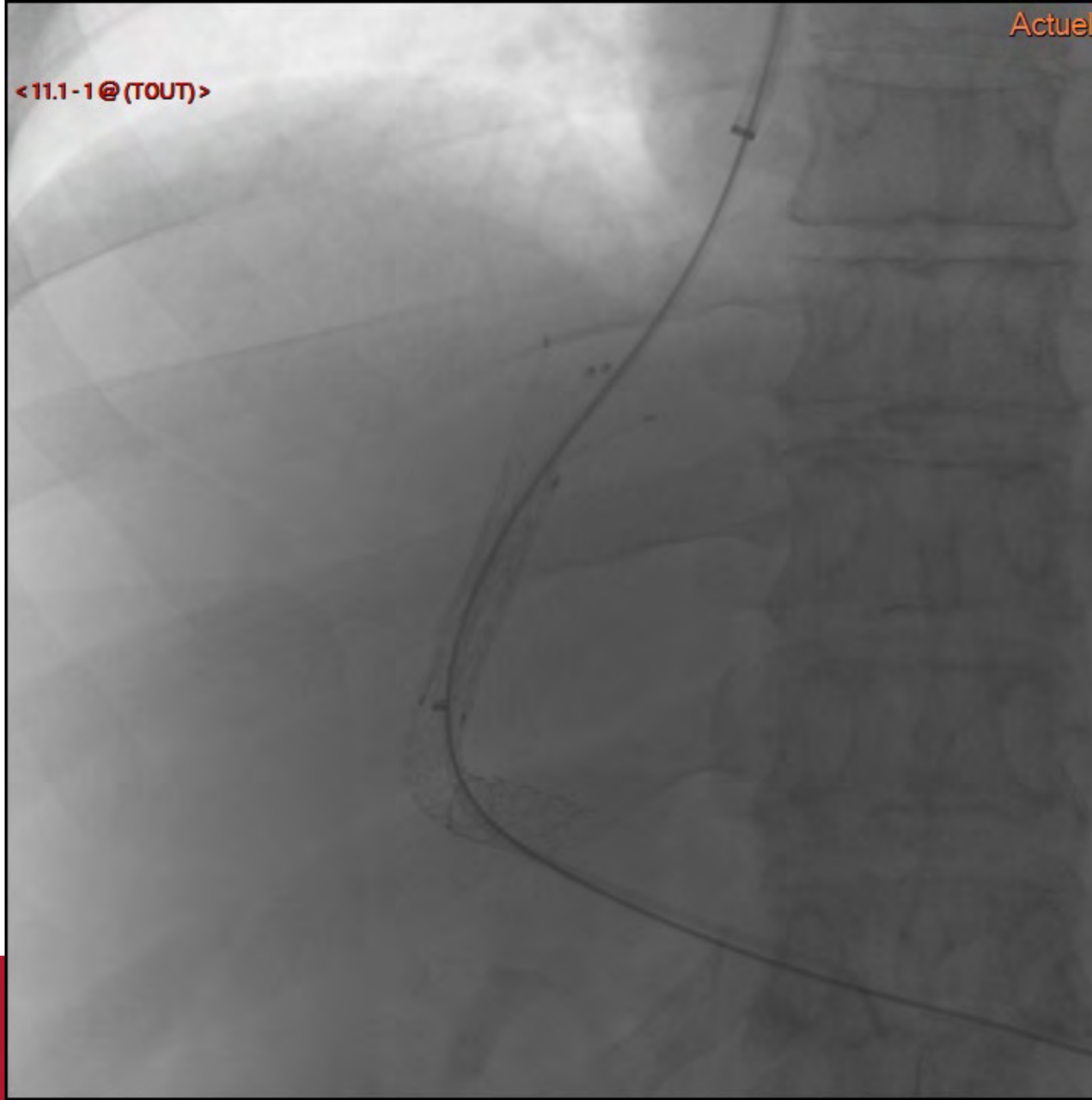
< 10.1 - 19 @ (TOUT) >



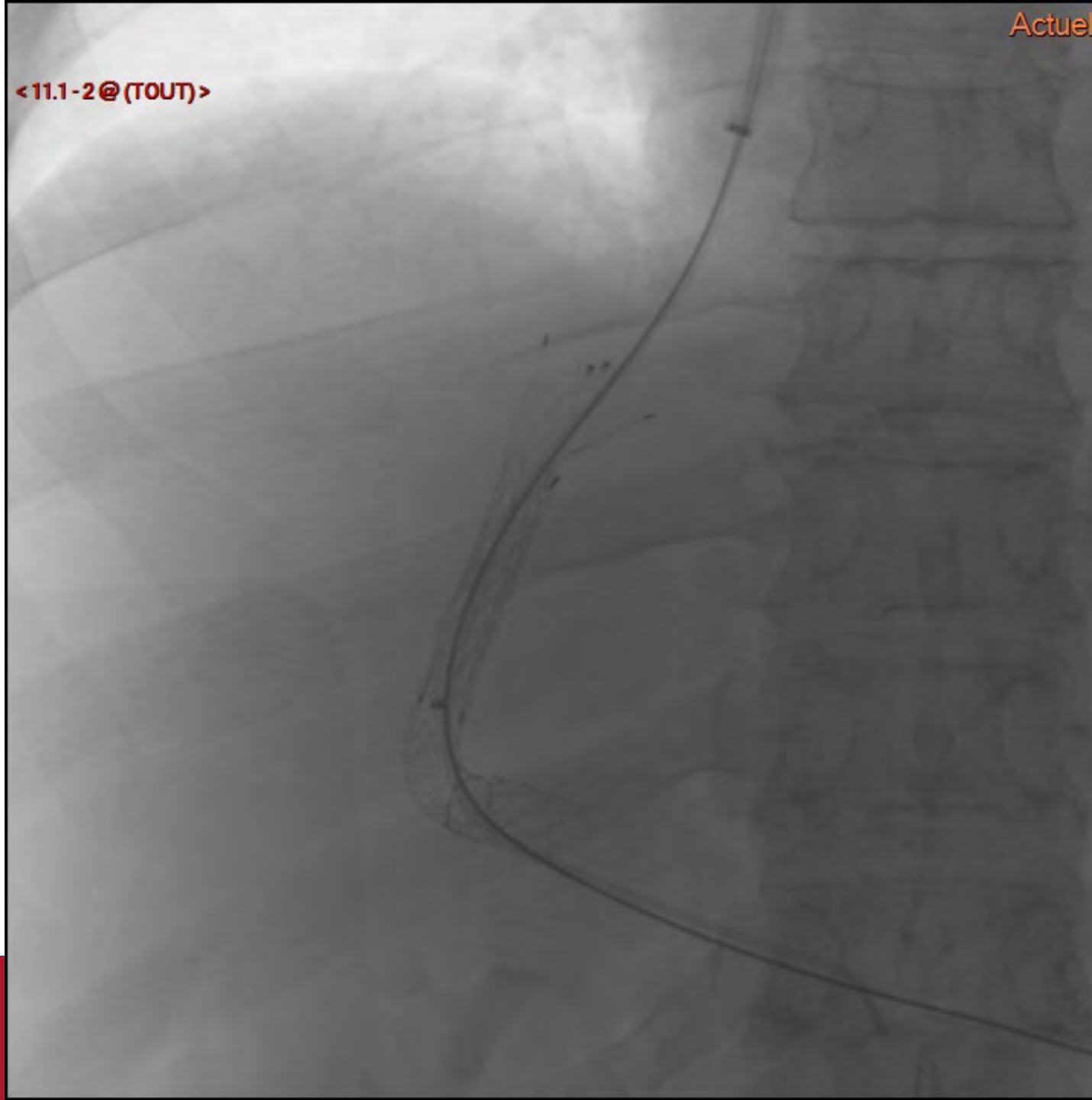
< 10.1 - 20 @ (TOUT) >



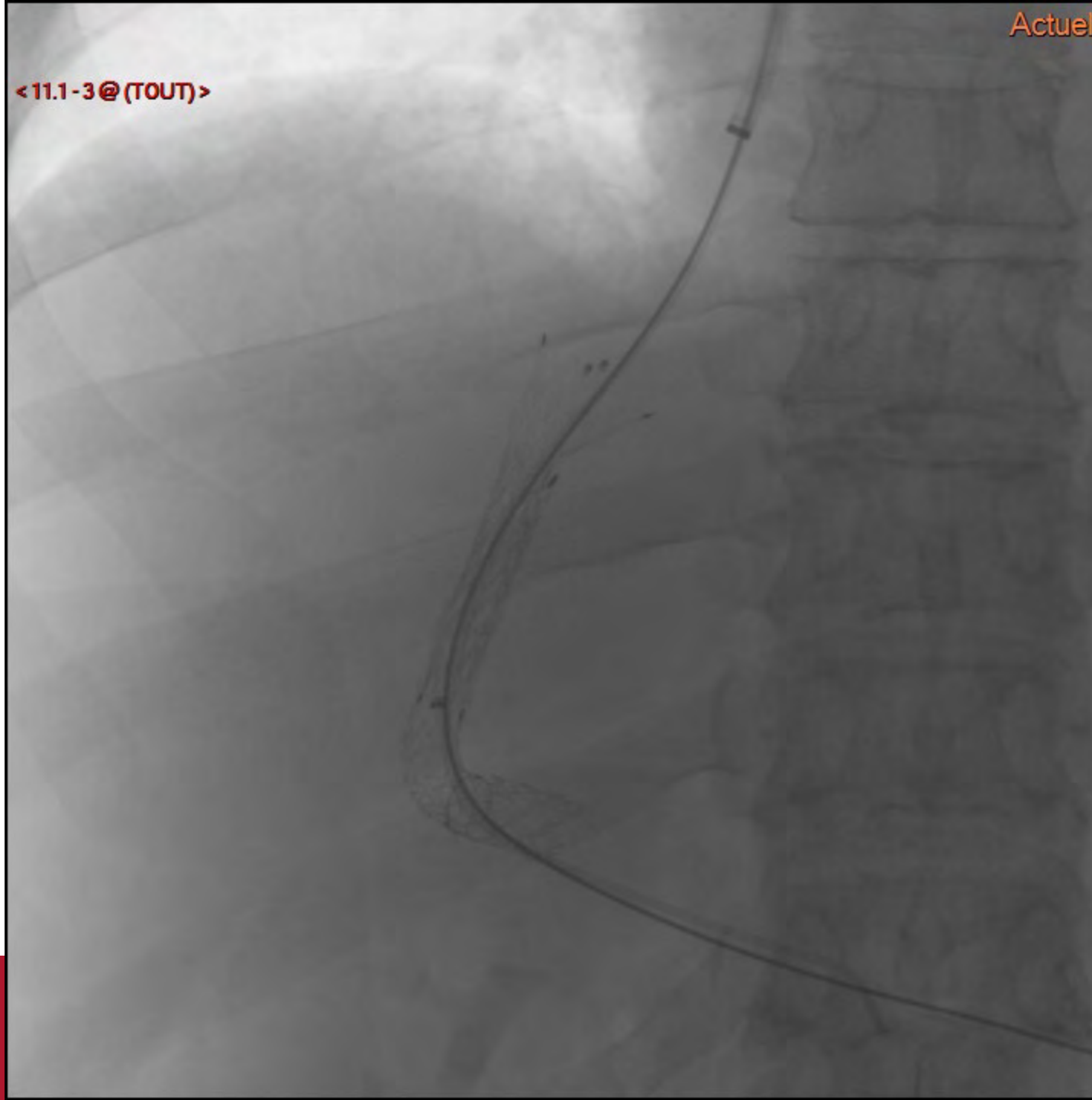
<11.1-1@ (TOU) >



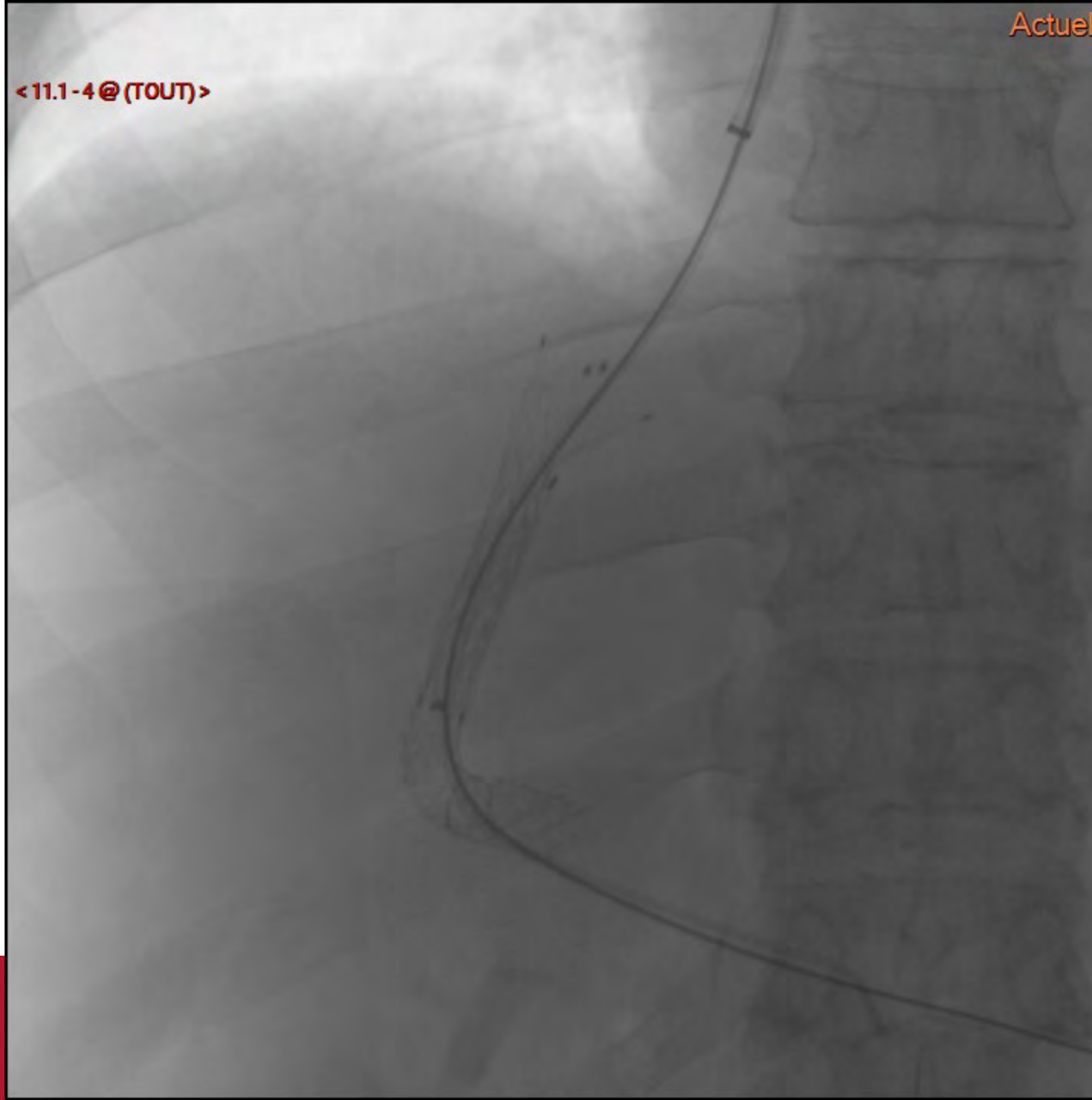
<11.1-2@(TOUT)>



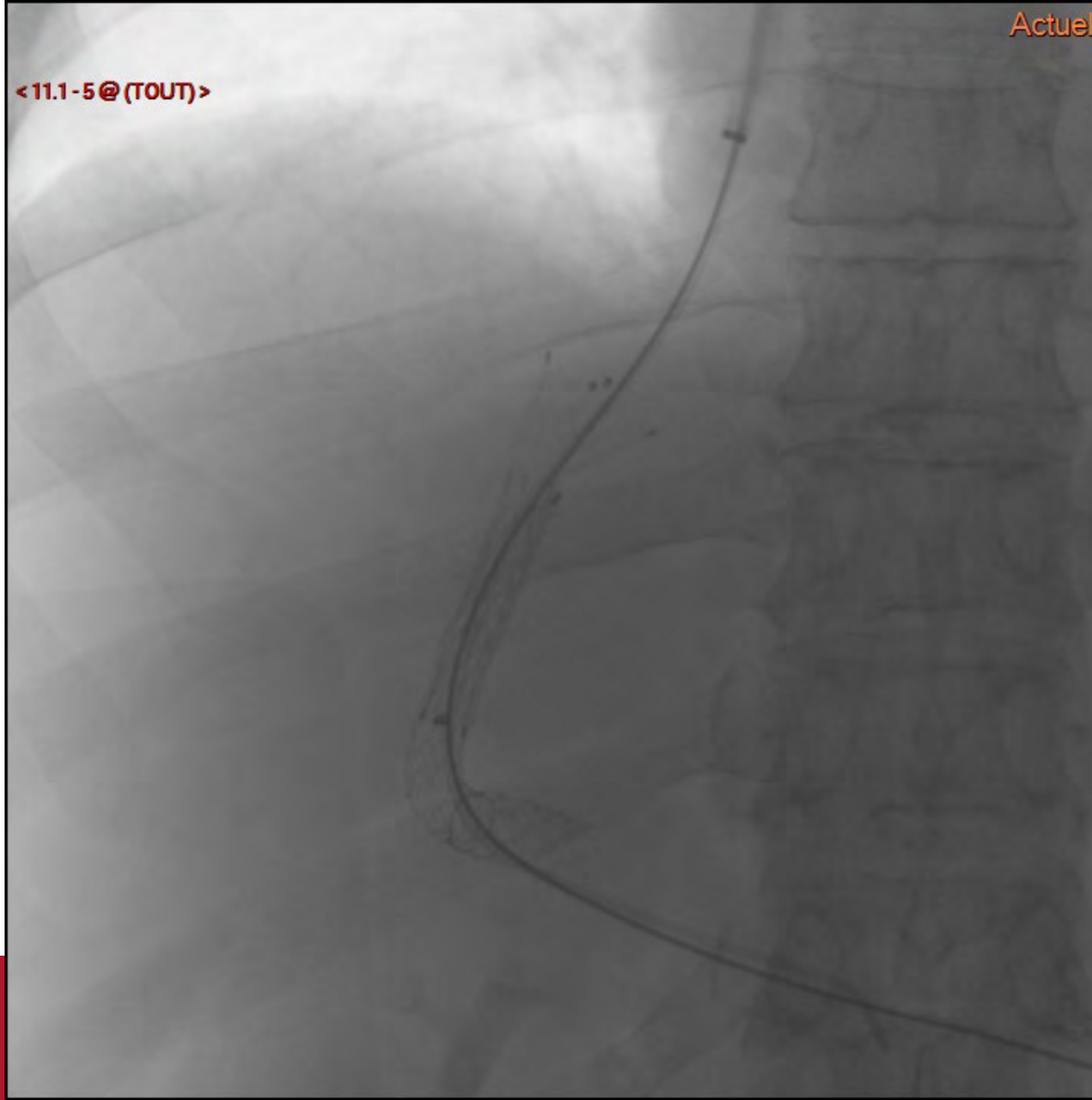
<11.1-3@ (TOUT)>



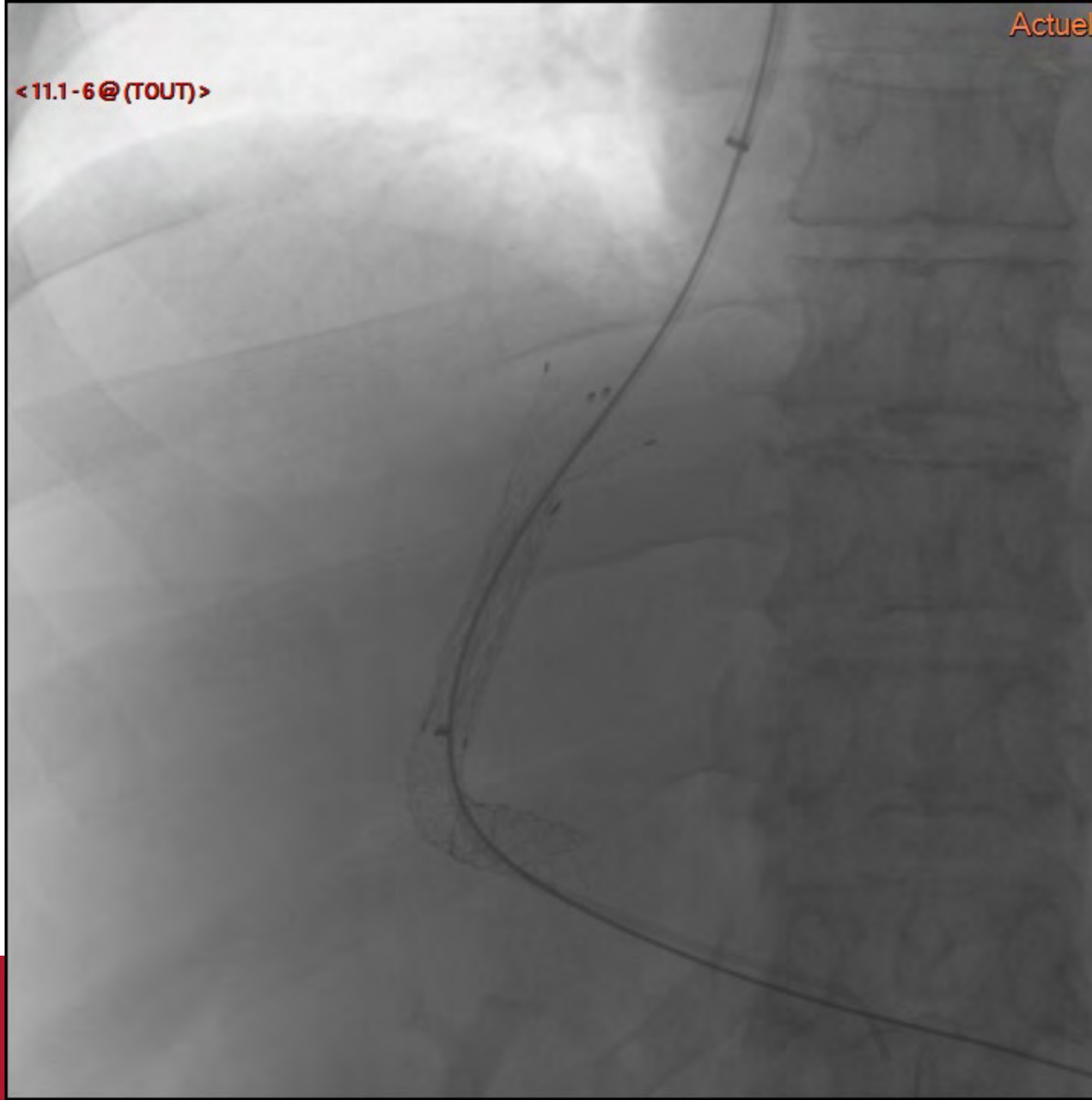
<11.1-4@ (TOUT)>



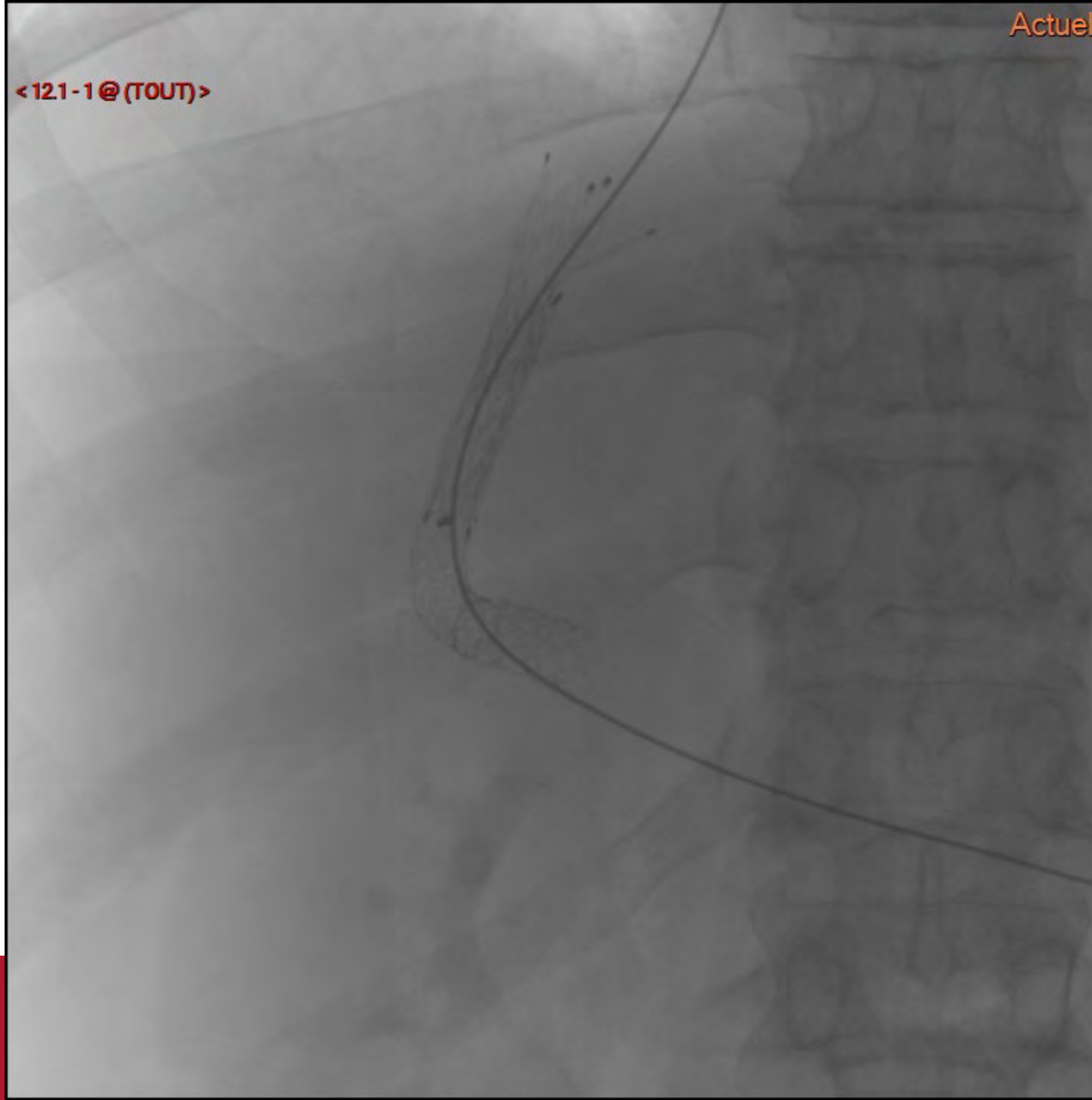
<11.1-5@(TOUT)>



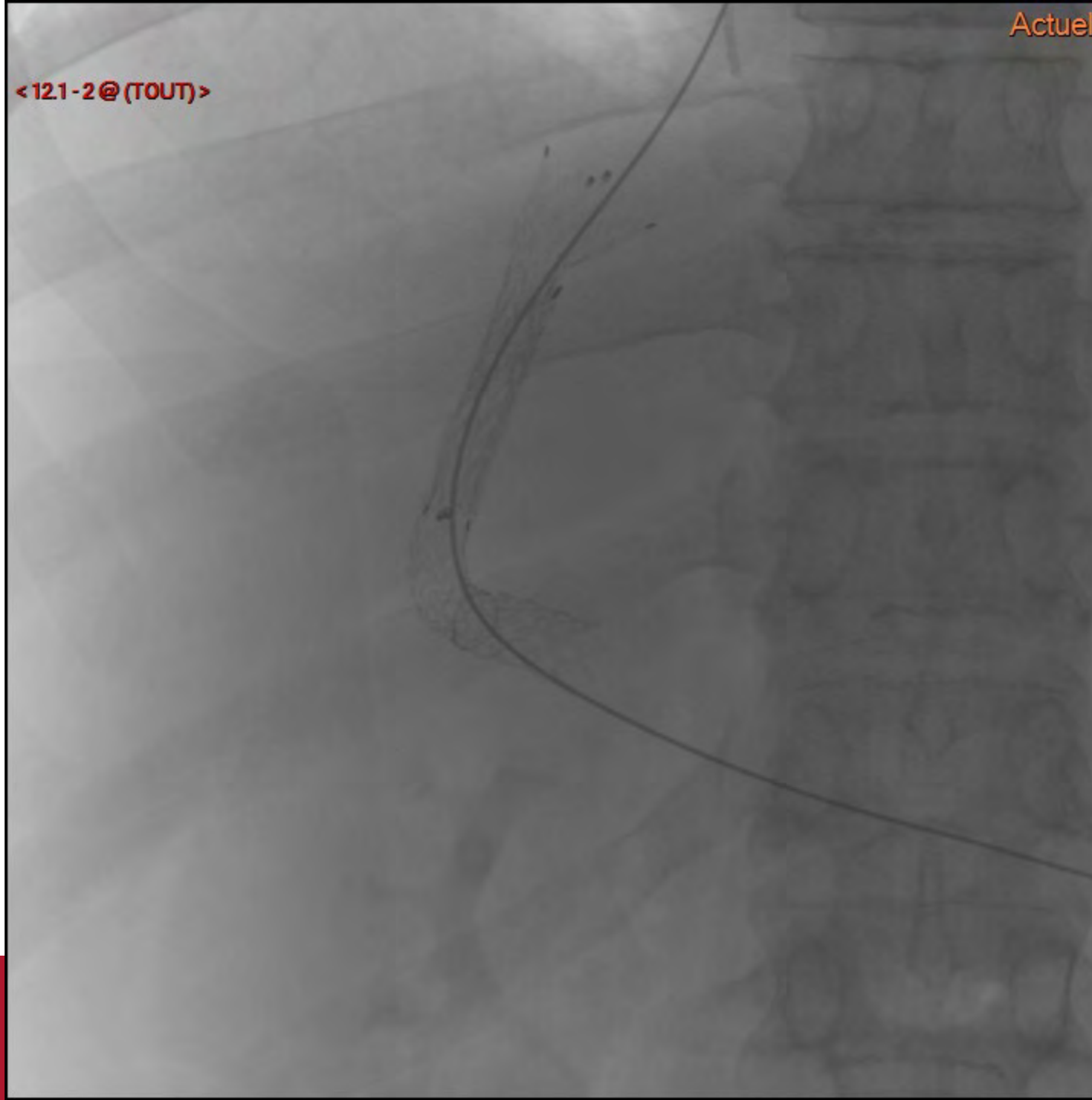
<11.1-6@ (TOUT)>



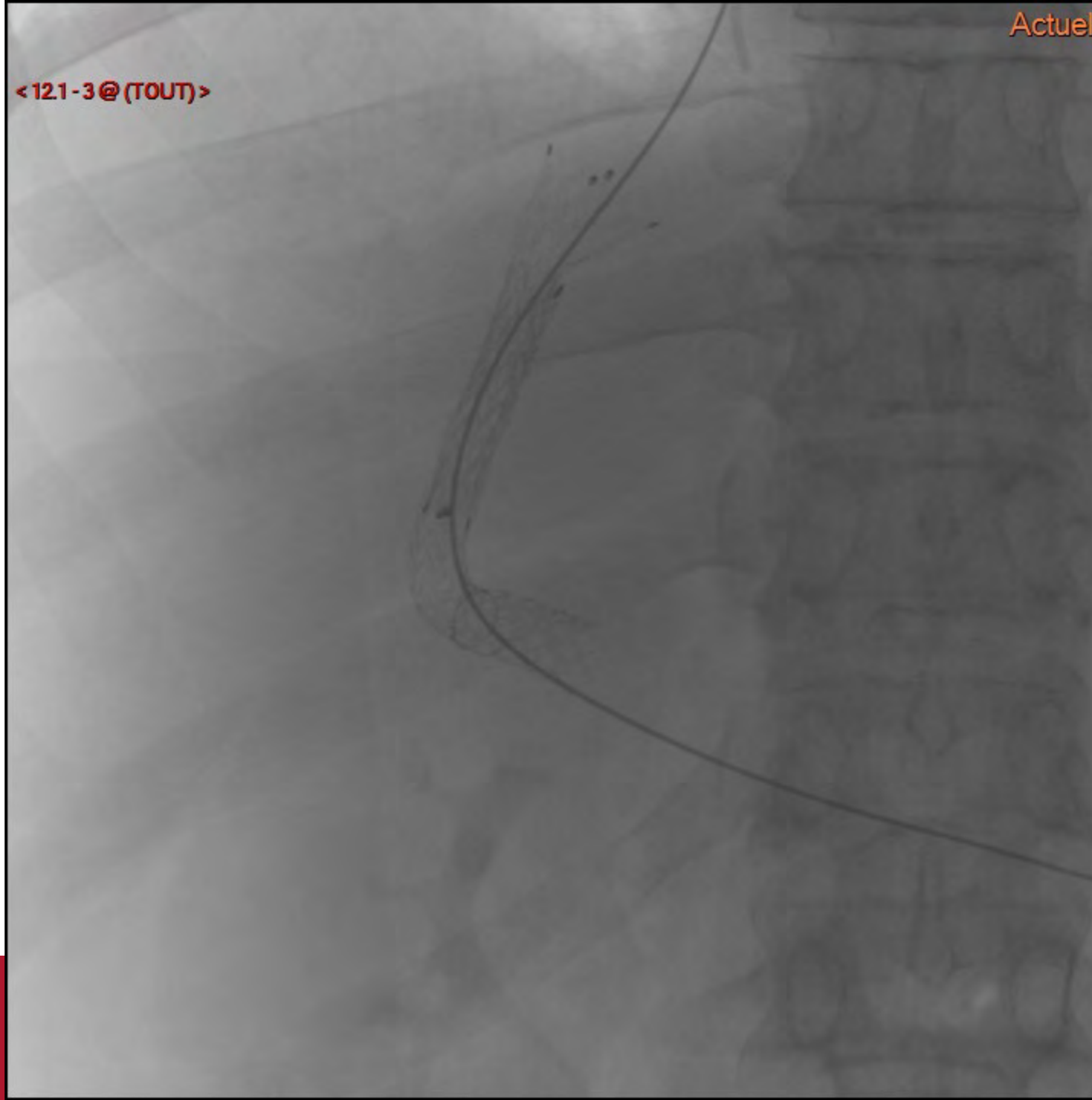
<121-1@TOUT>



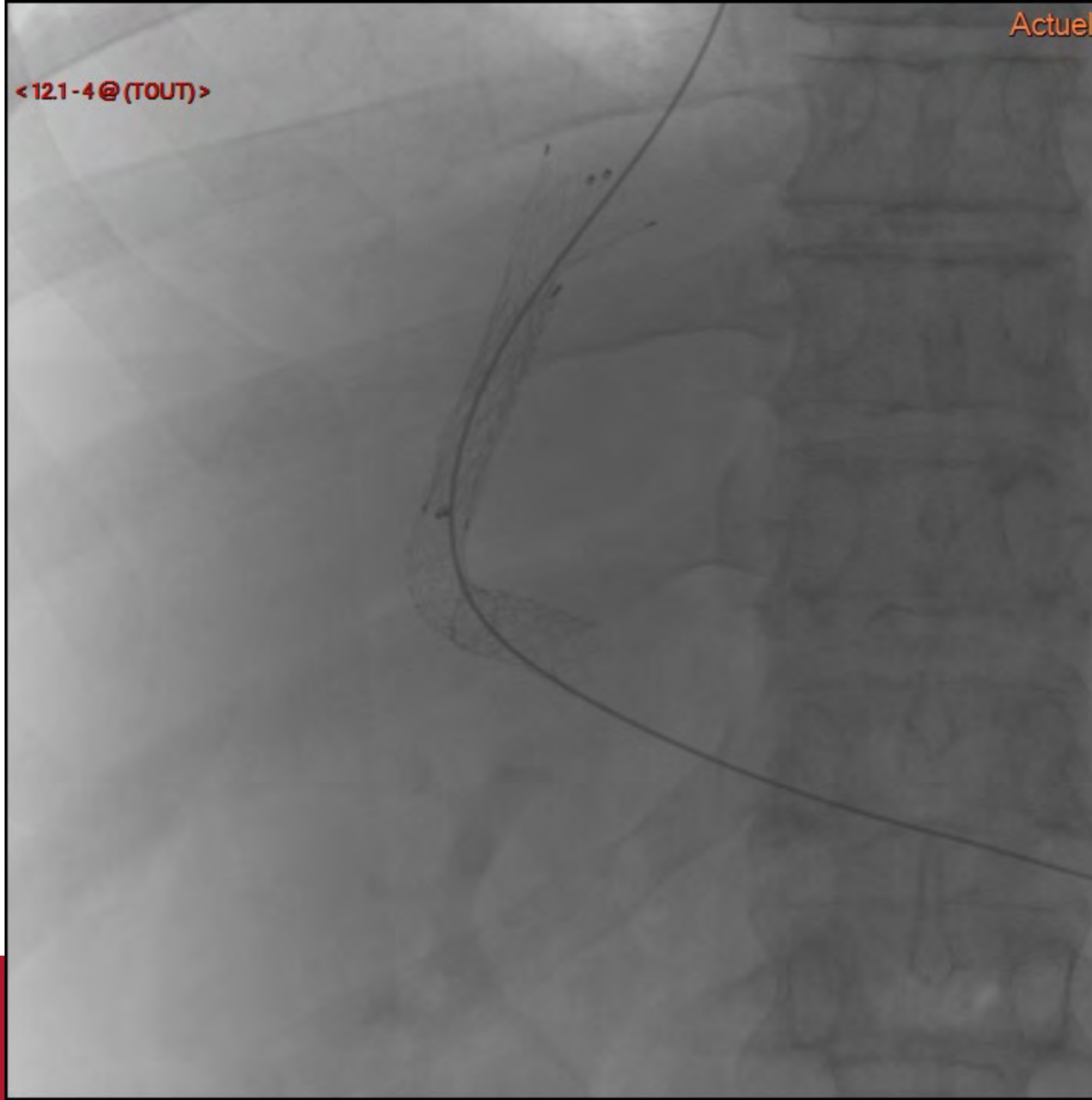
<121-2@(TOUT)>



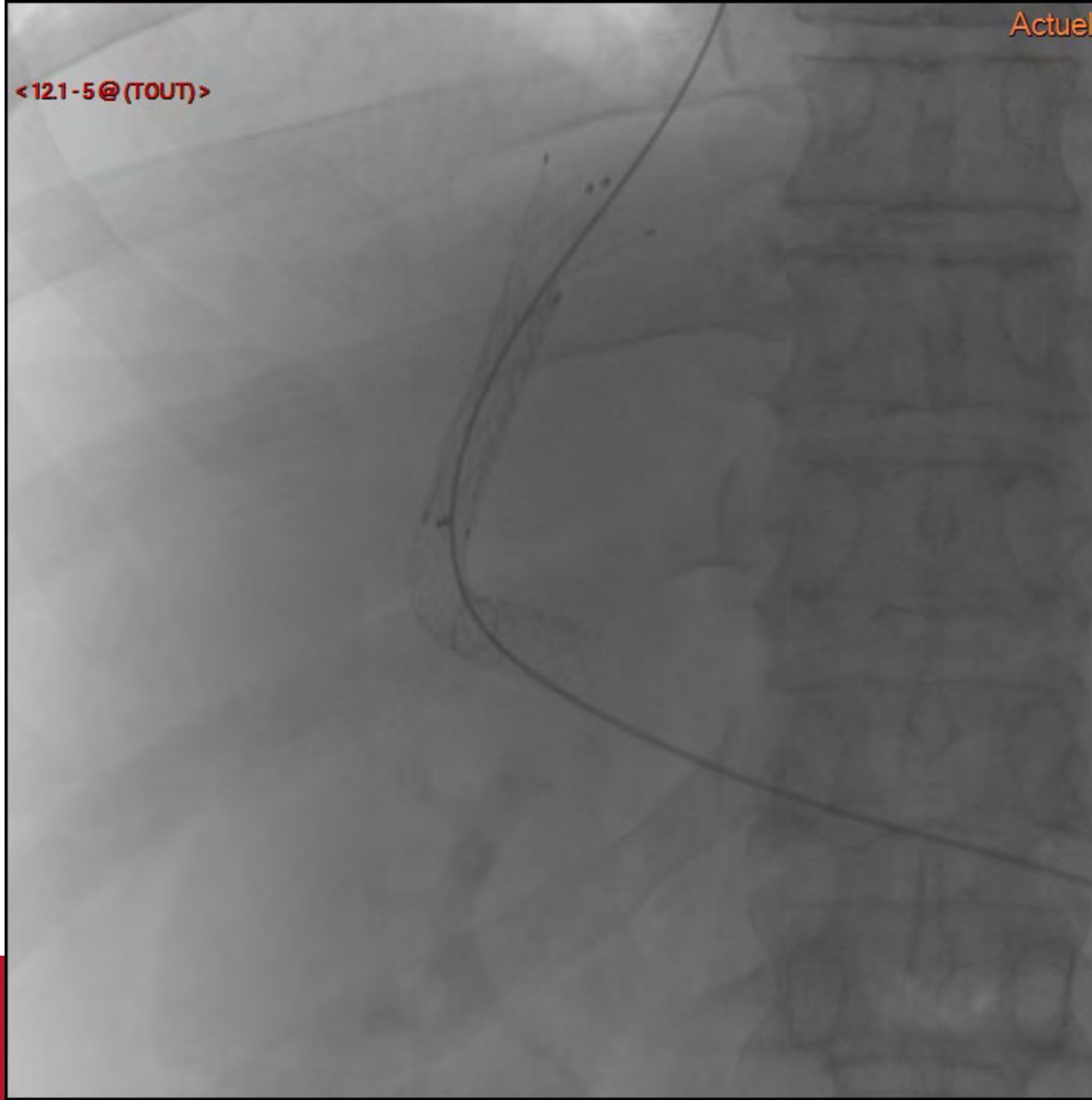
<121-3@ (TOUT)>



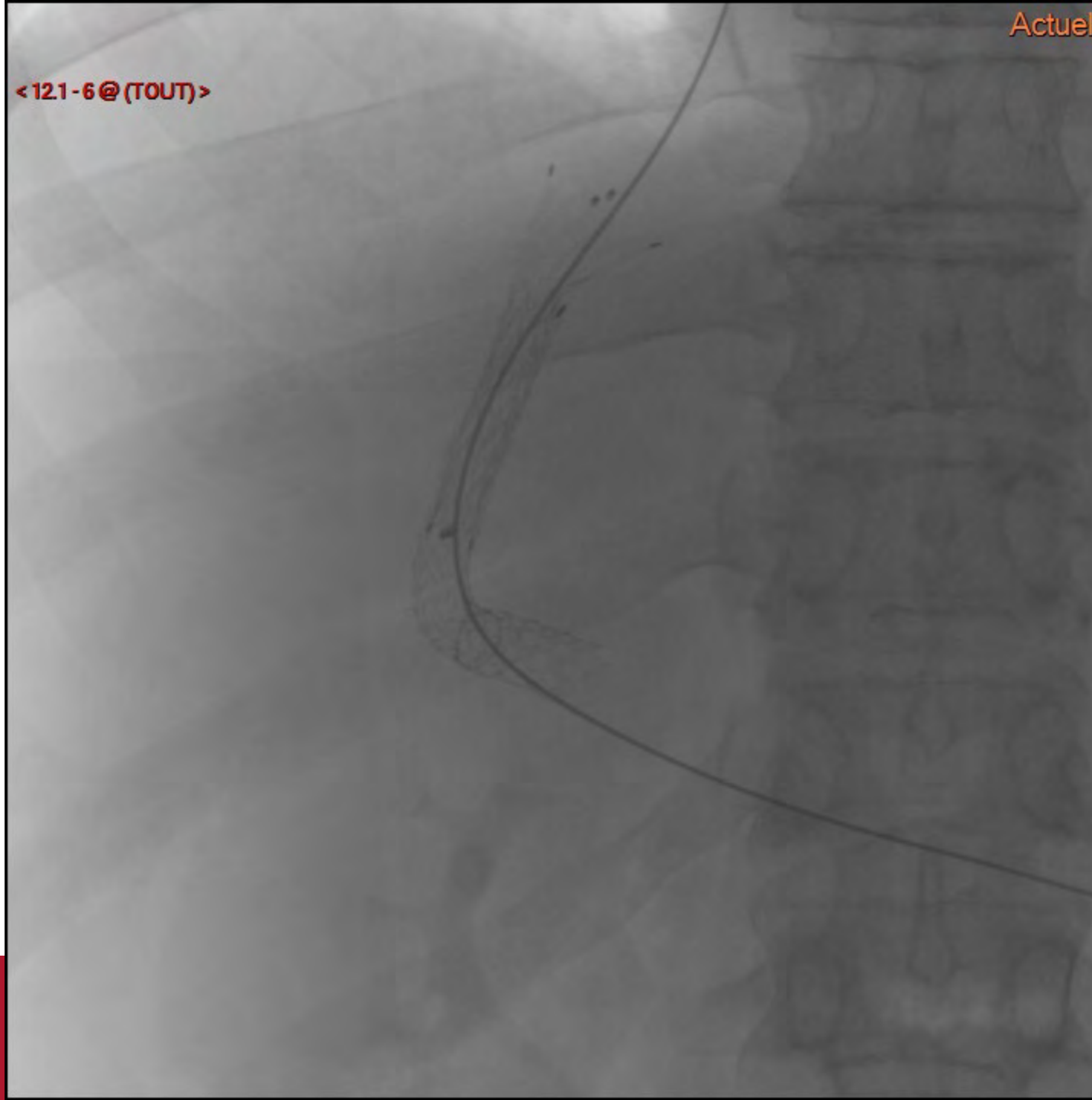
<121-4@ (TOUT)>



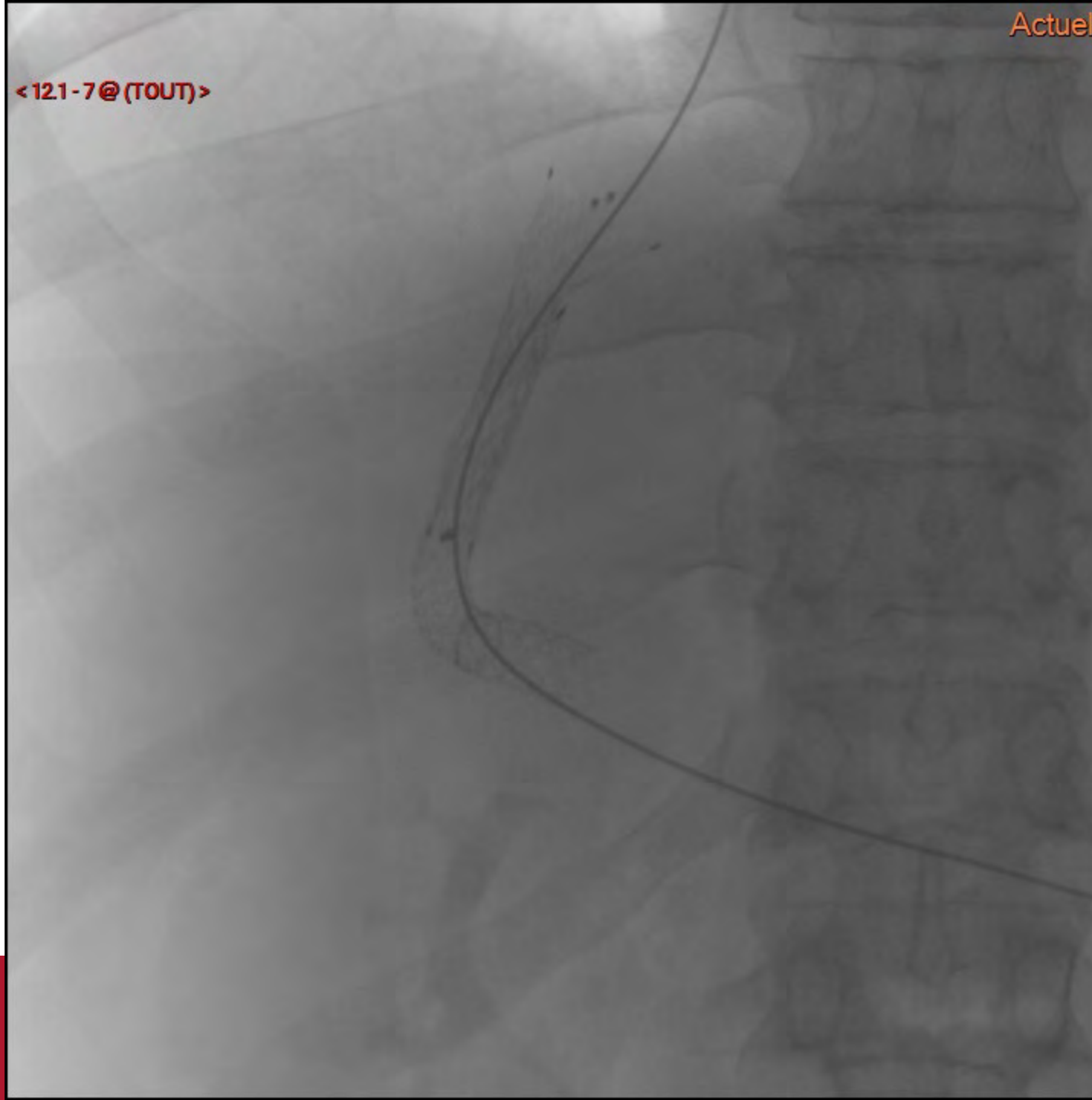
<121-5@ (TOUT)>



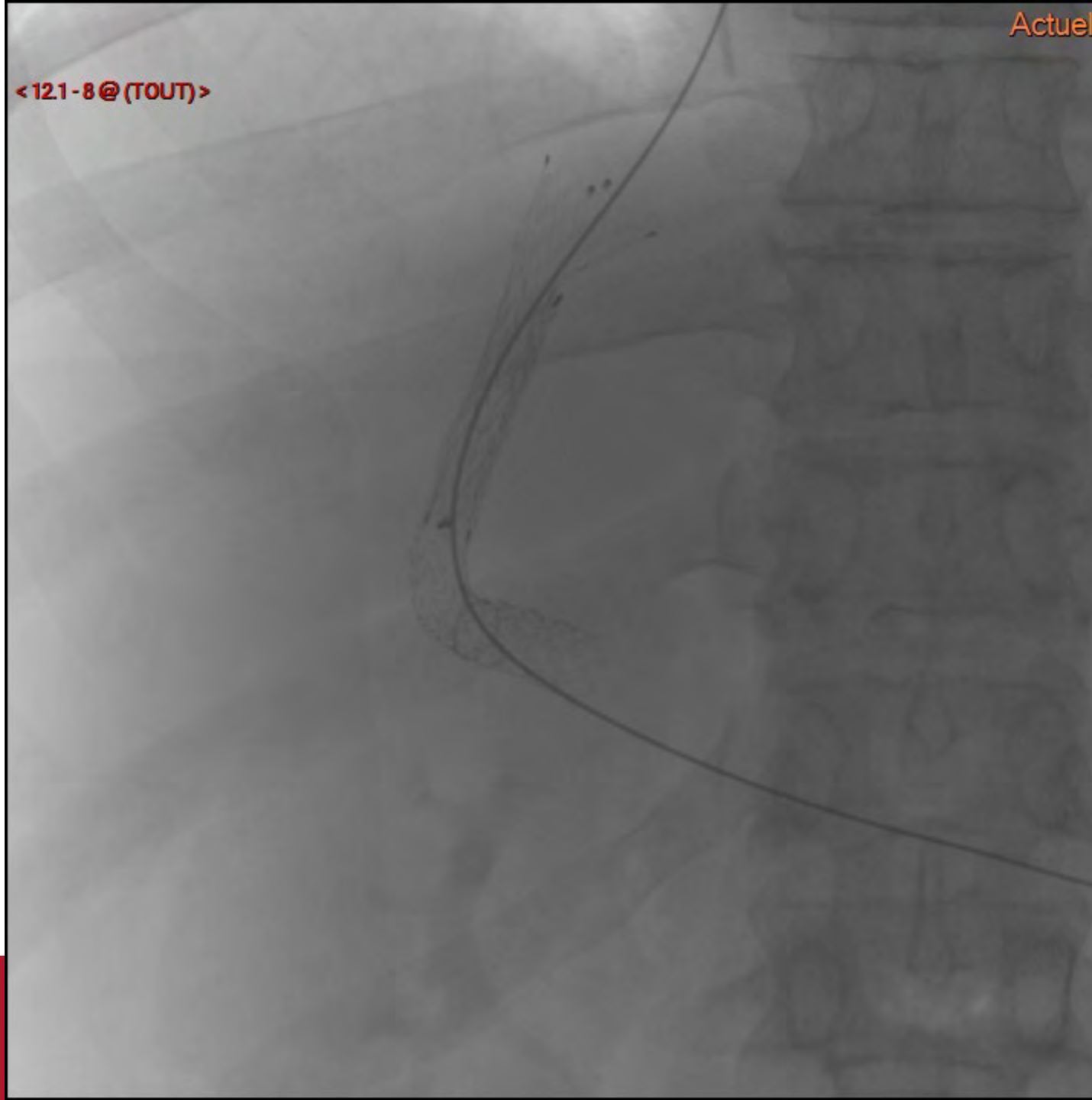
<121-6@ (TOUT)>



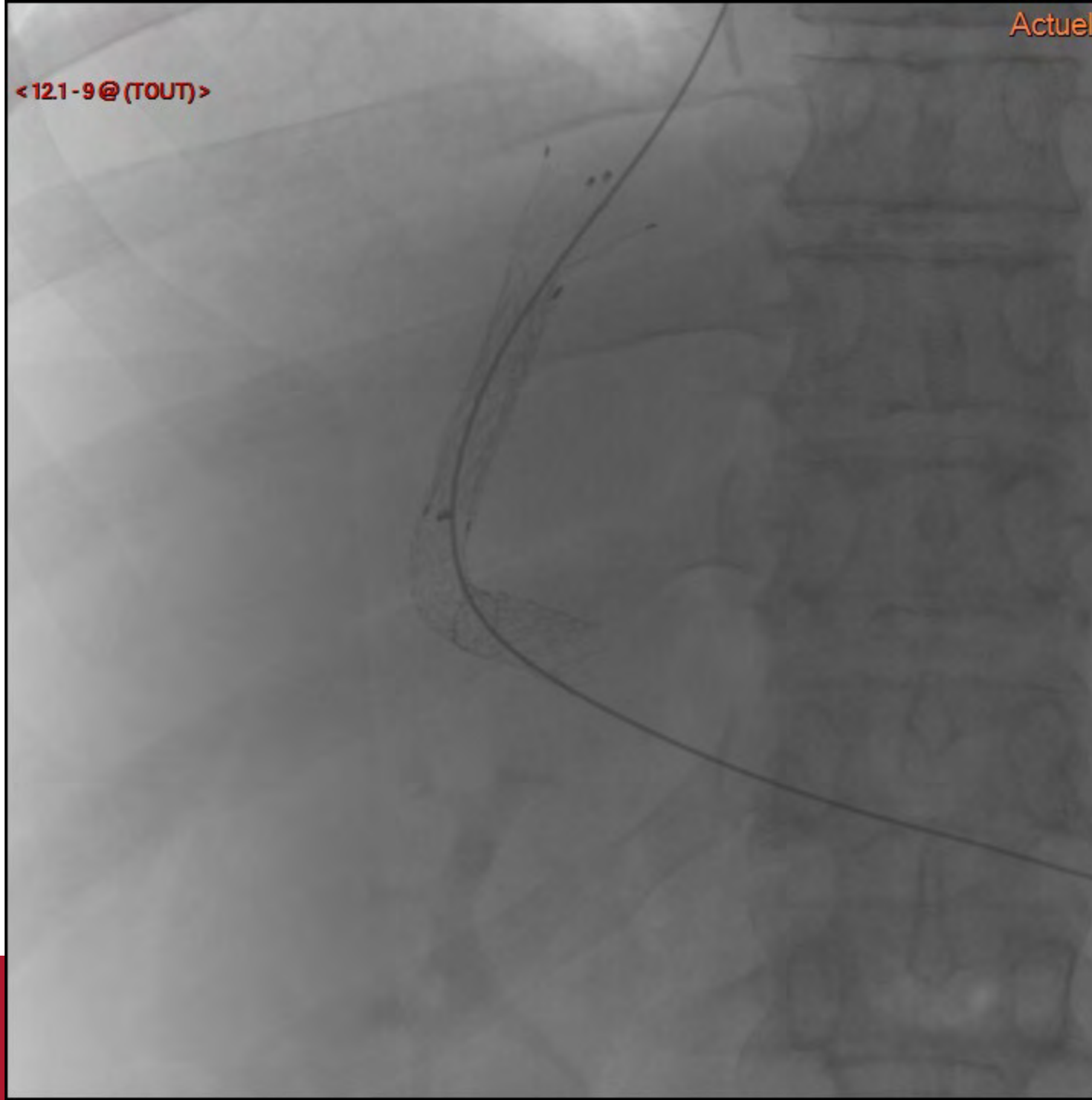
<121-7@ (TOUT)>



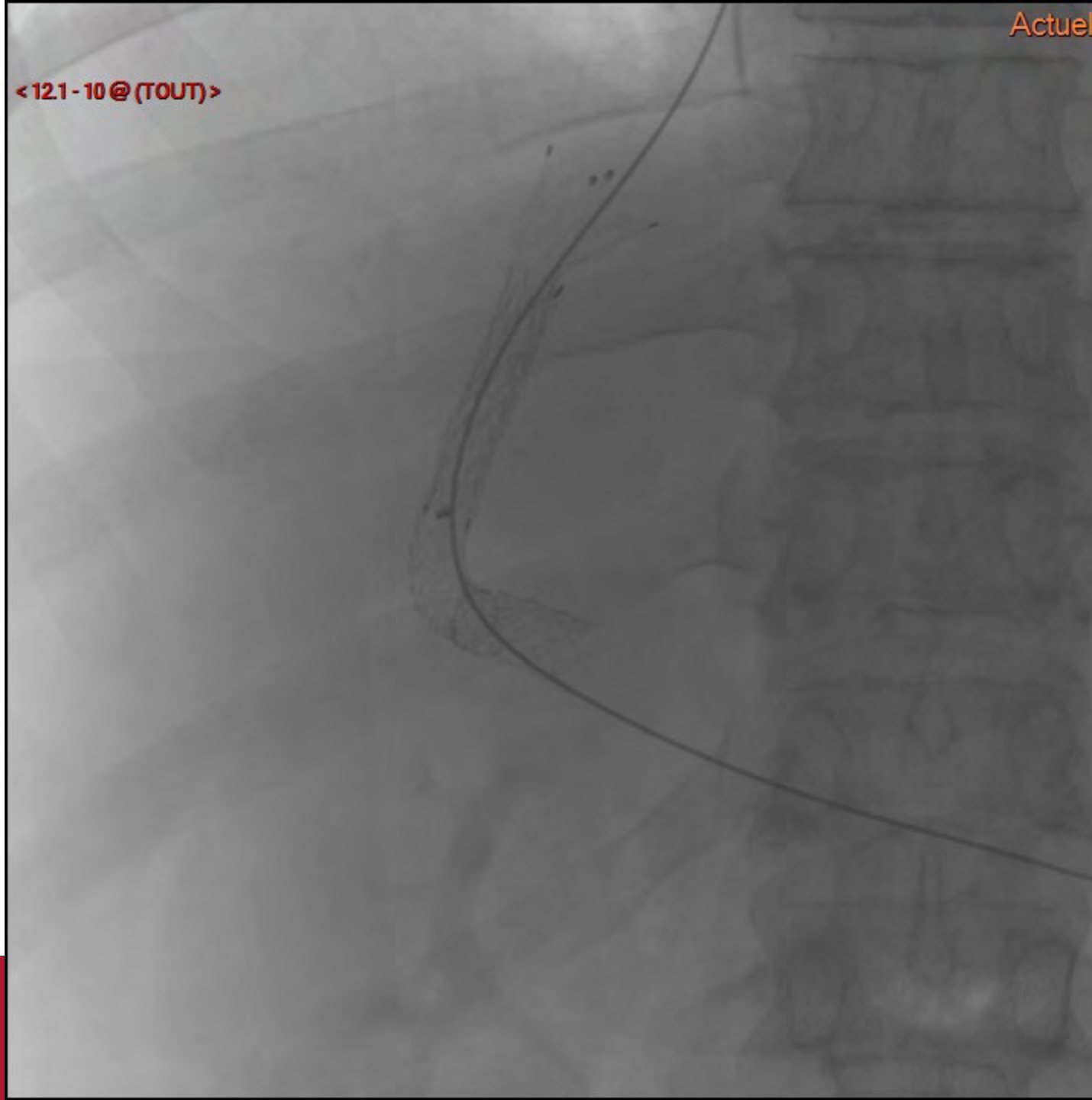
<121-8@ (TOUT)>



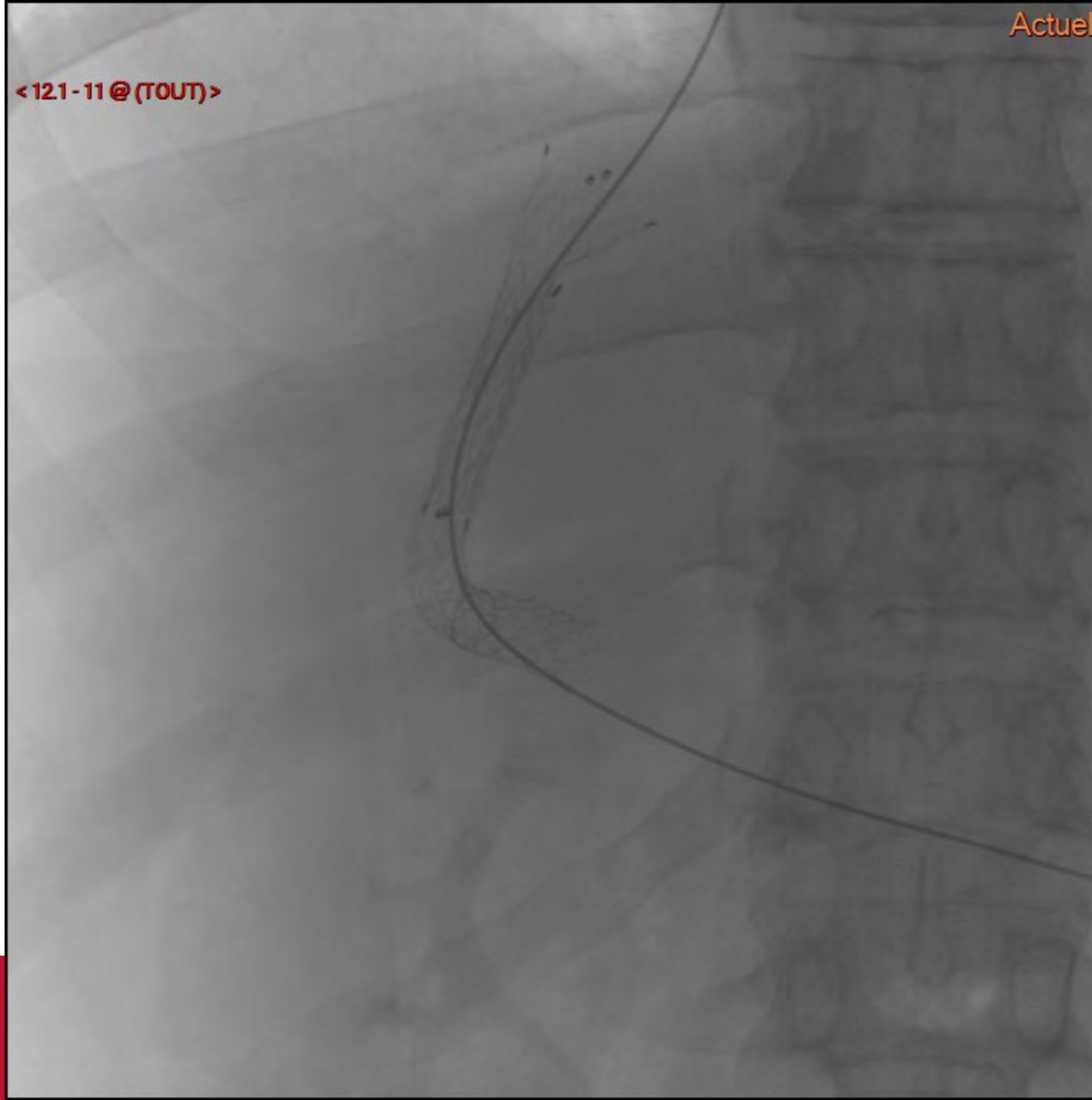
<121-9@ (TOUT)>



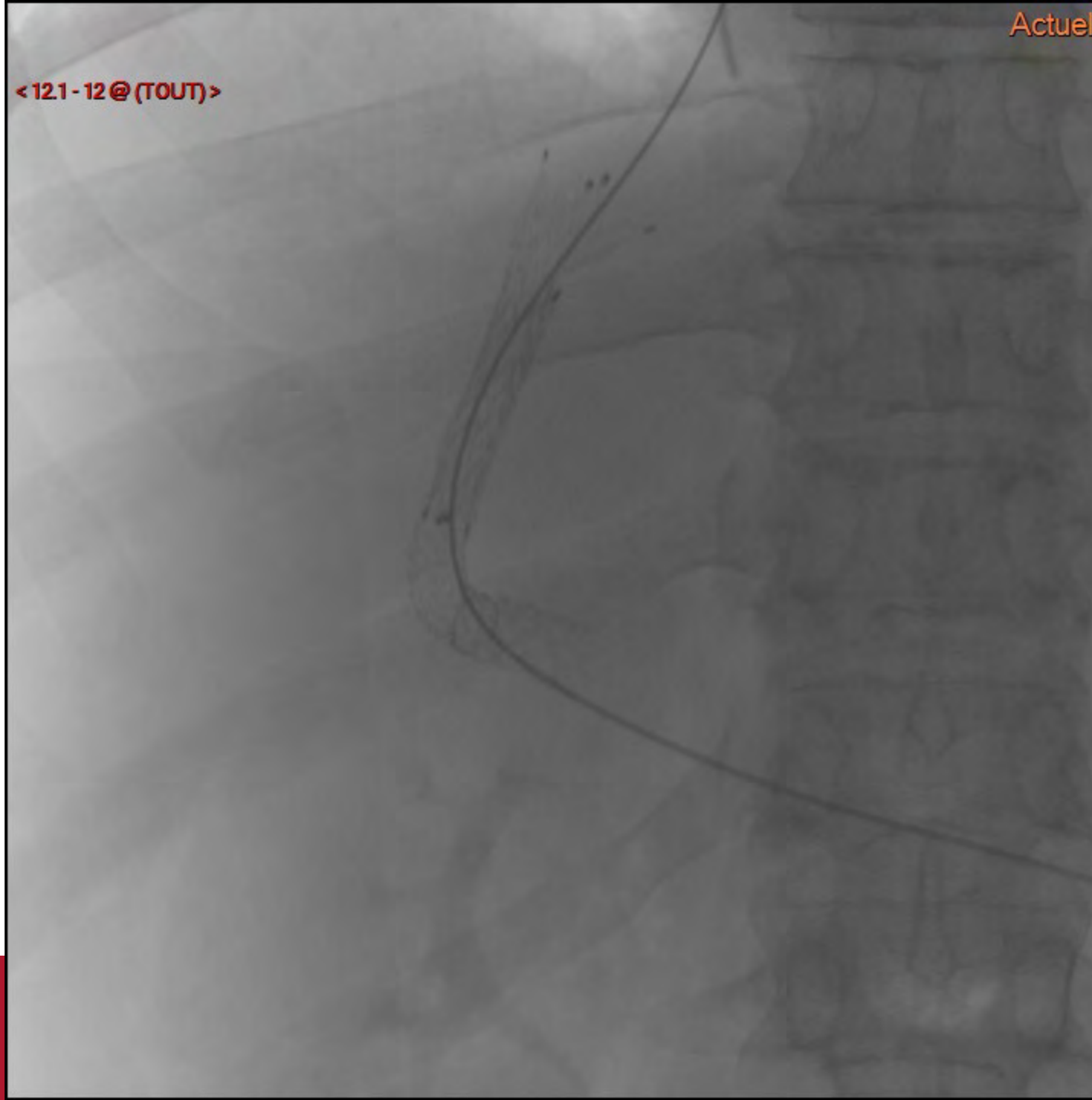
<12.1-10@ (TOUT)>



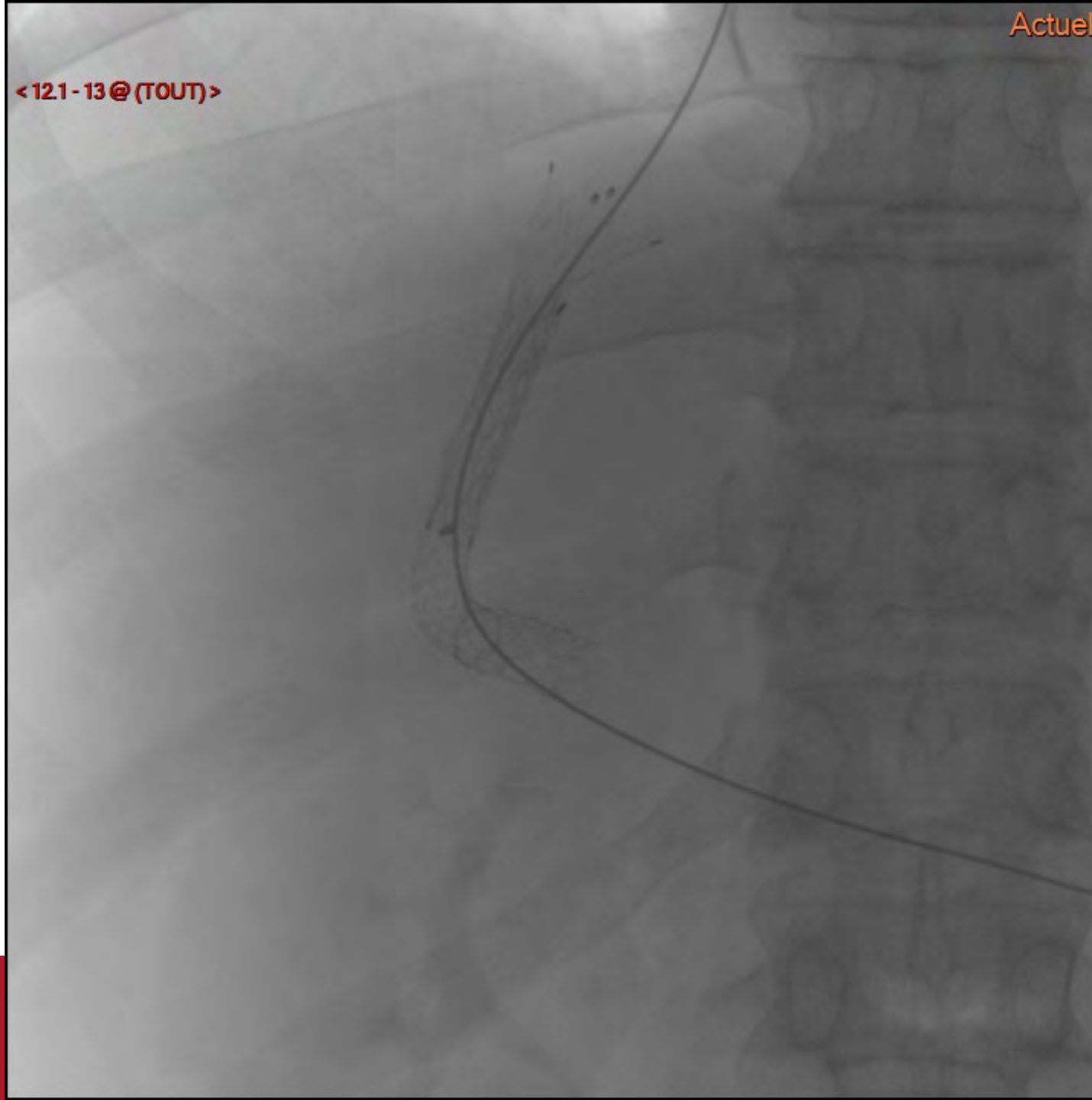
<121-11@TOUT>



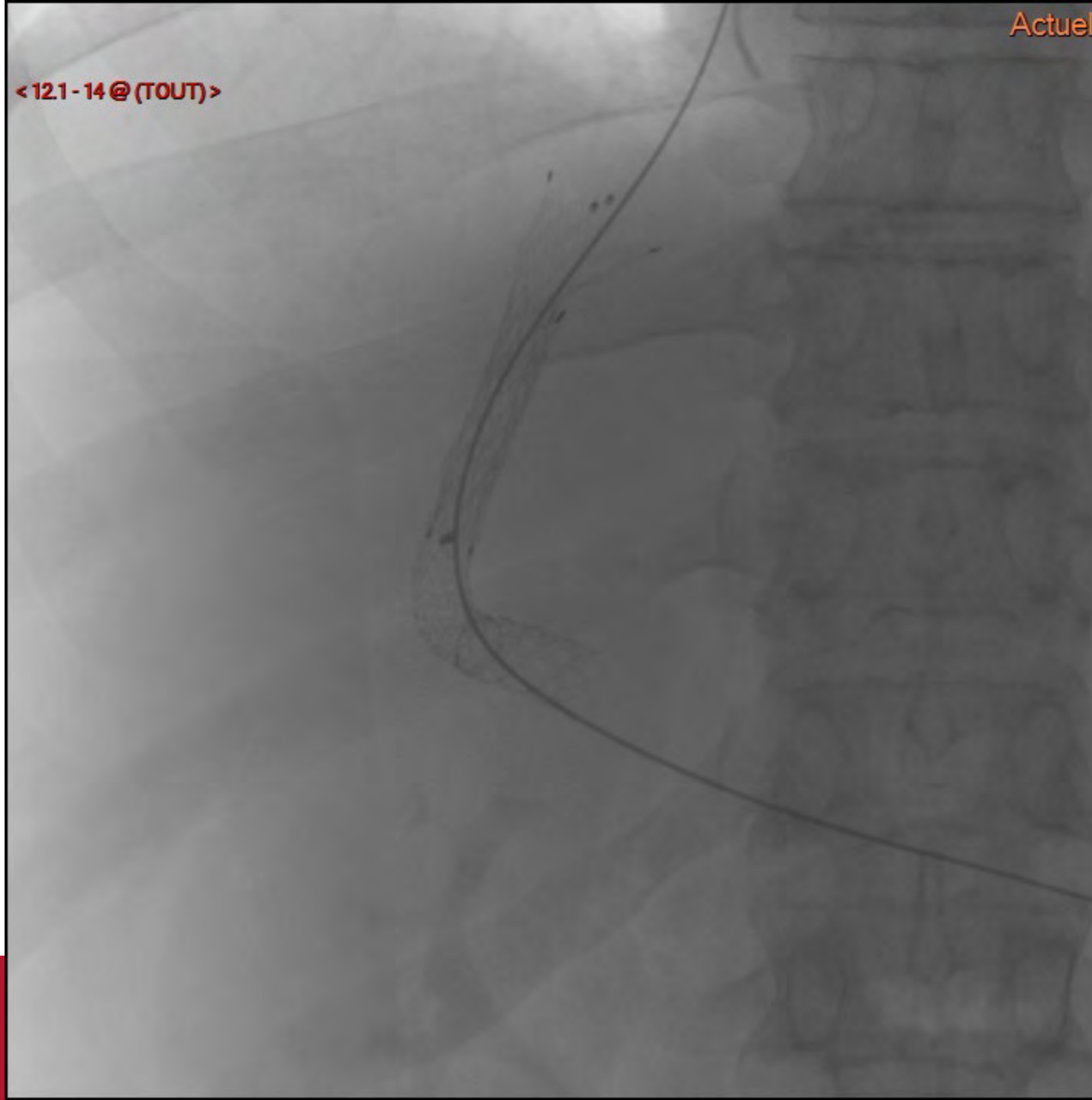
<121-12@ (TOUT)>



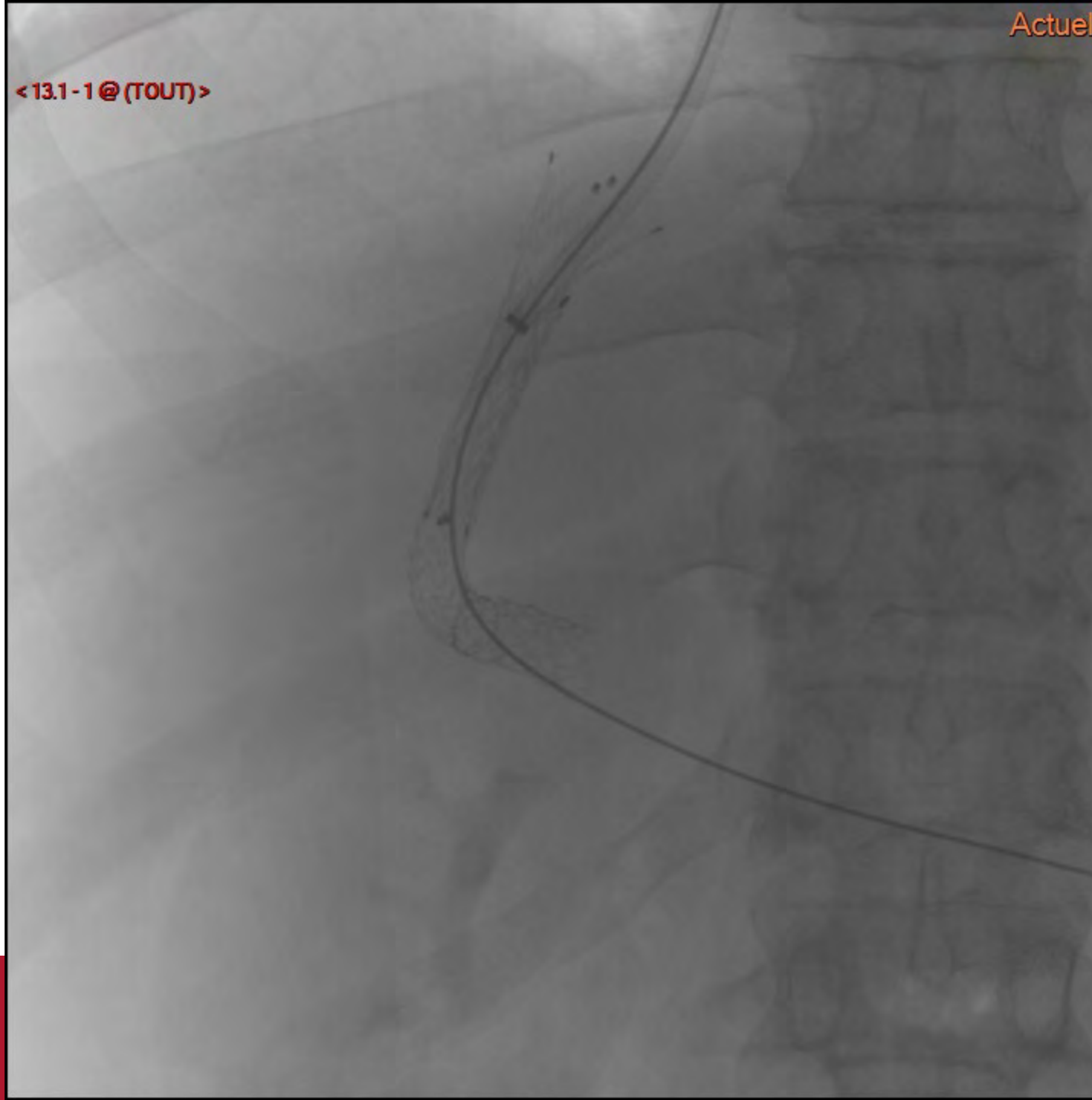
<121-13@ (TOUT)>



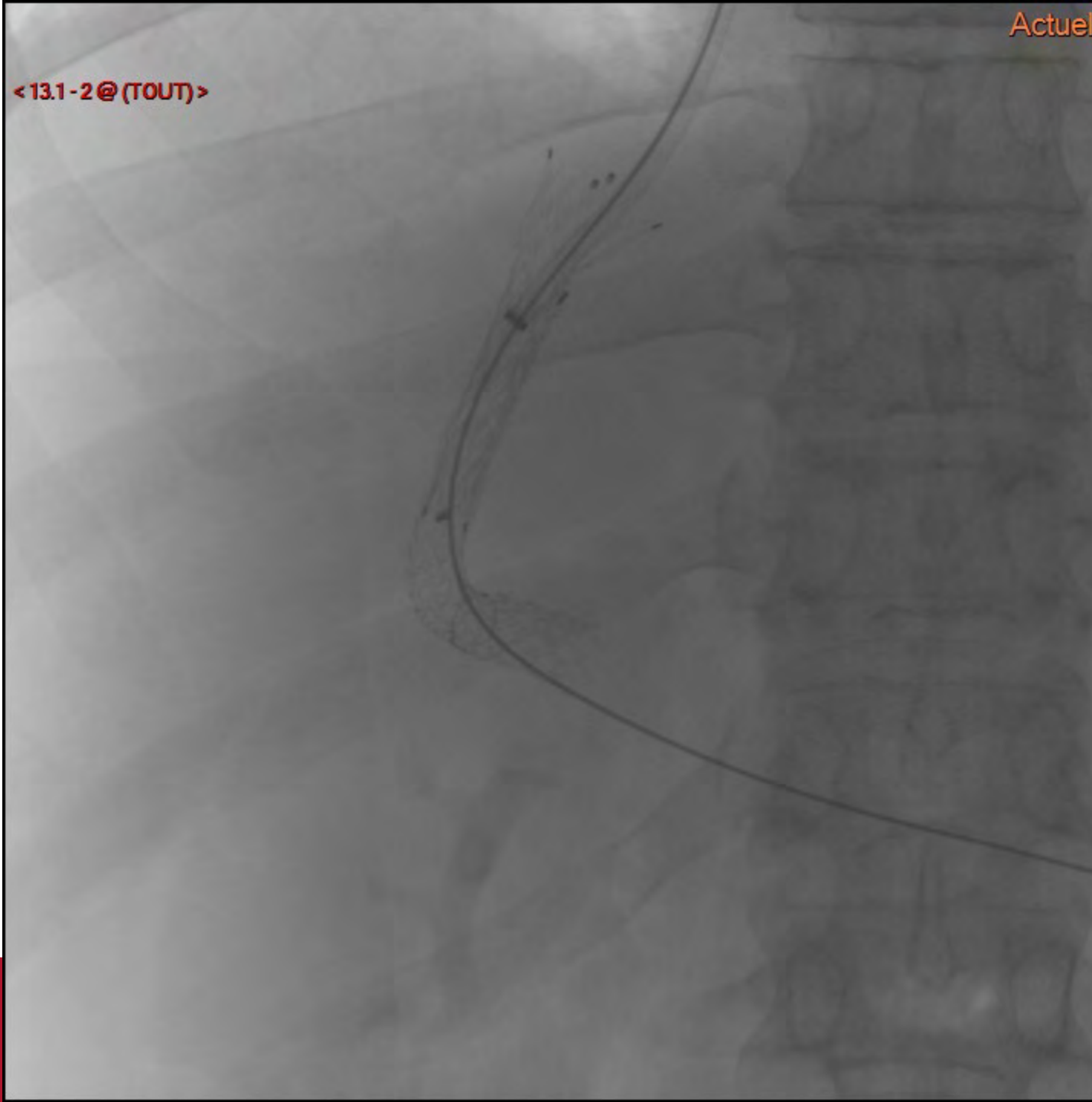
<121-14@ (TOUT)>



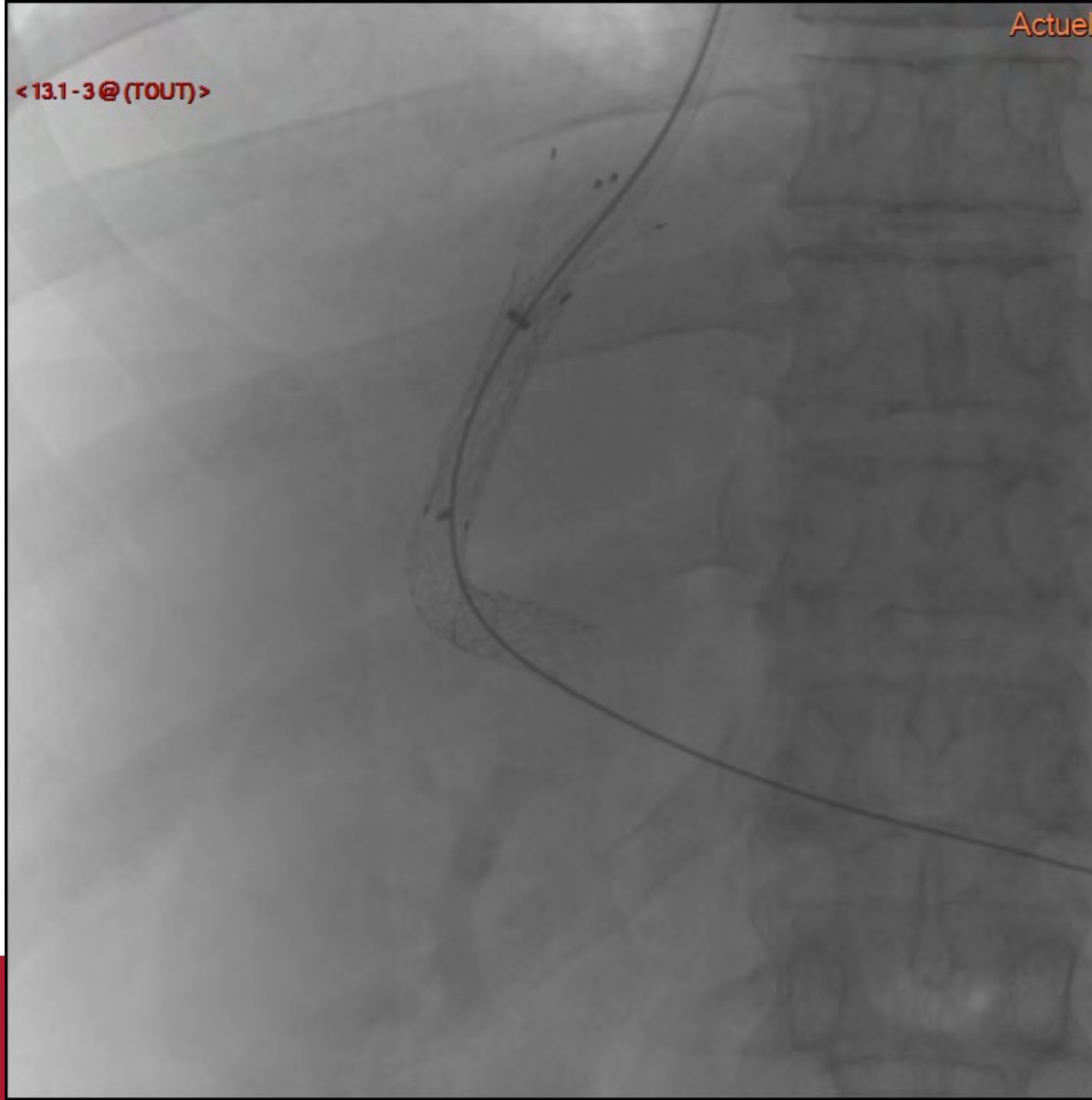
<13.1-1@TOUT>



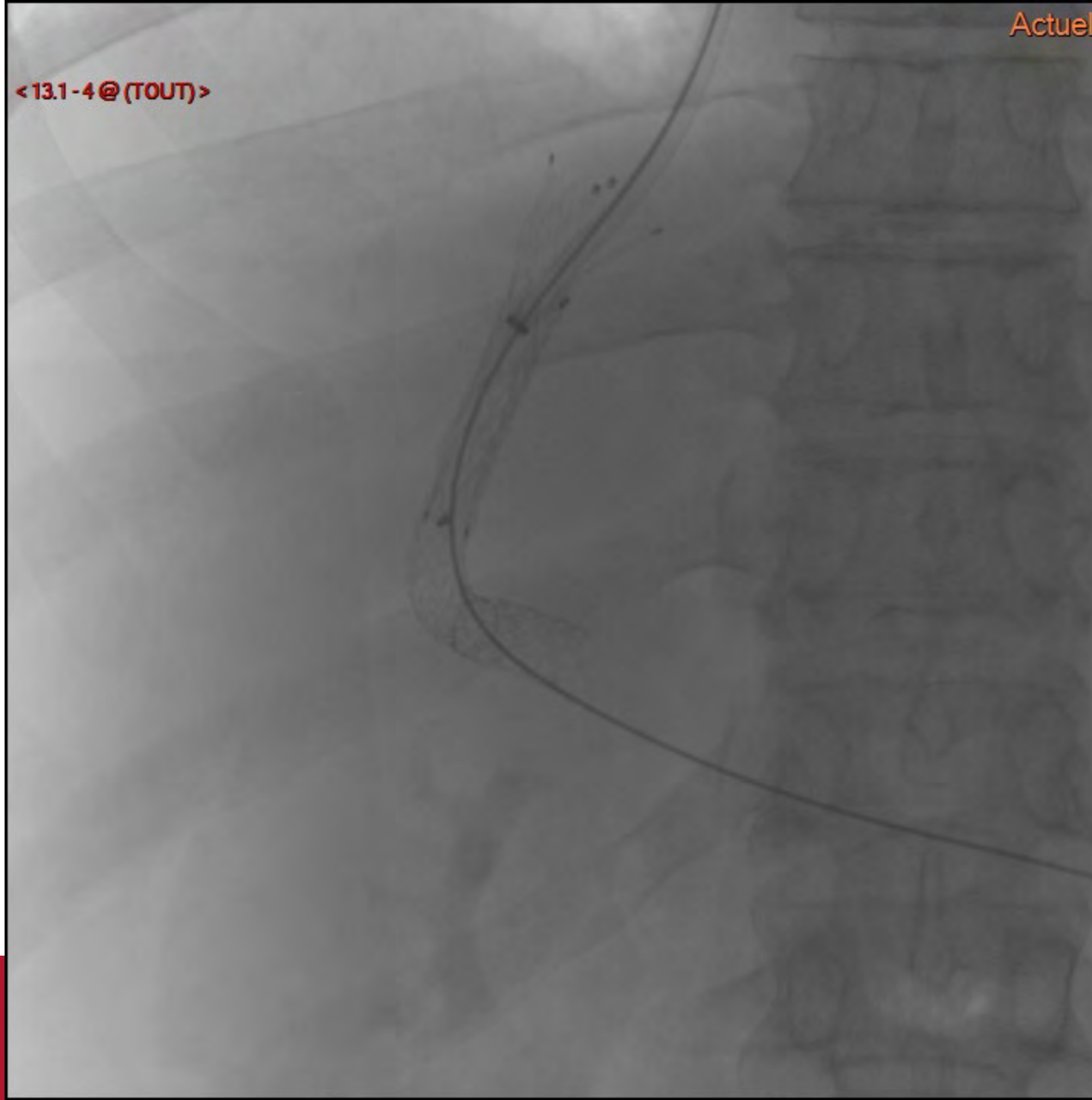
<13.1-2@(TOUT)>



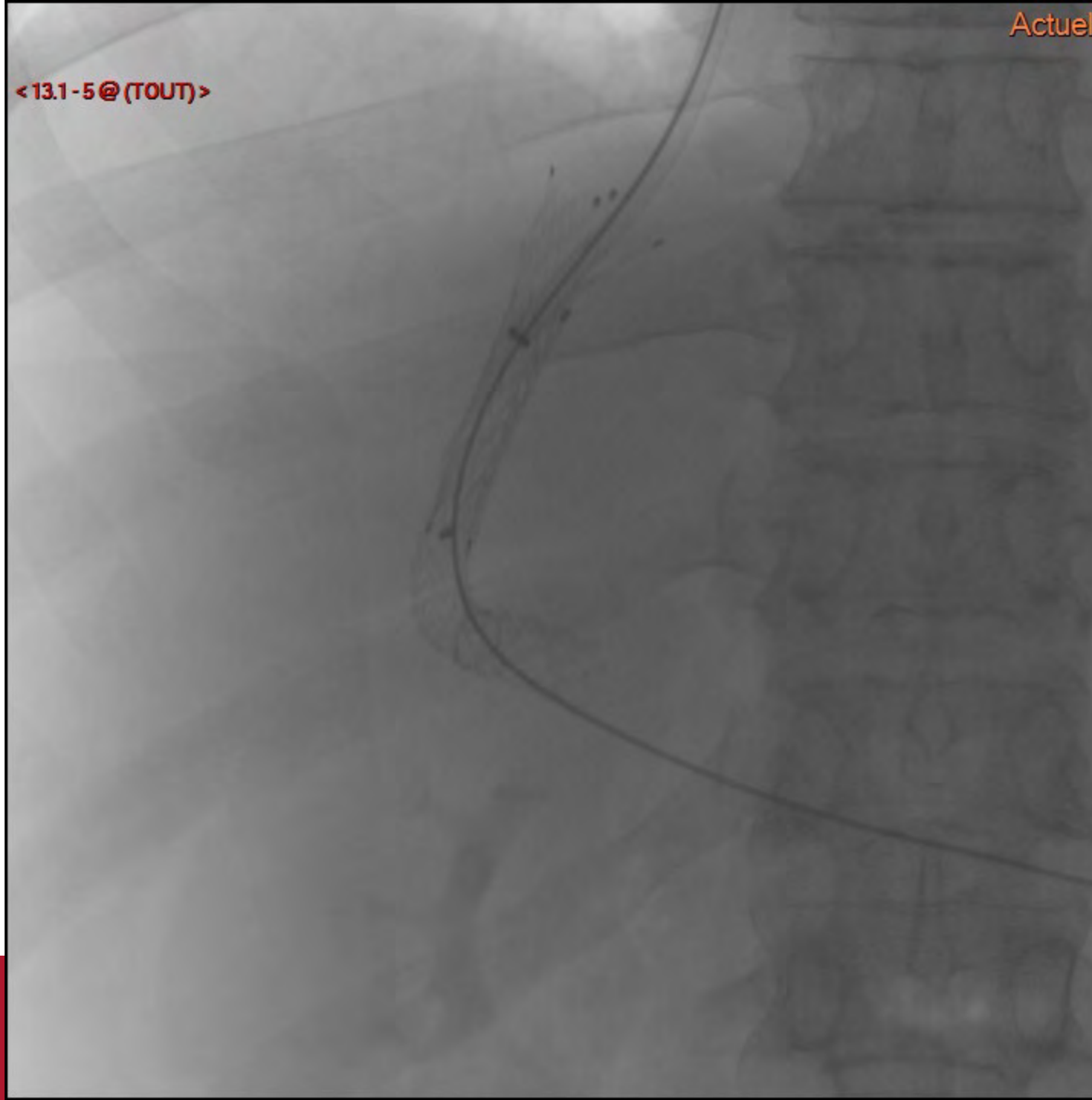
<13.1-3@ (TOUT)>



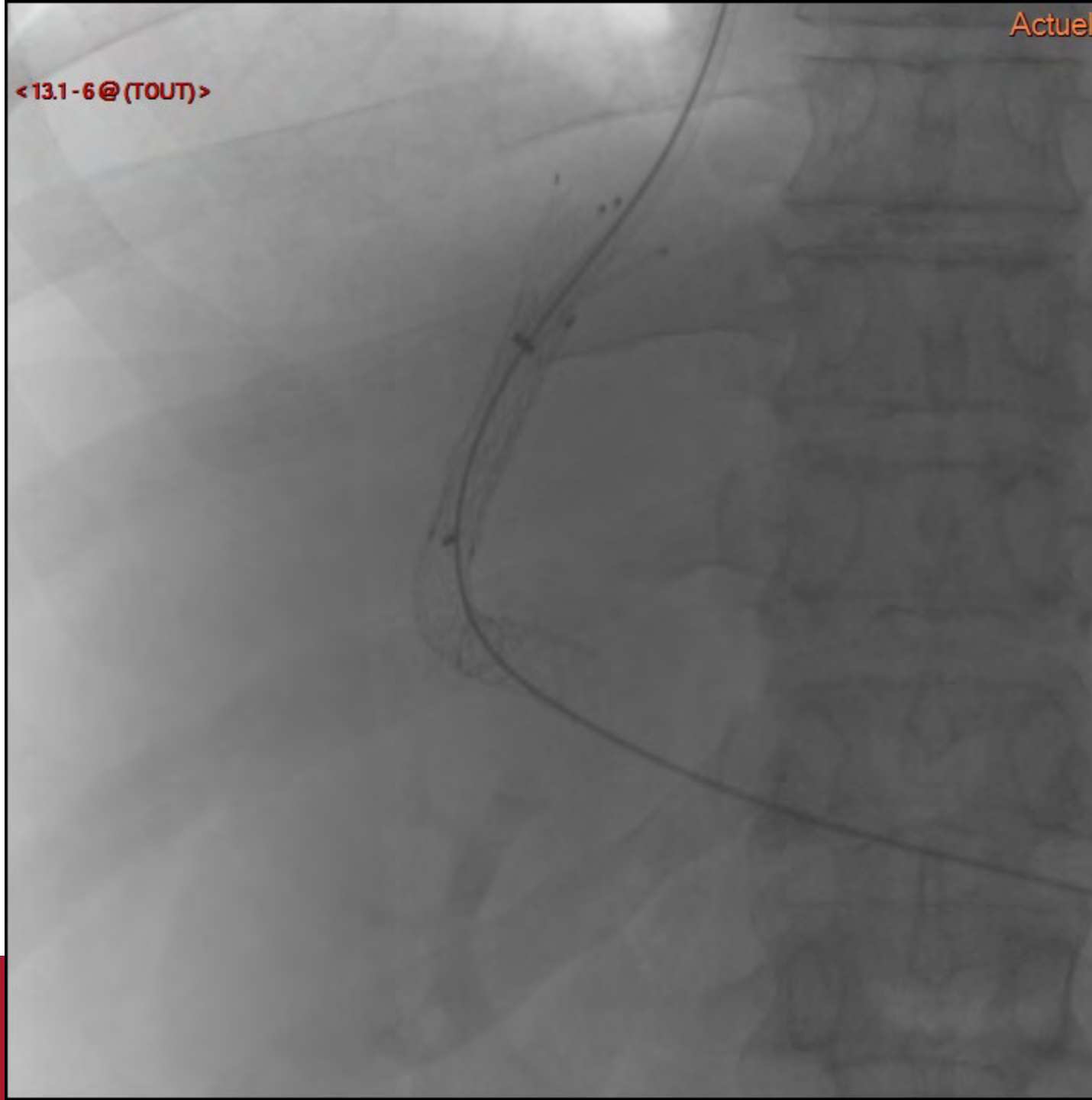
<13.1-4@ (TOUT)>



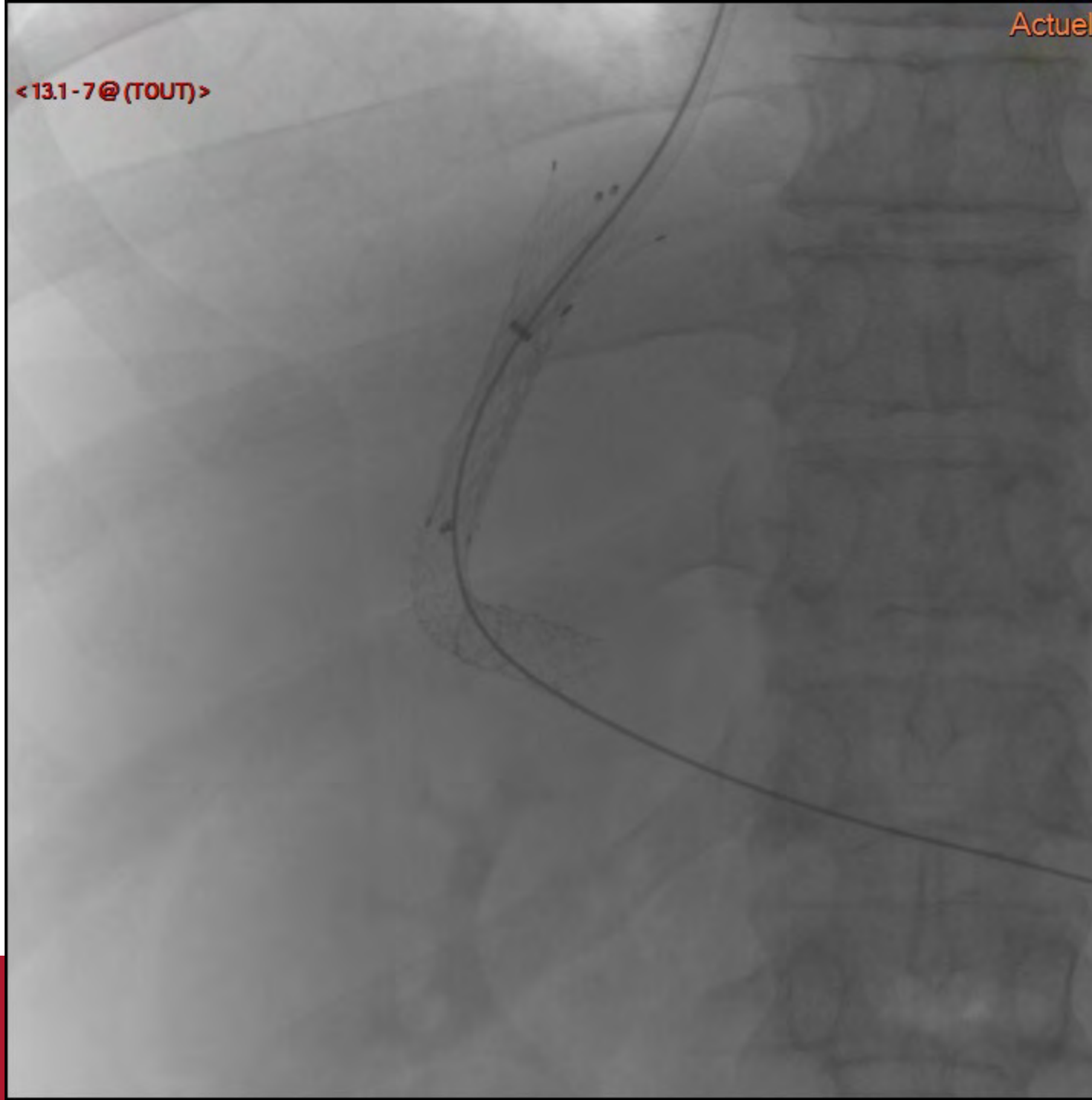
<13.1-5@ (TOUT)>



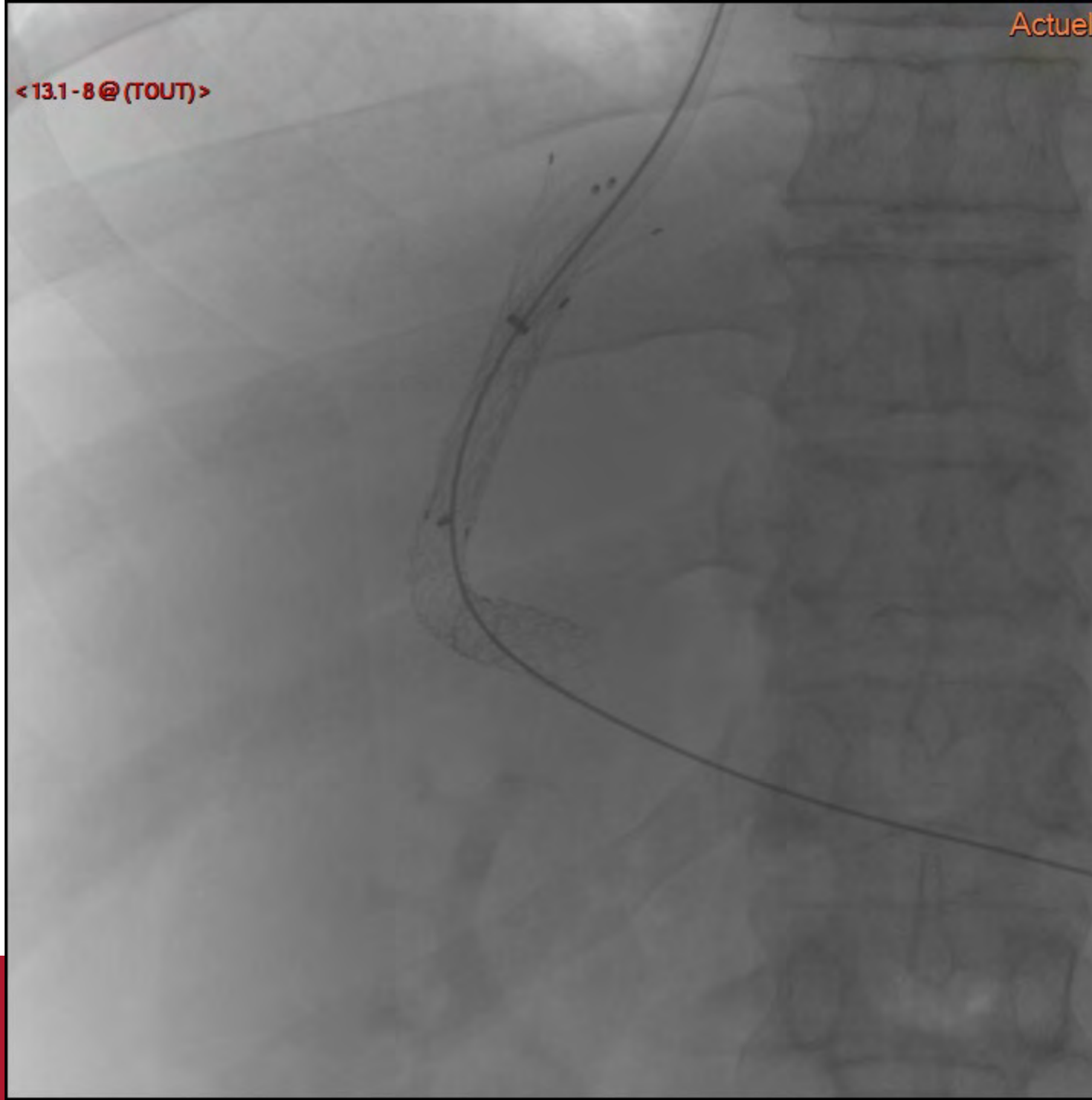
<13.1-6@ (TOUT)>



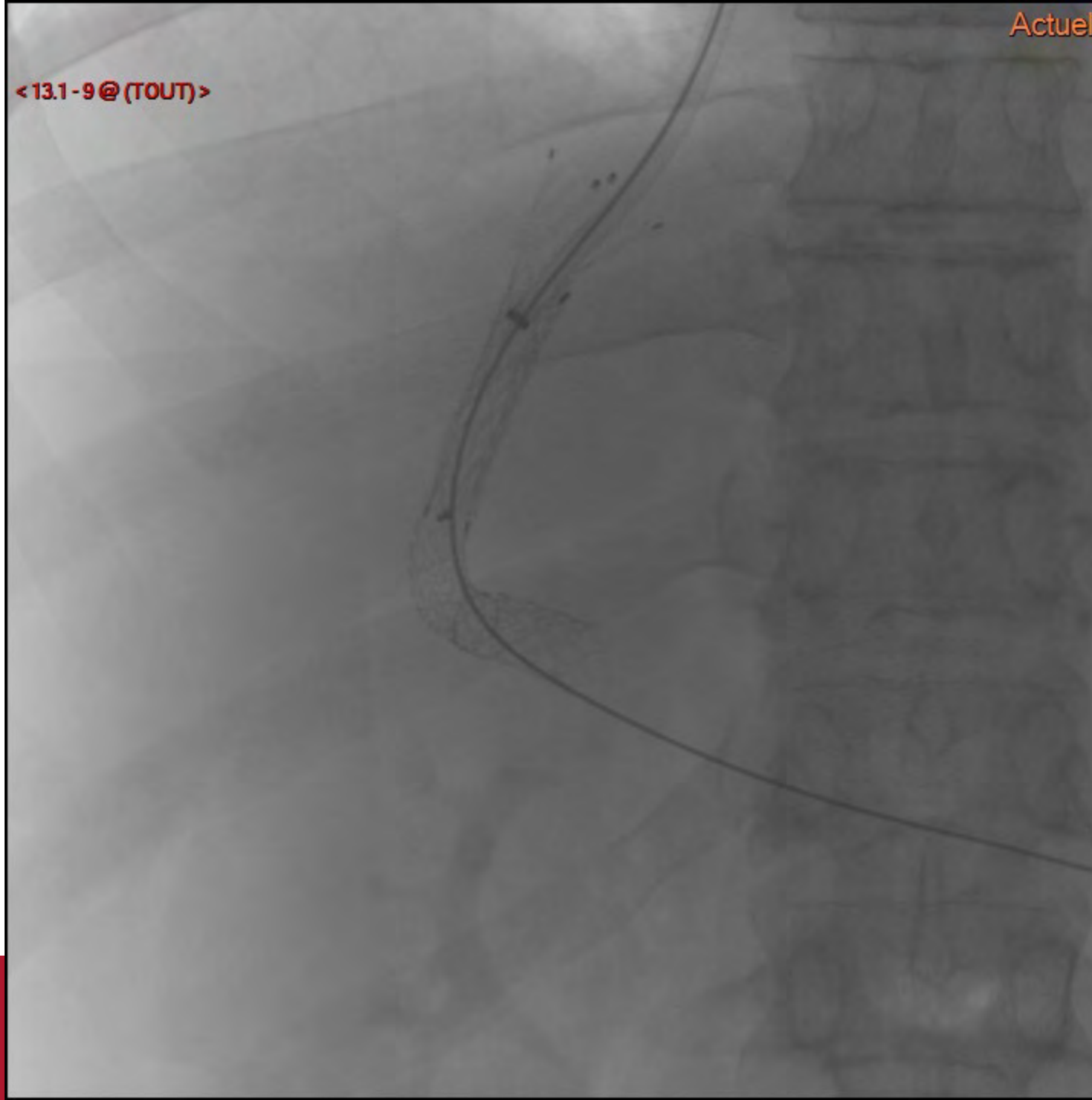
<13.1-7@ (TOUT)>



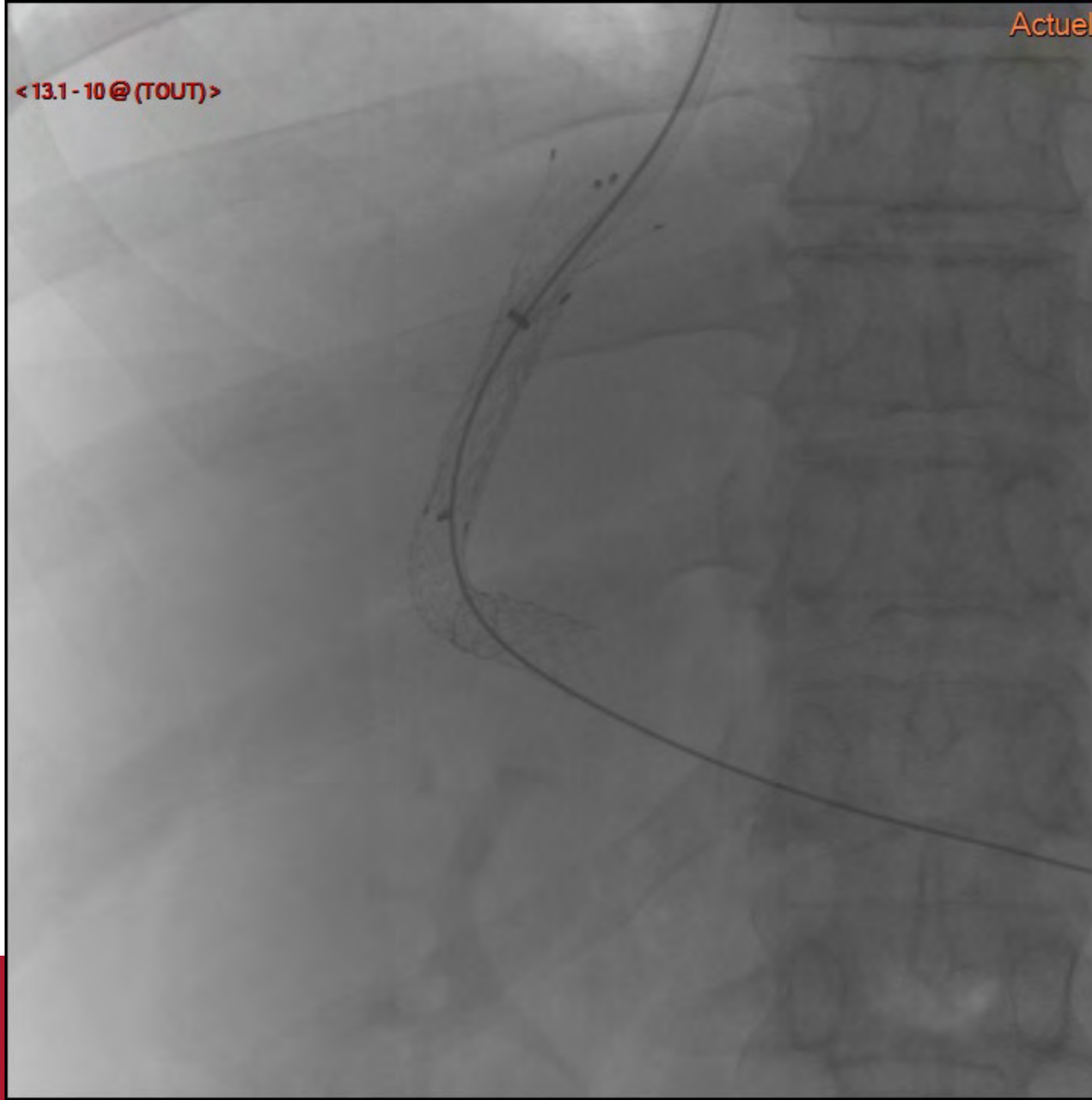
<13.1-8@TOU>



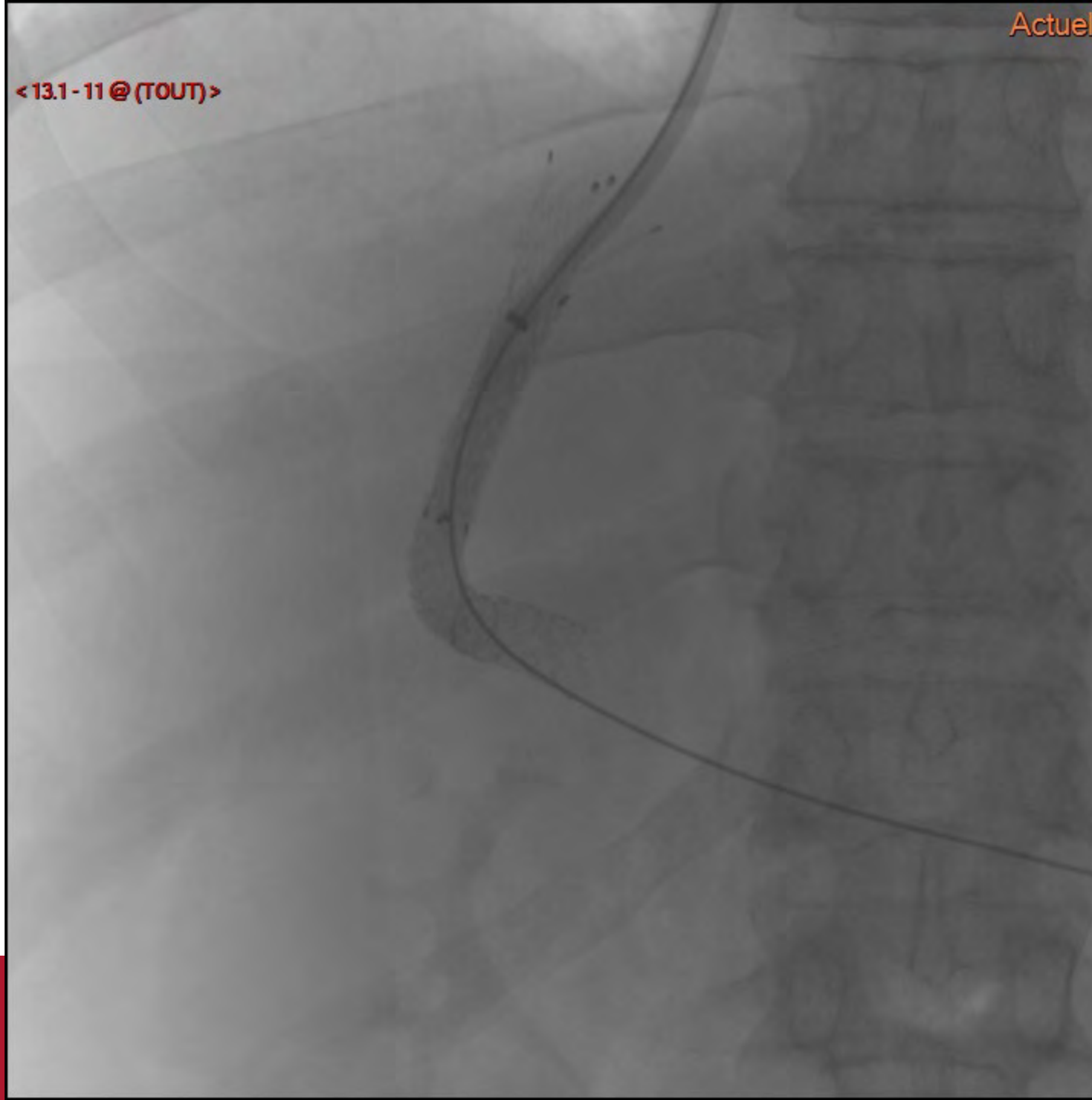
<13.1-9@TOUT>



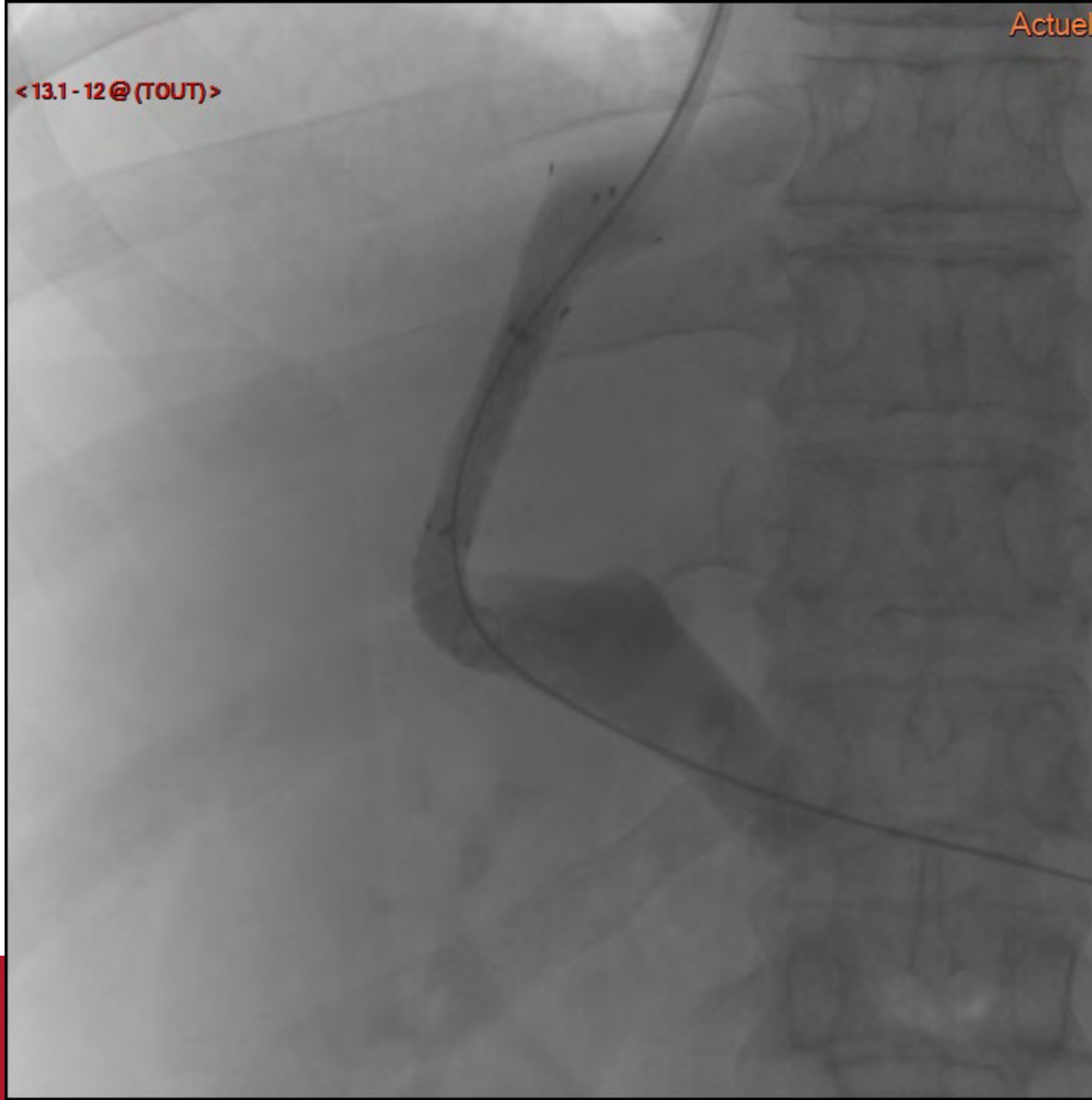
<13.1 - 10@ (TOUT)>



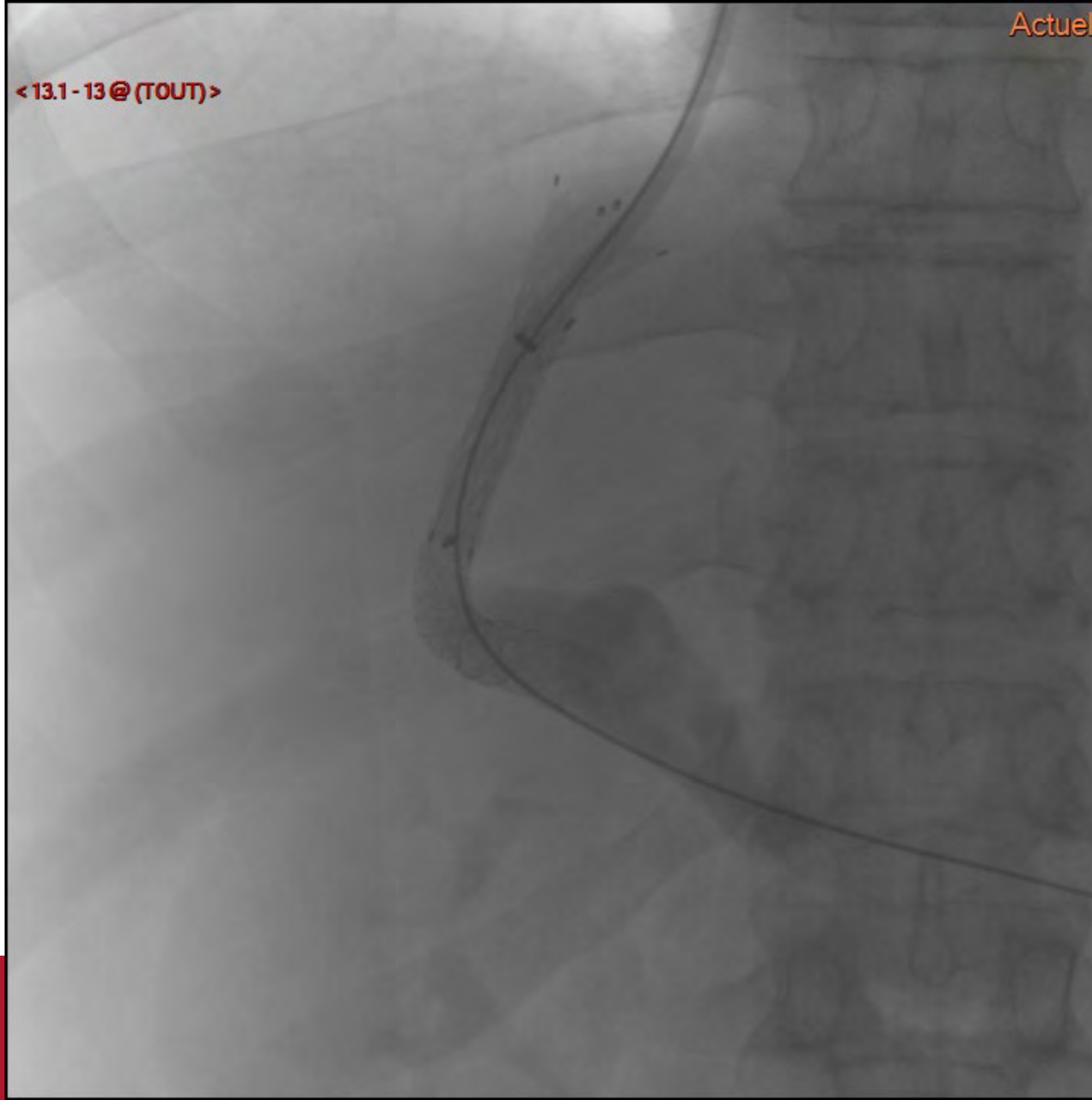
<13.1-11@ (TOUT)>



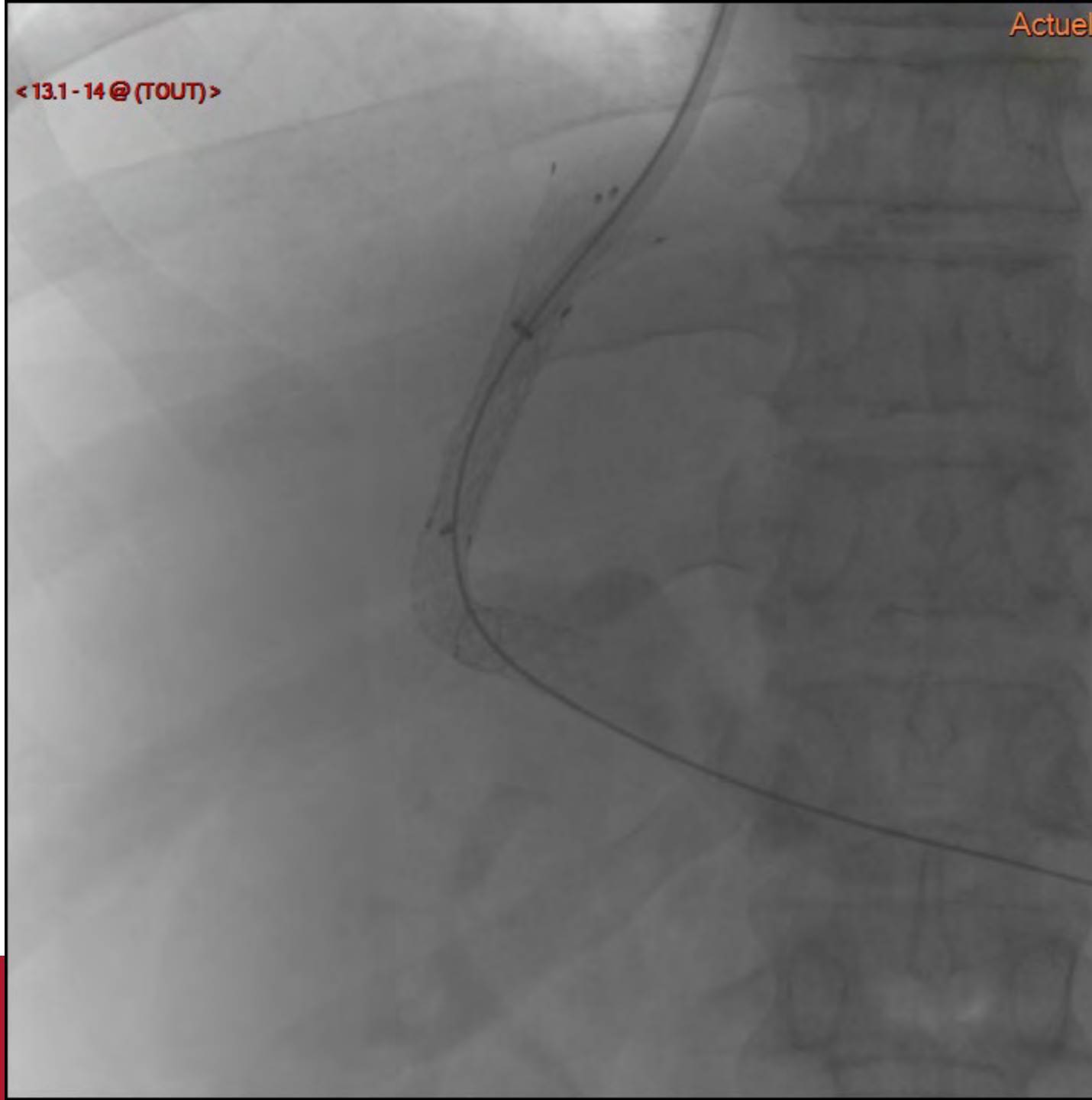
<13.1-12@ (TOUT)>



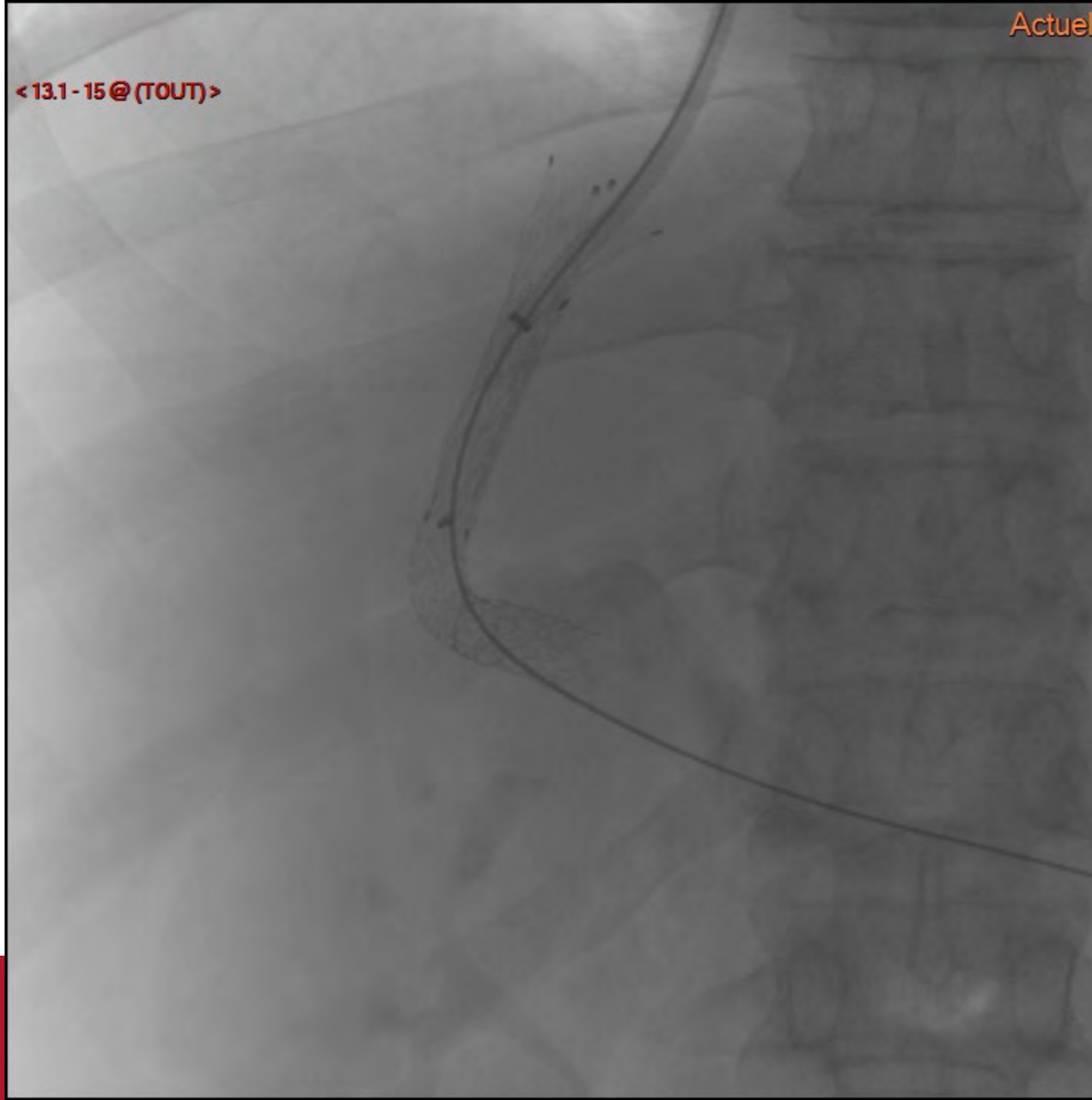
<13.1-13@ (TOUT)>



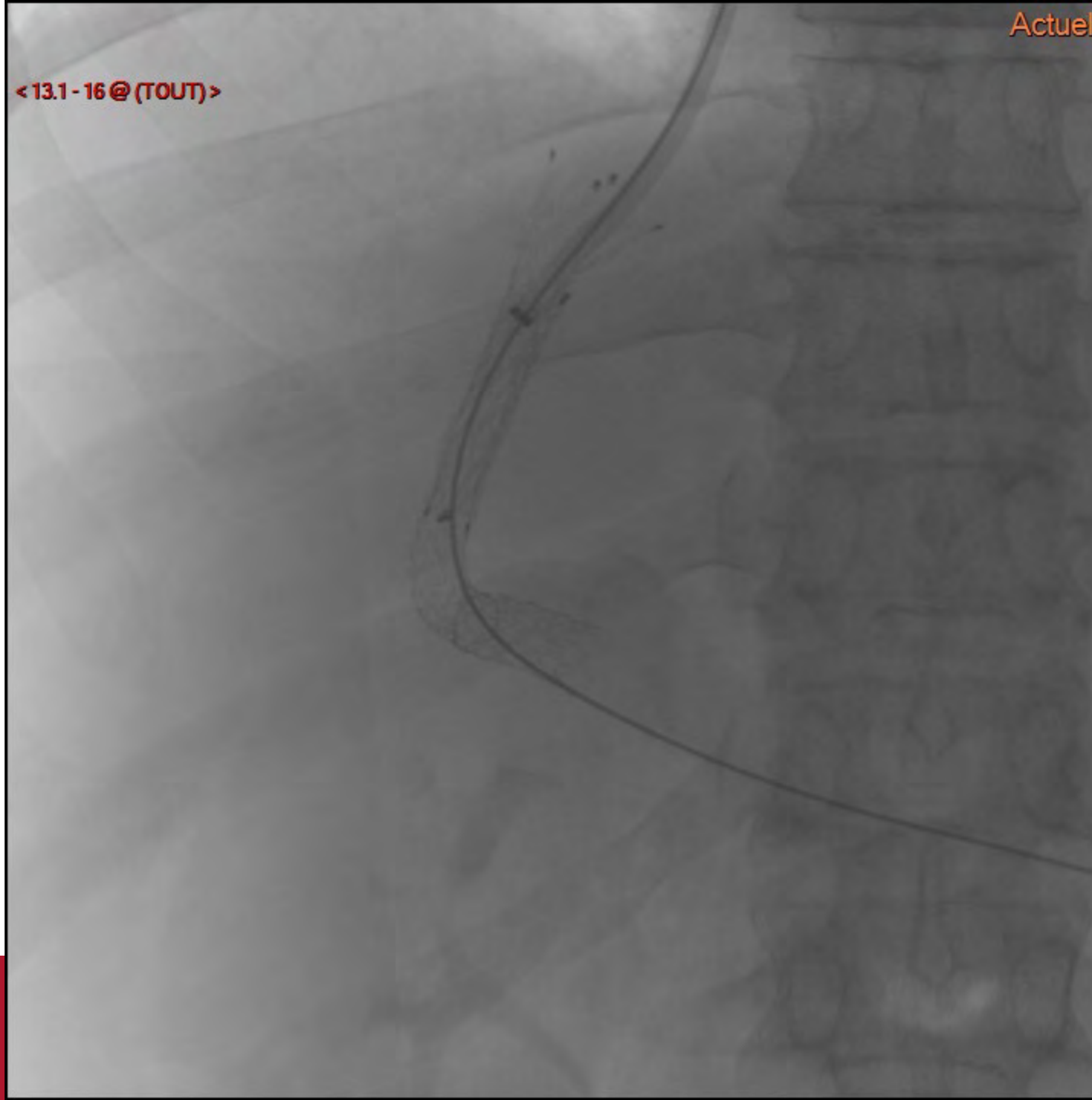
<13.1-14@ (TOUT)>



<13.1 - 15@ (TOUT)>



<13.1-16@ (TOUT)>



<13.1-17@TOUT>

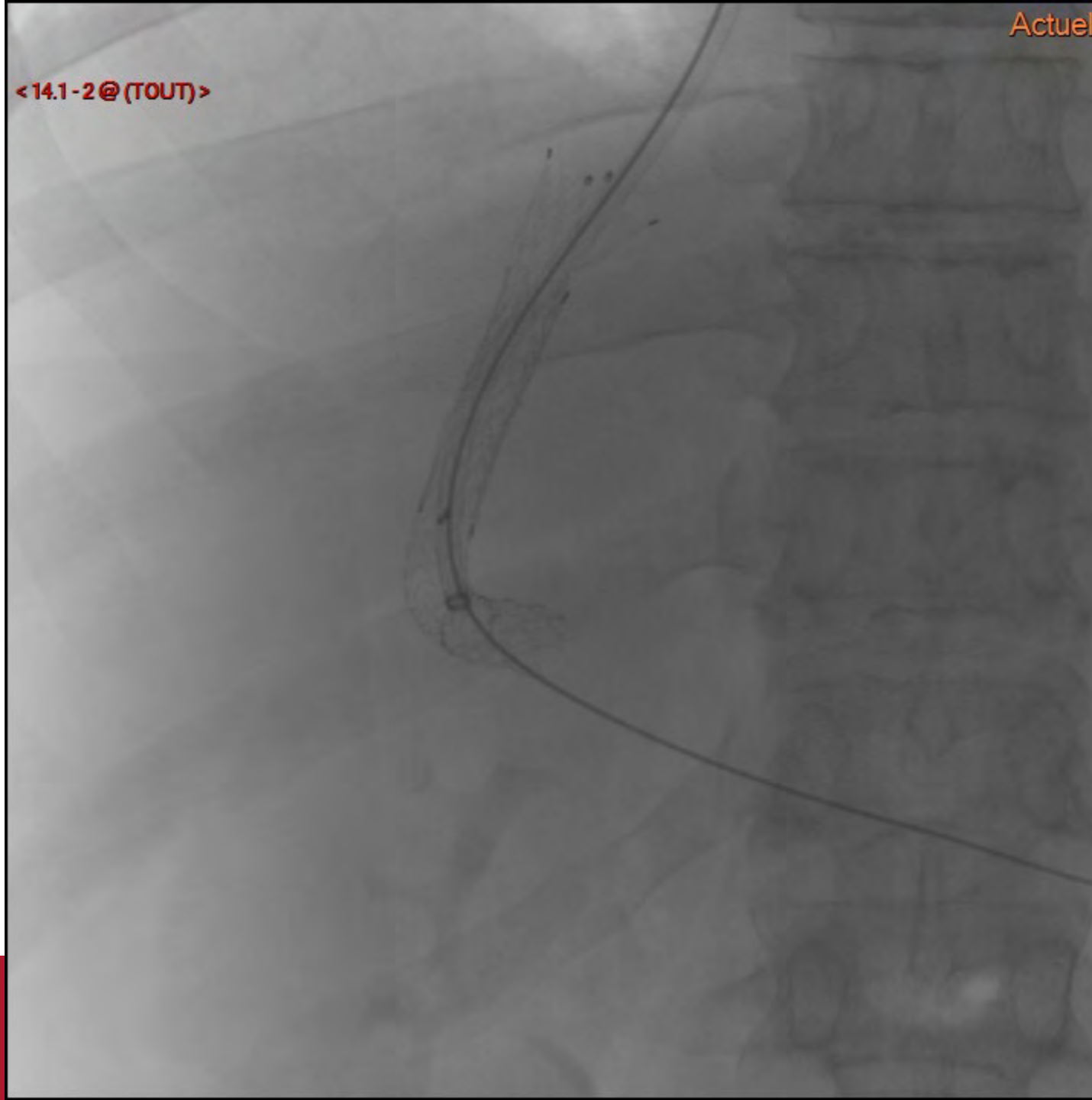
Appel du l'hépatologue
de garde

Gradient de pression porto-cave > 12 mmHg

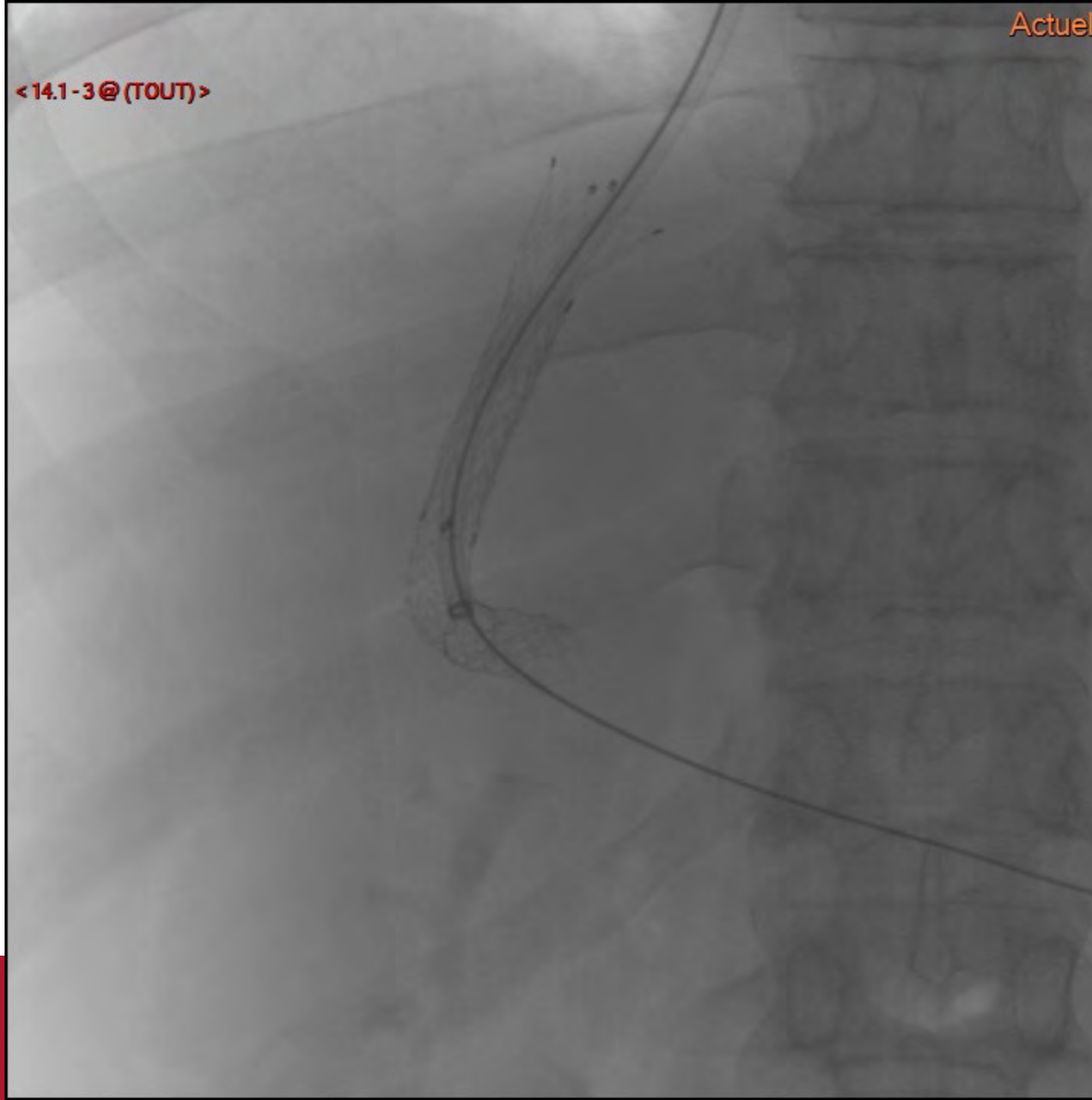
<14.1-1@ (TOUT)>

Recalibration: 10 mm

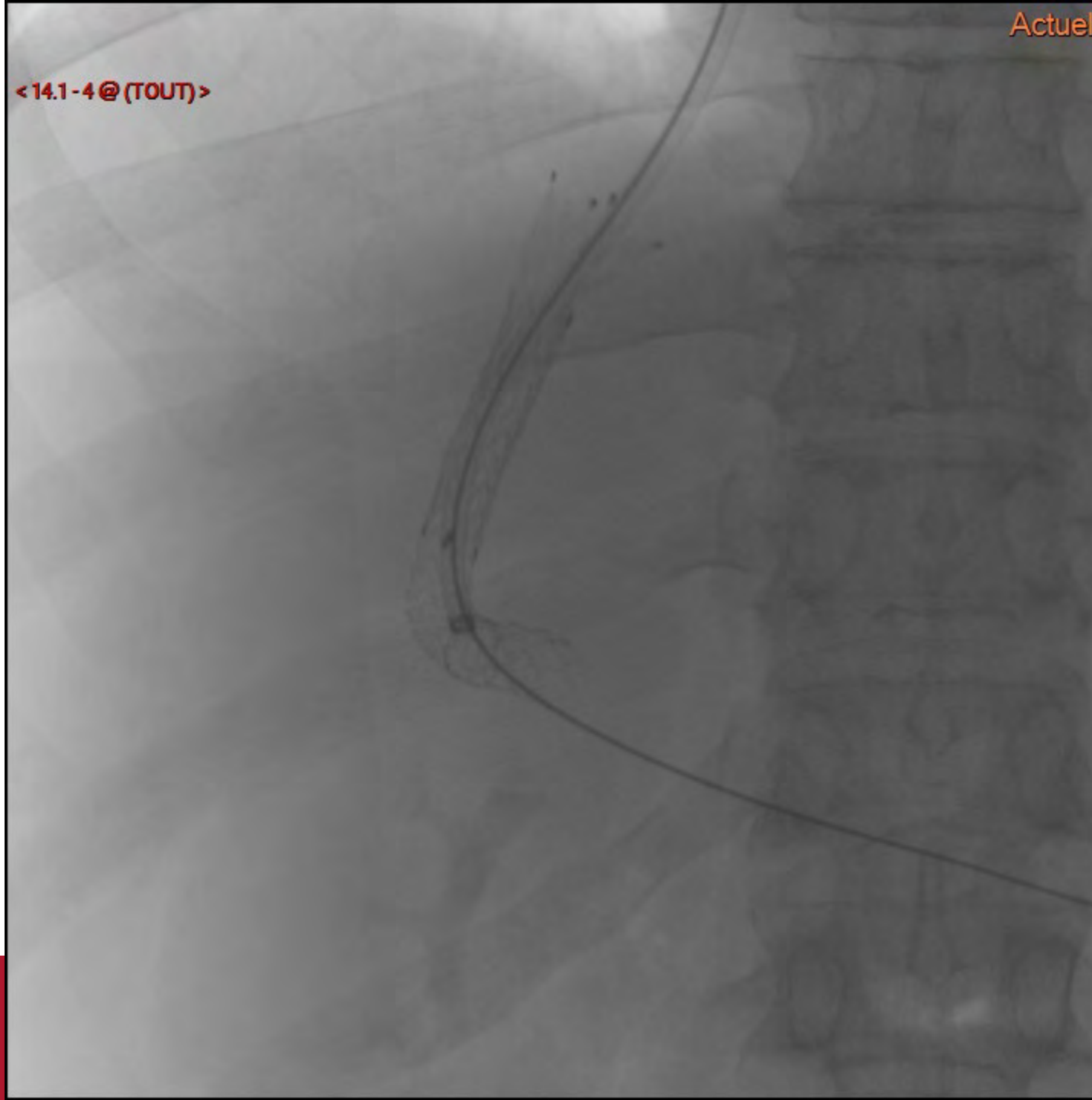
<14.1-2@(TOUT)>



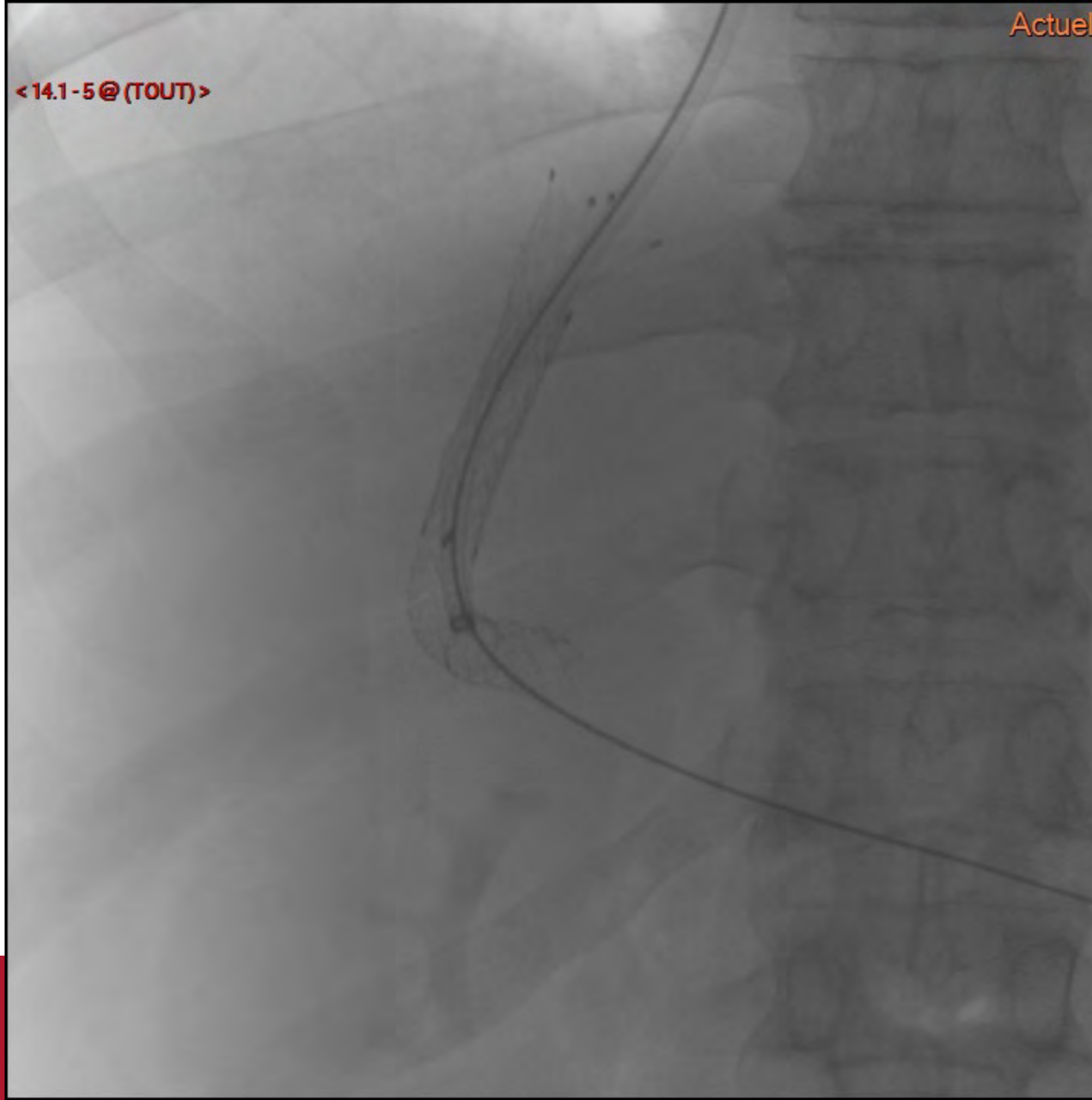
<14.1-3@(TOUT)>



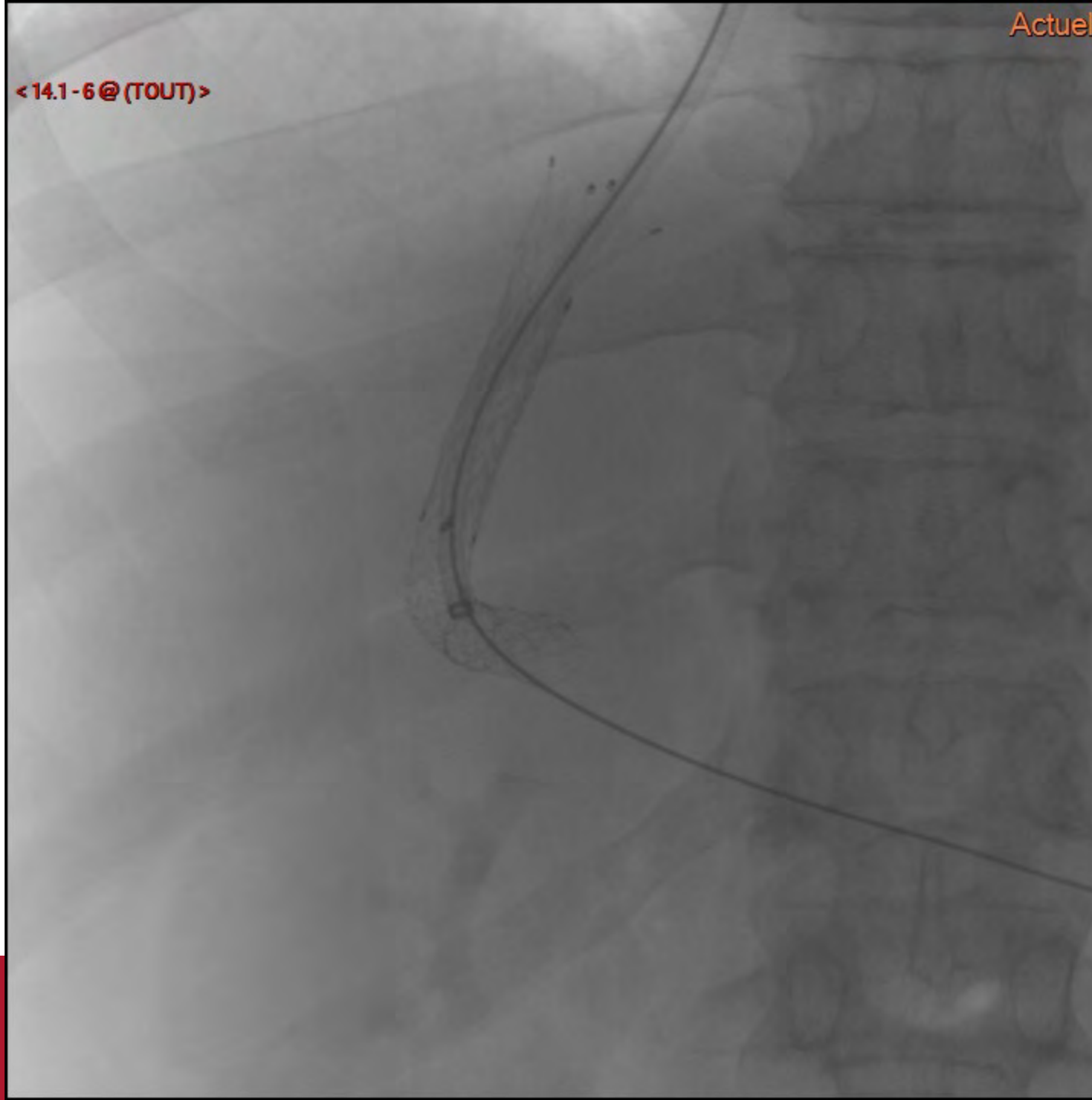
<14.1-4@ (TOUT)>



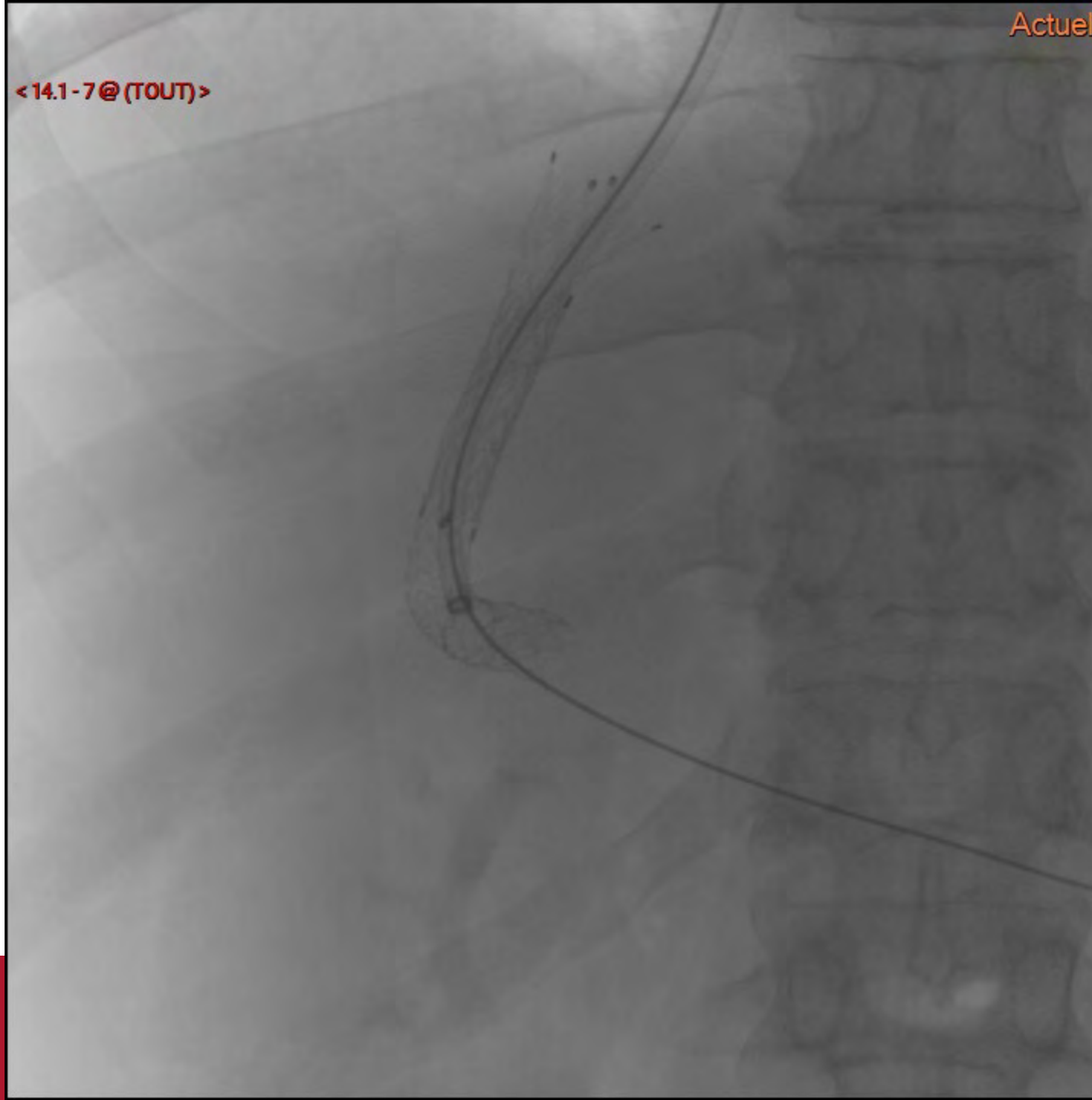
<14.1-5@(TOUT)>



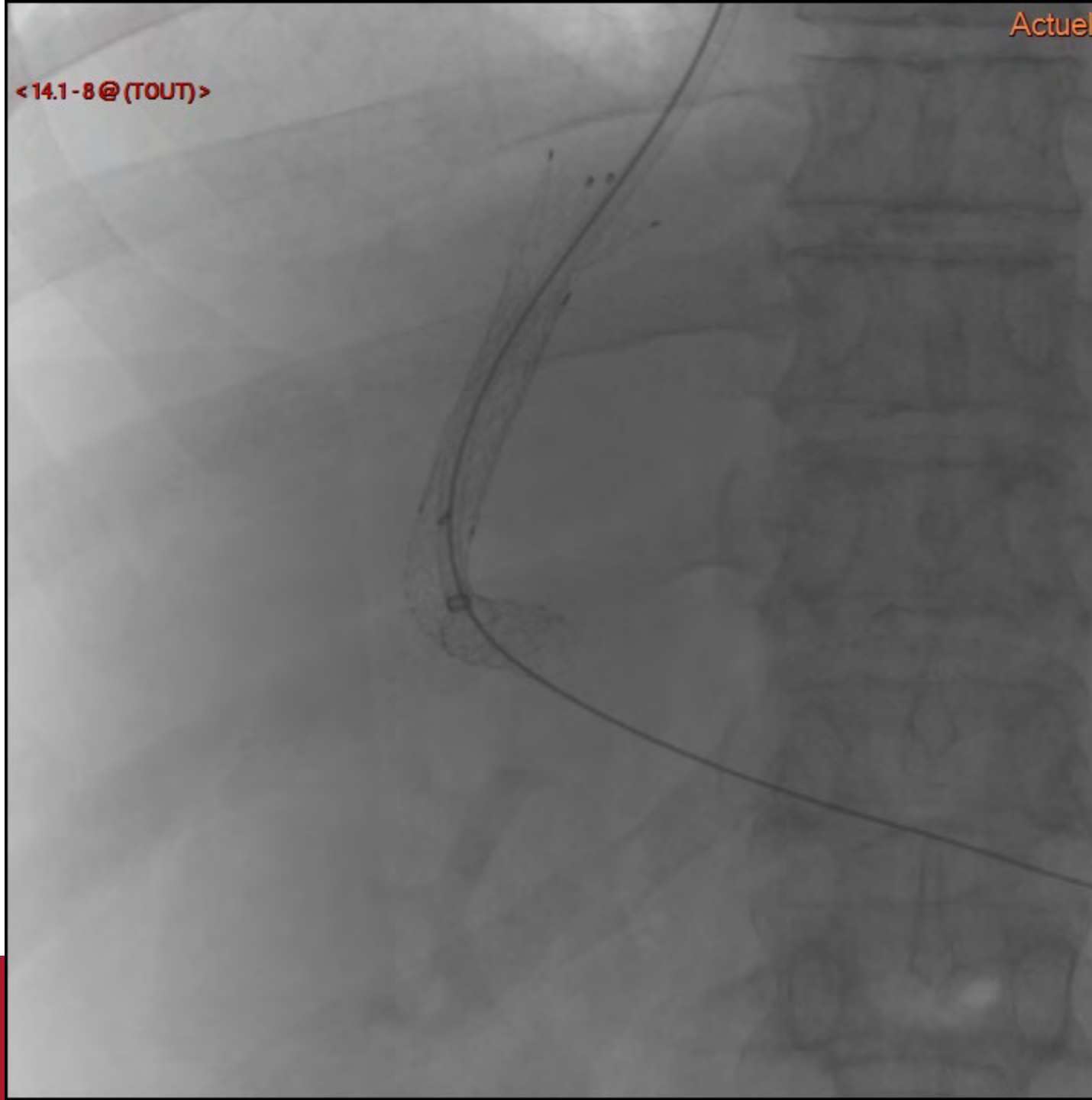
<14.1-6@(TOUT)>



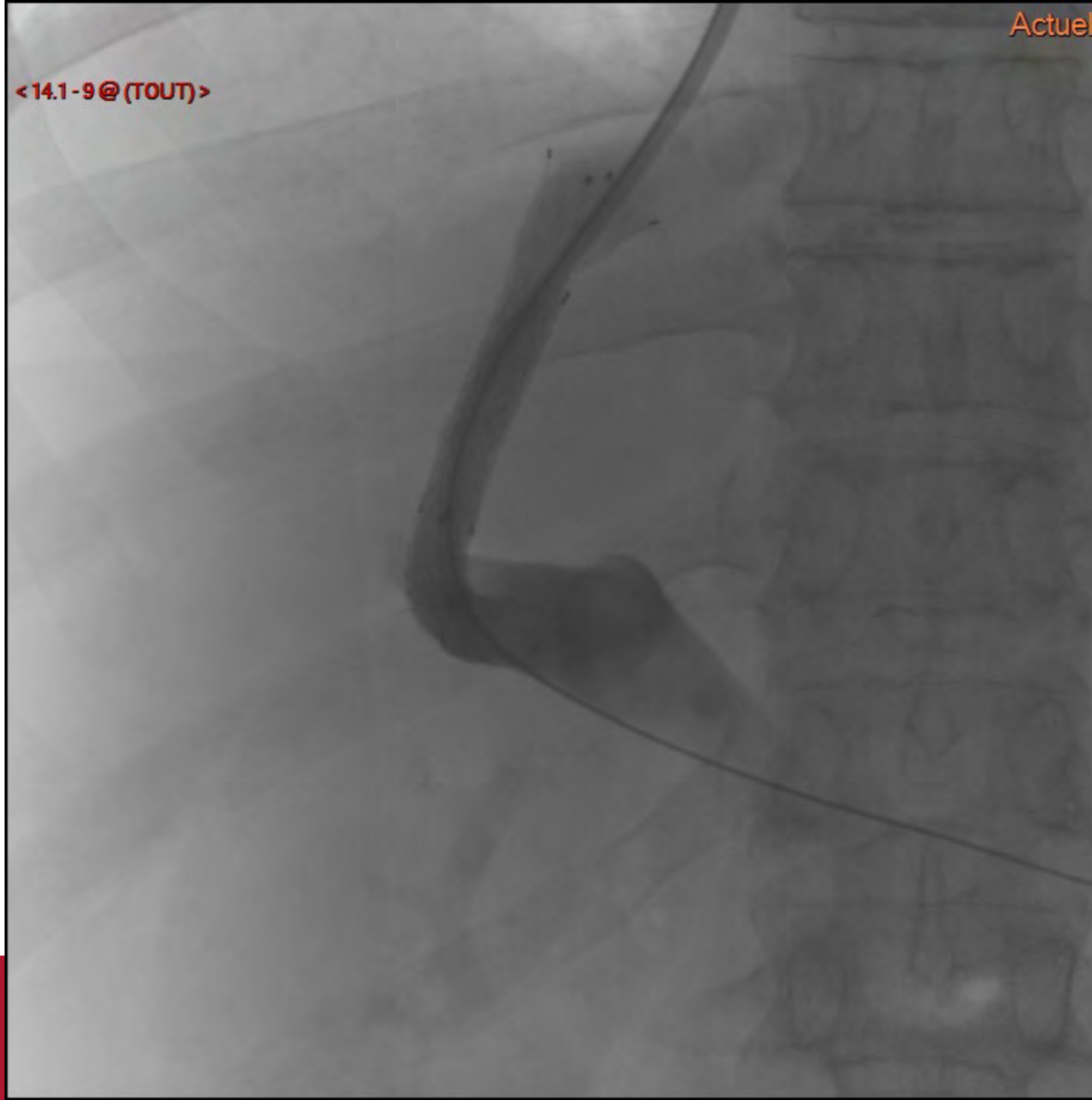
<14.1-7@ (TOUT)>



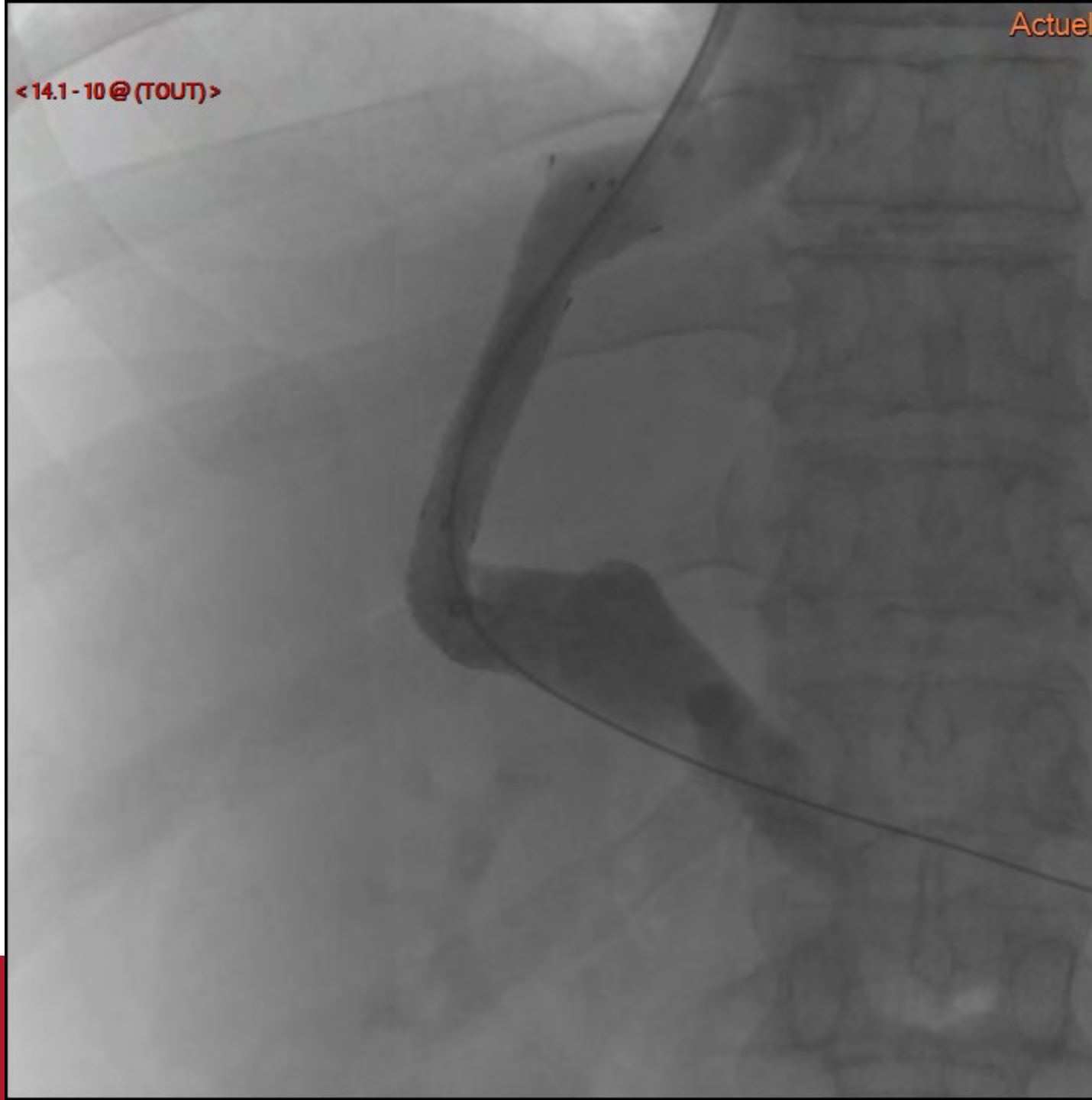
<14.1-8@ (TOUT)>



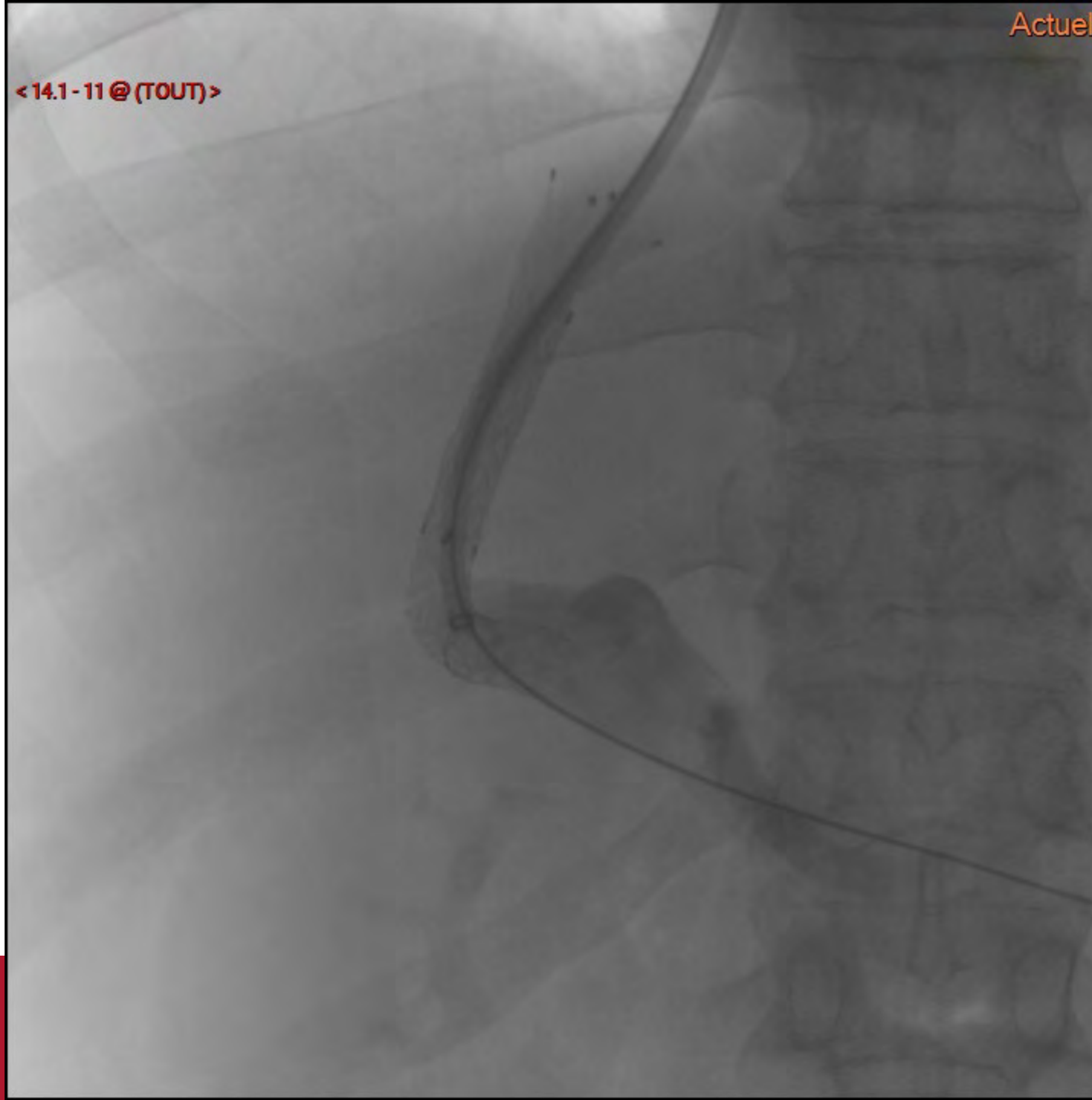
<14.1-9@ (TOU7)>



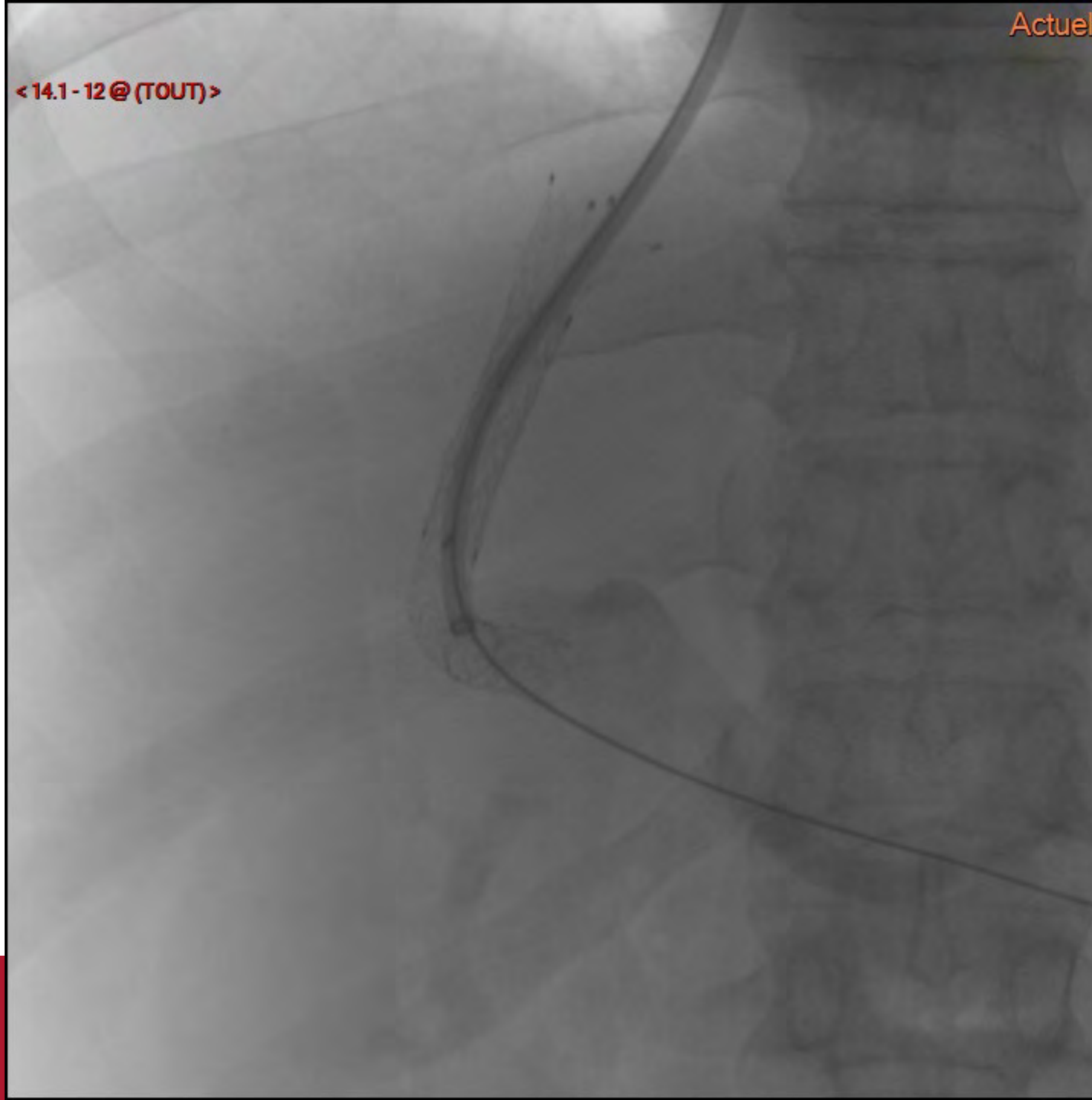
<14.1-10@ (TOUT)>



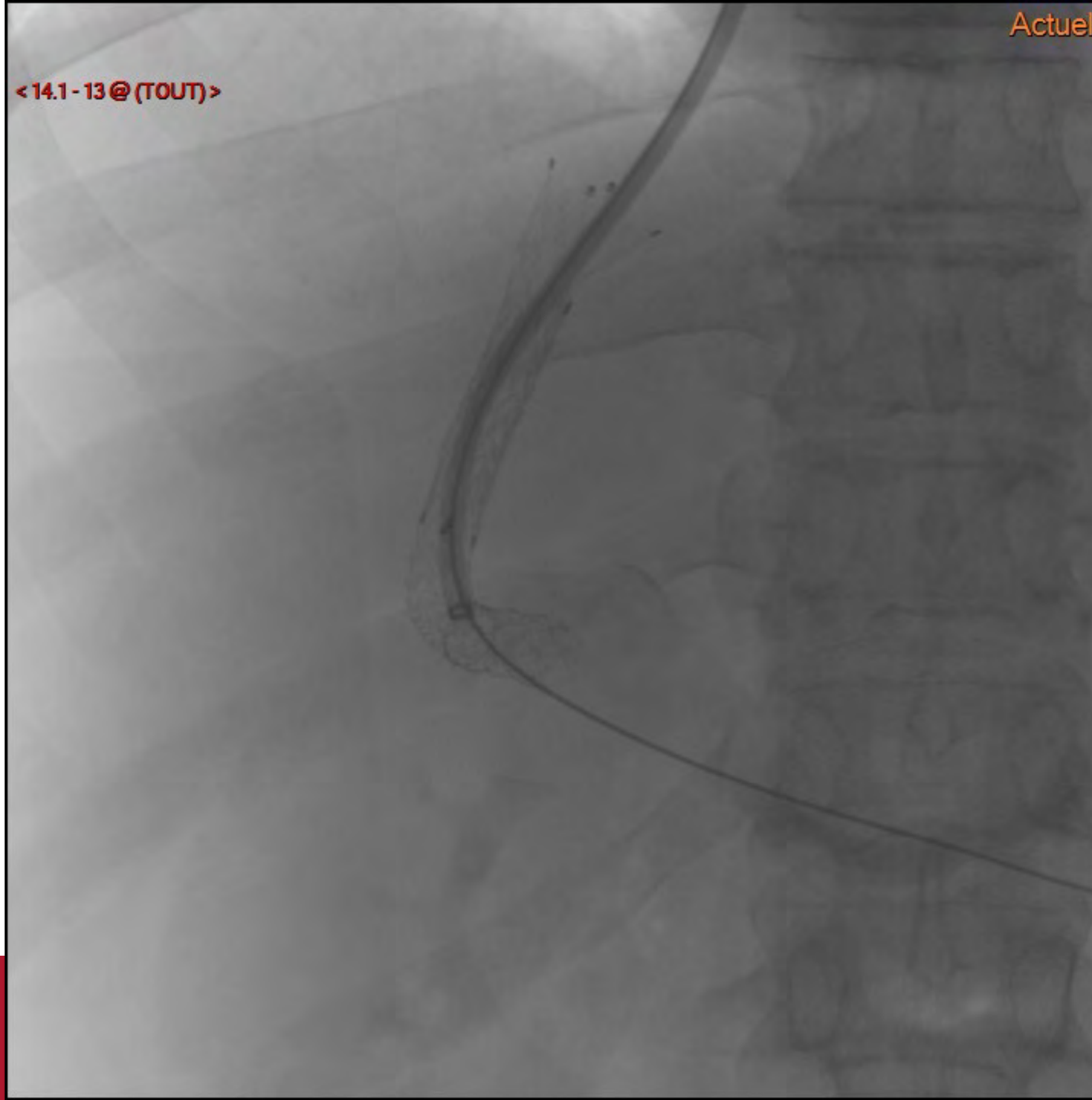
<14.1-11@ (TOUT)>



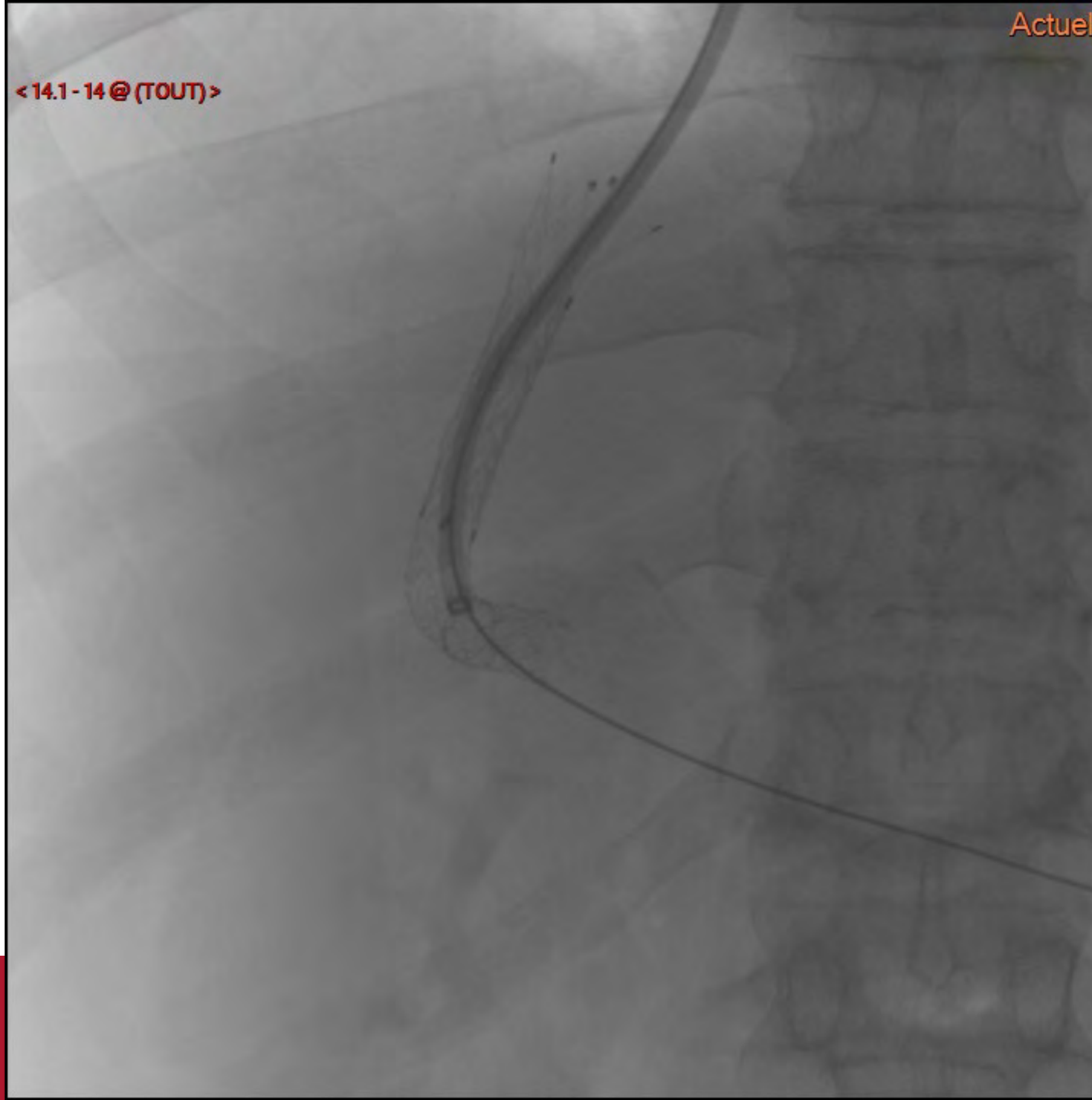
<14.1-12@ (TOUT)>



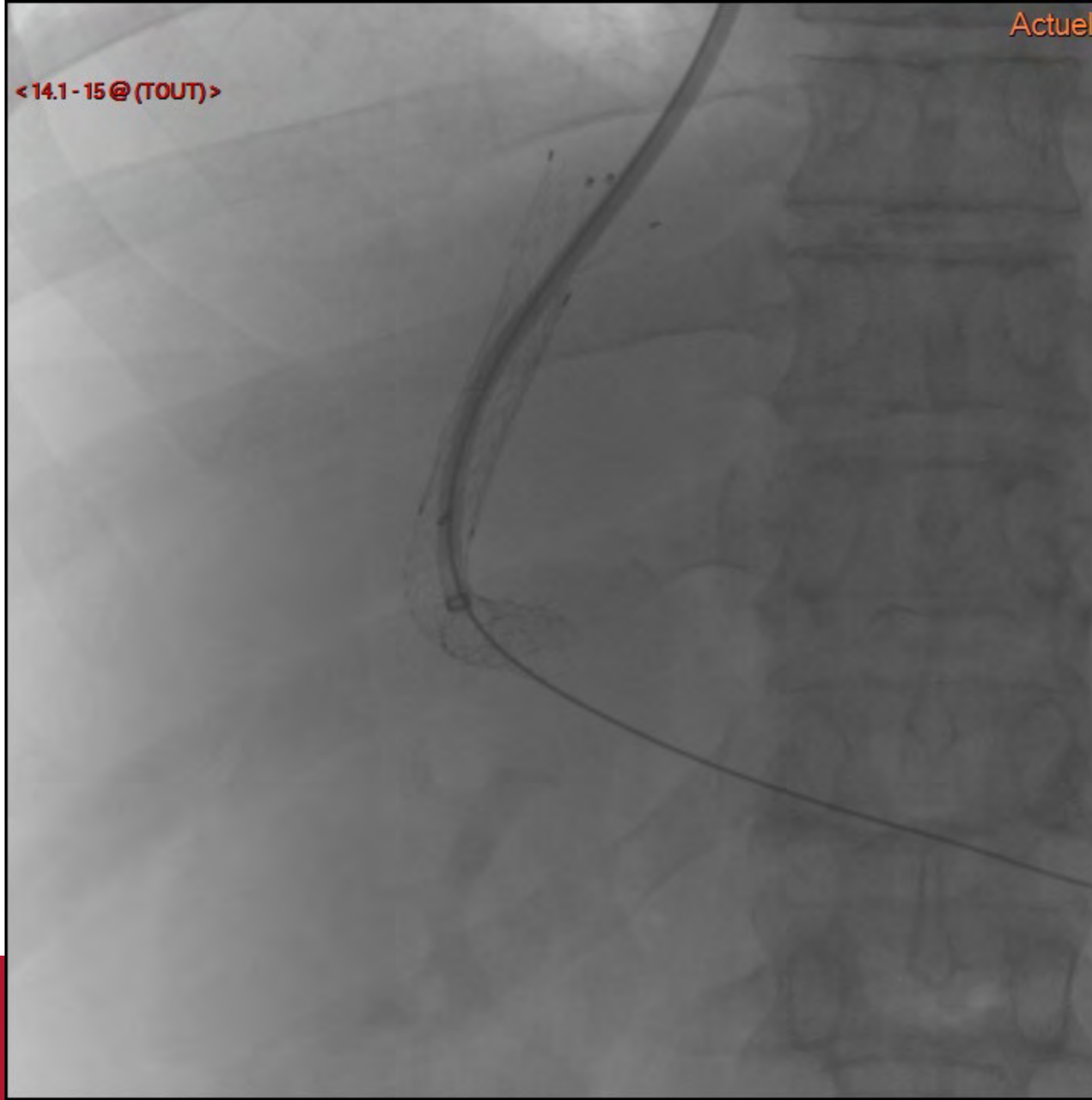
<14.1-13@ (TOUT)>



<14.1-14@ (TOUT)>



< 14.1 - 15 @ (TOUT) >



<14.1 - 16@ (TOUT)>

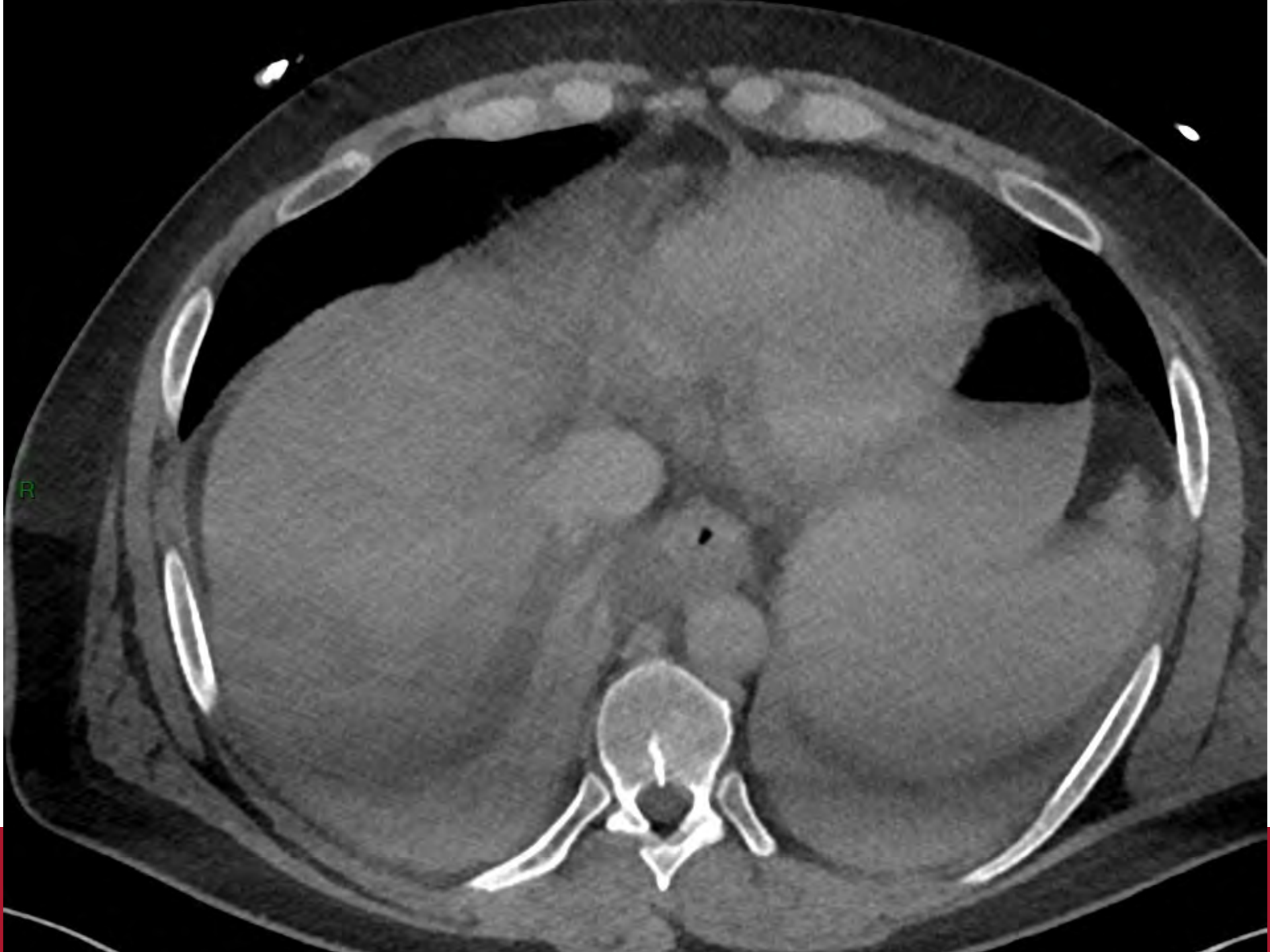
Gradient final : 14 mmHg

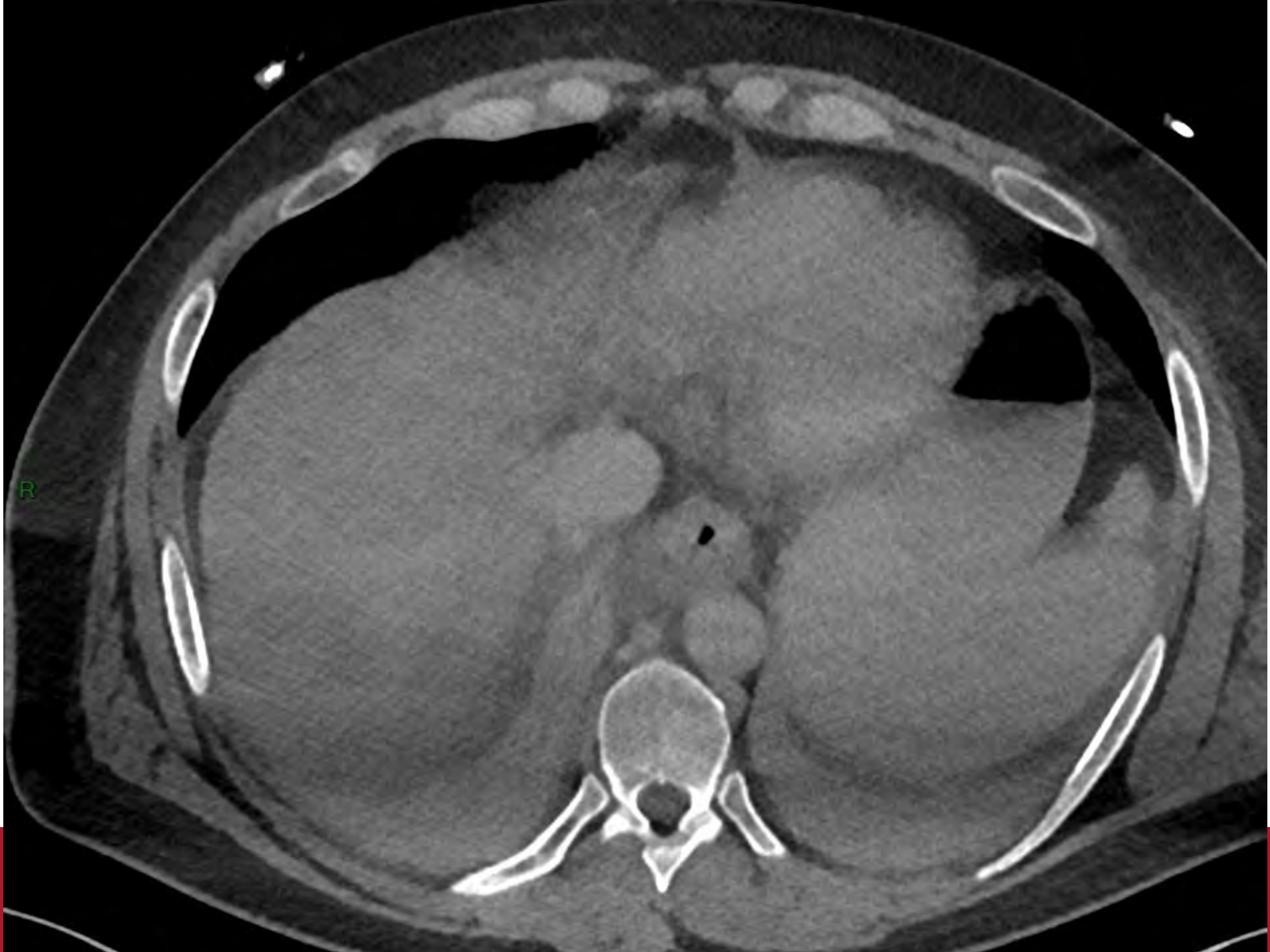Cas n°3

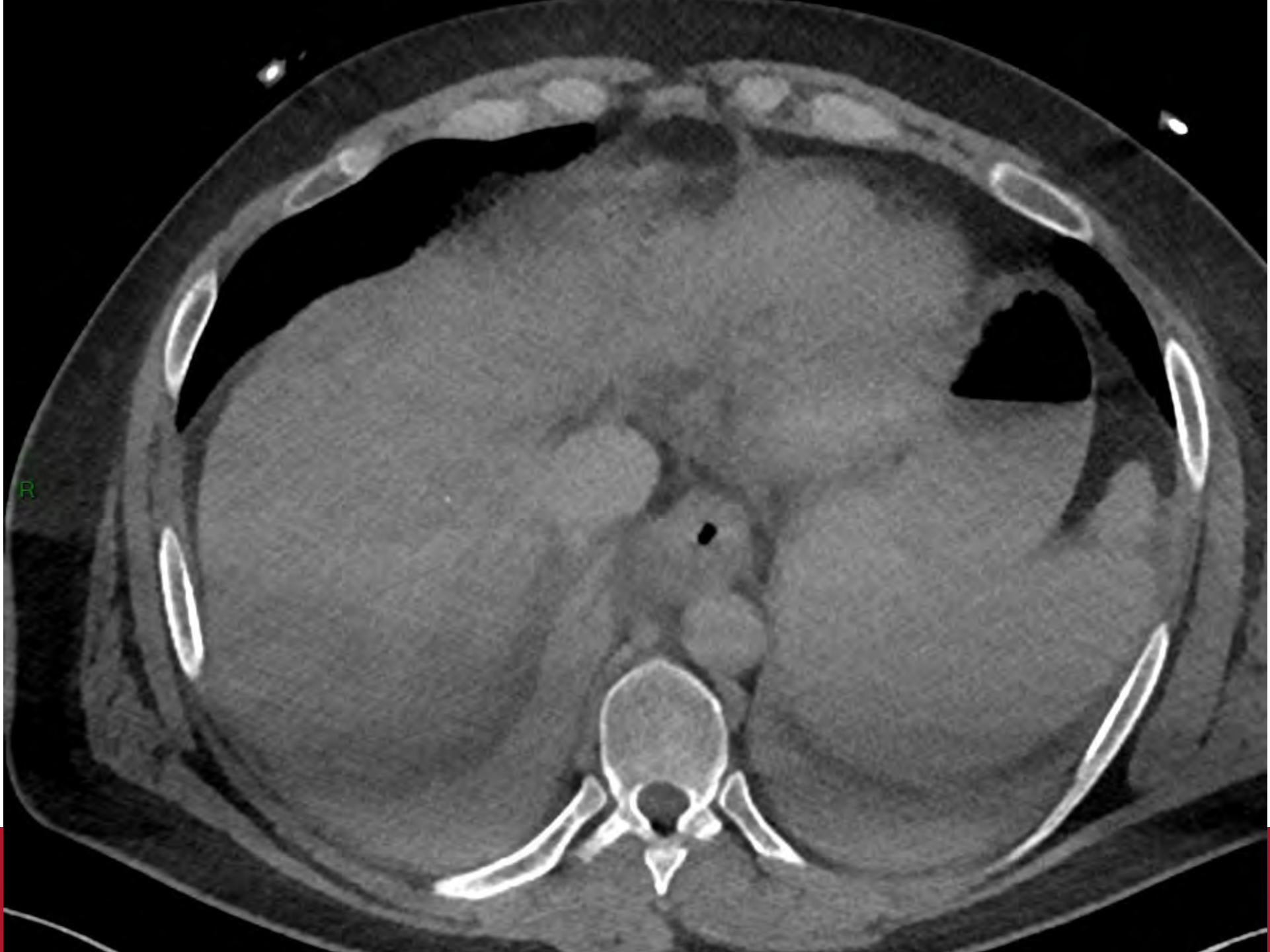
- Evolution:
 - Contrôle du choc hémorragique sans rentabilité transfusionnelle
 - Reprise endoscopique (premier ttt endoscopique pas optimal)
 - Arrêt saignement
- Alternative en RX vasculaire ...

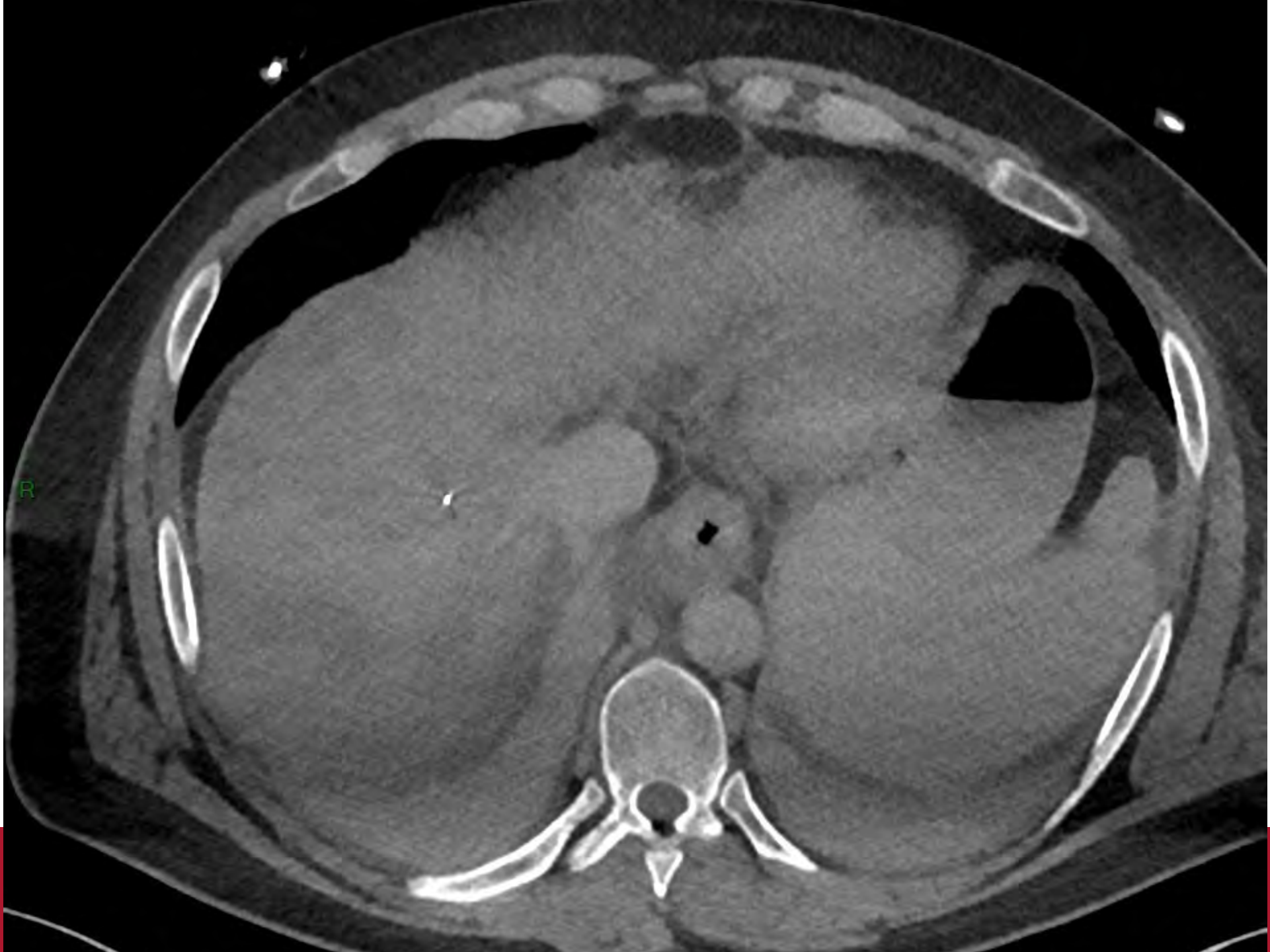Cas n°3

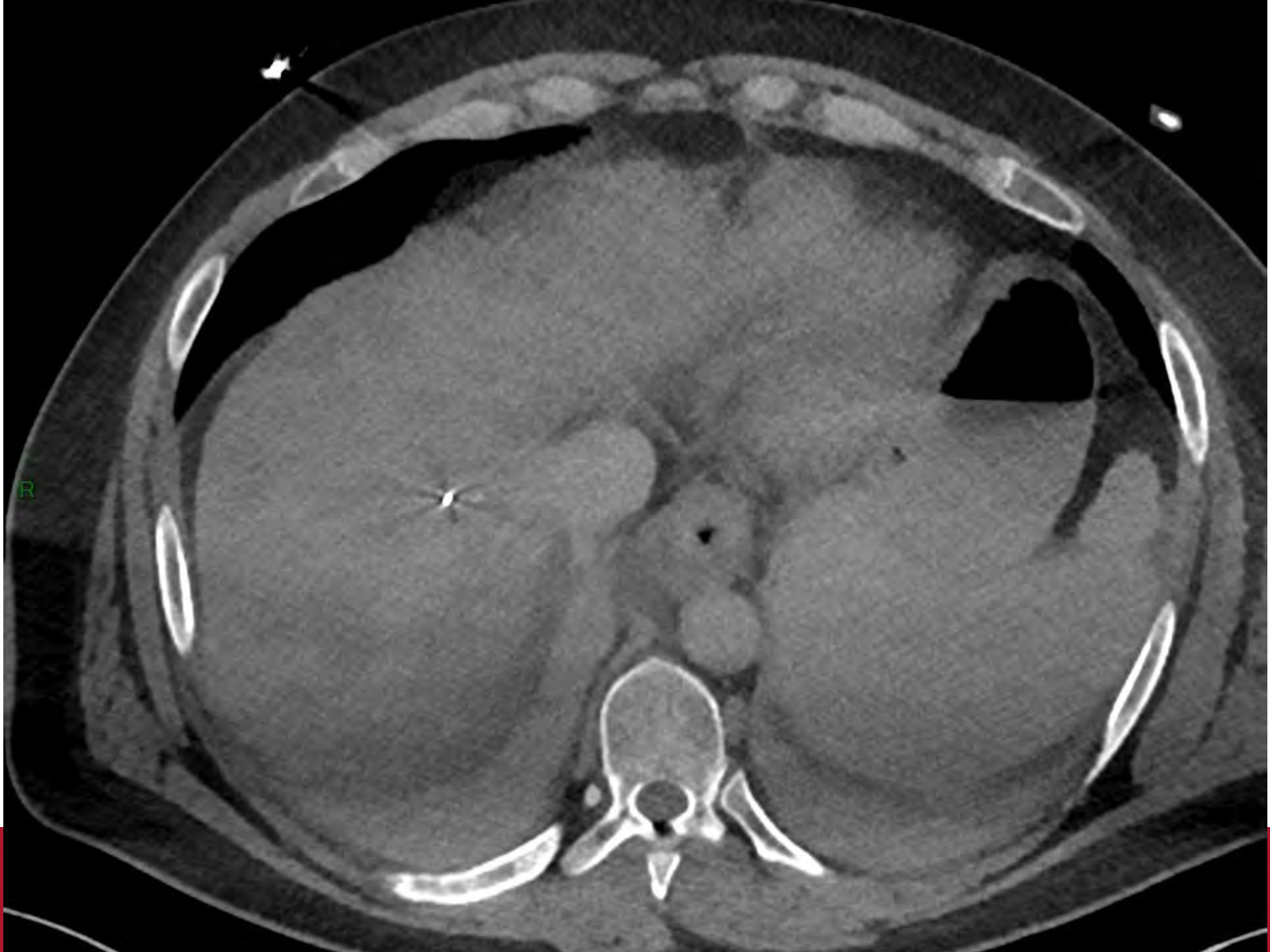- Evolution:
 - 2 épisodes infectieux: PAVM et infection sur KT, résolutifs
 - Nouvelle mesure du GPH le 25/05/22

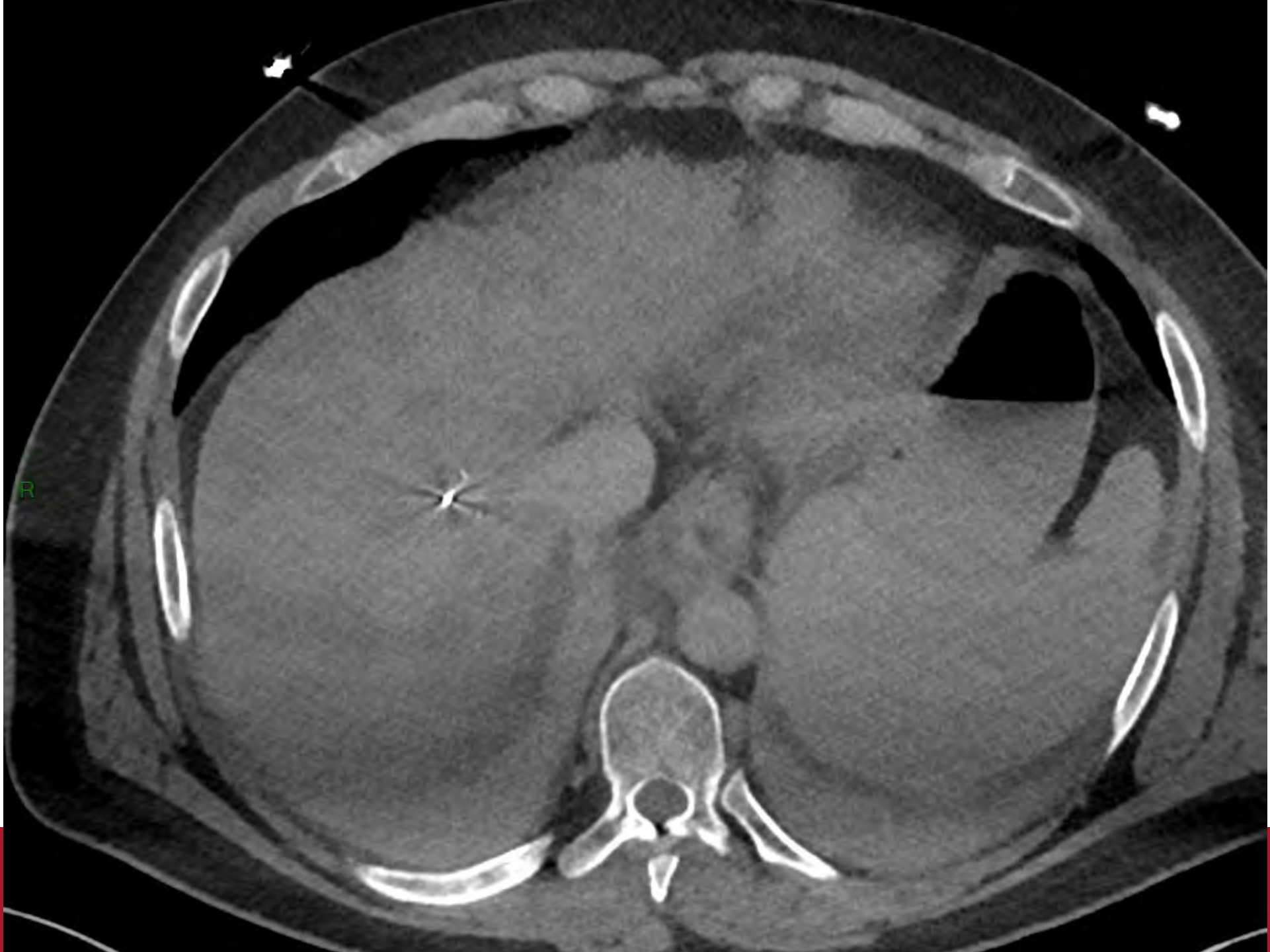


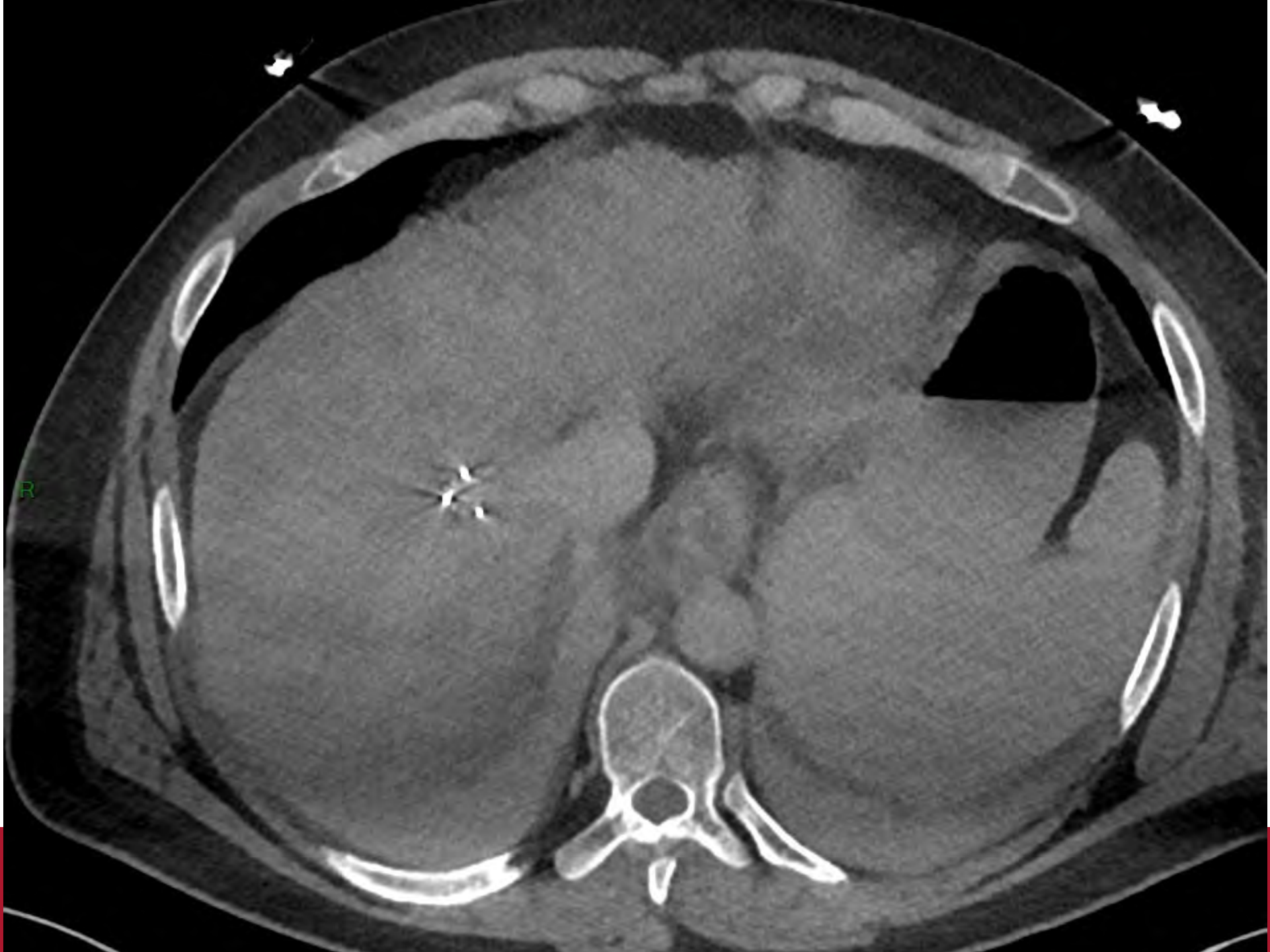


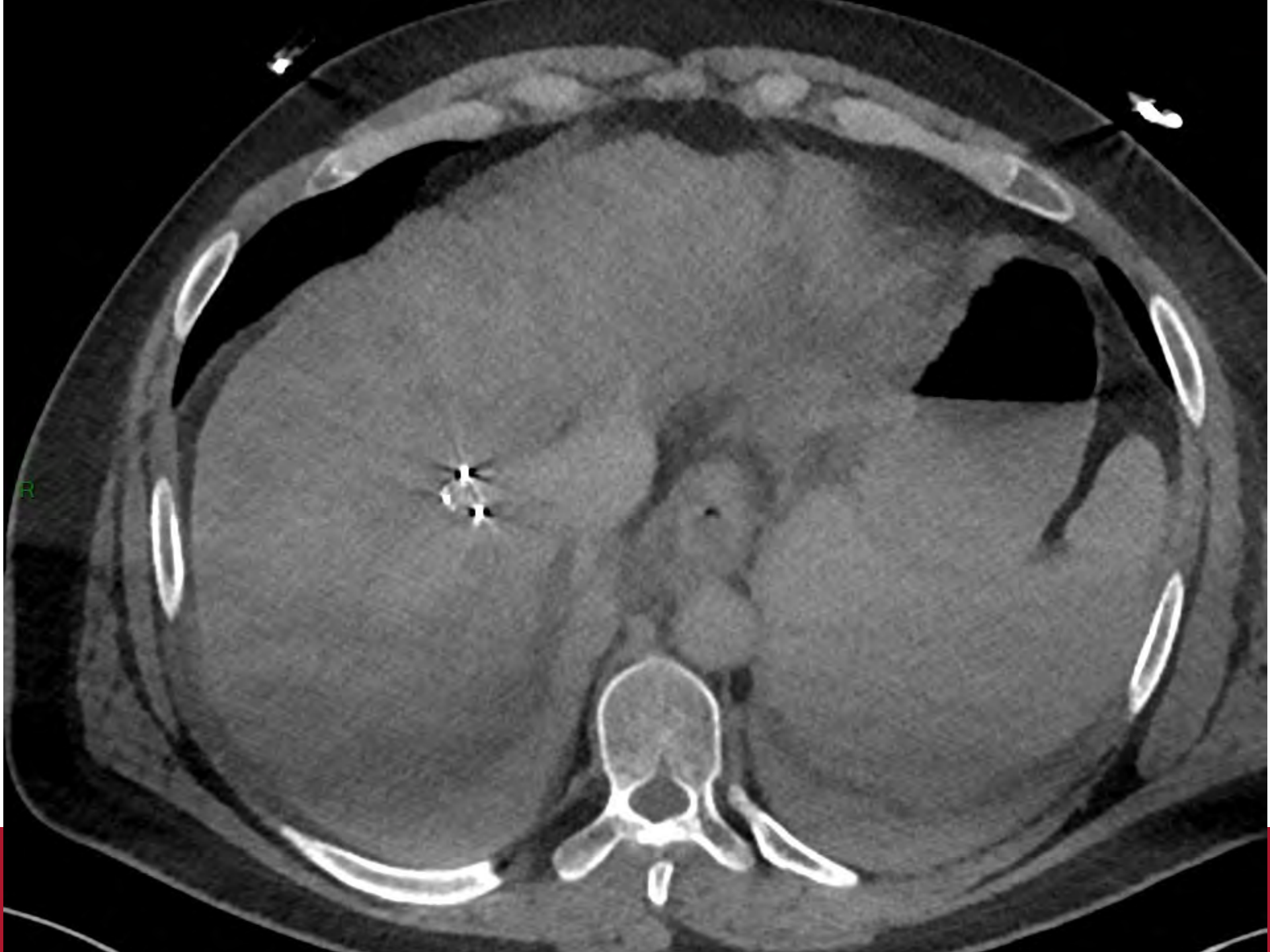

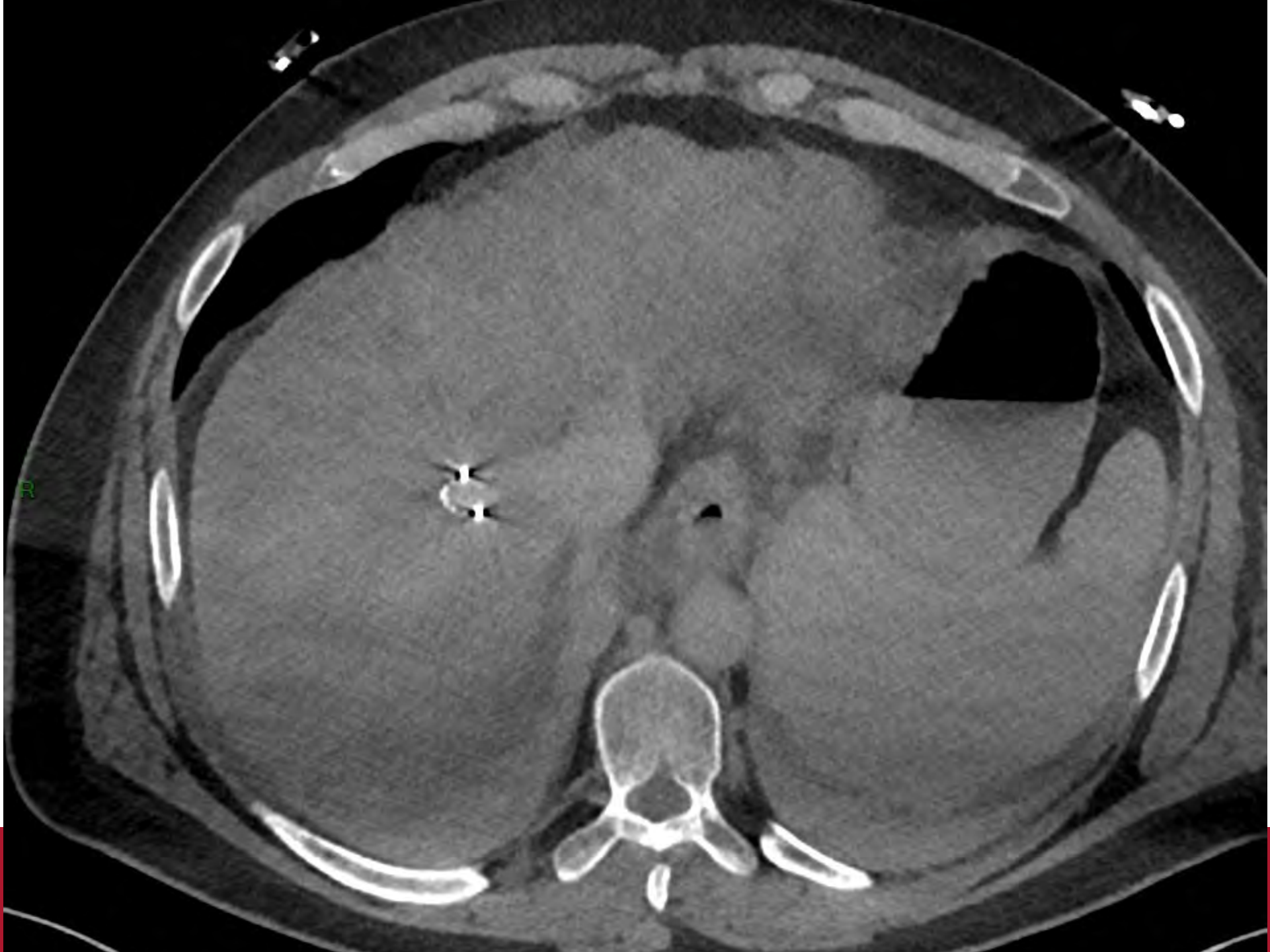


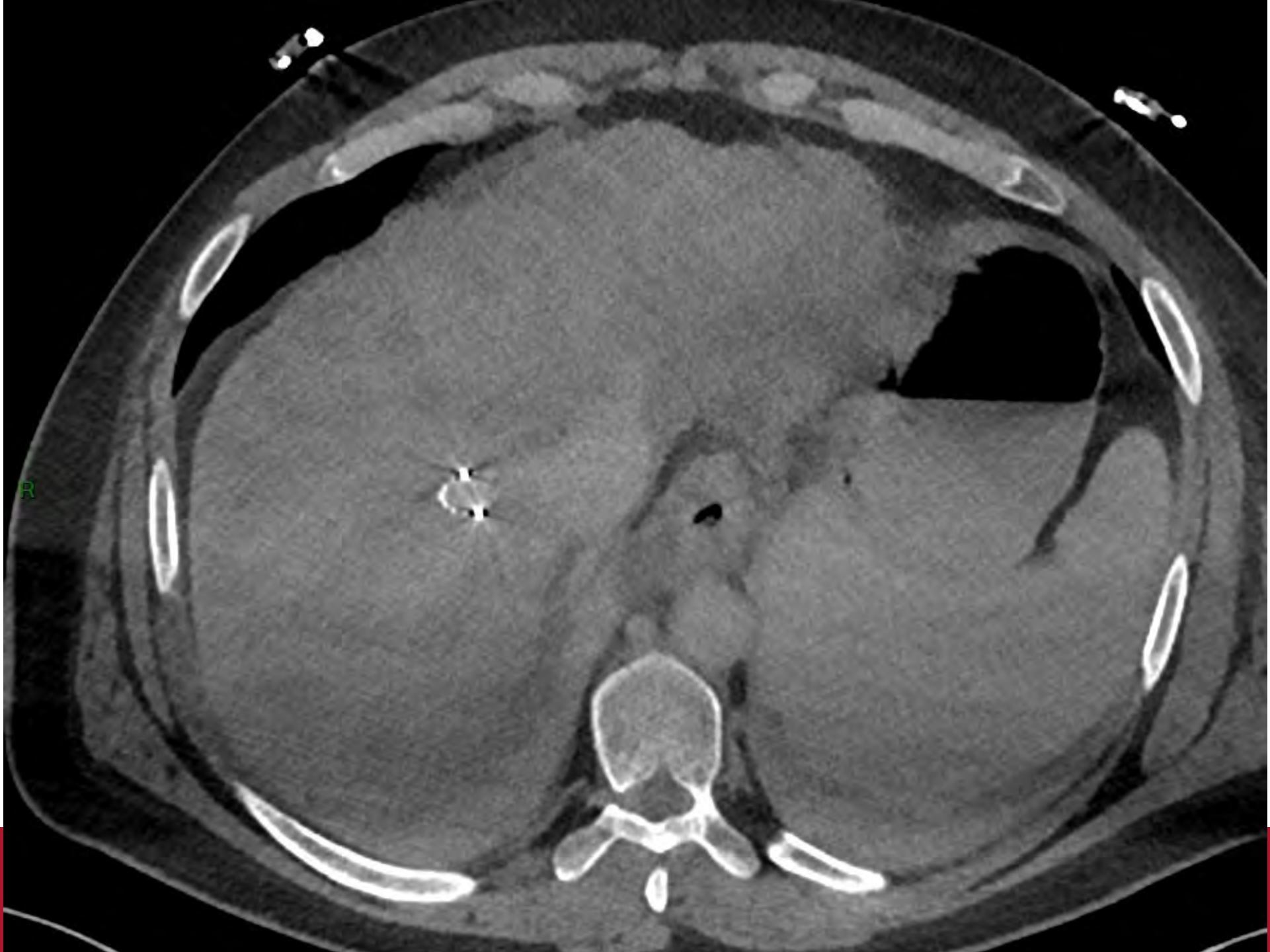



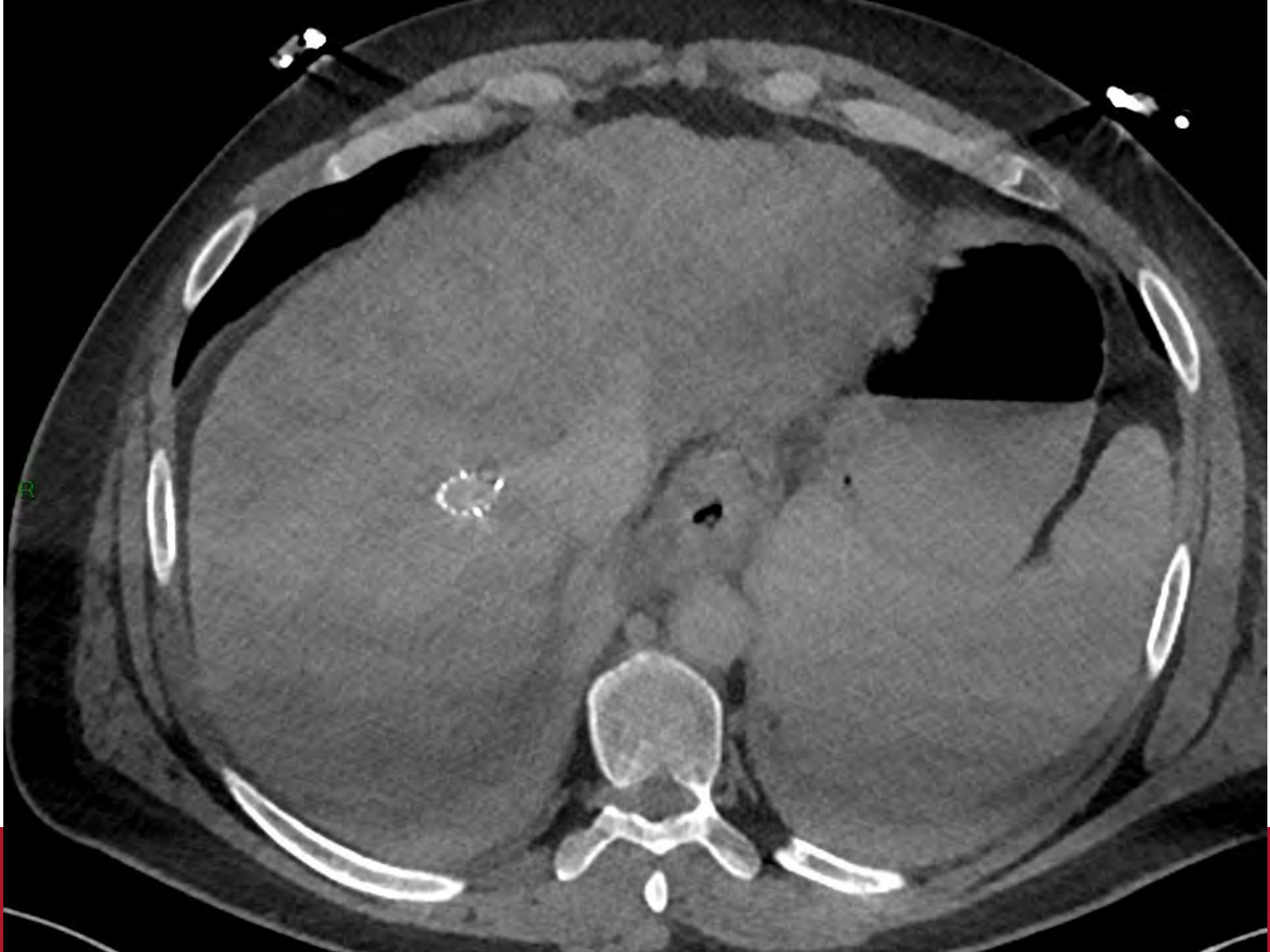


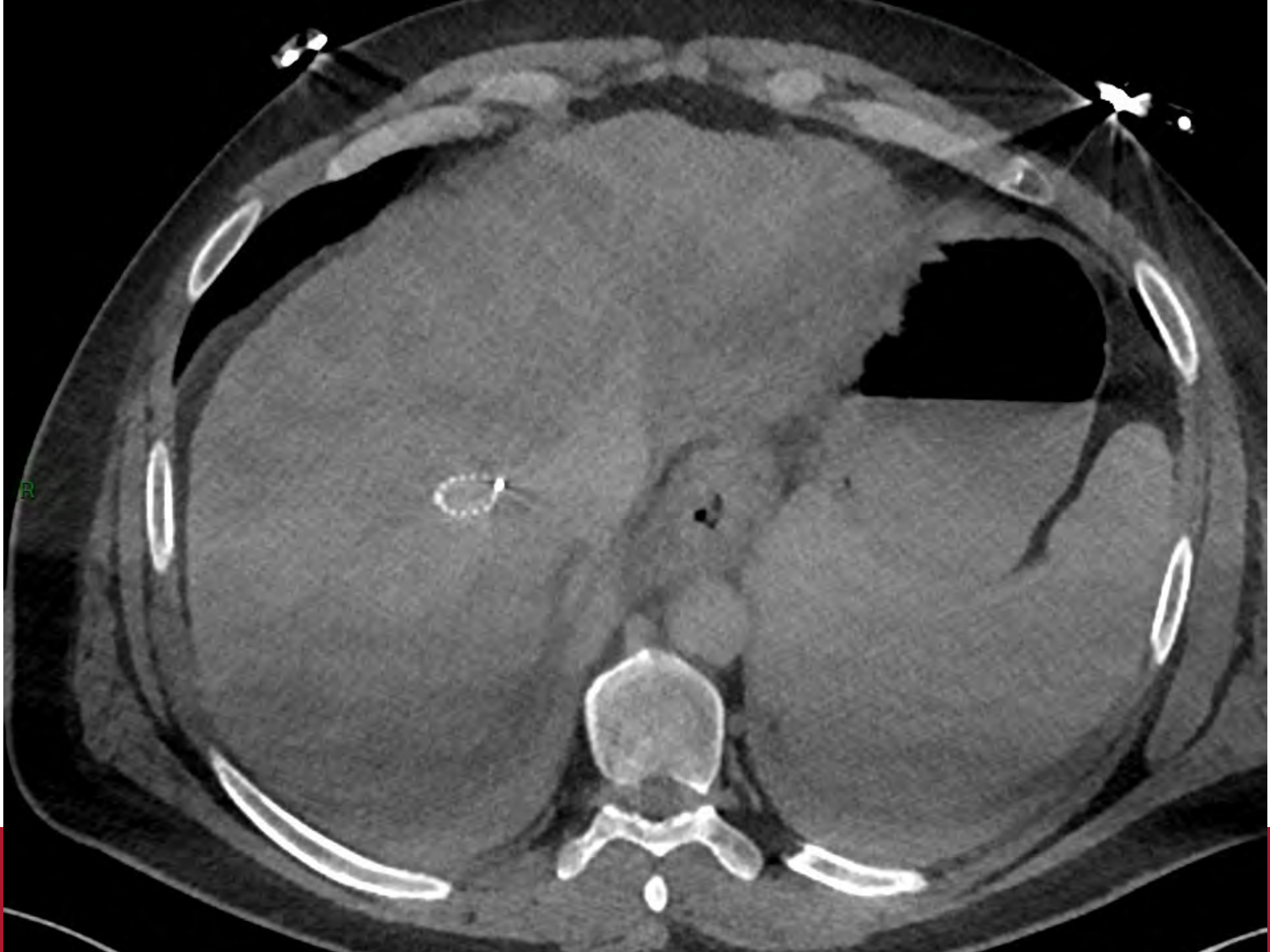

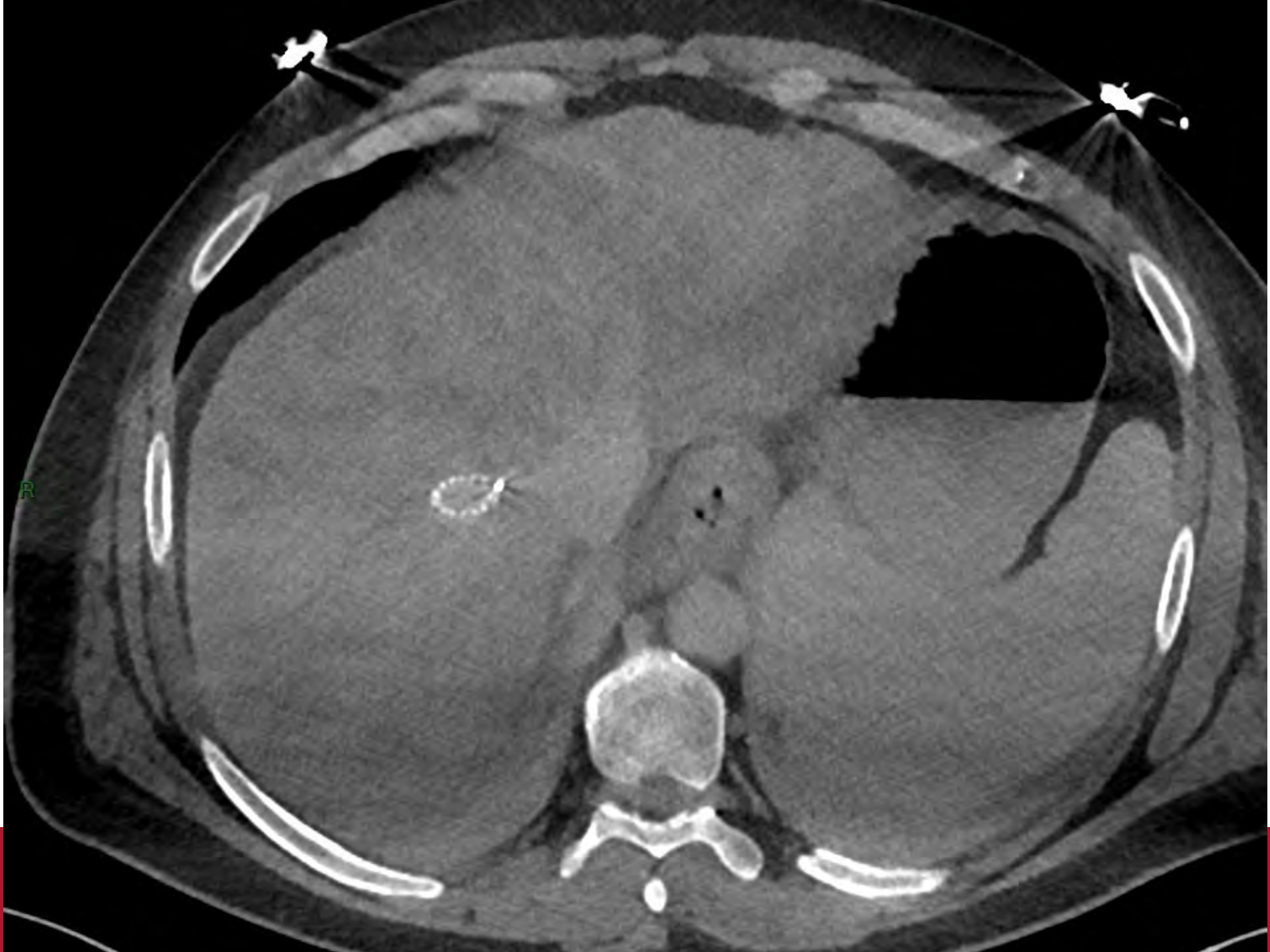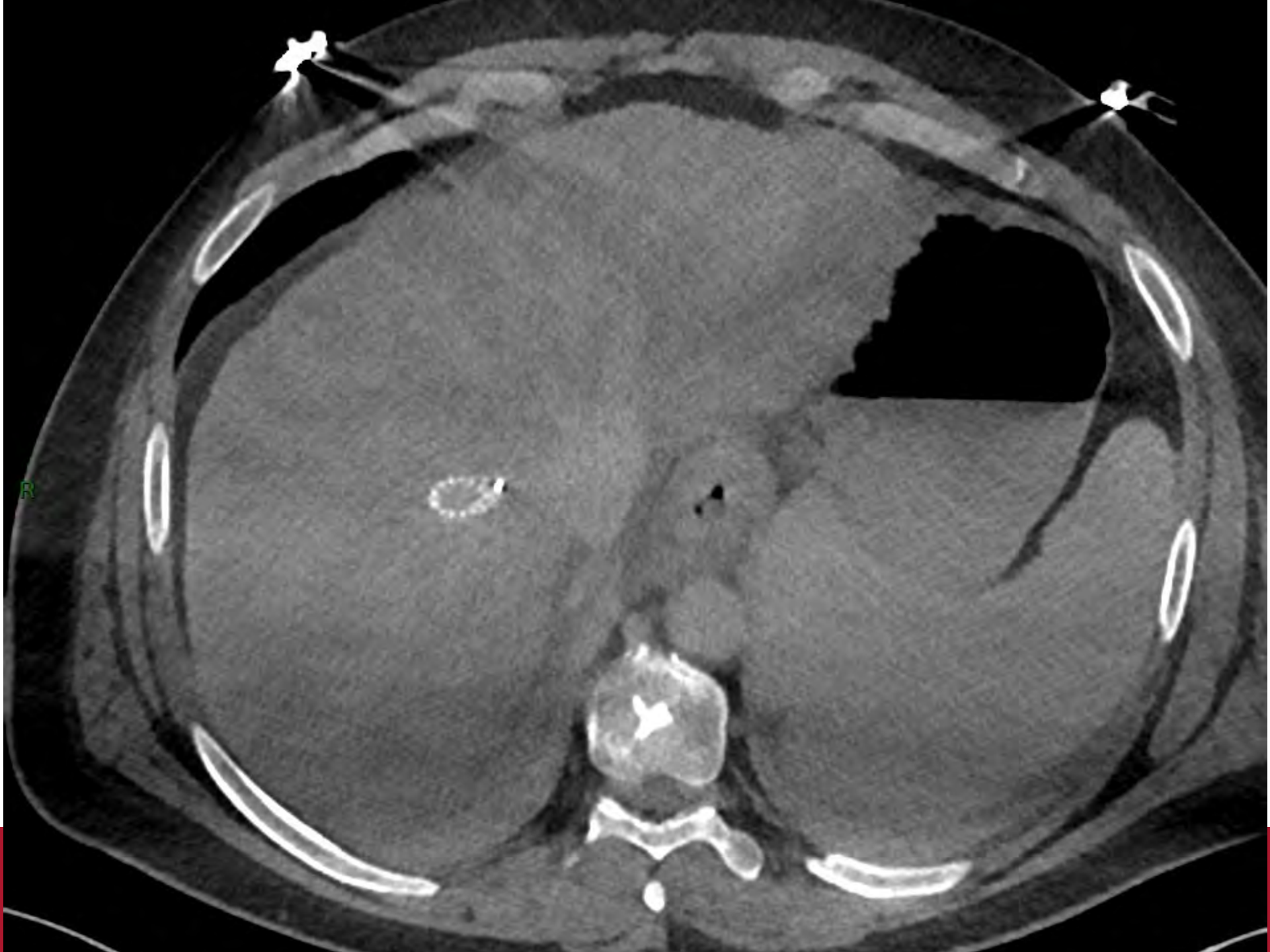


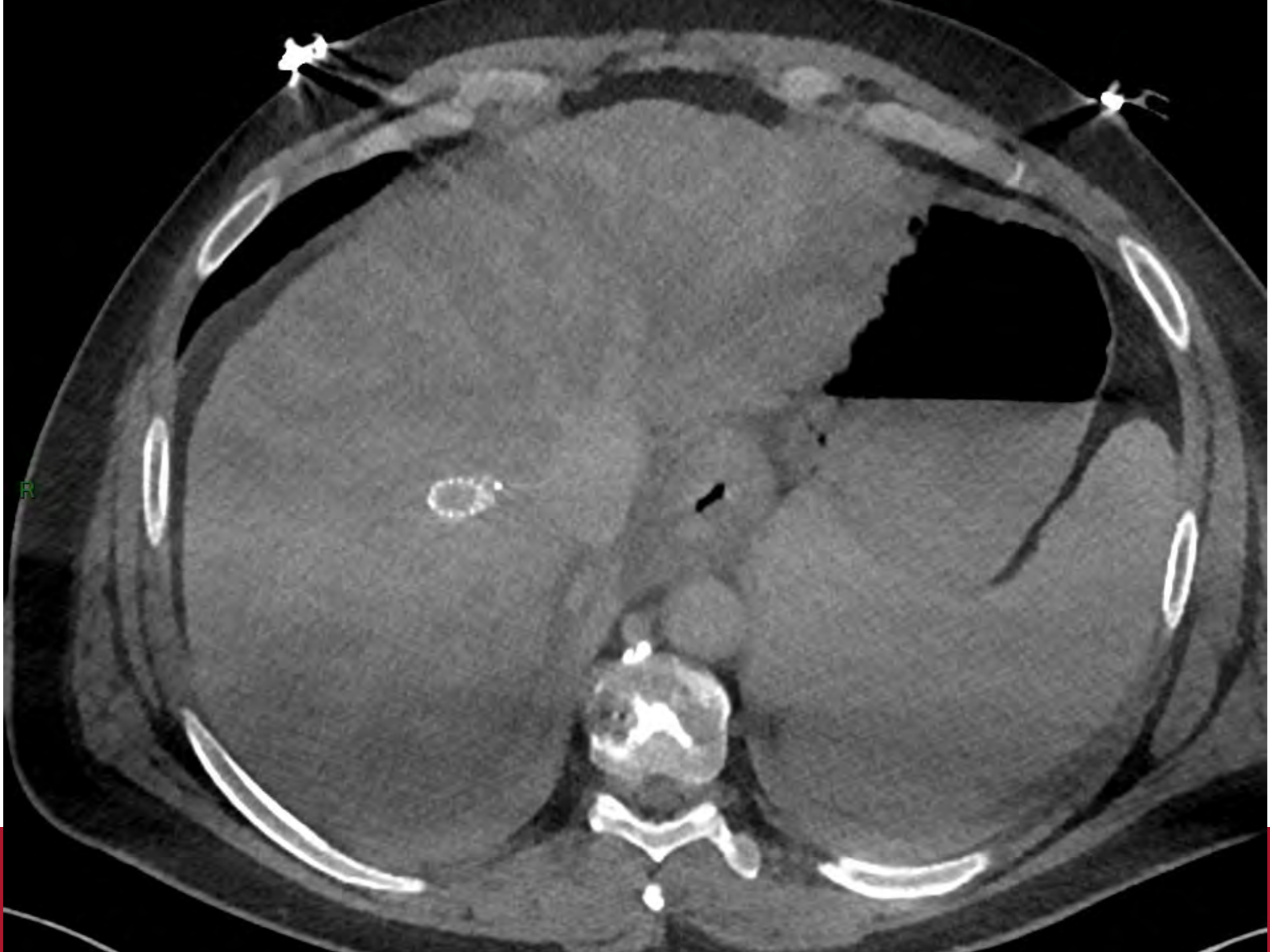






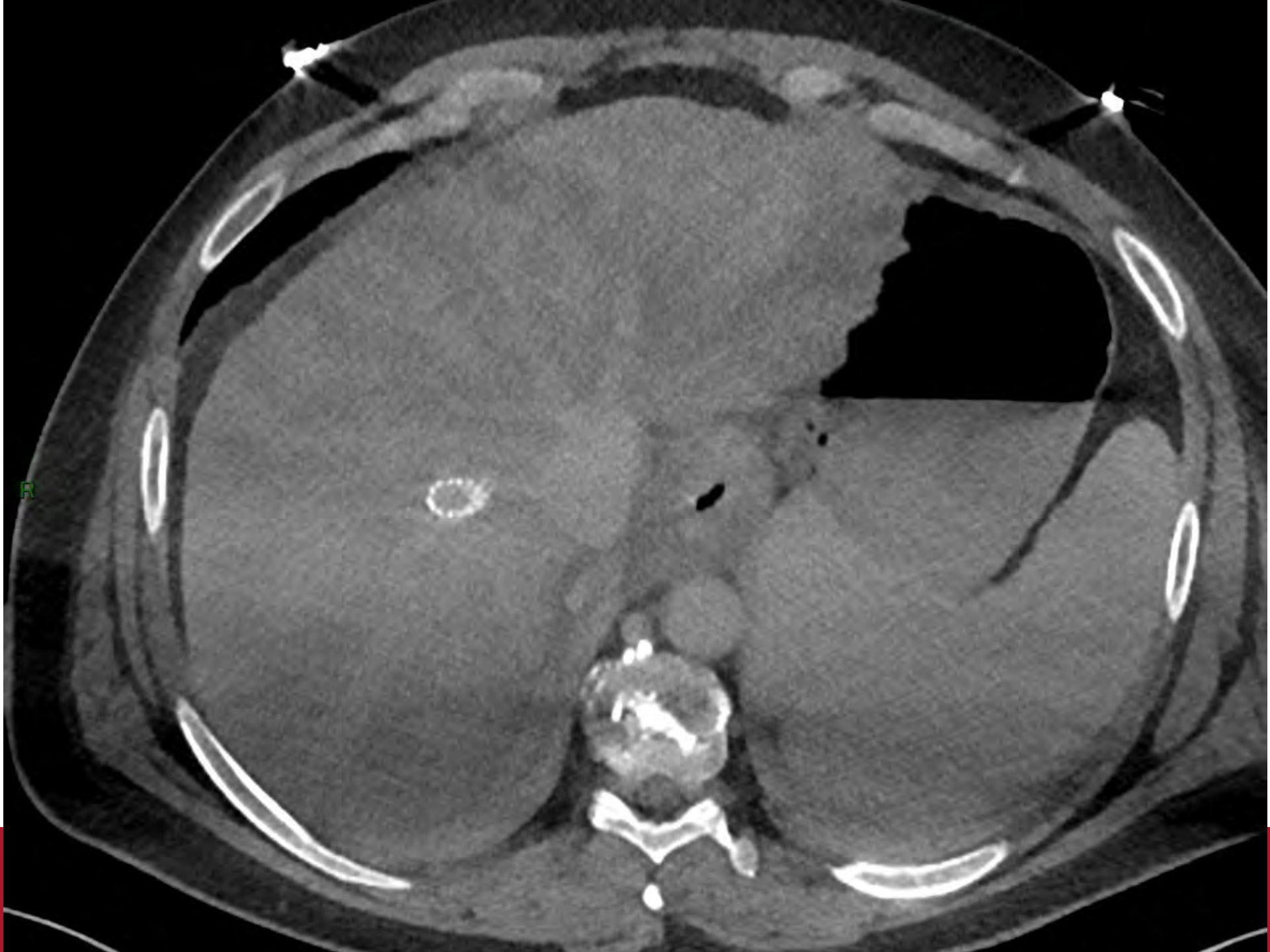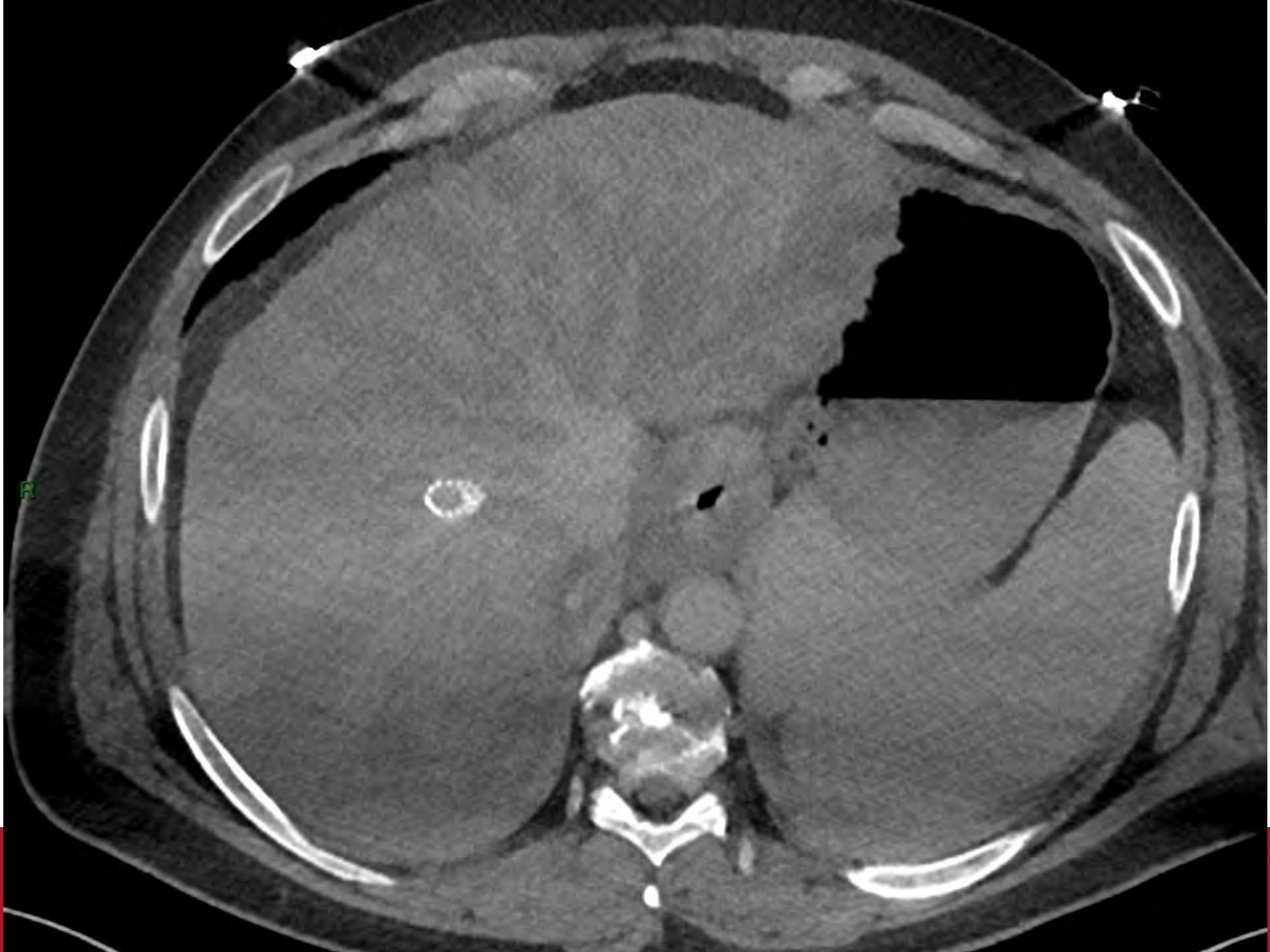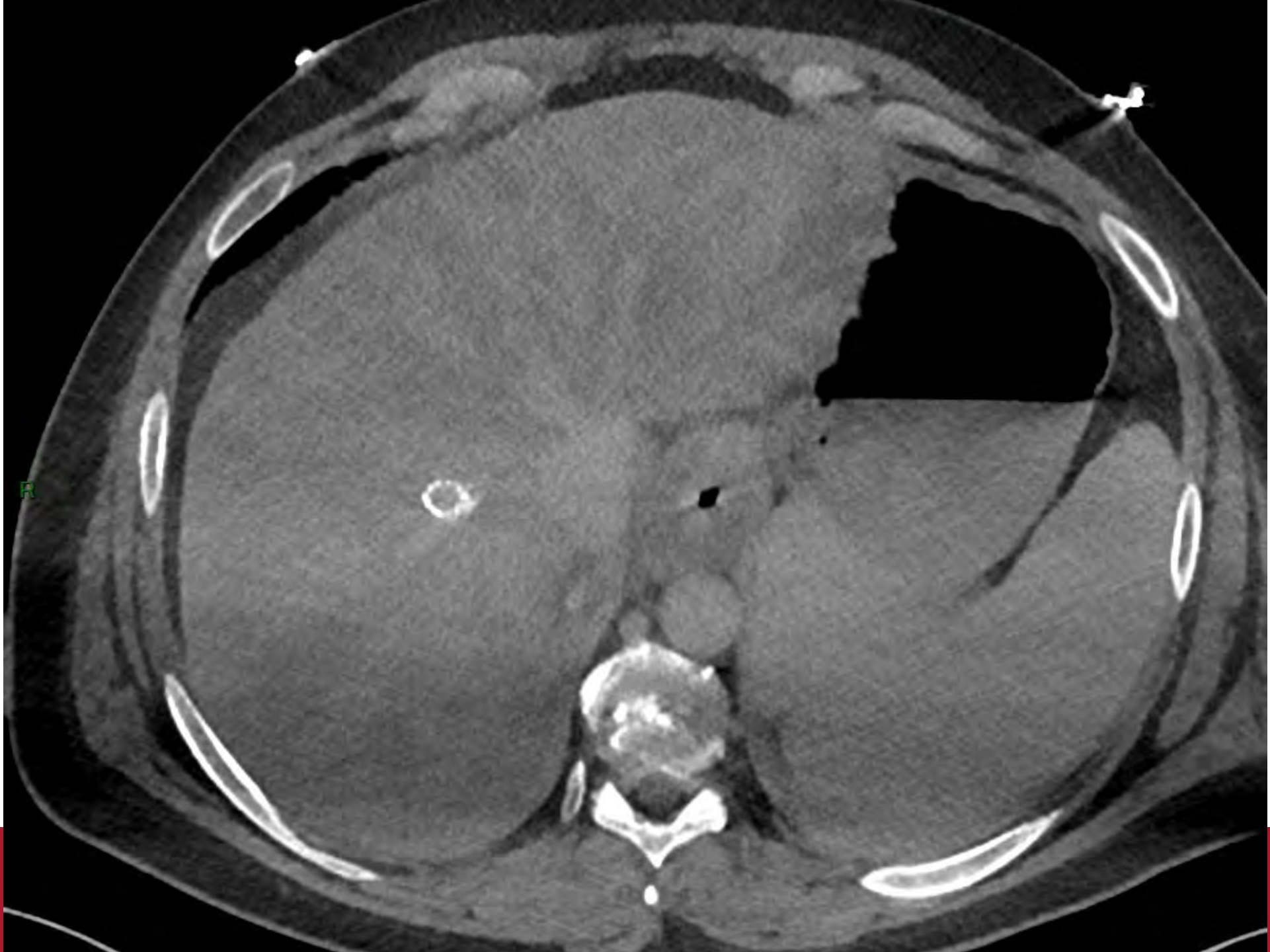


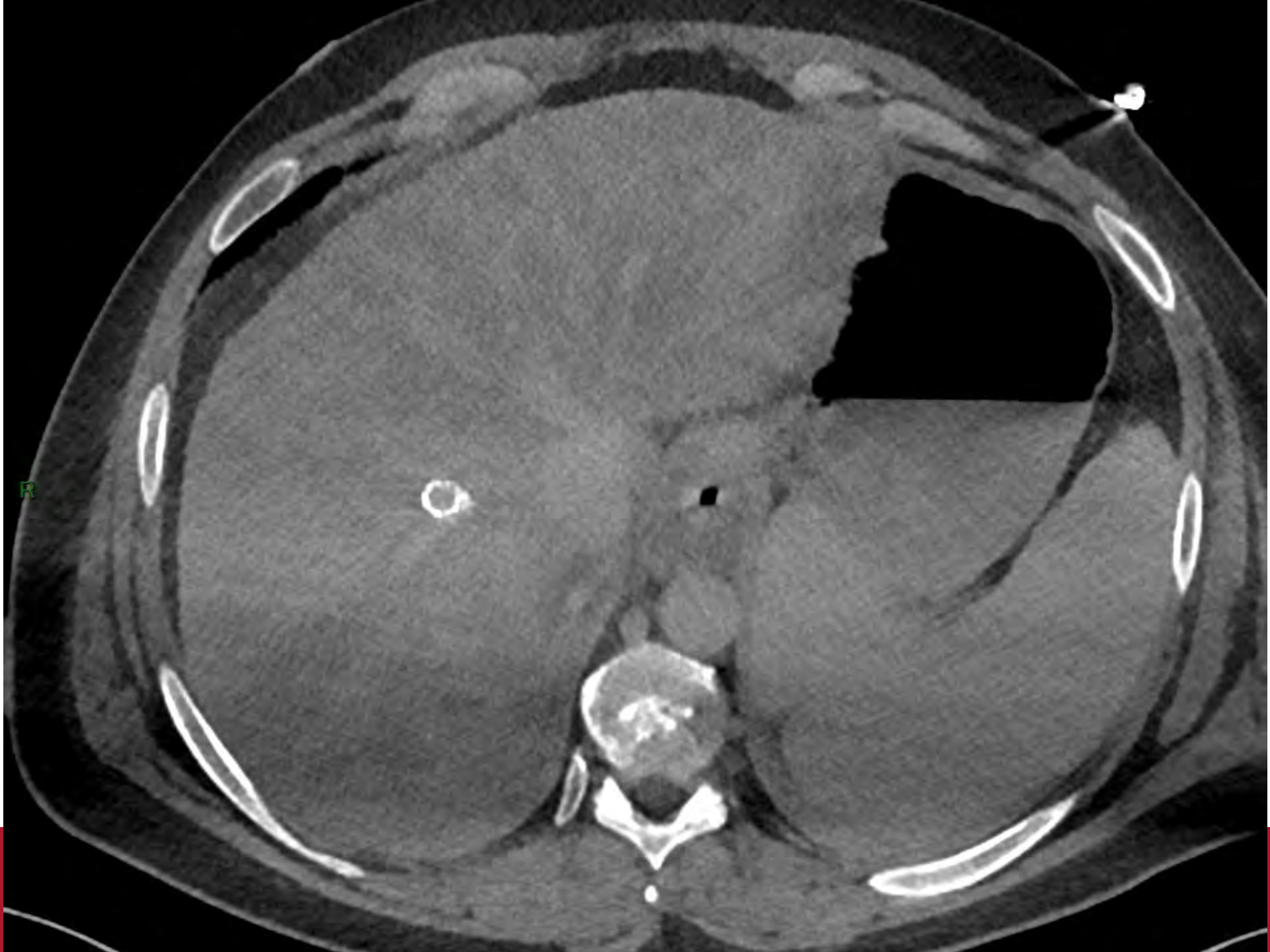


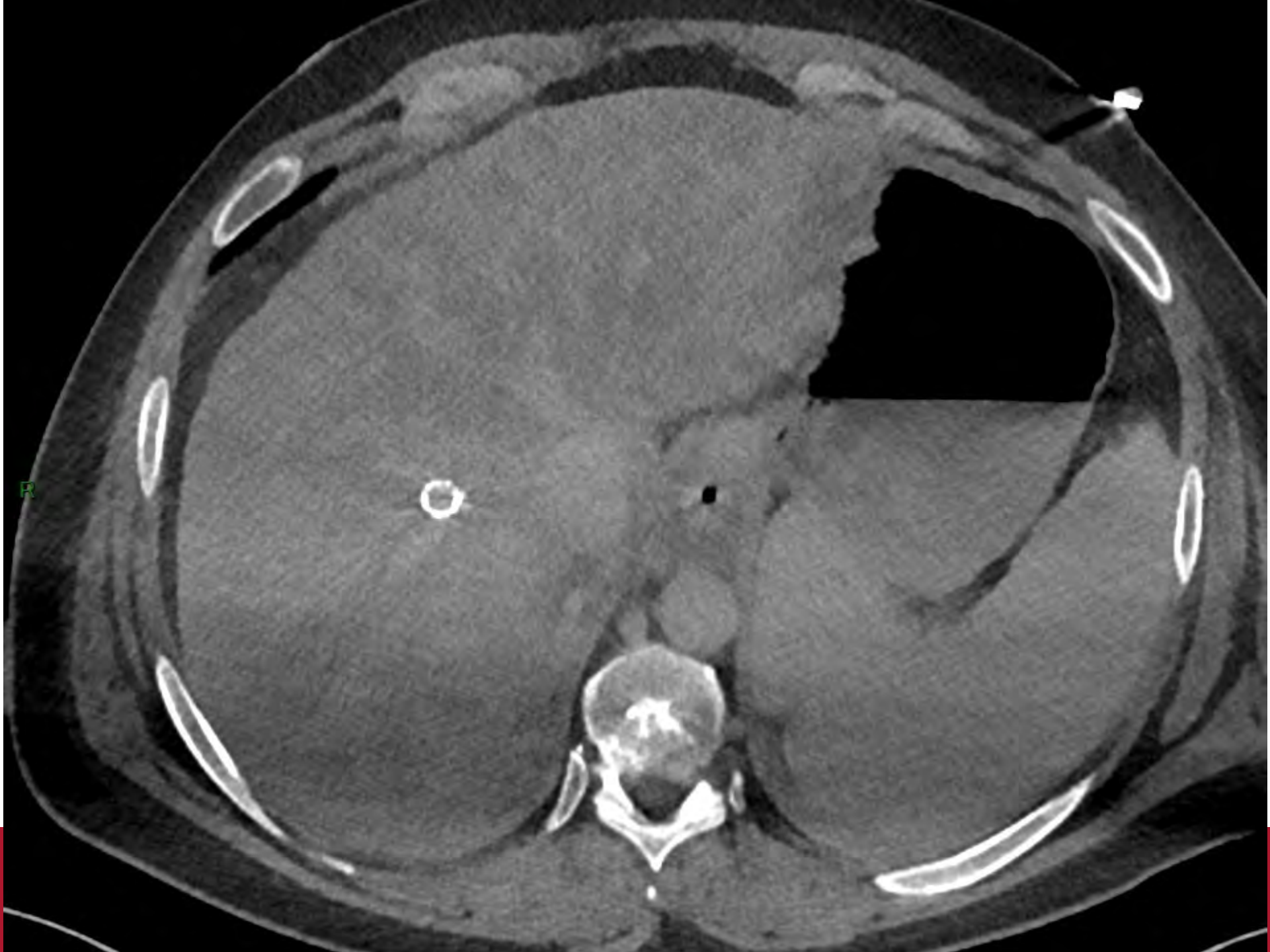


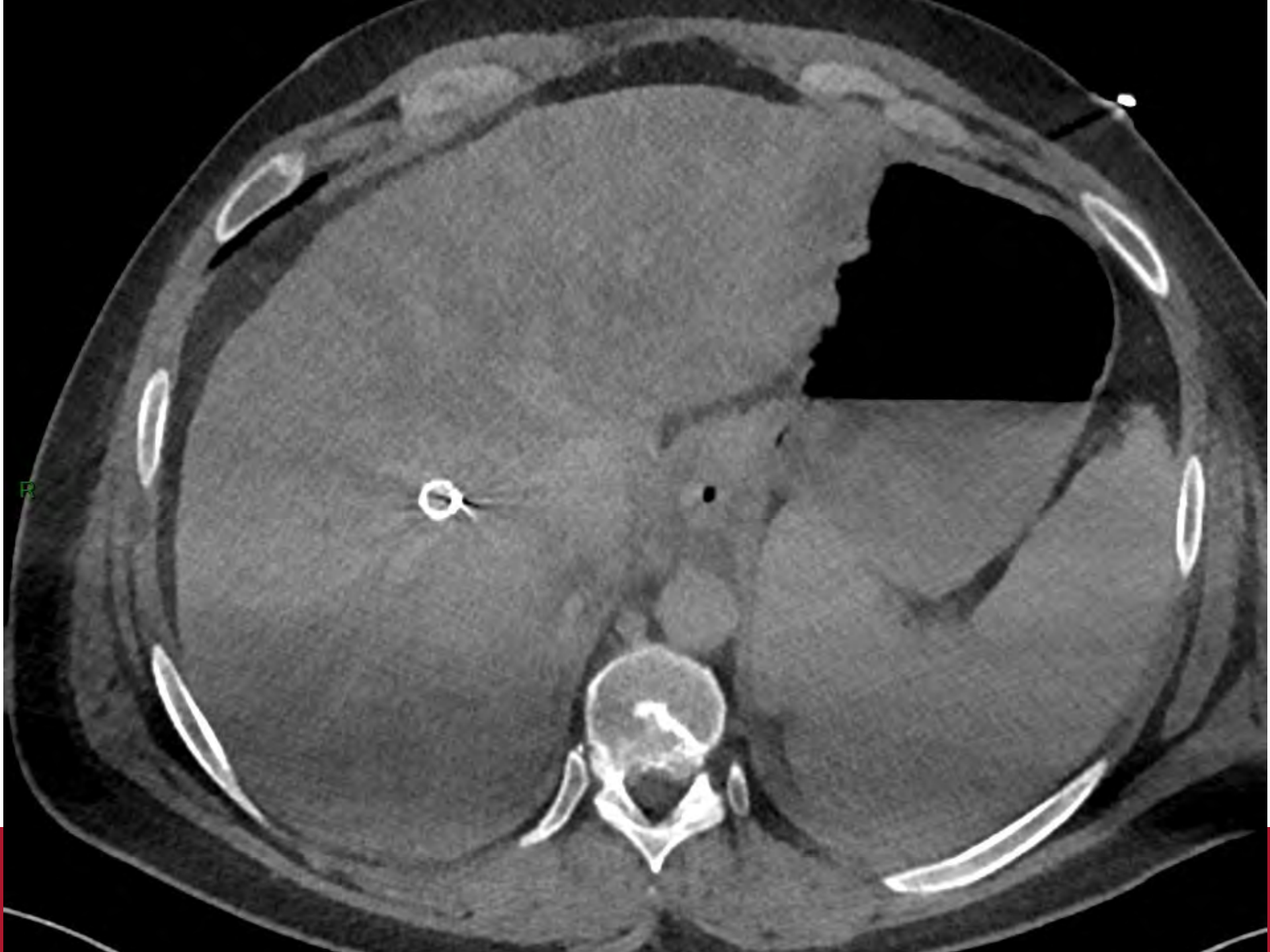


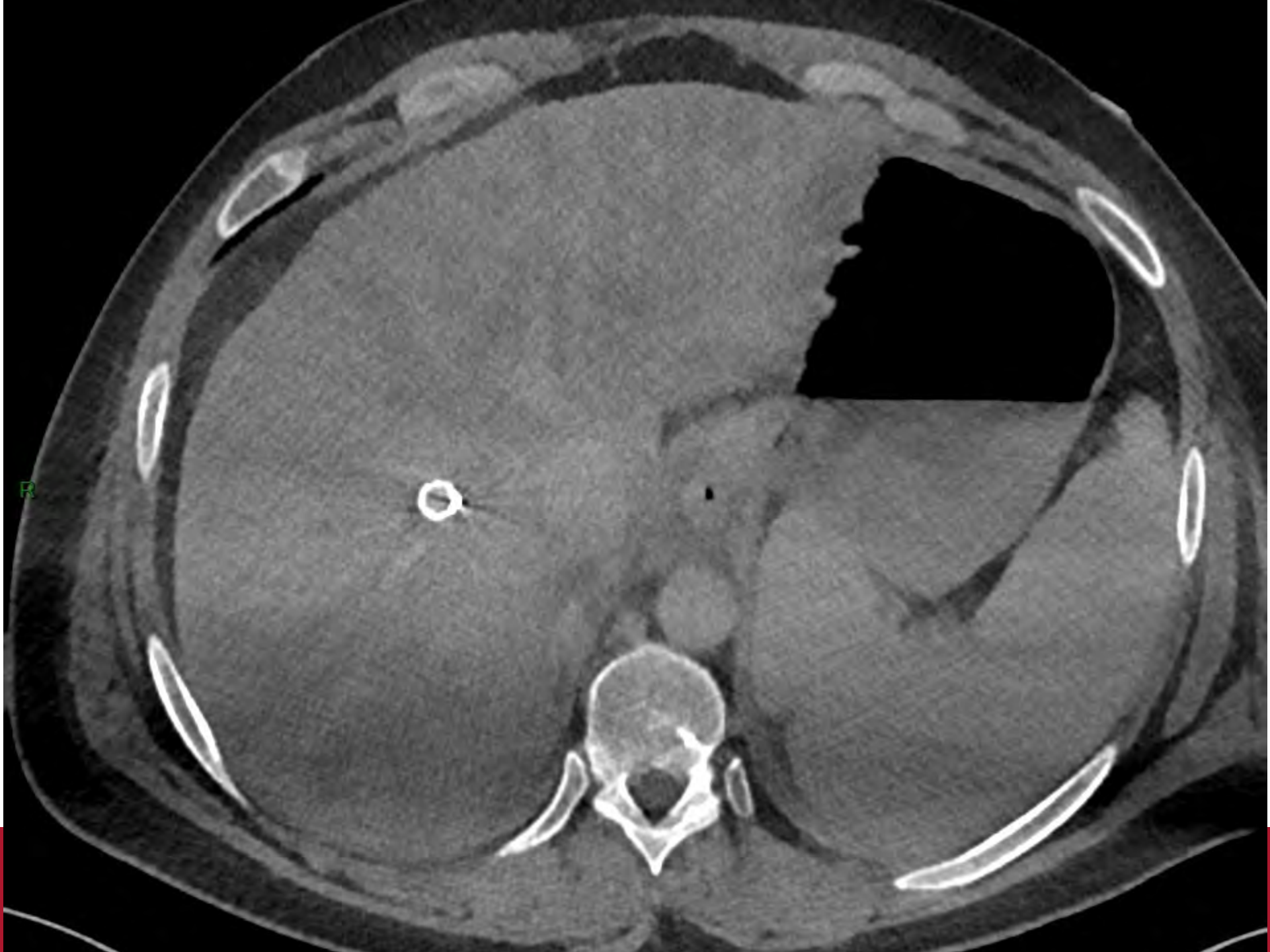


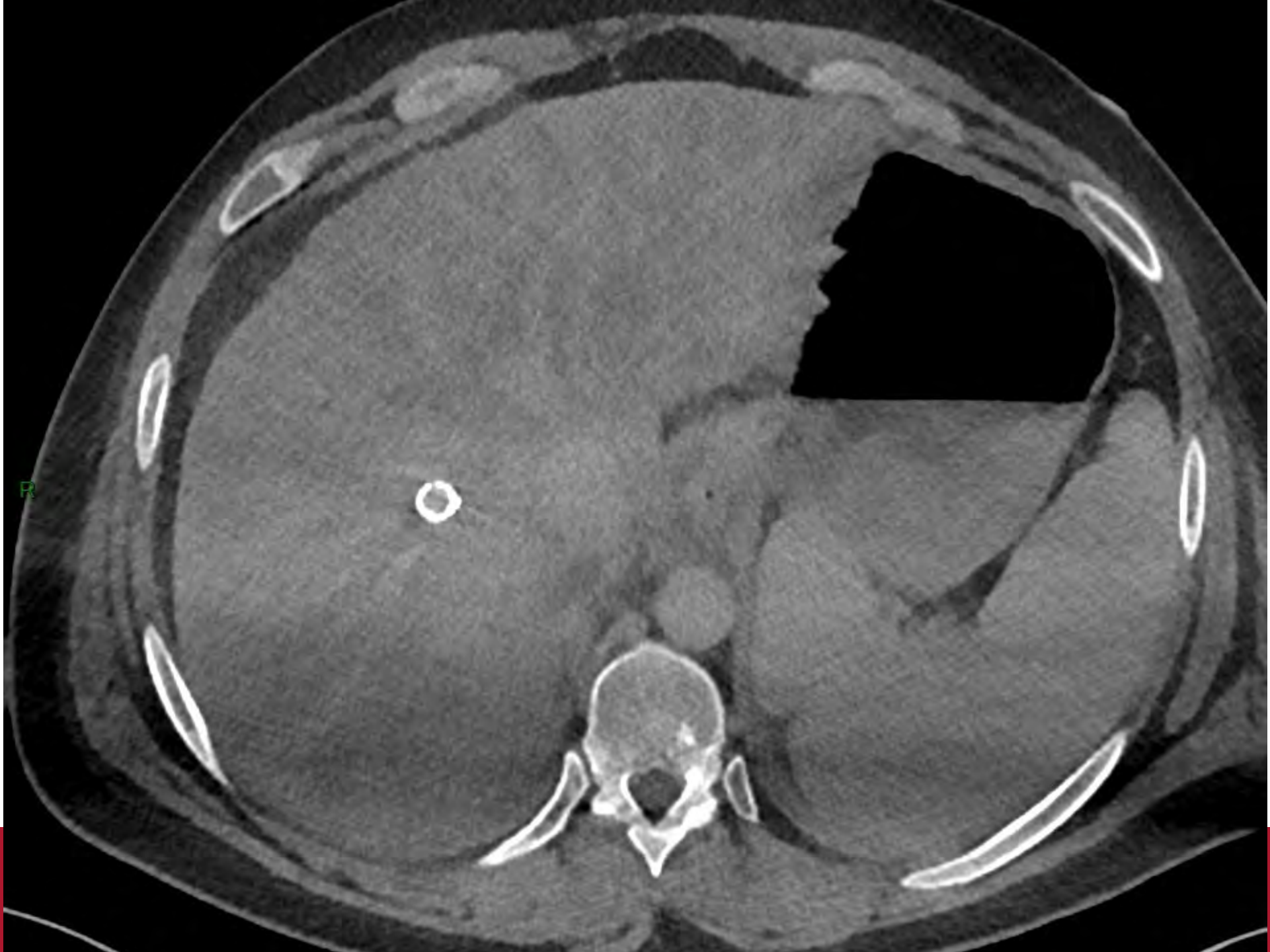


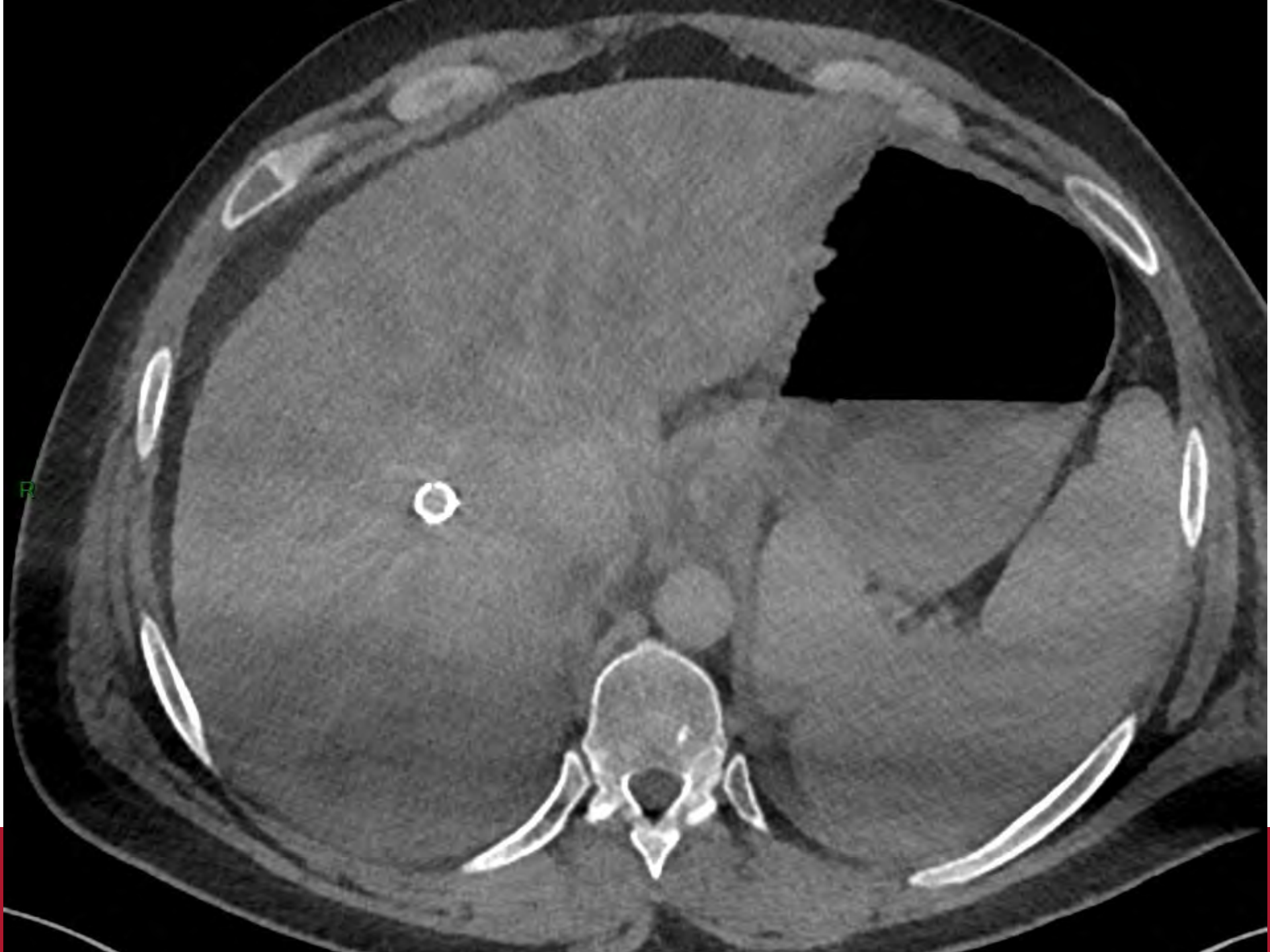


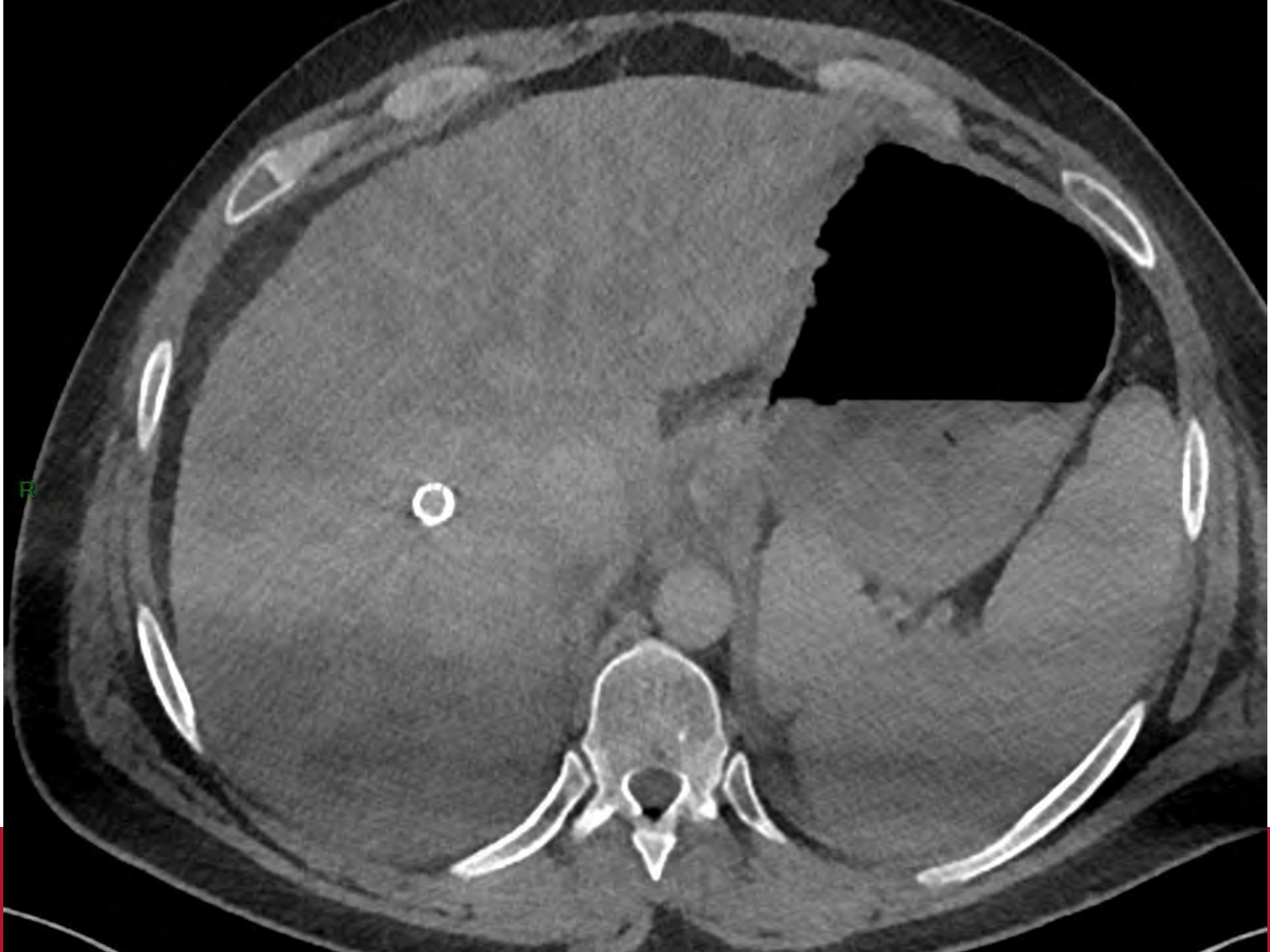


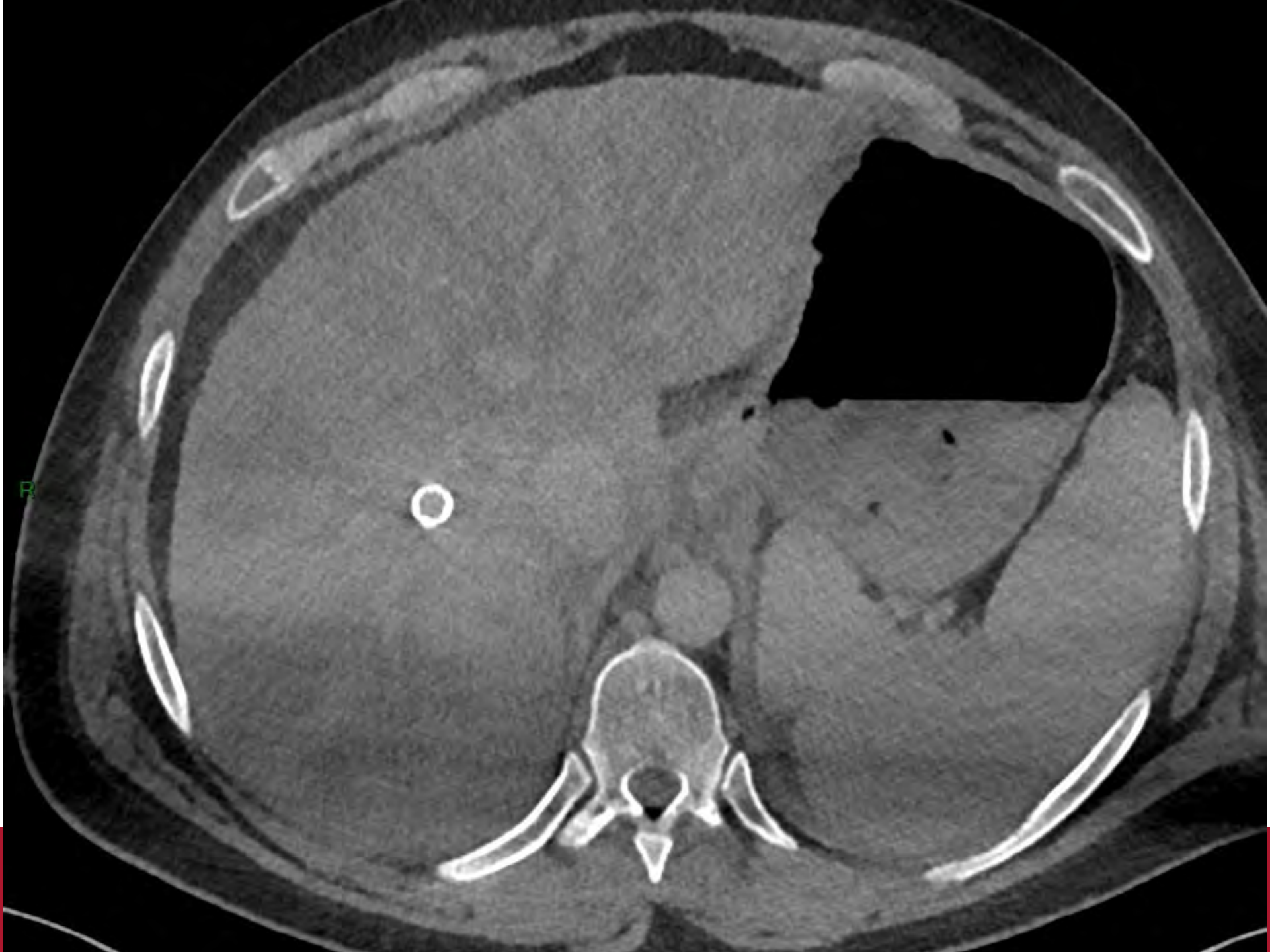


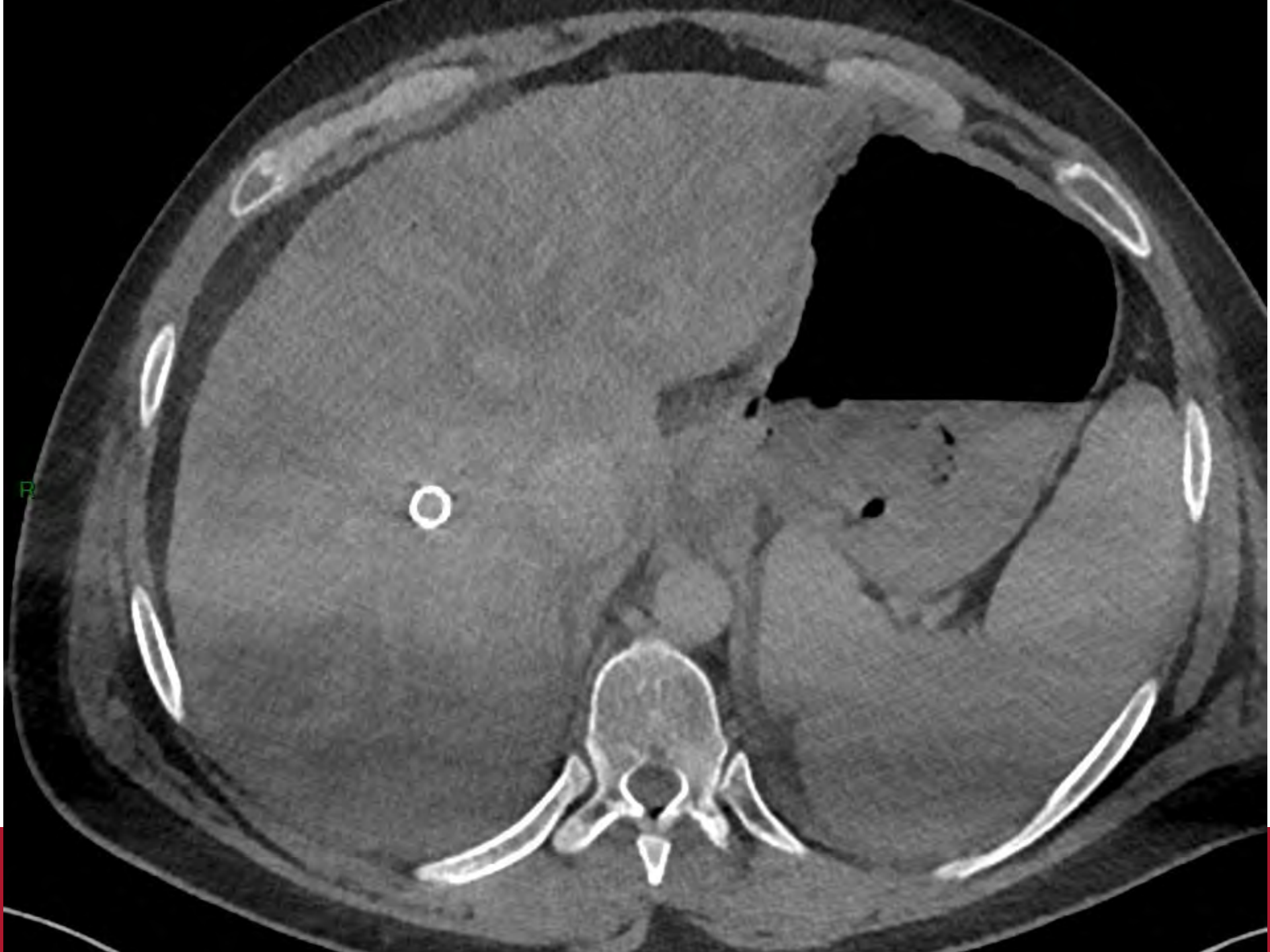


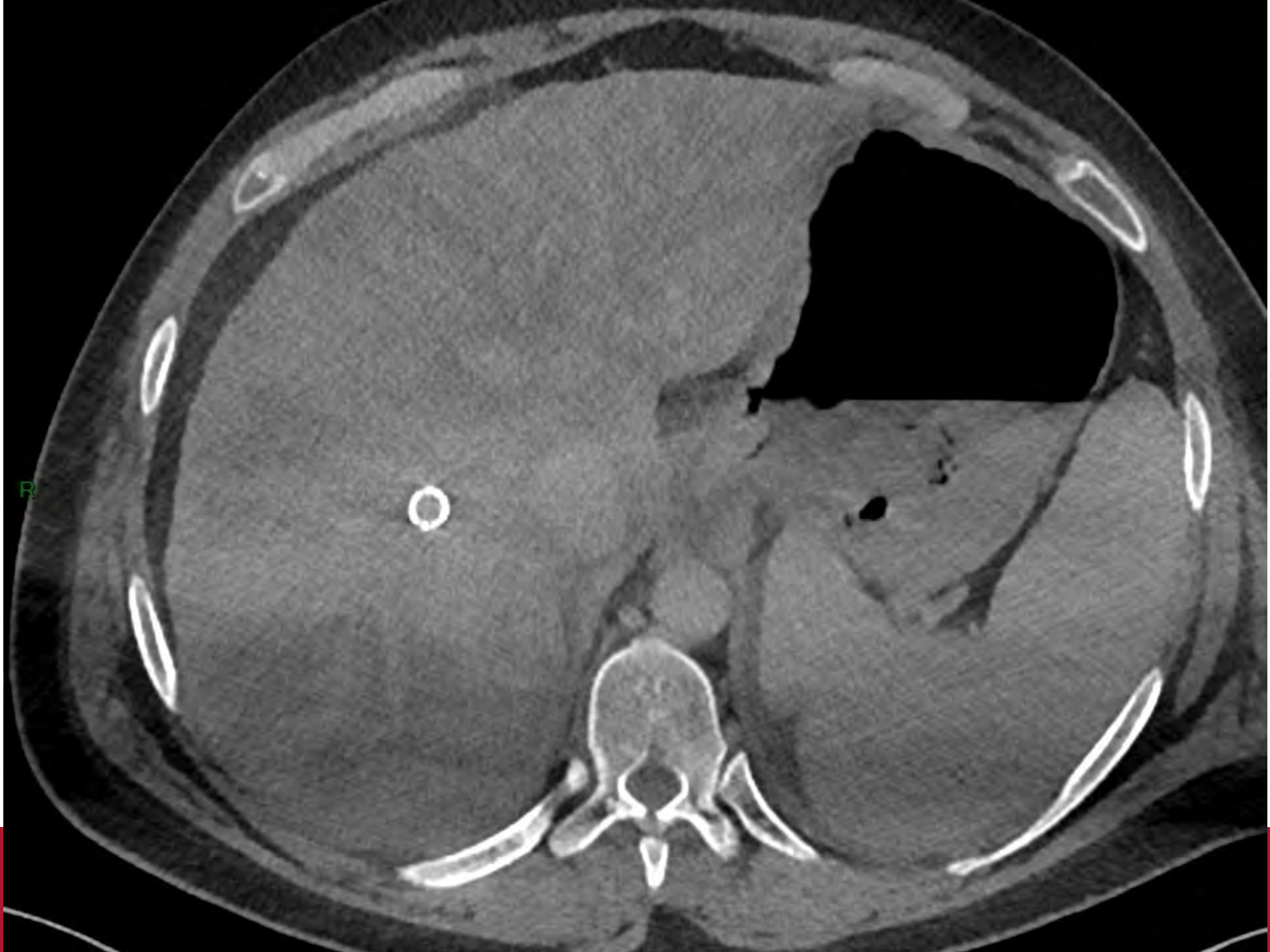


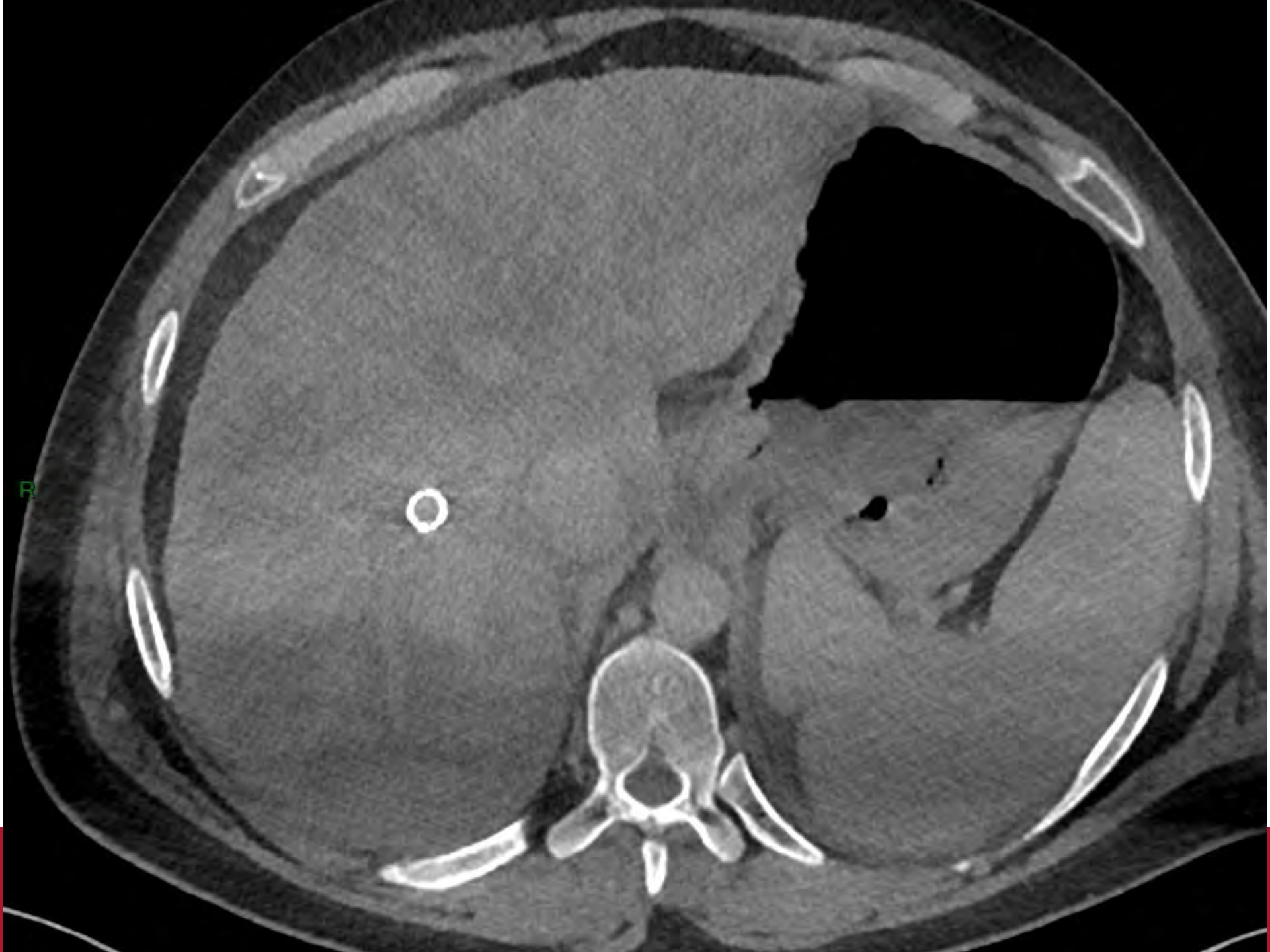


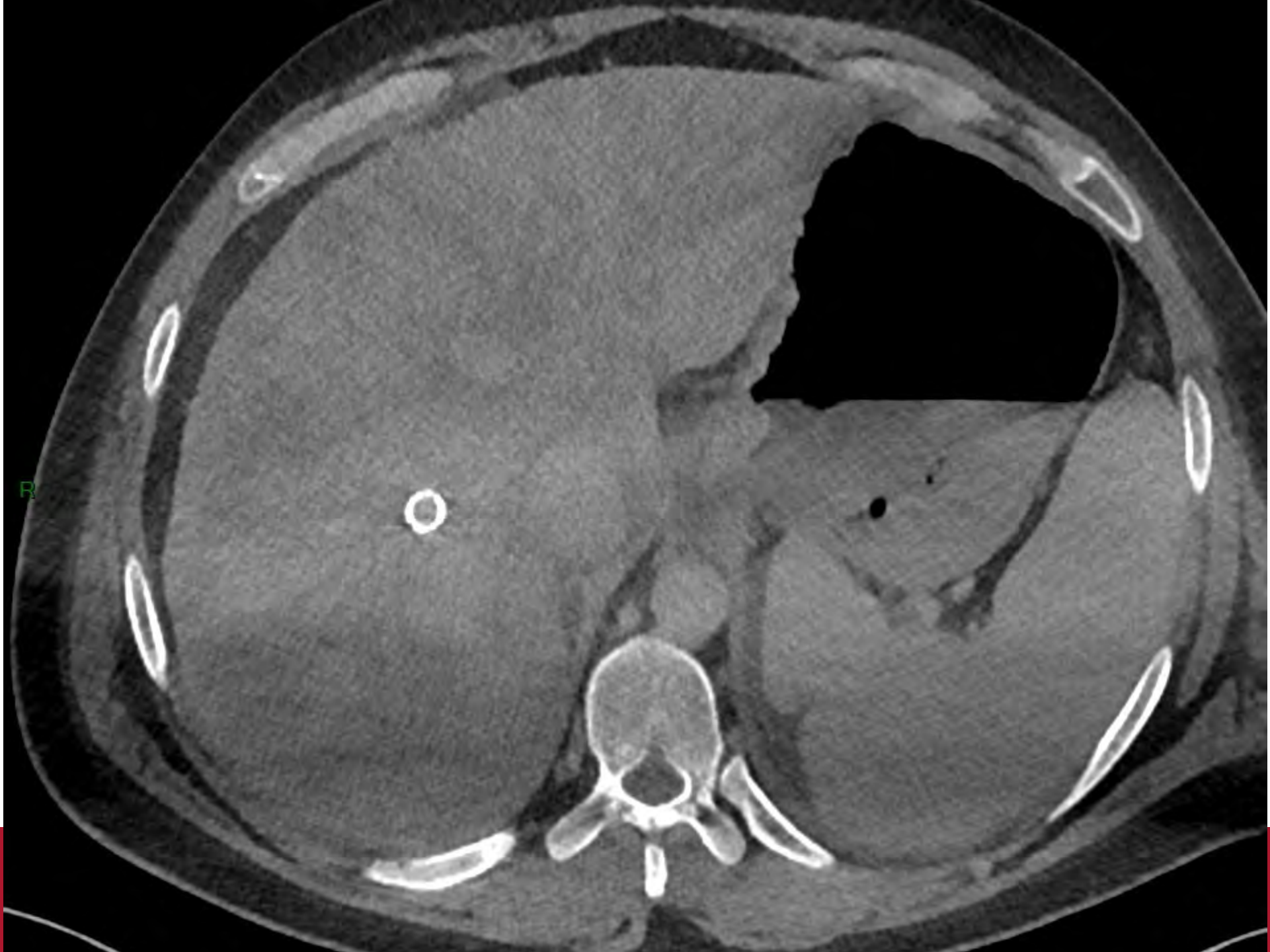


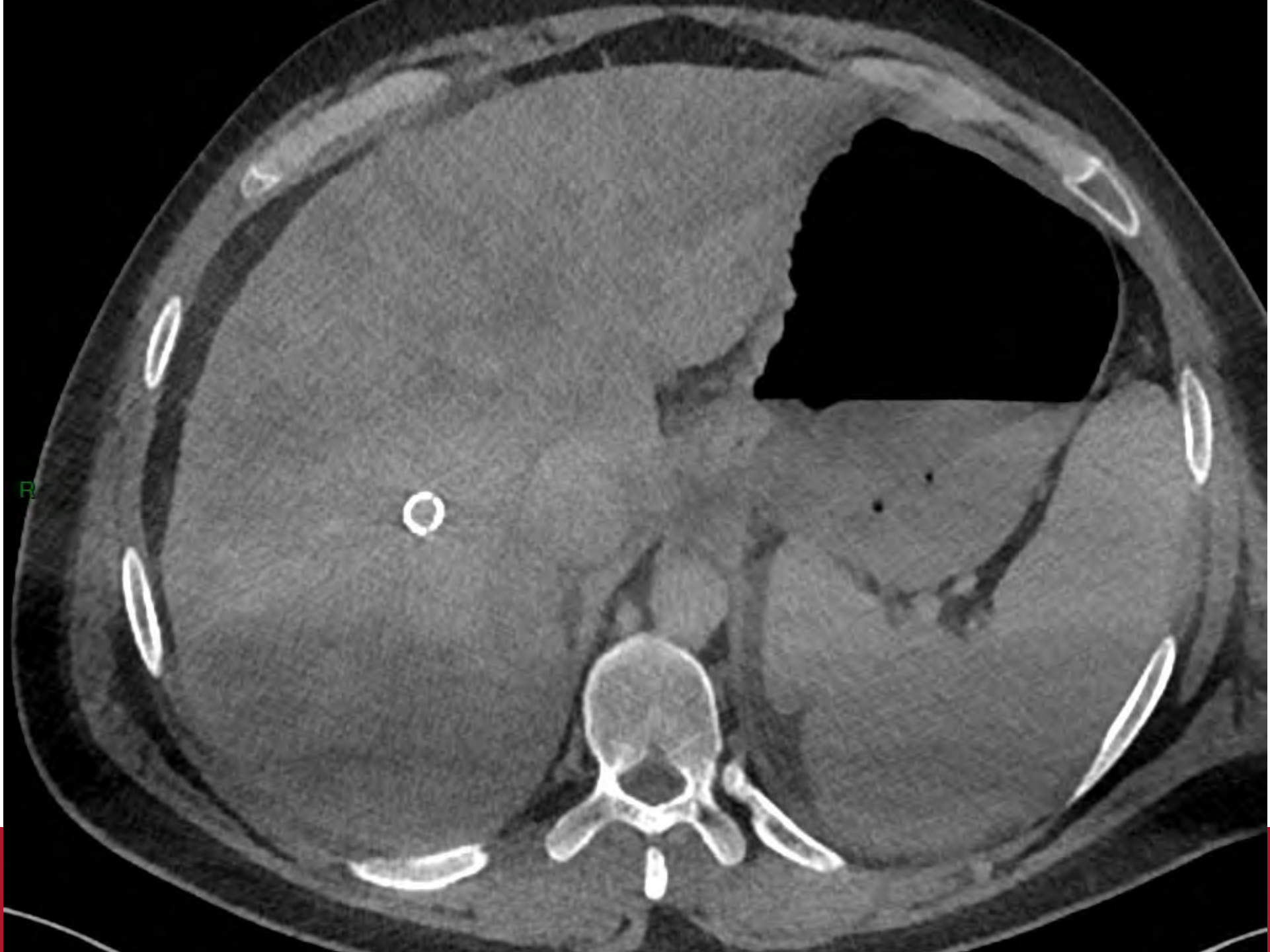


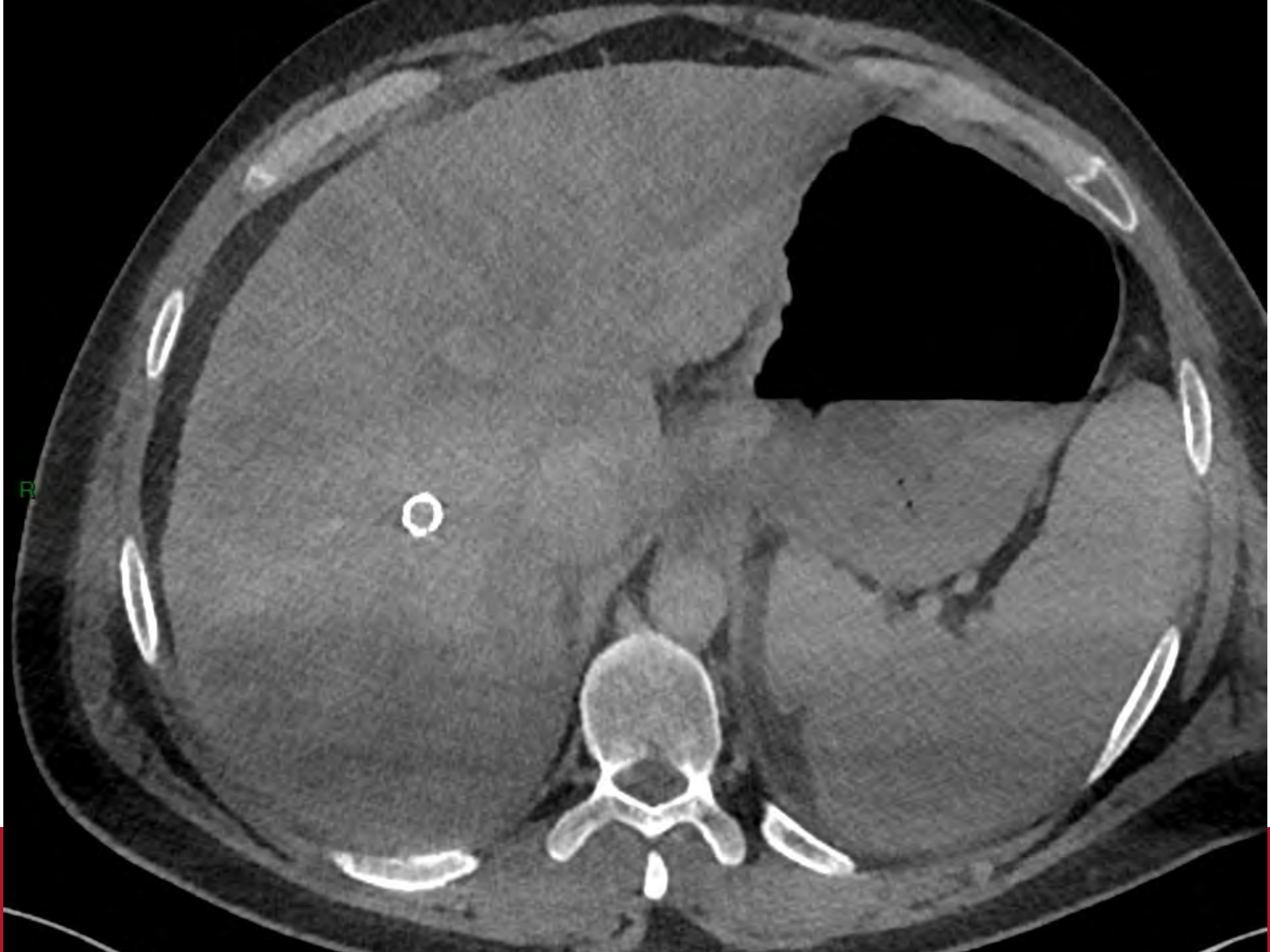


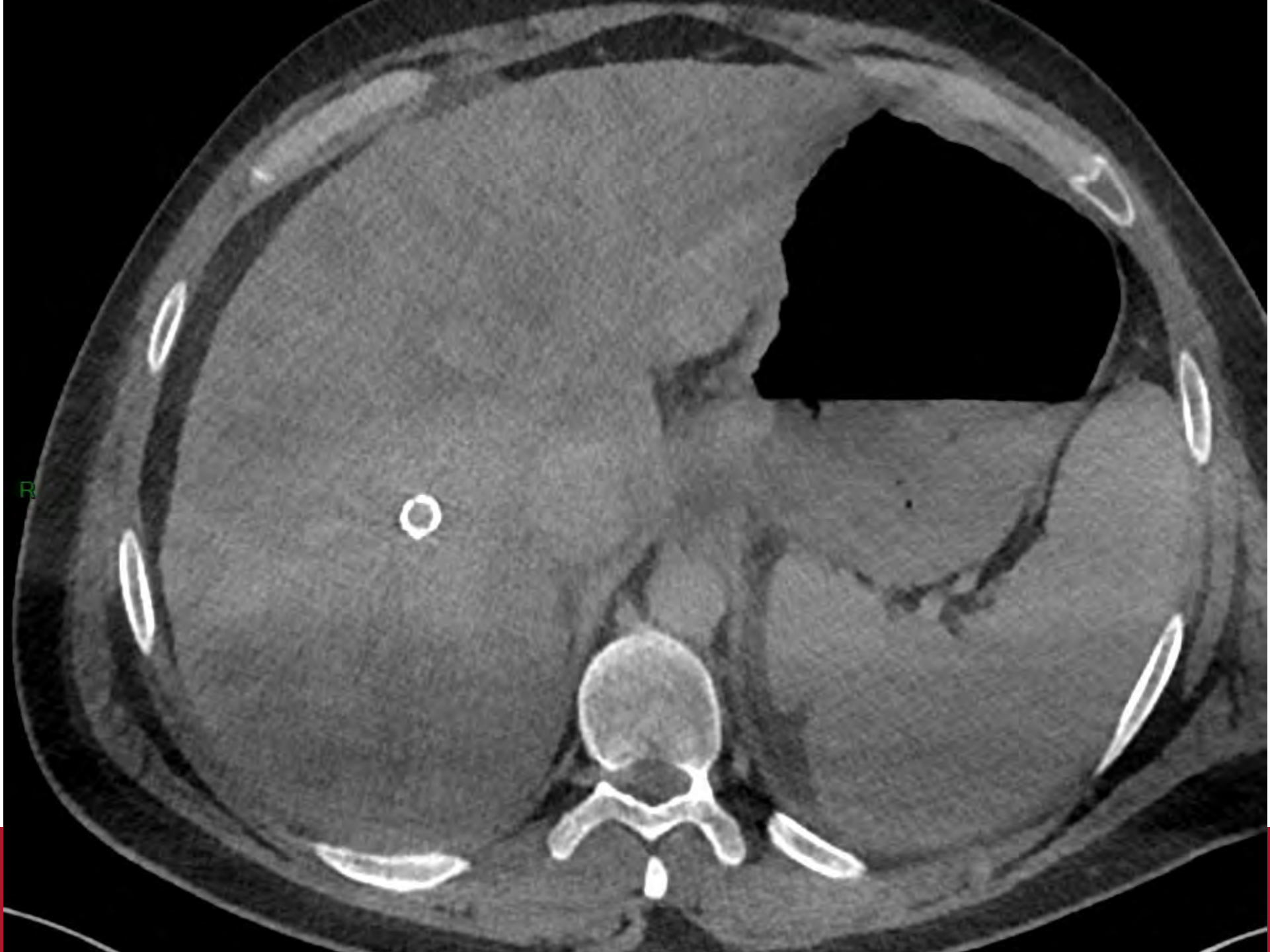


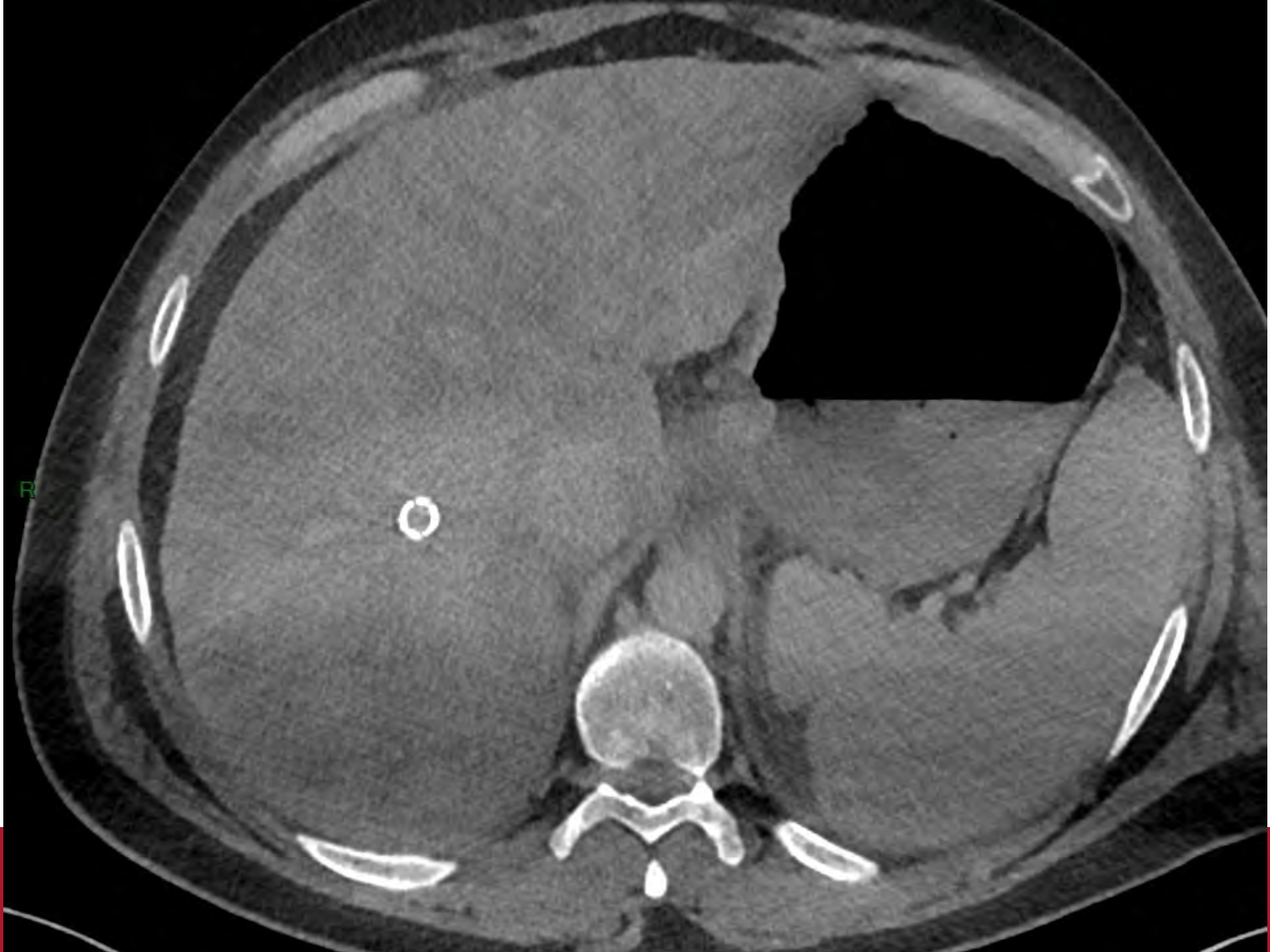


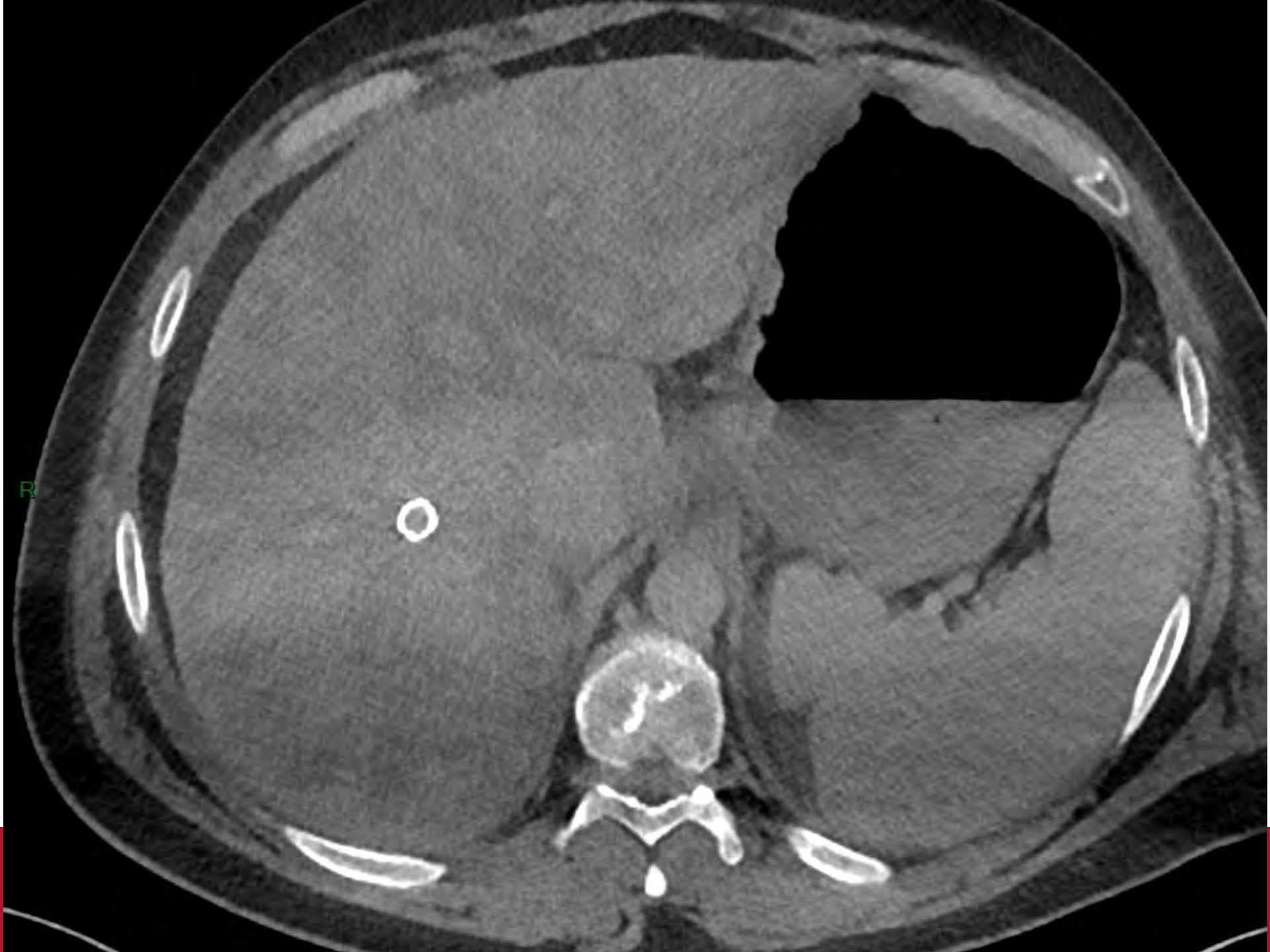


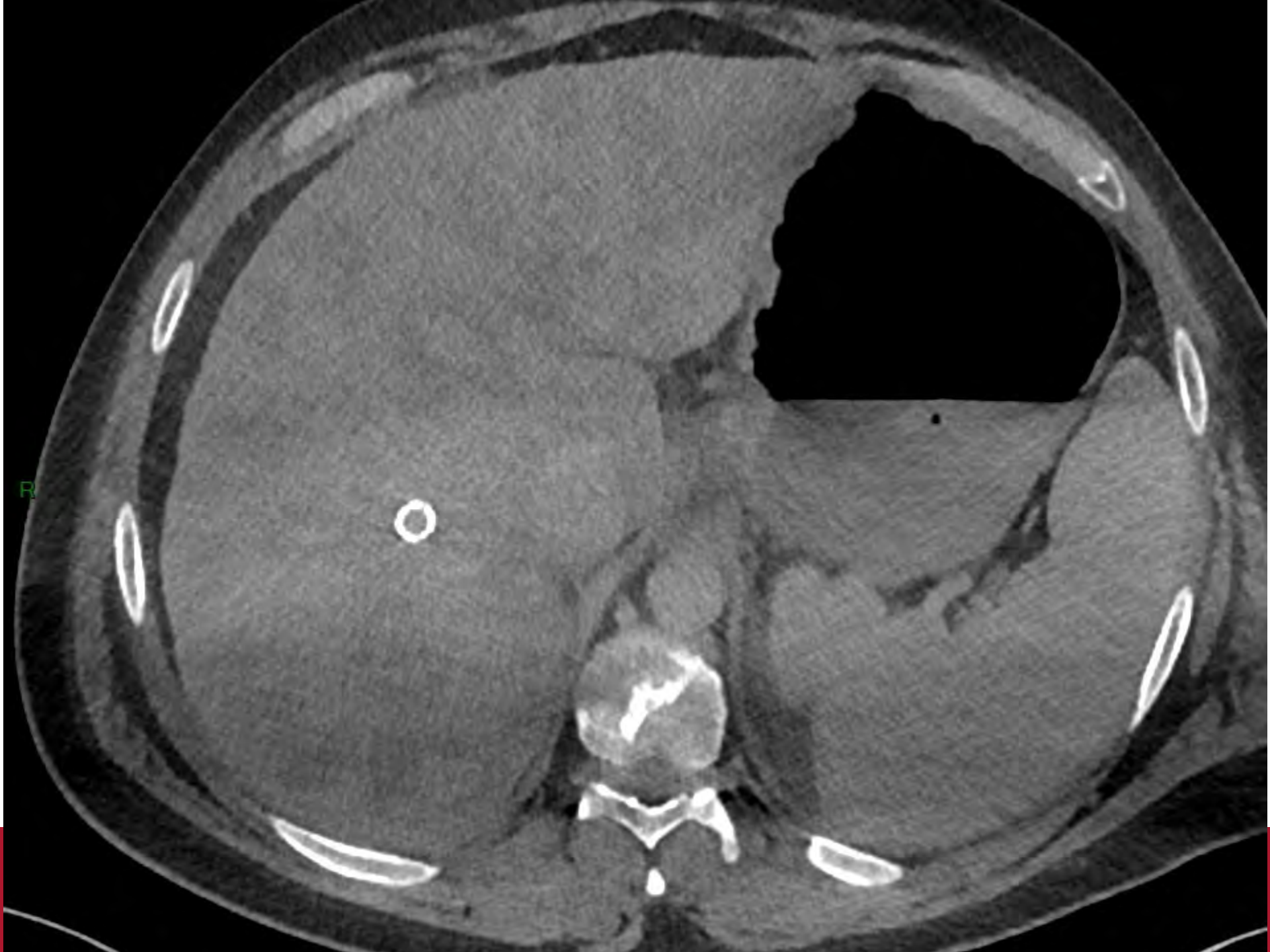


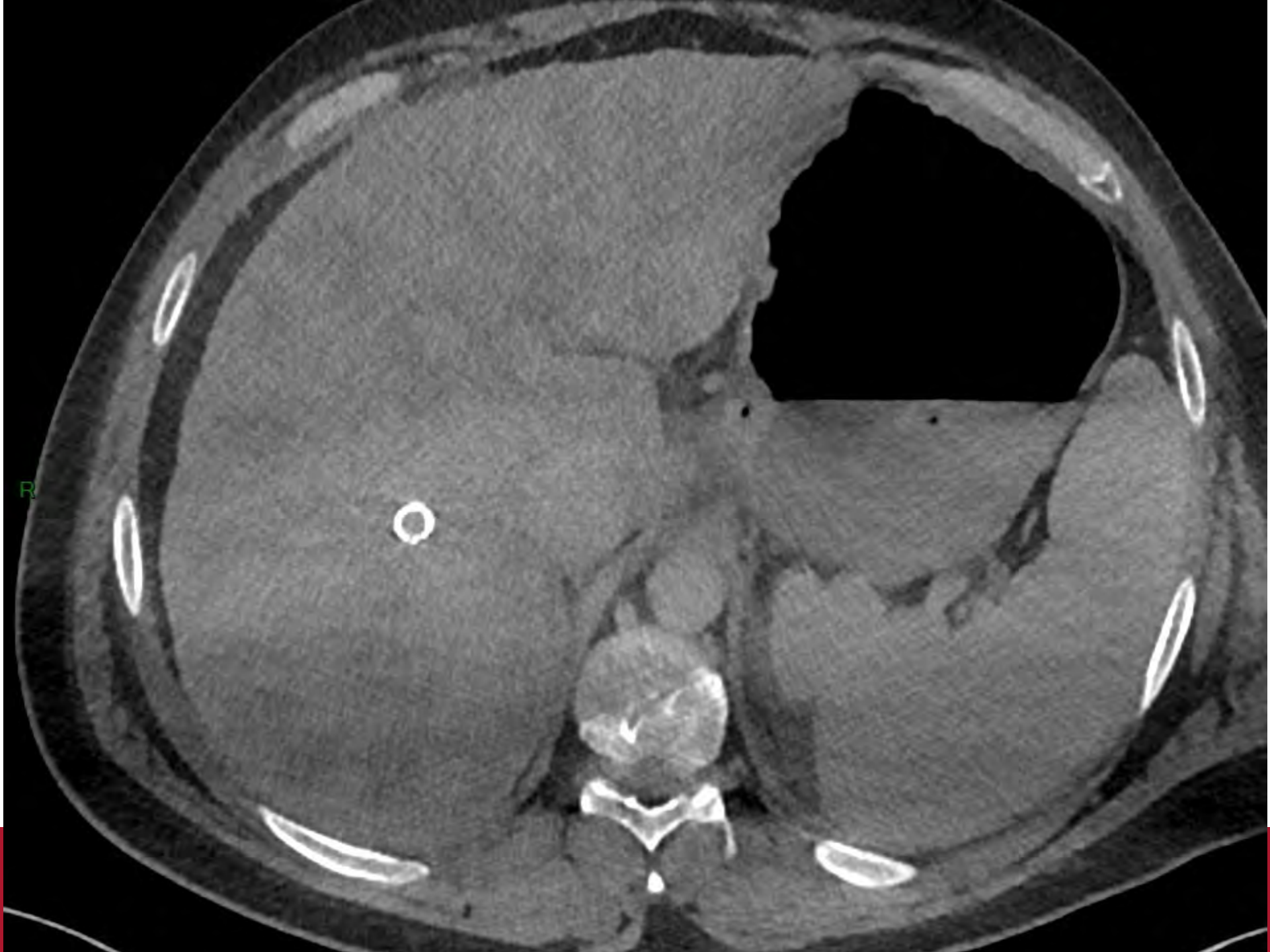


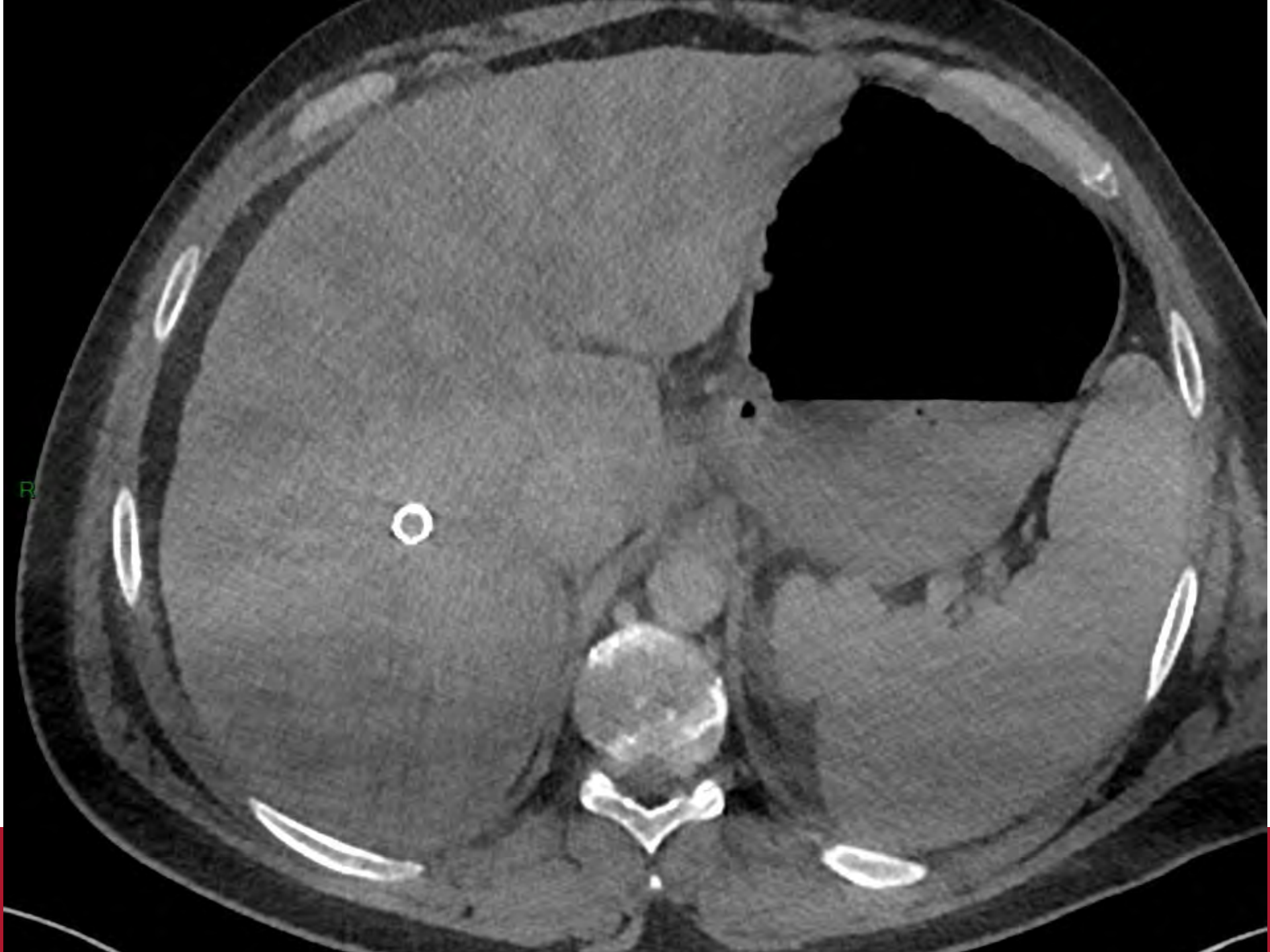


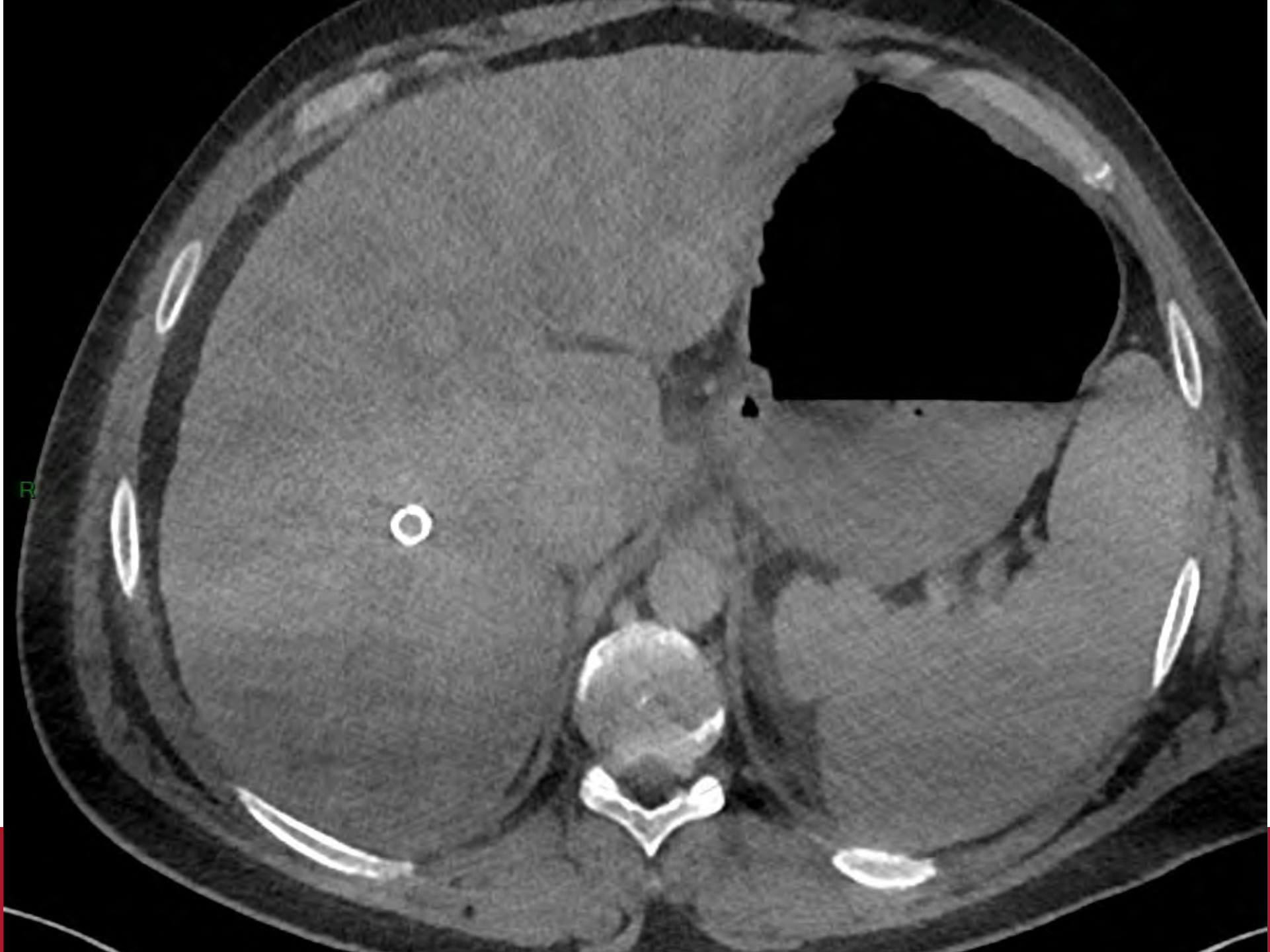


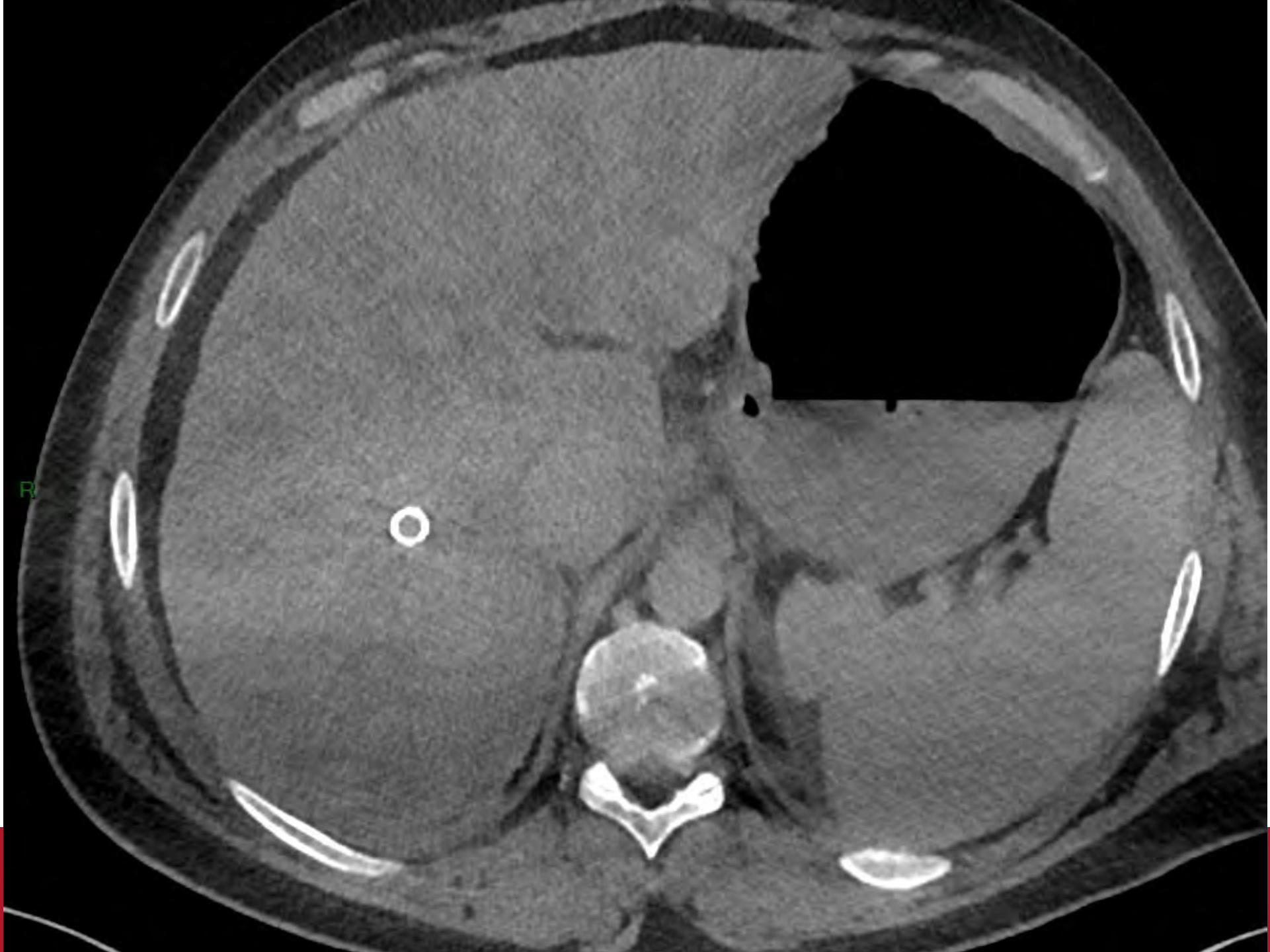


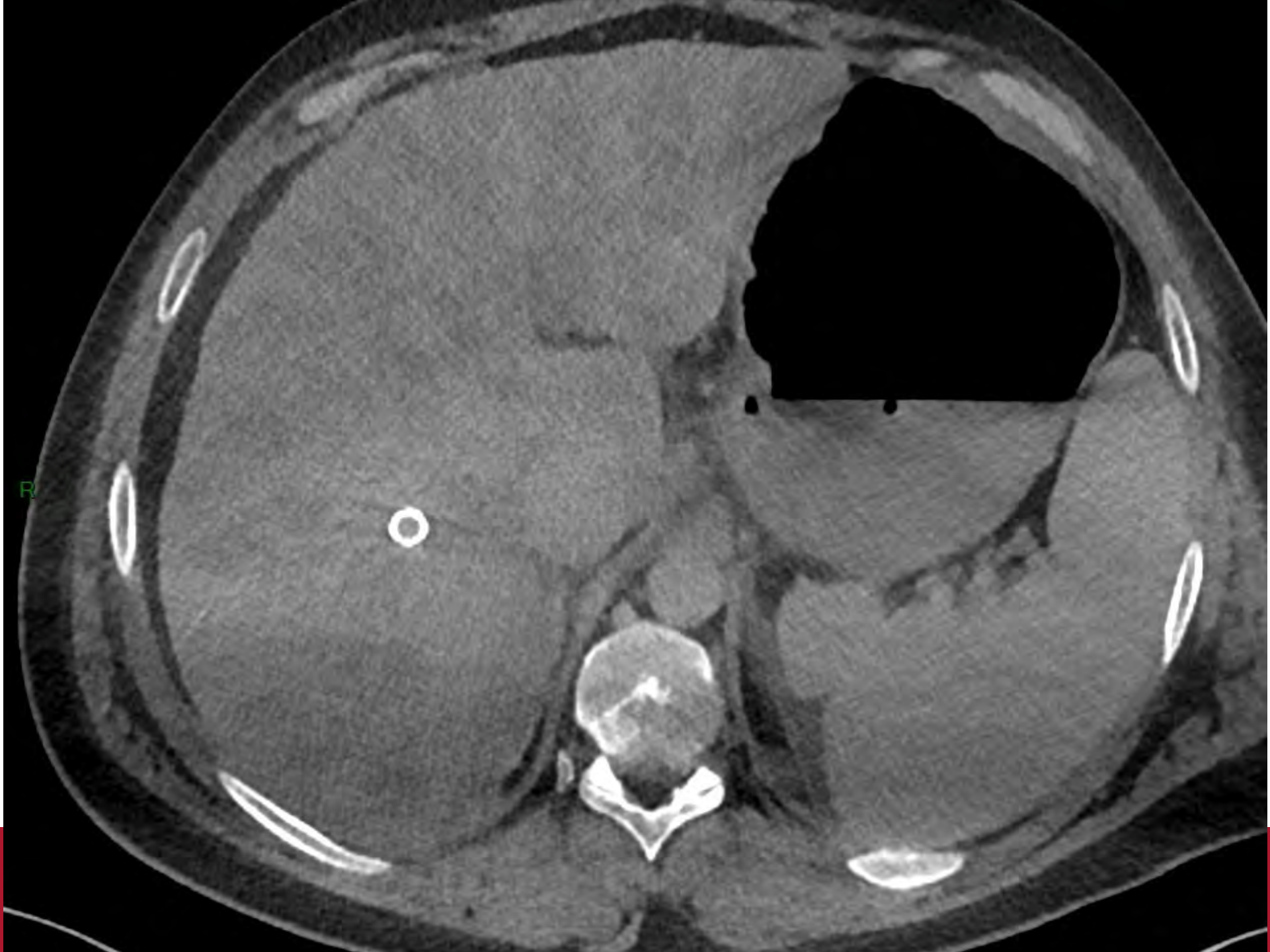


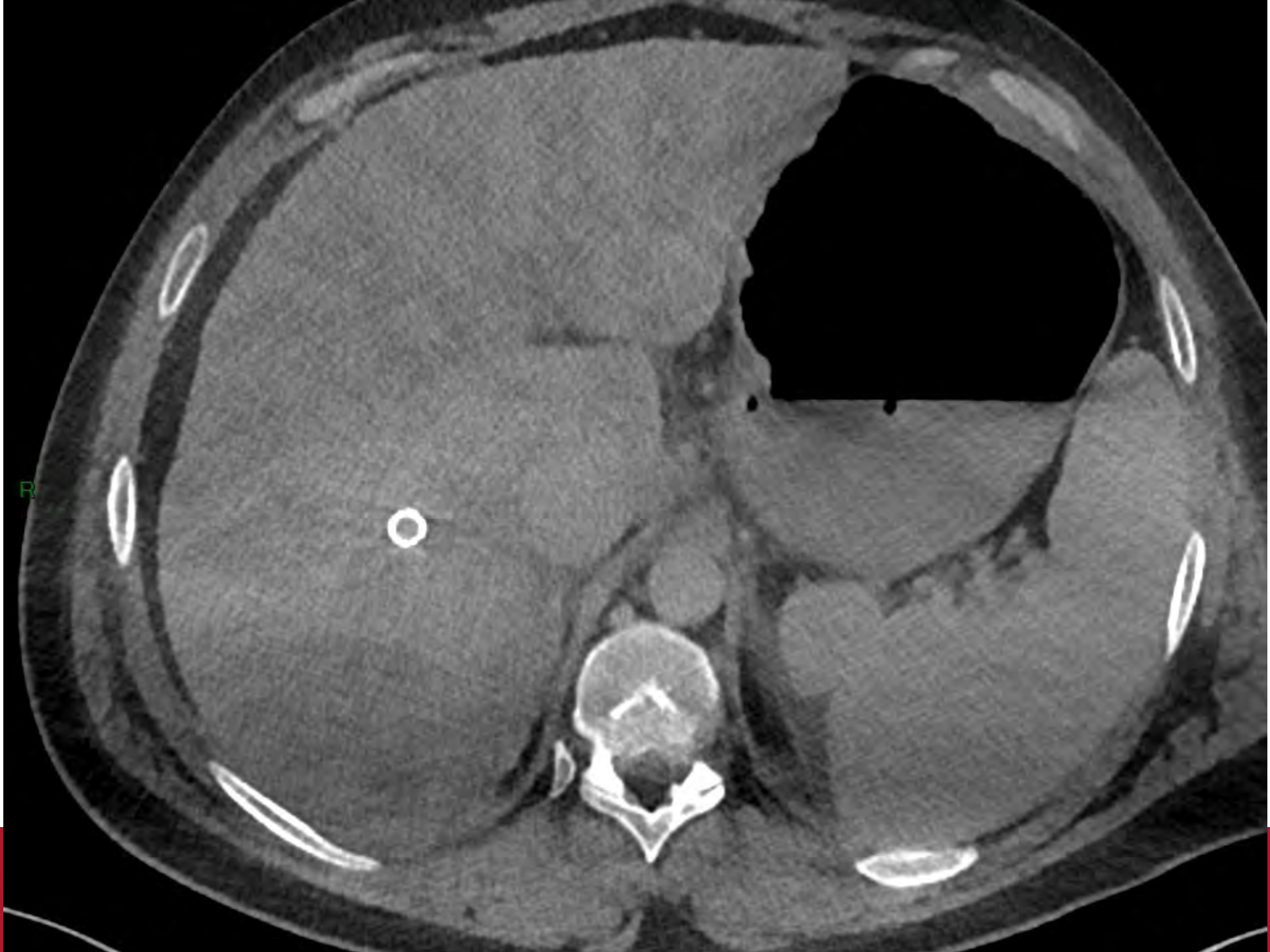


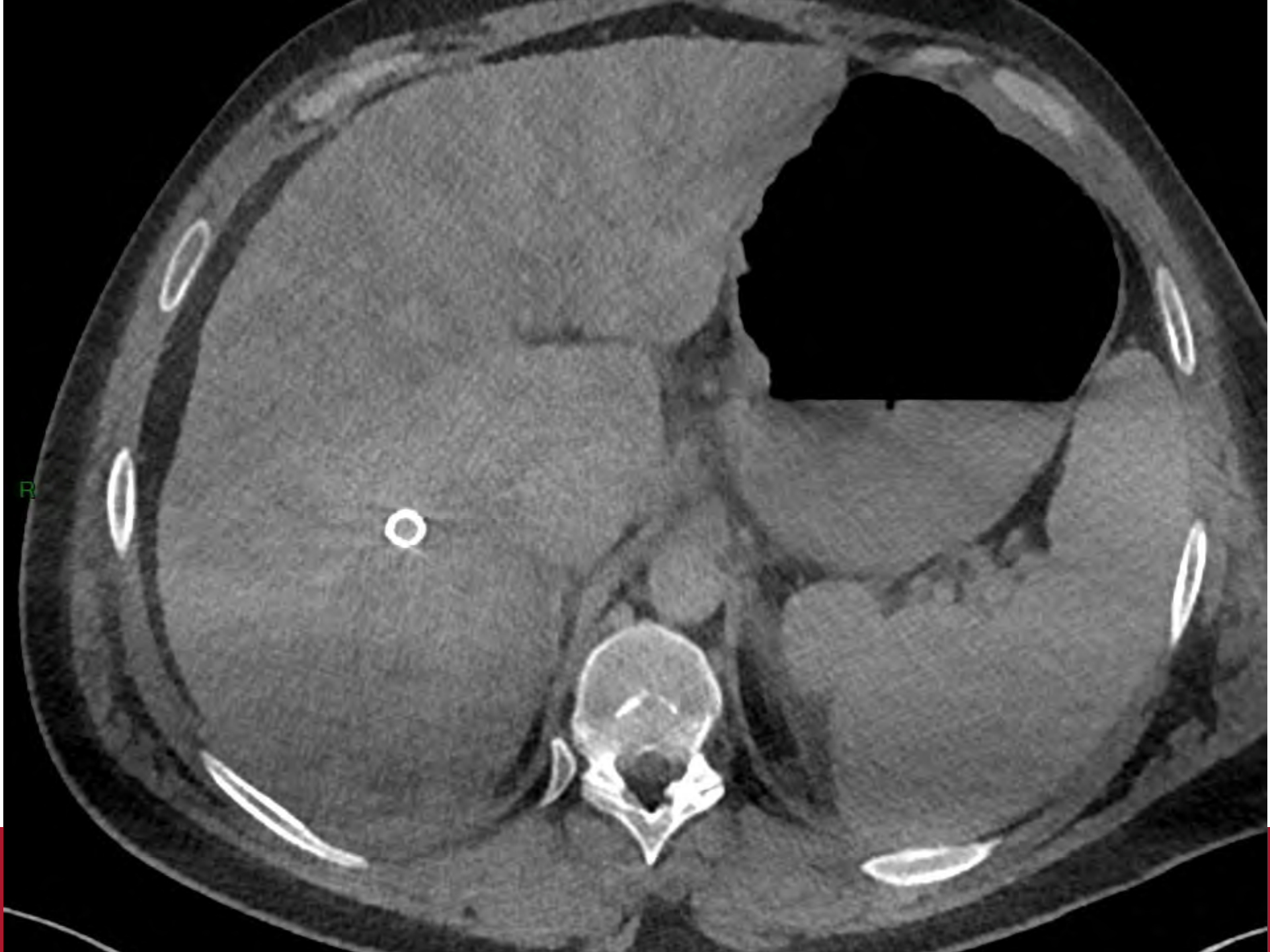




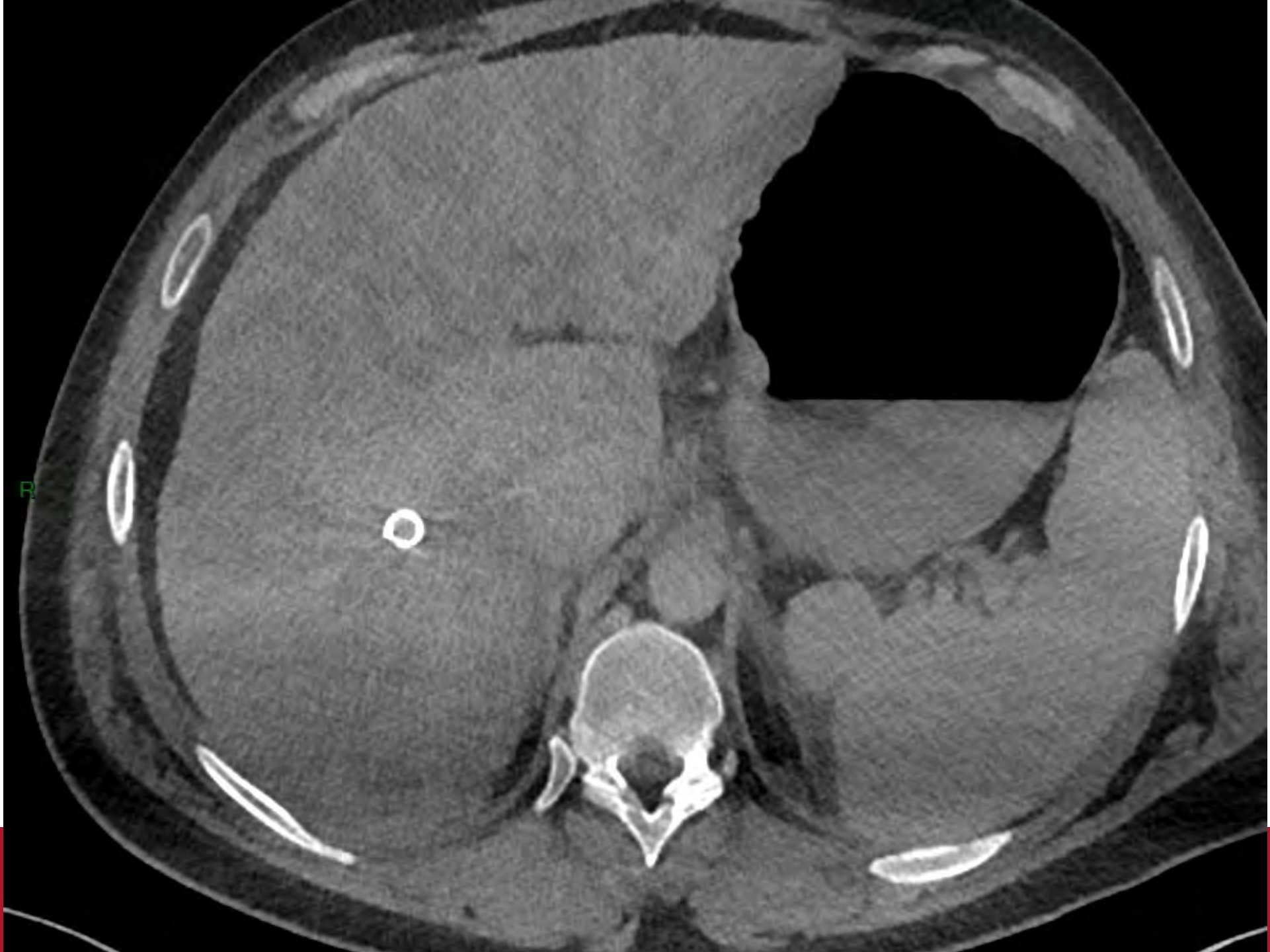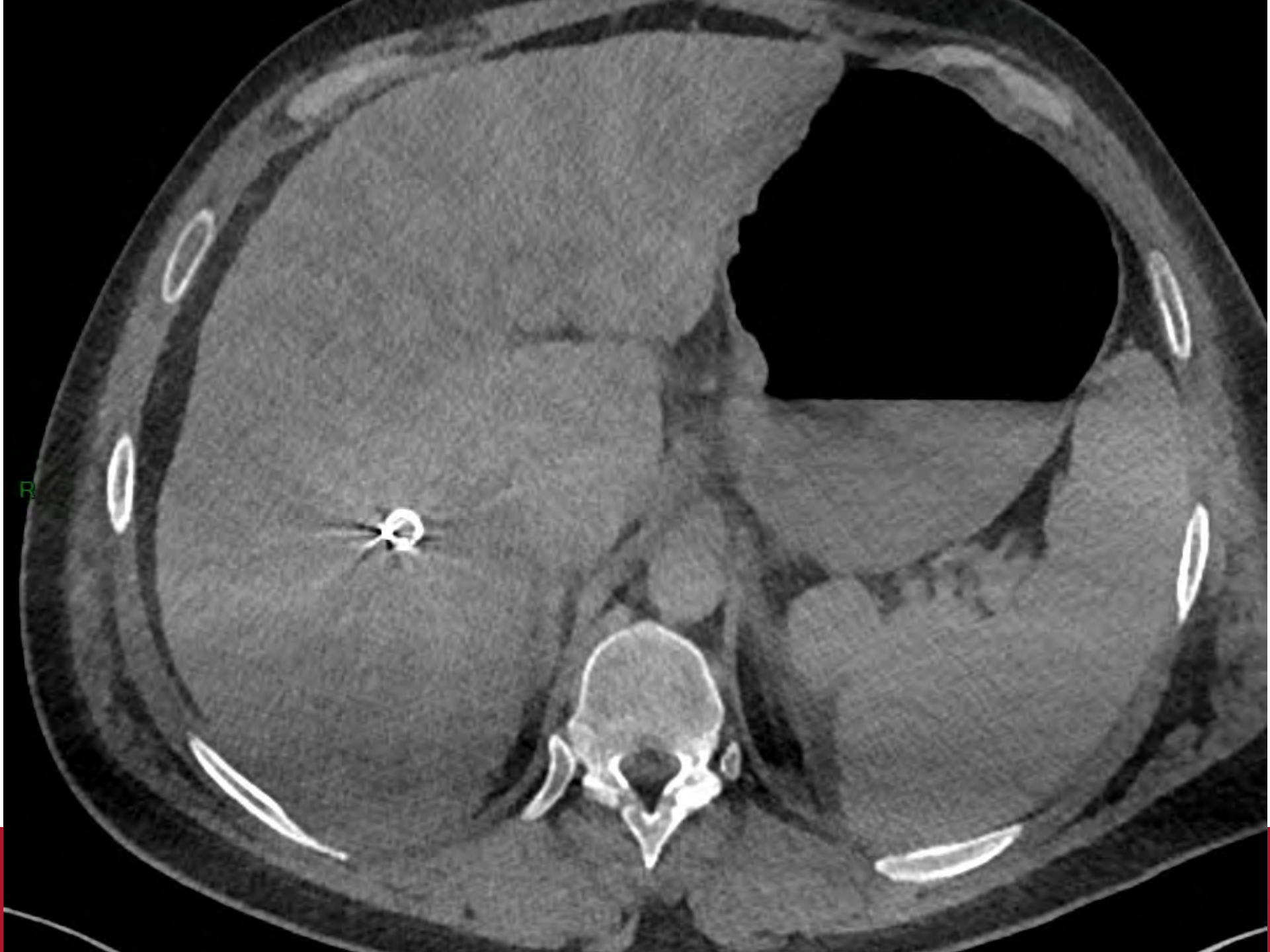


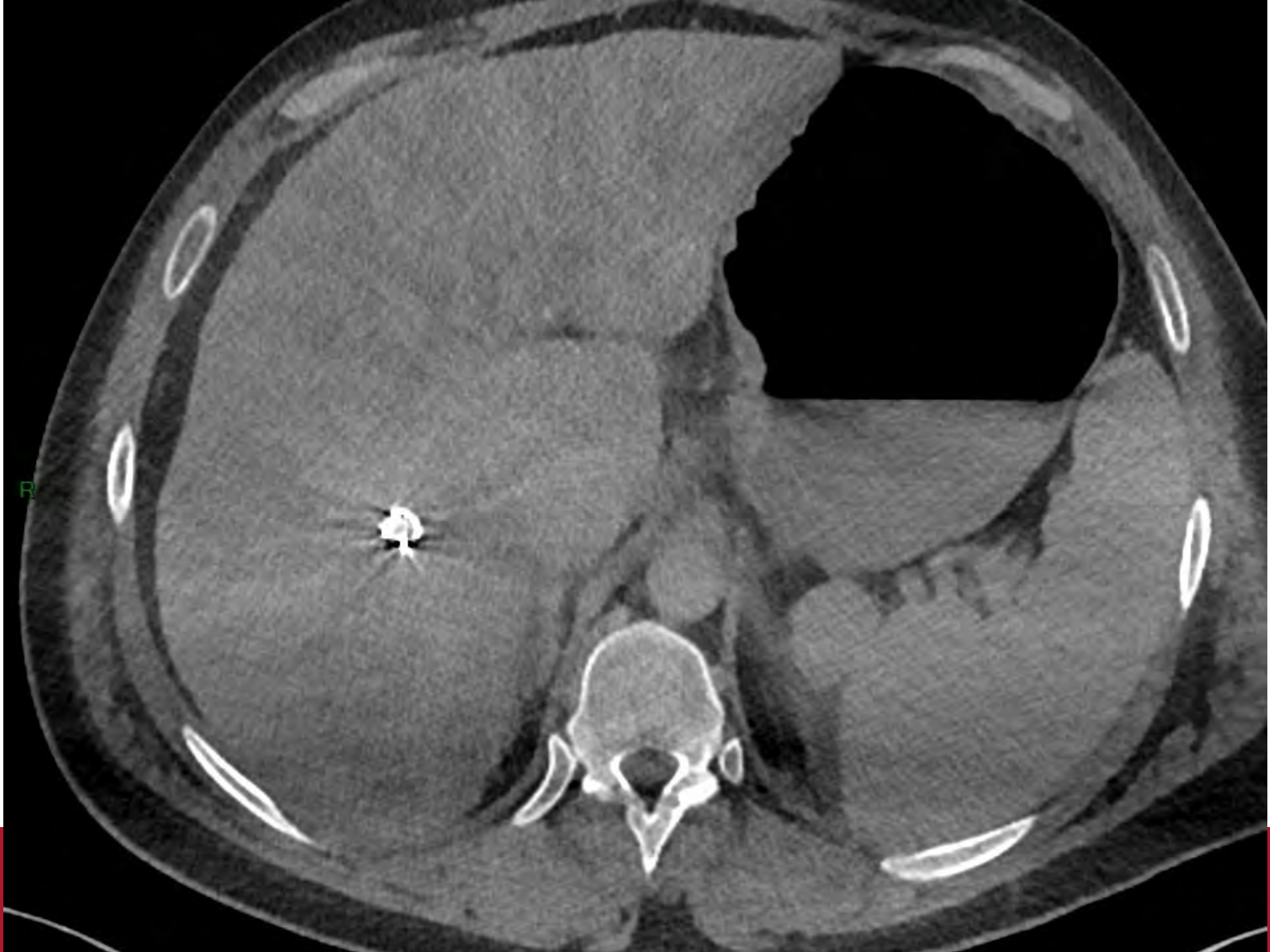


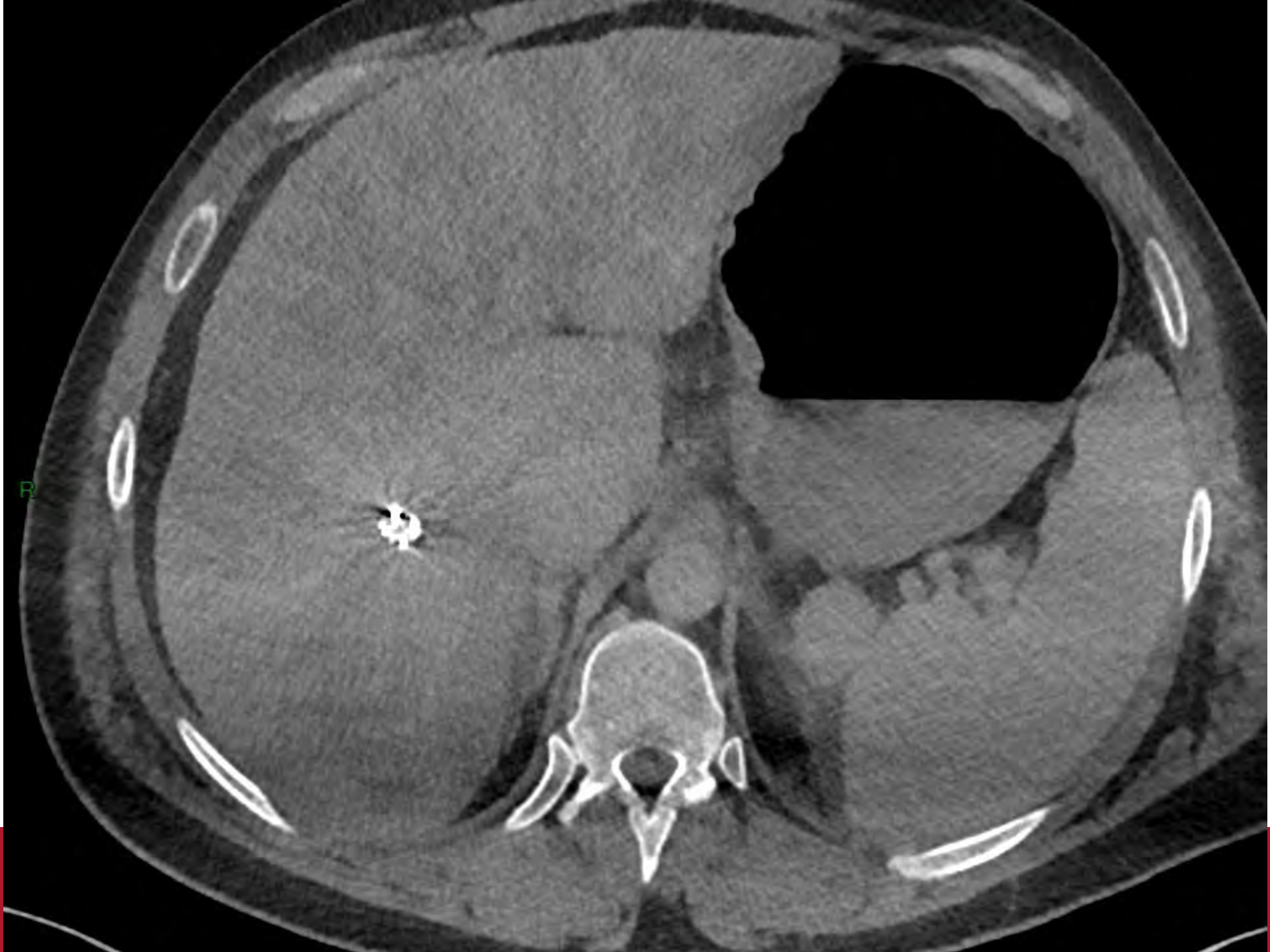


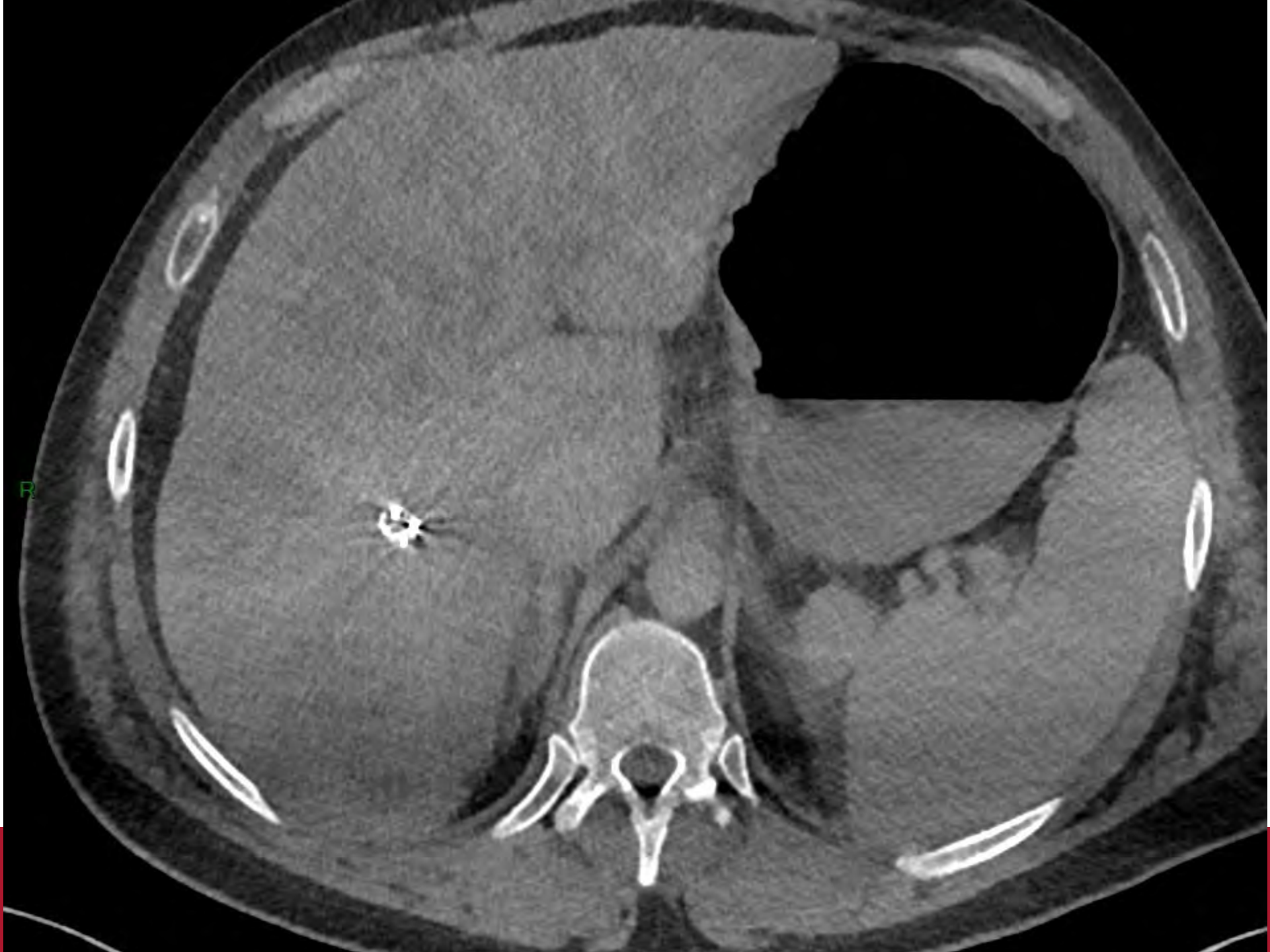


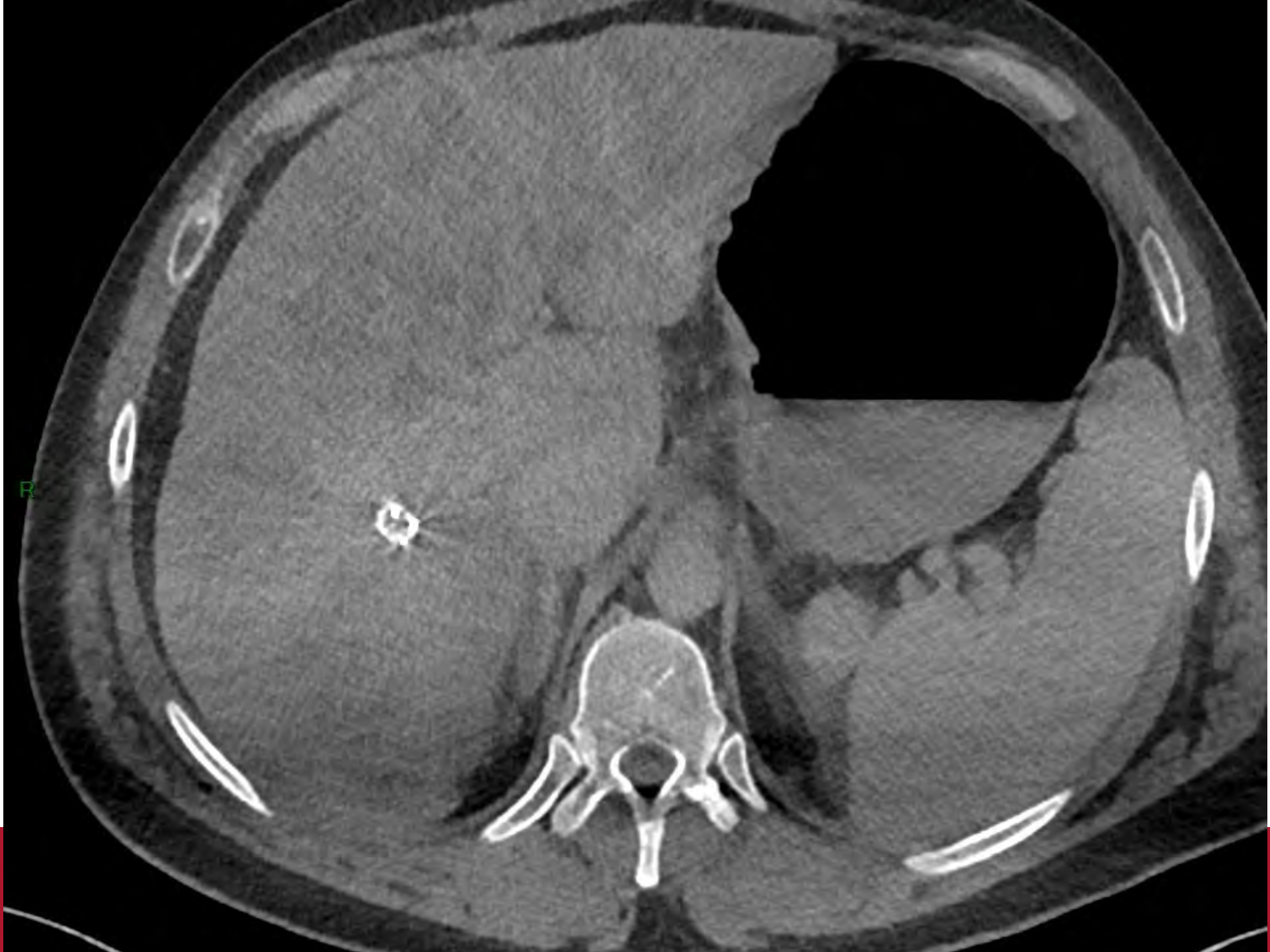


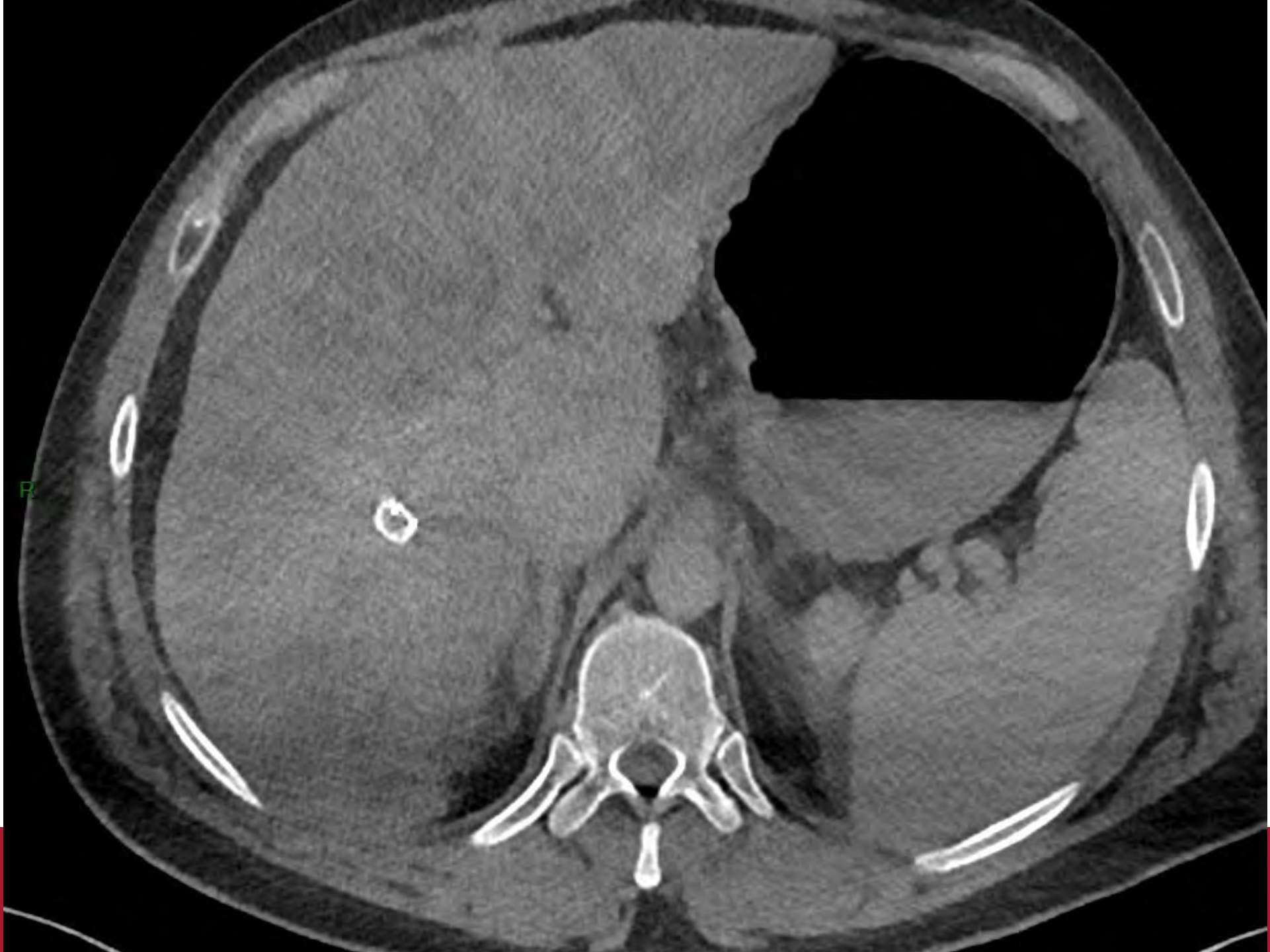









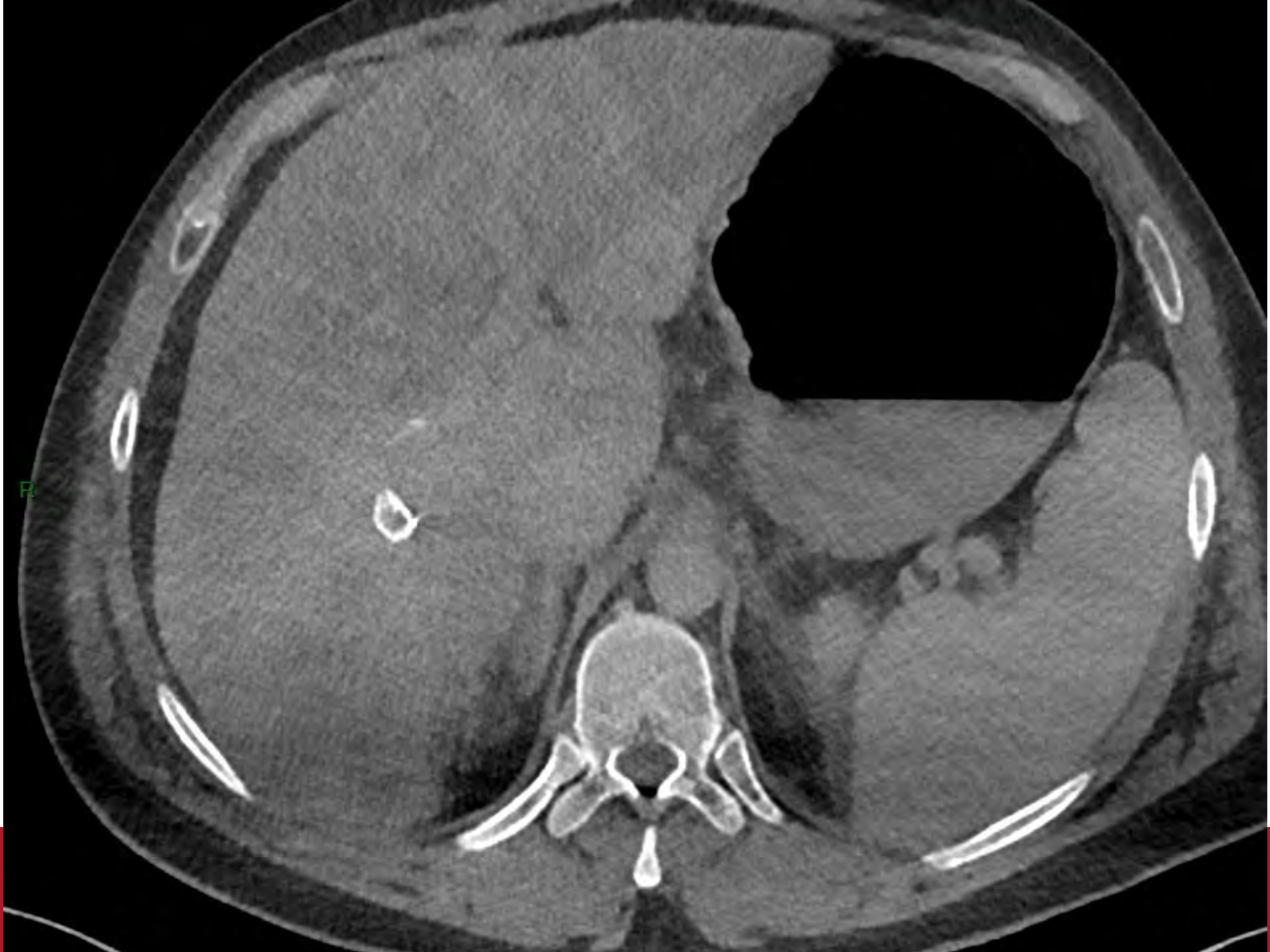


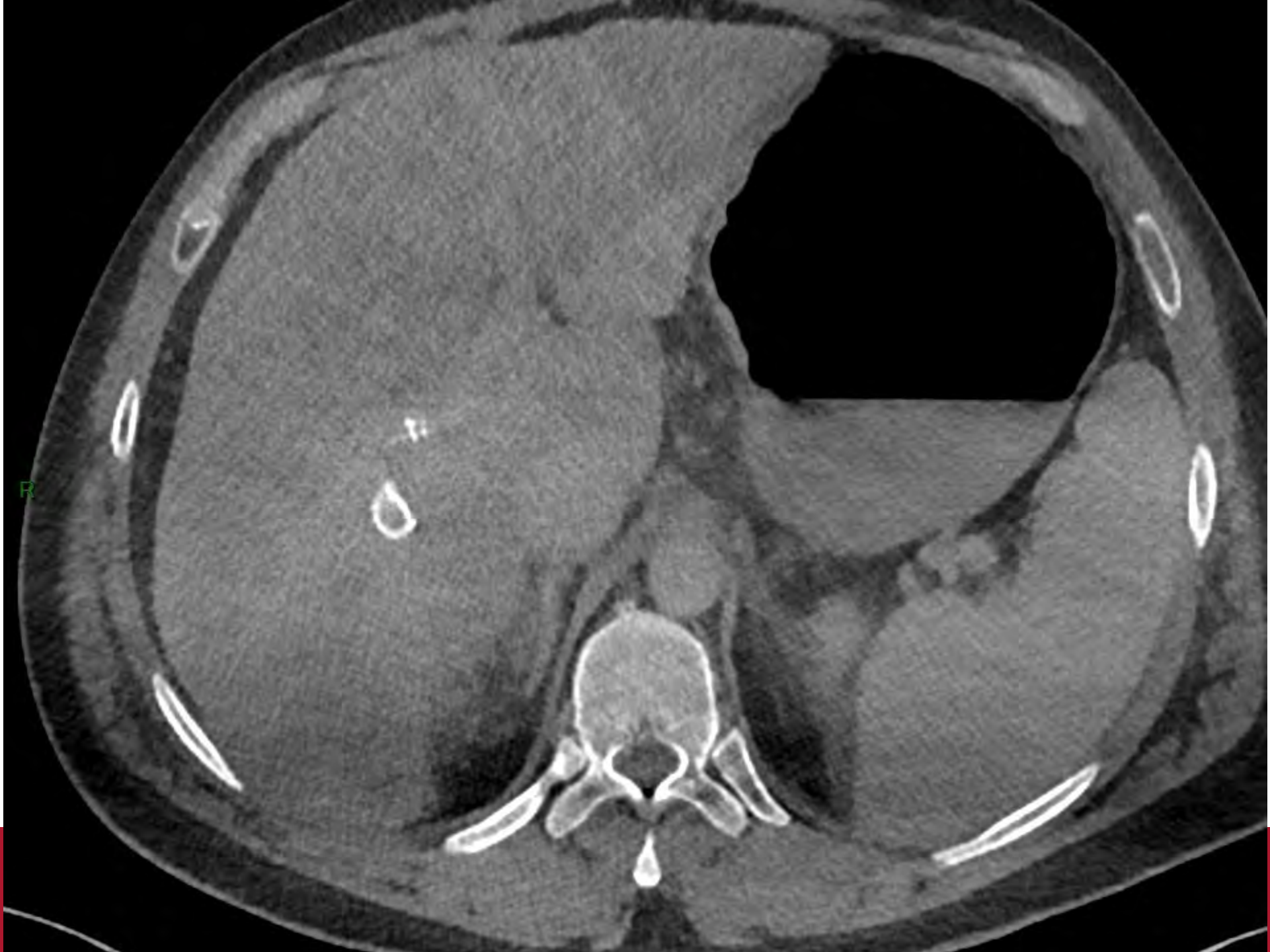


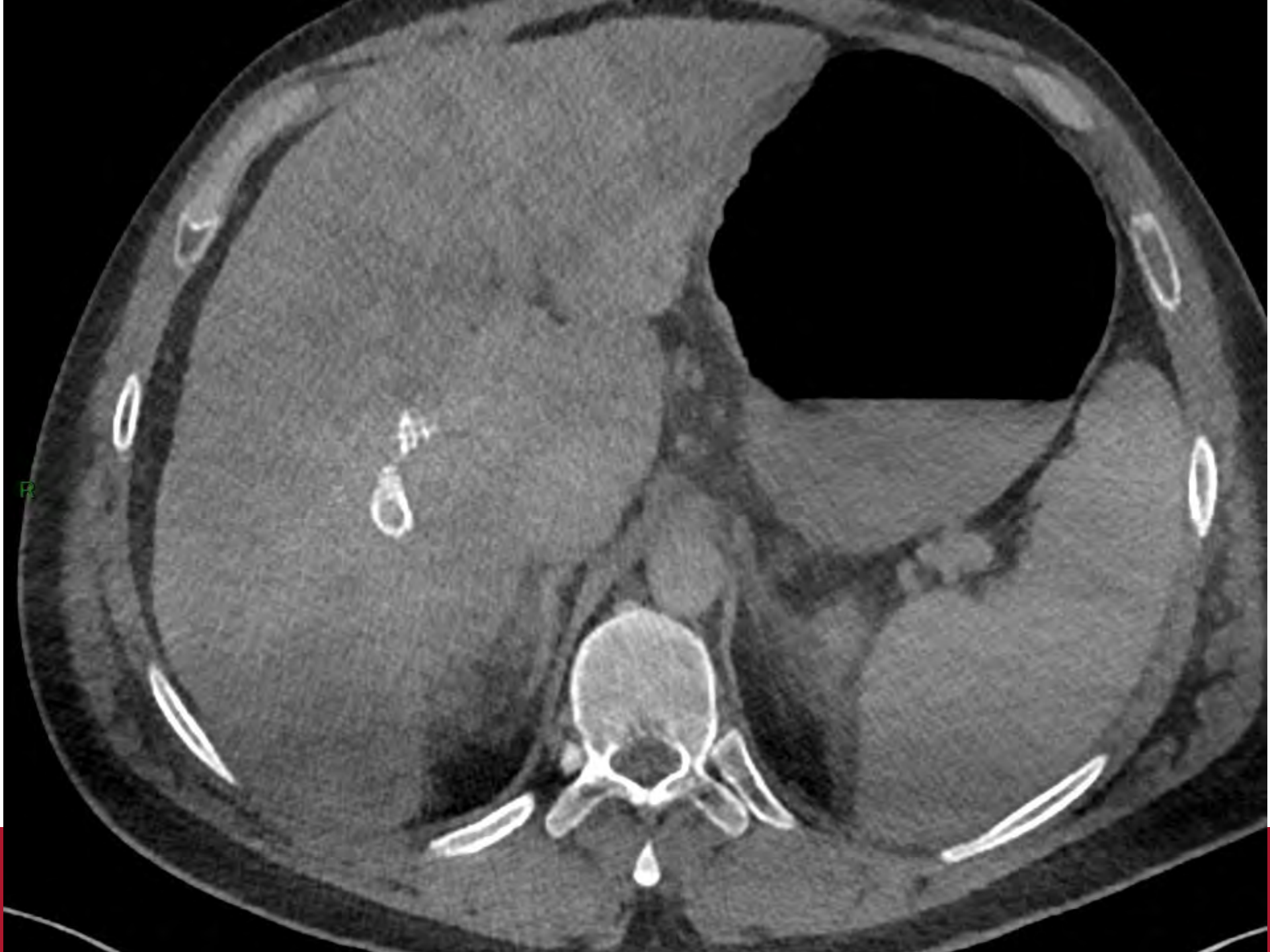


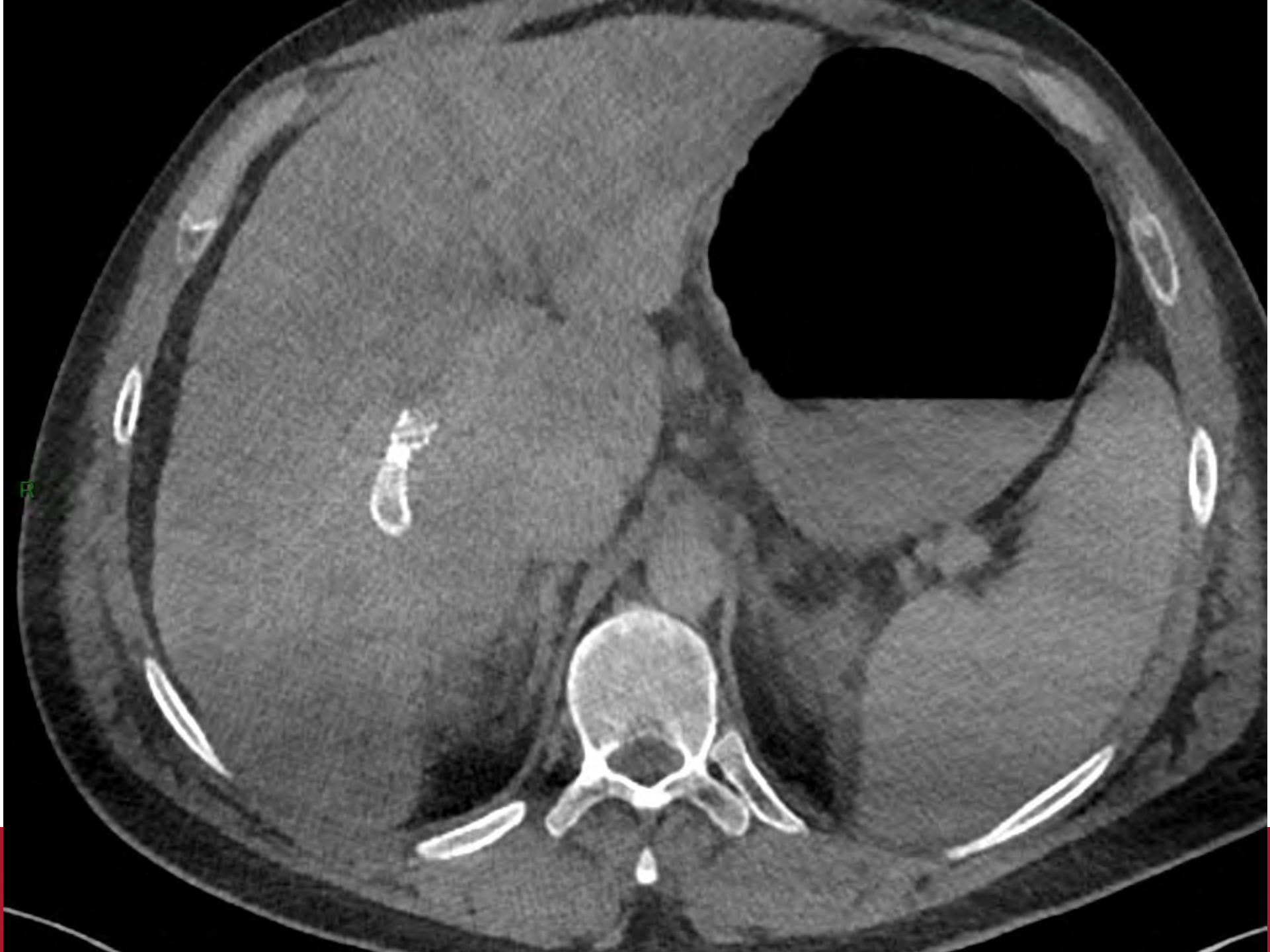


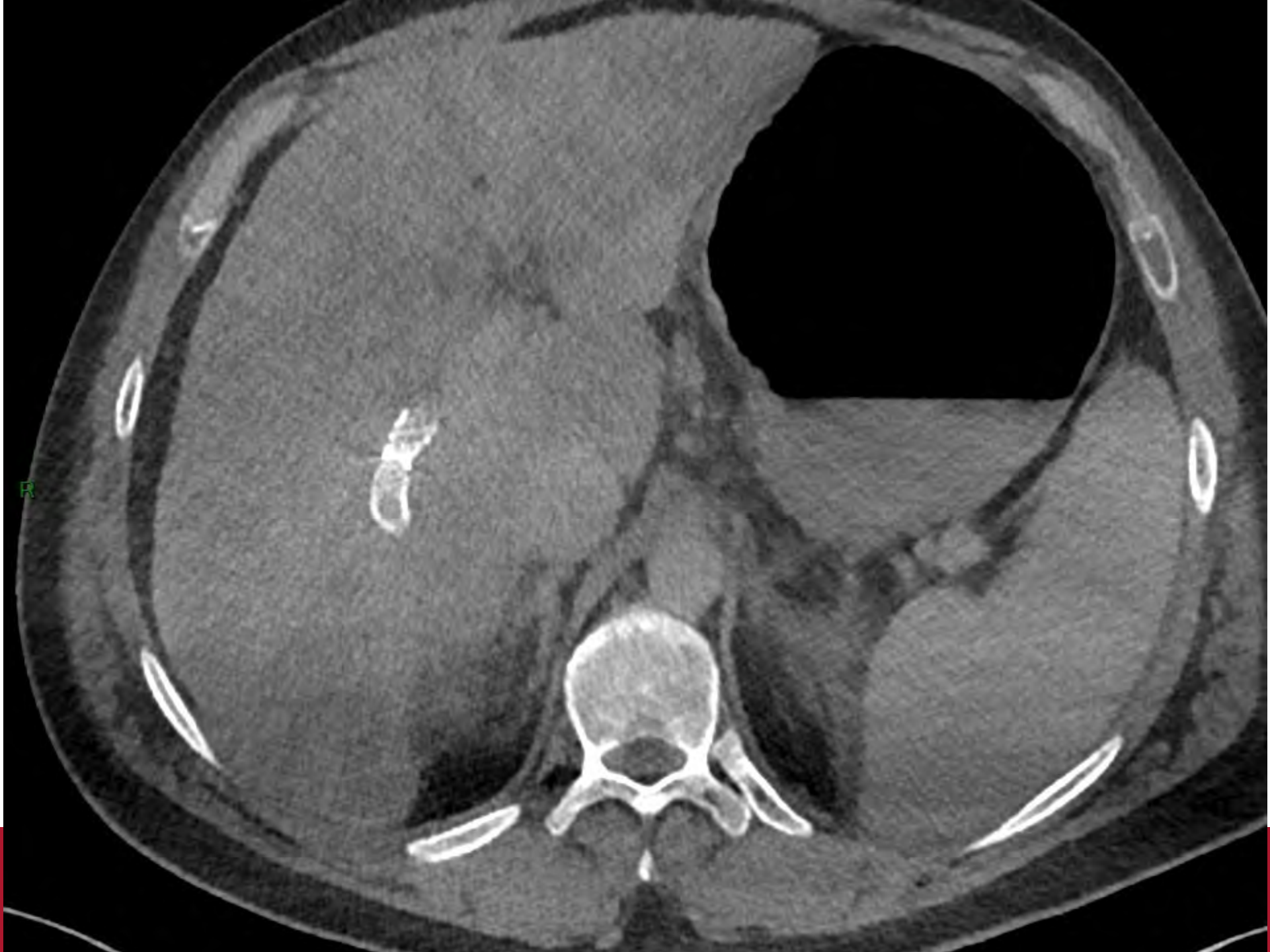


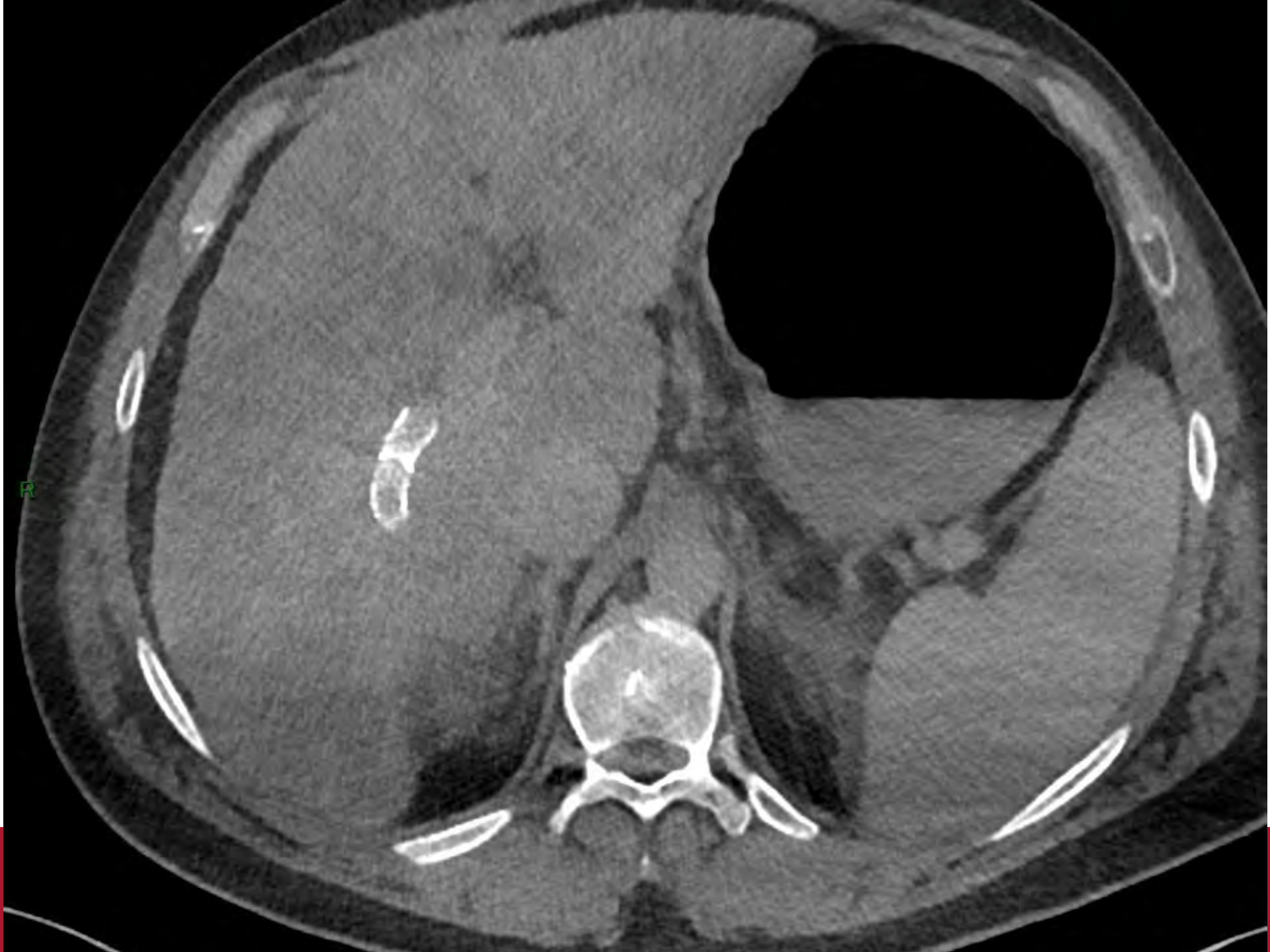


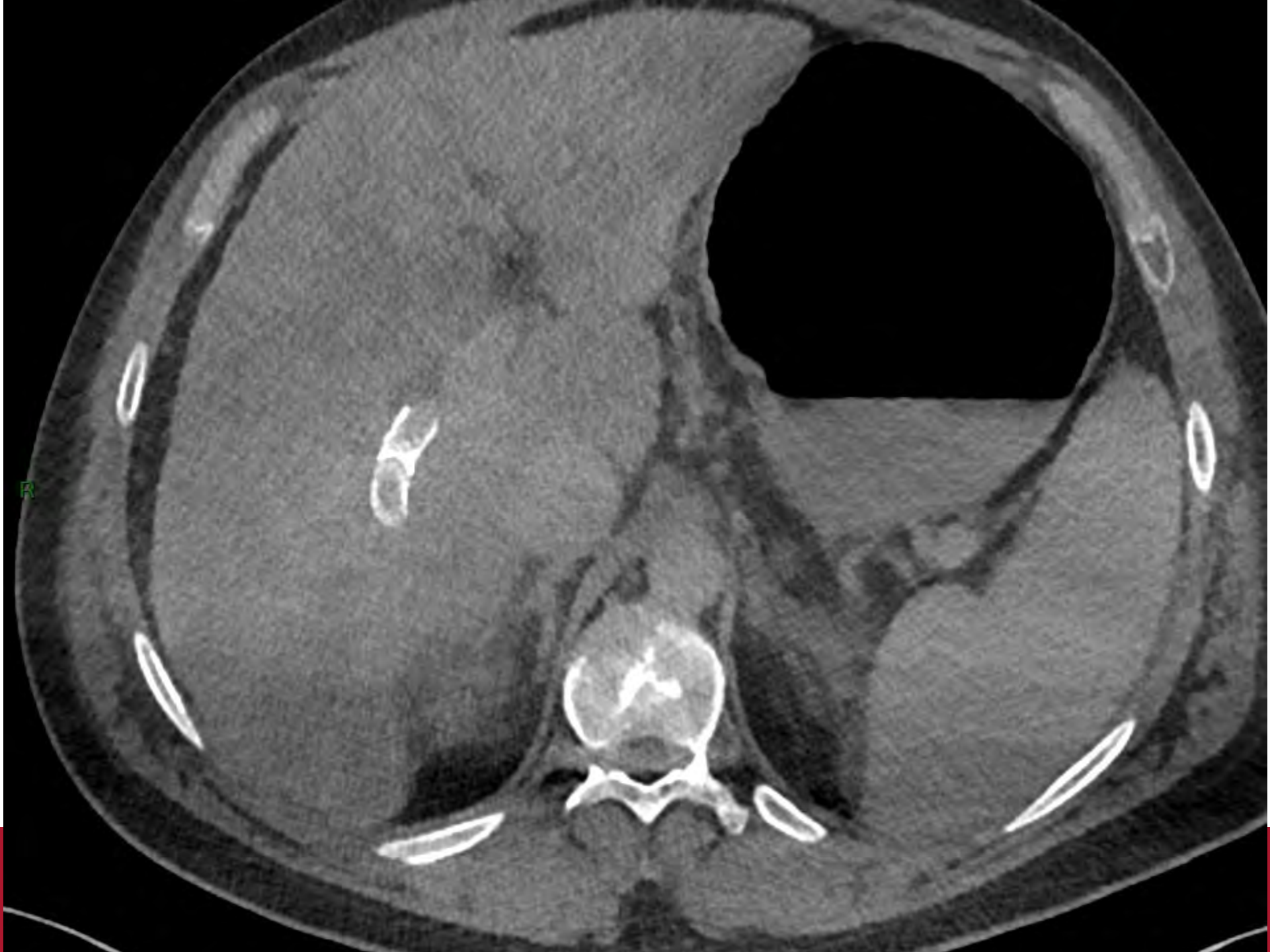


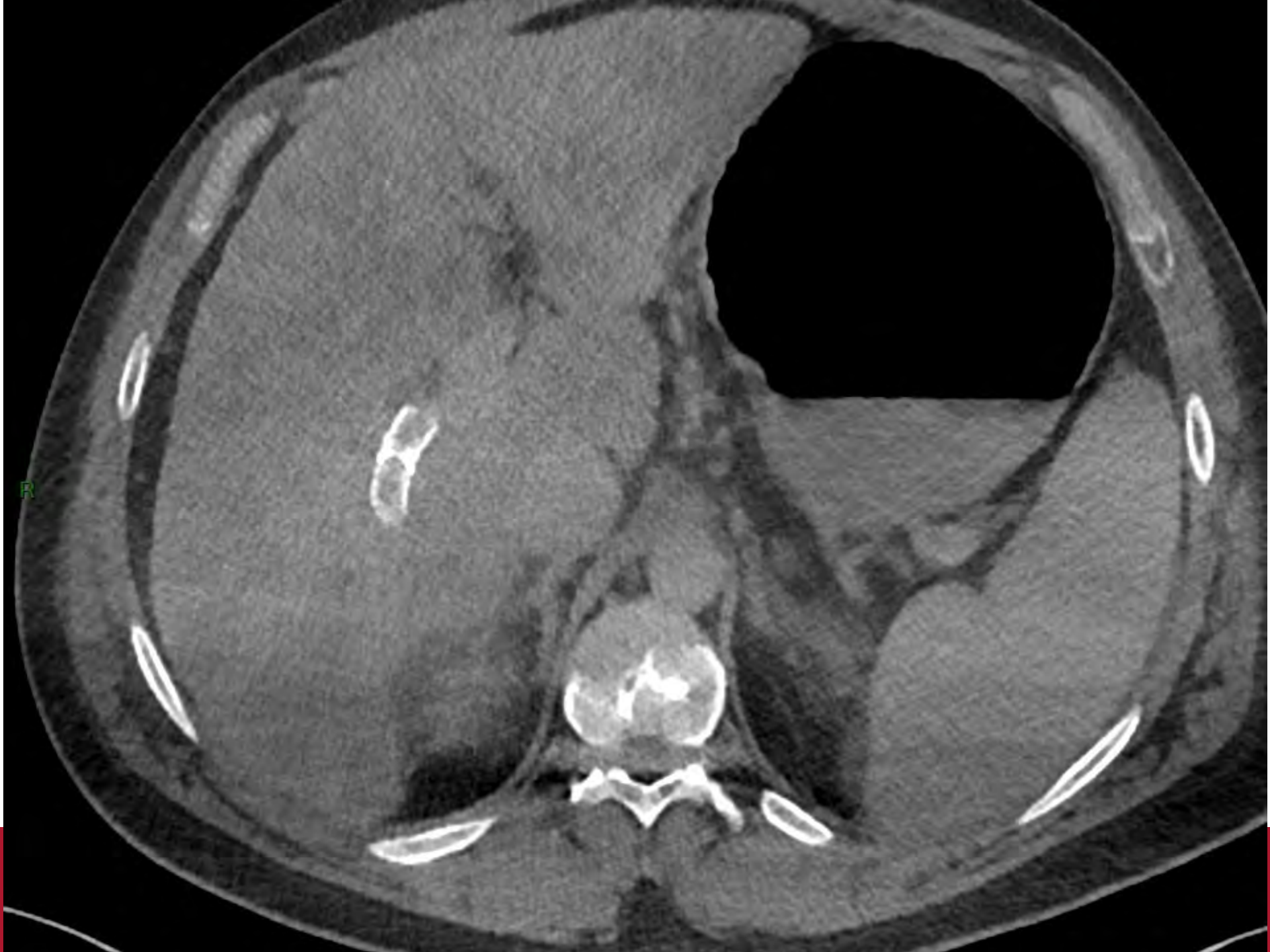


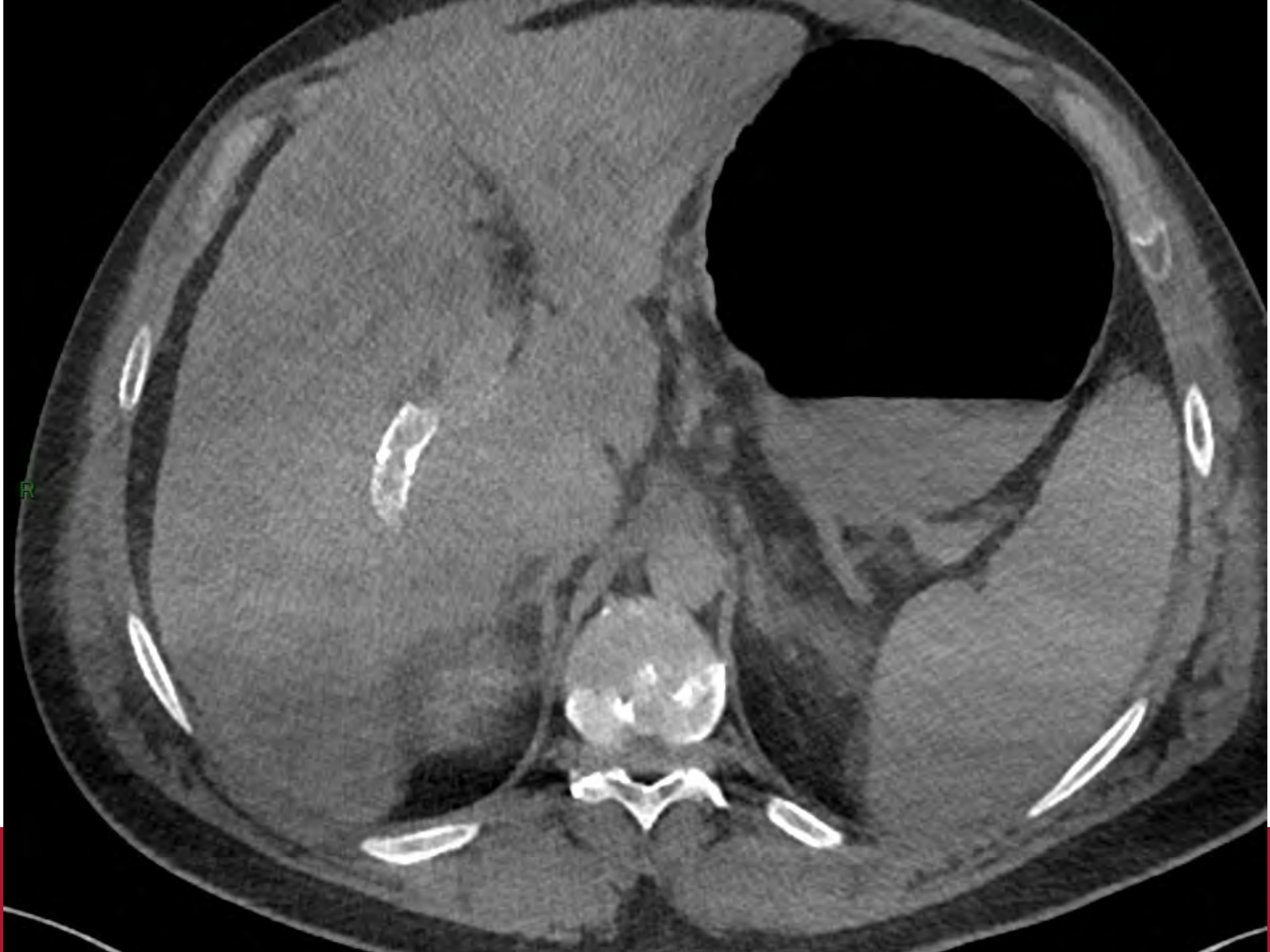


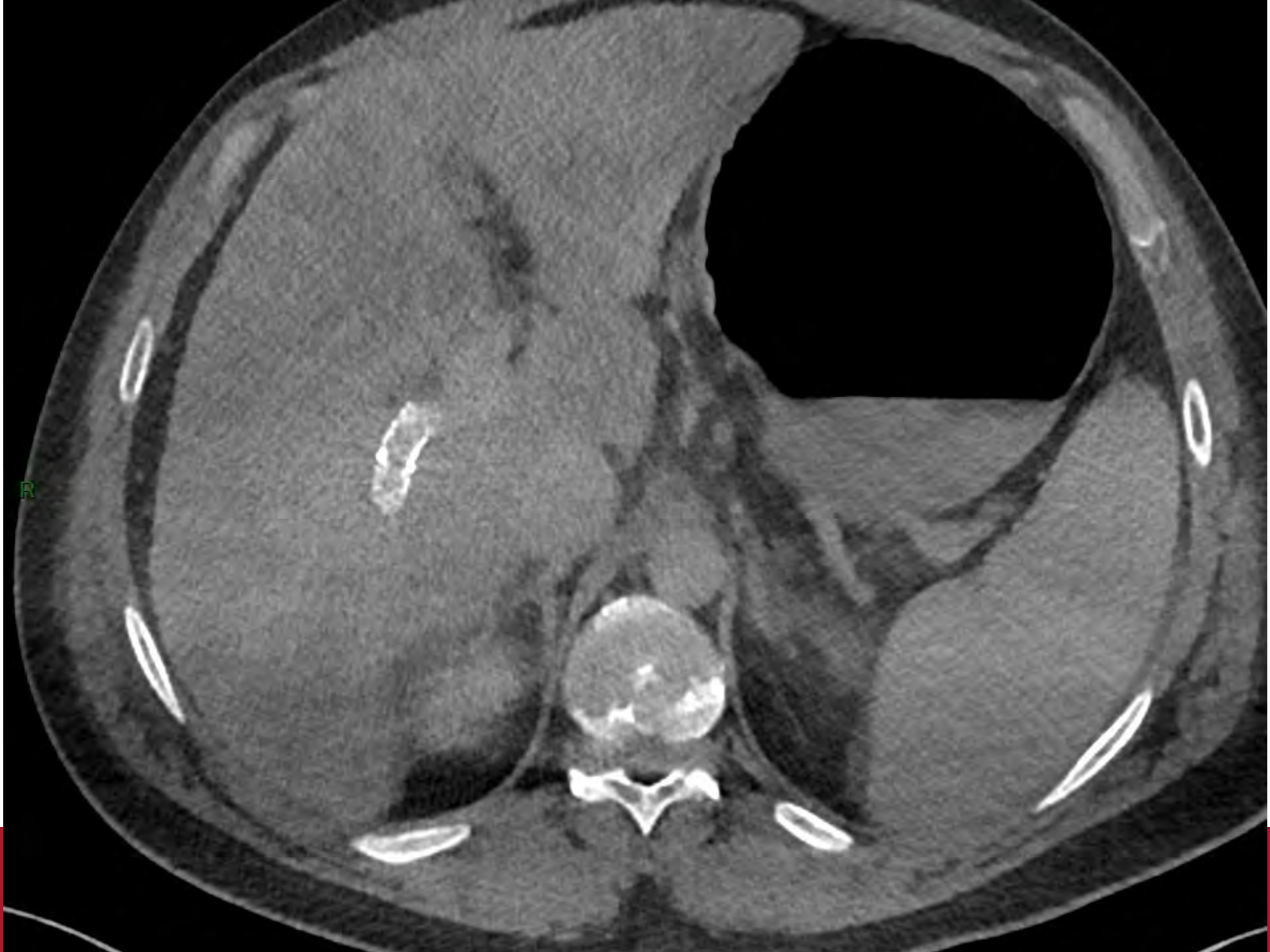


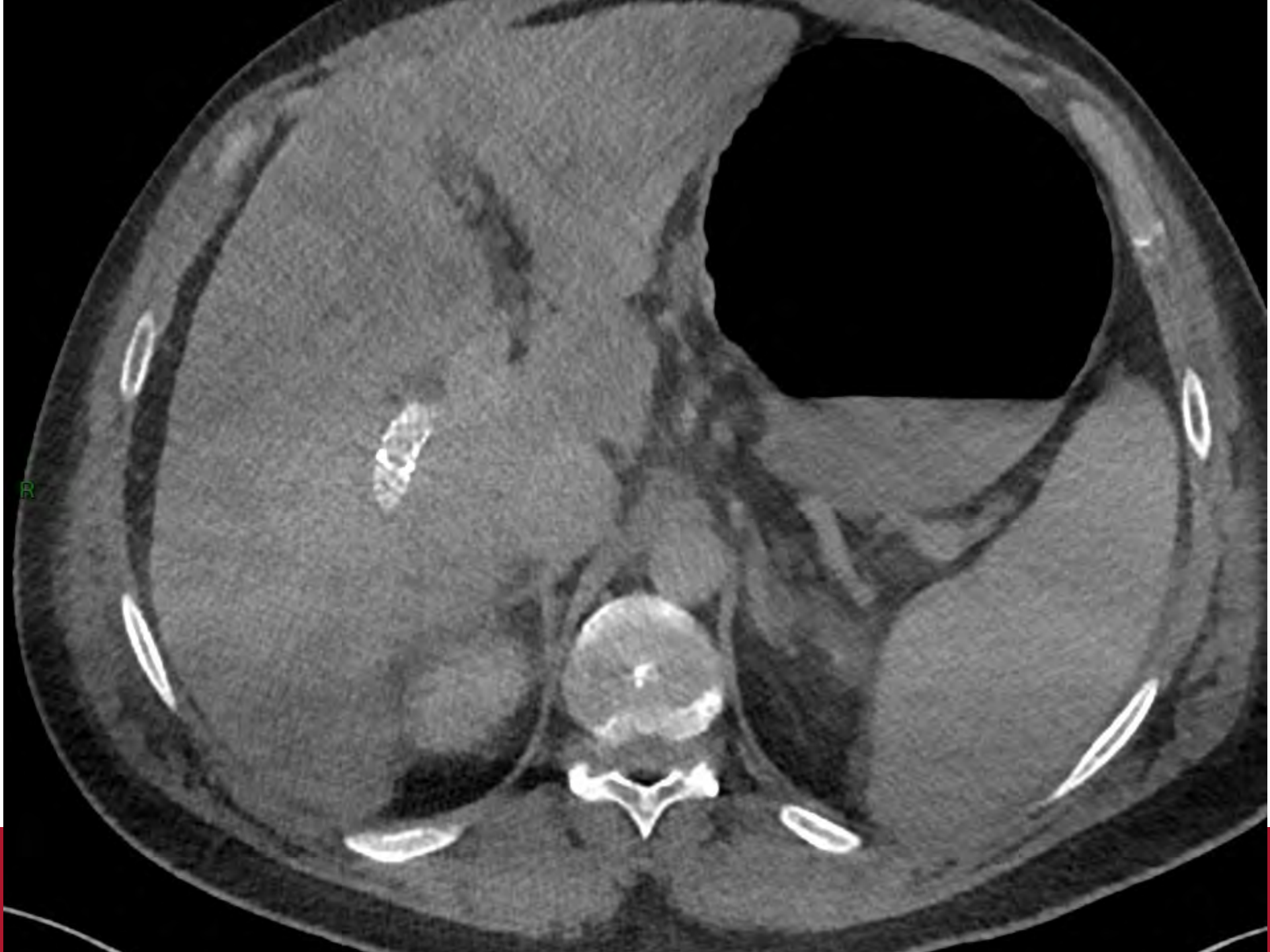
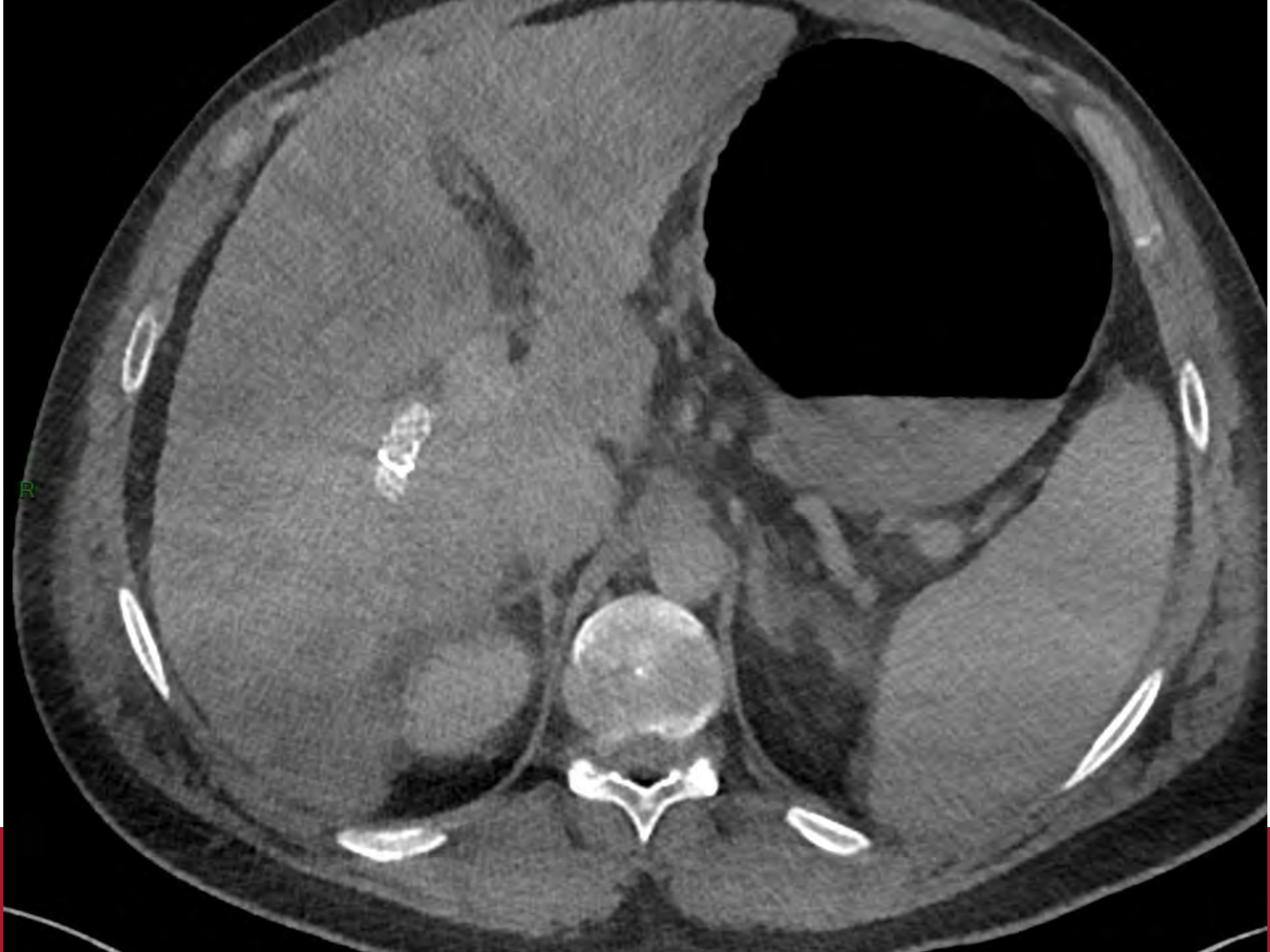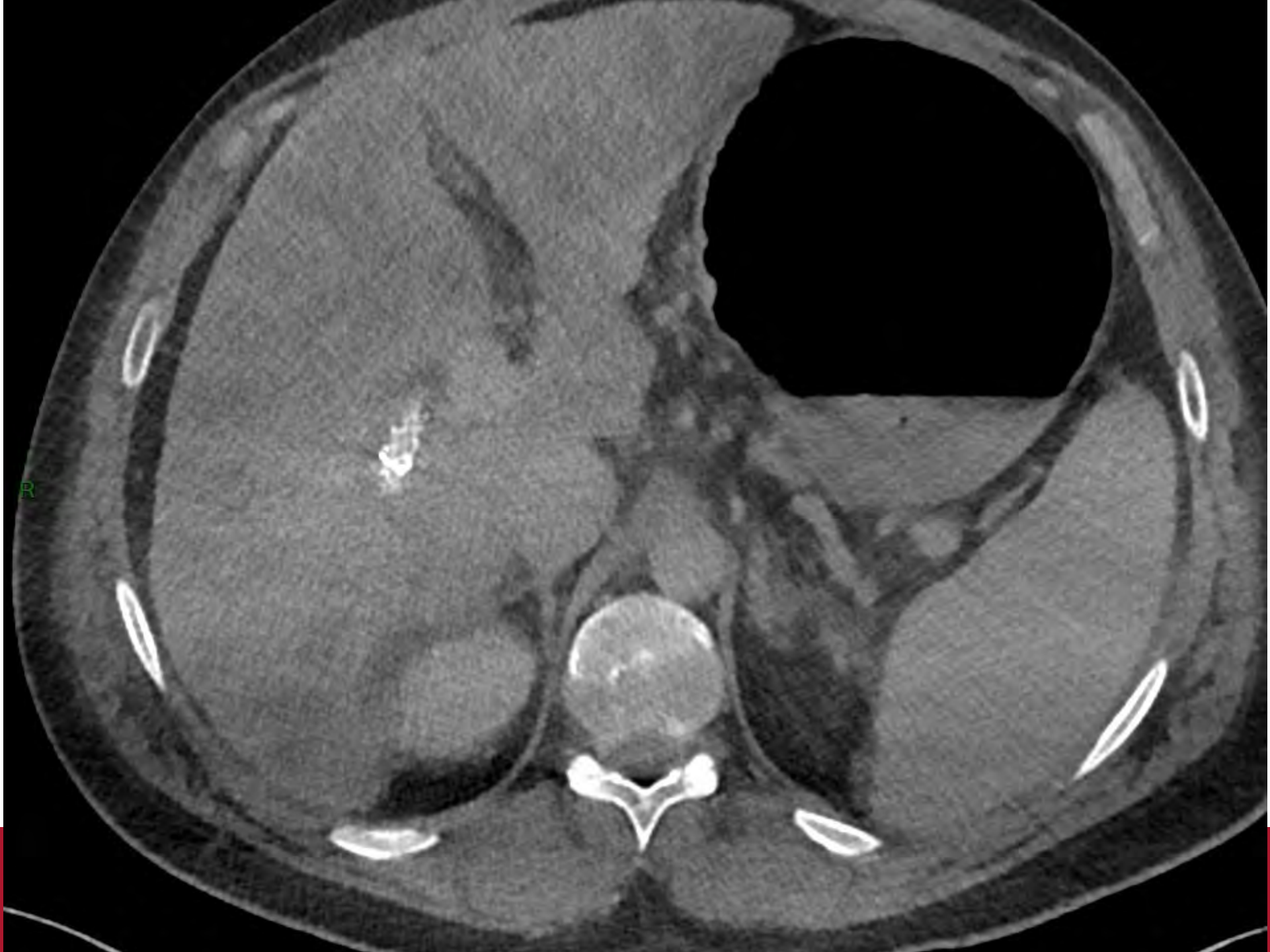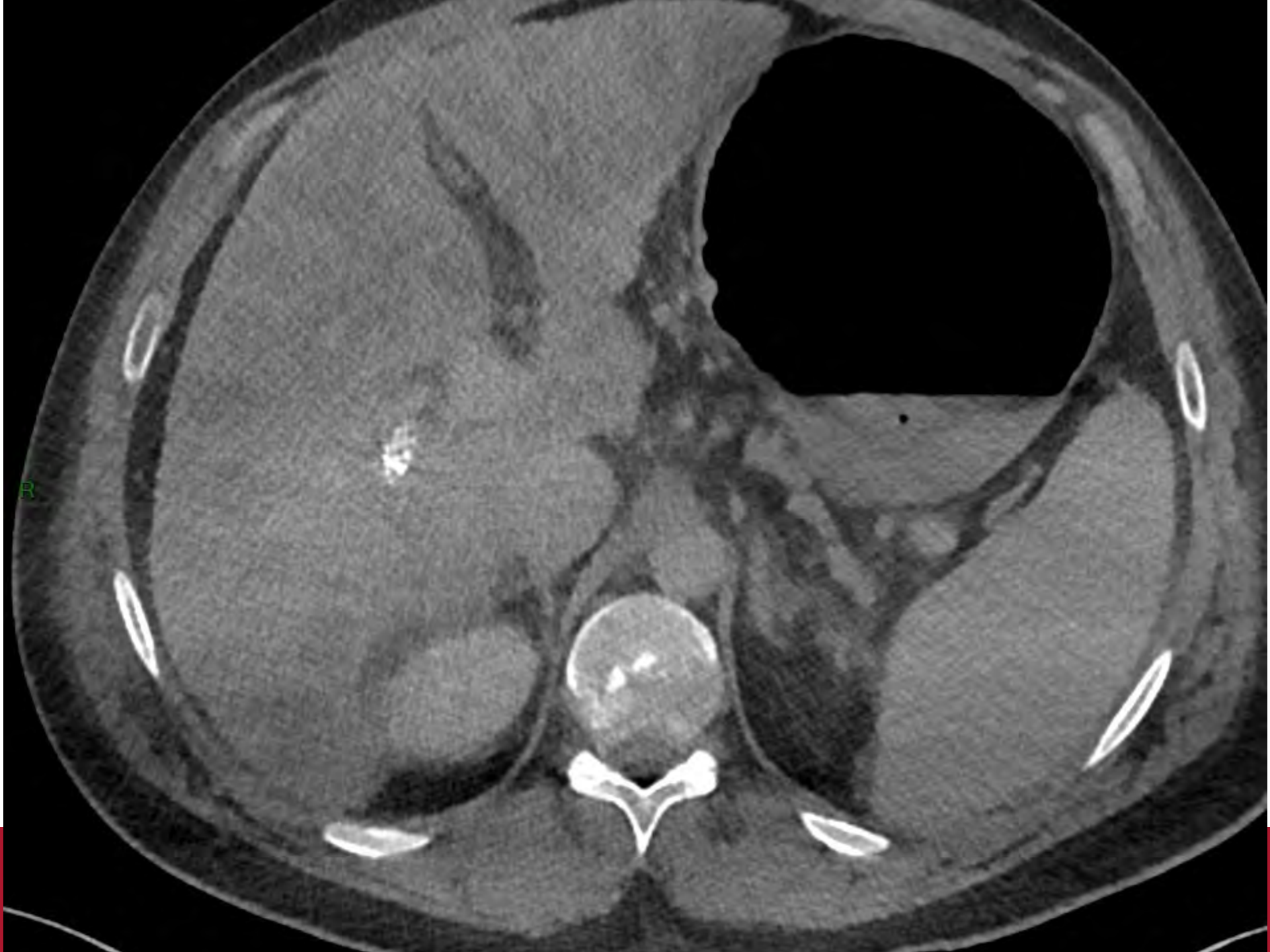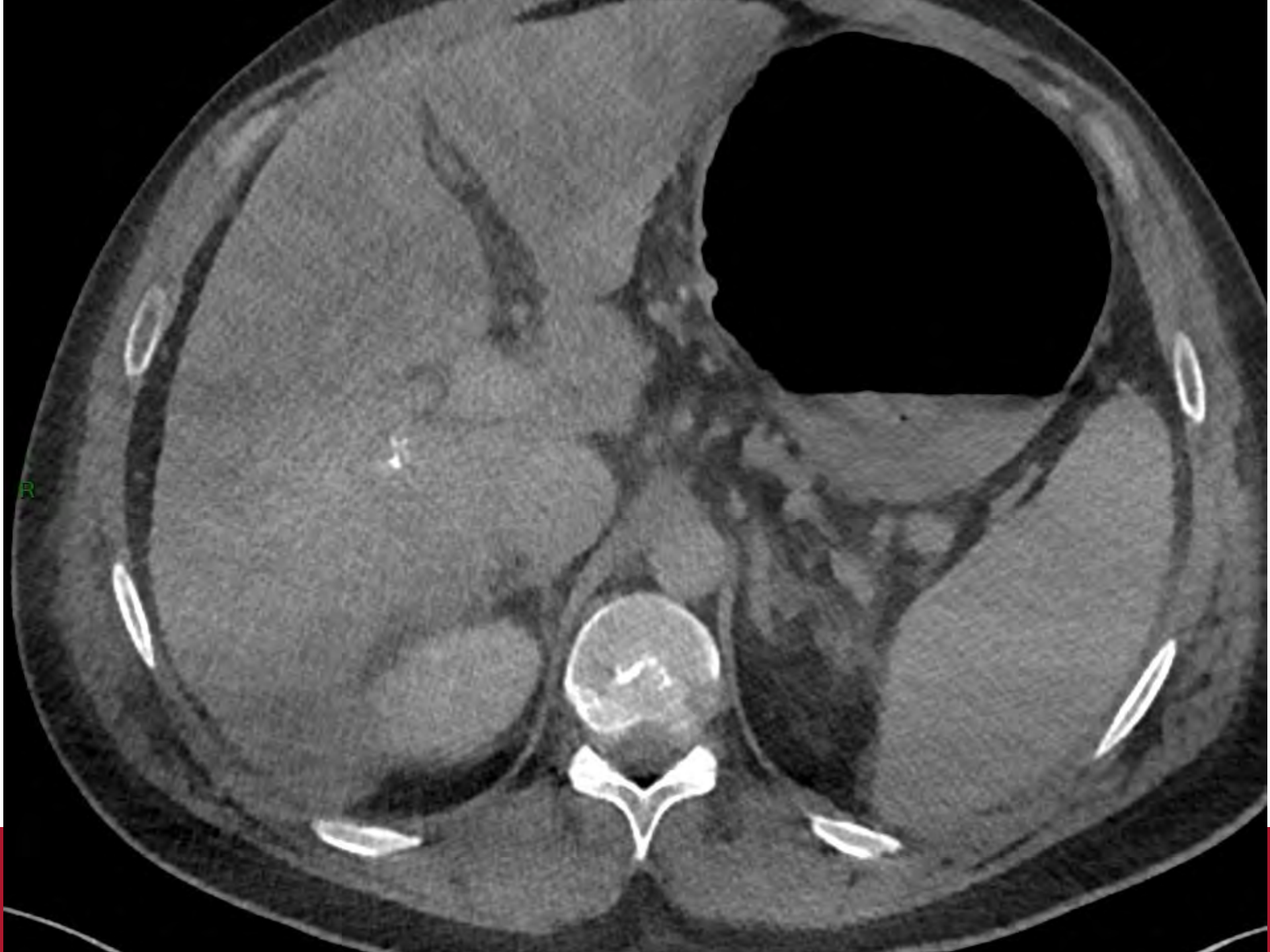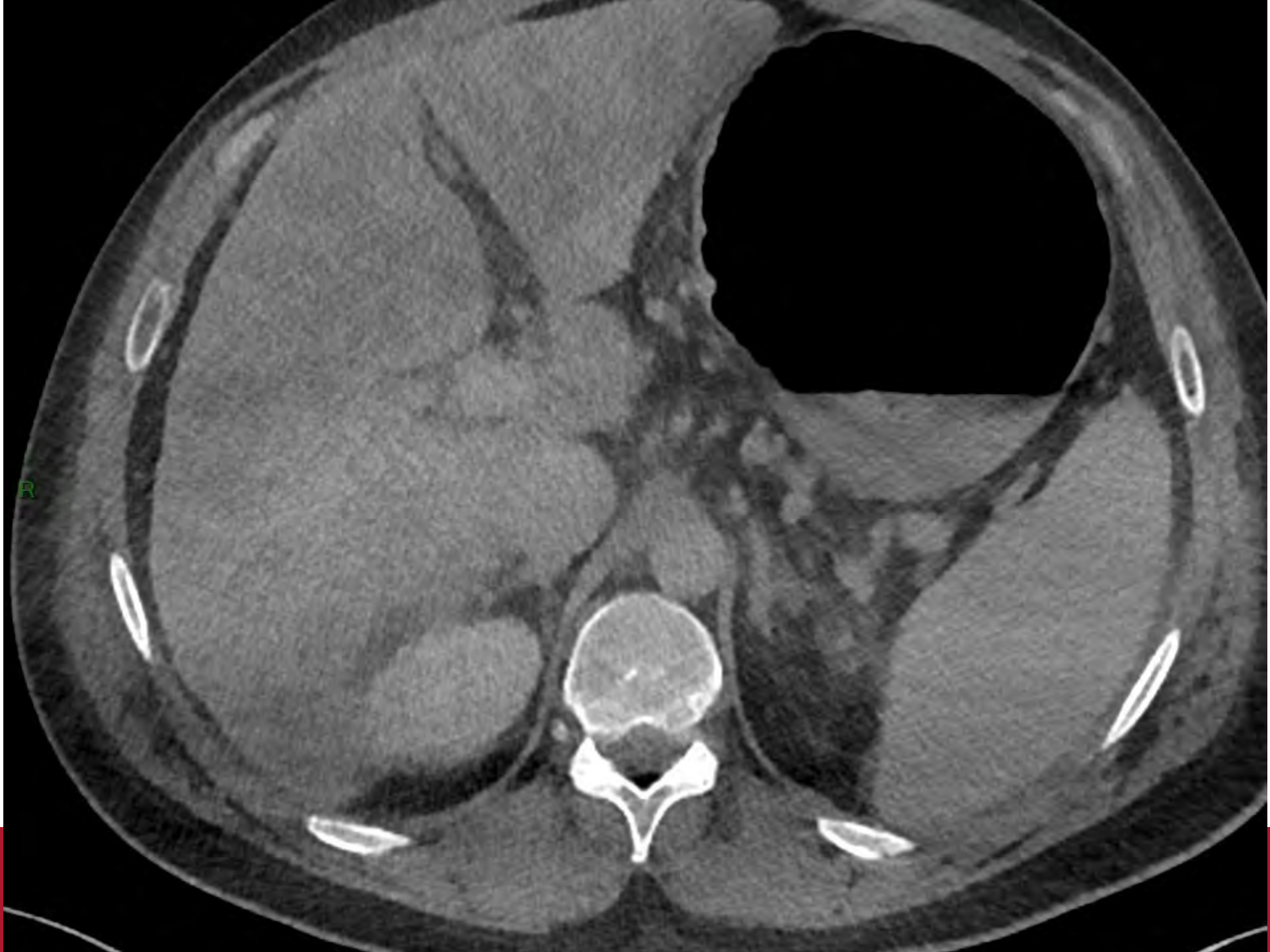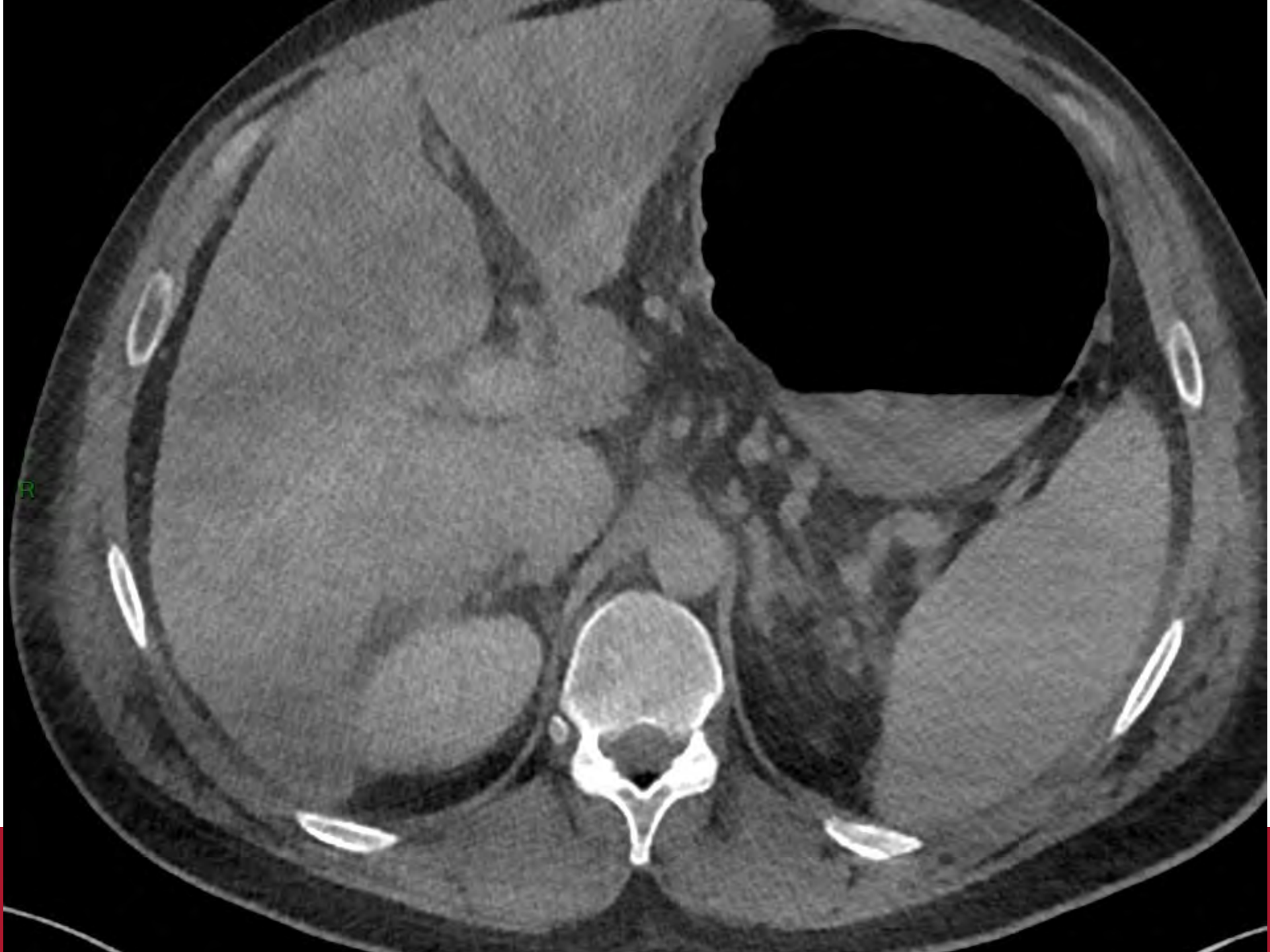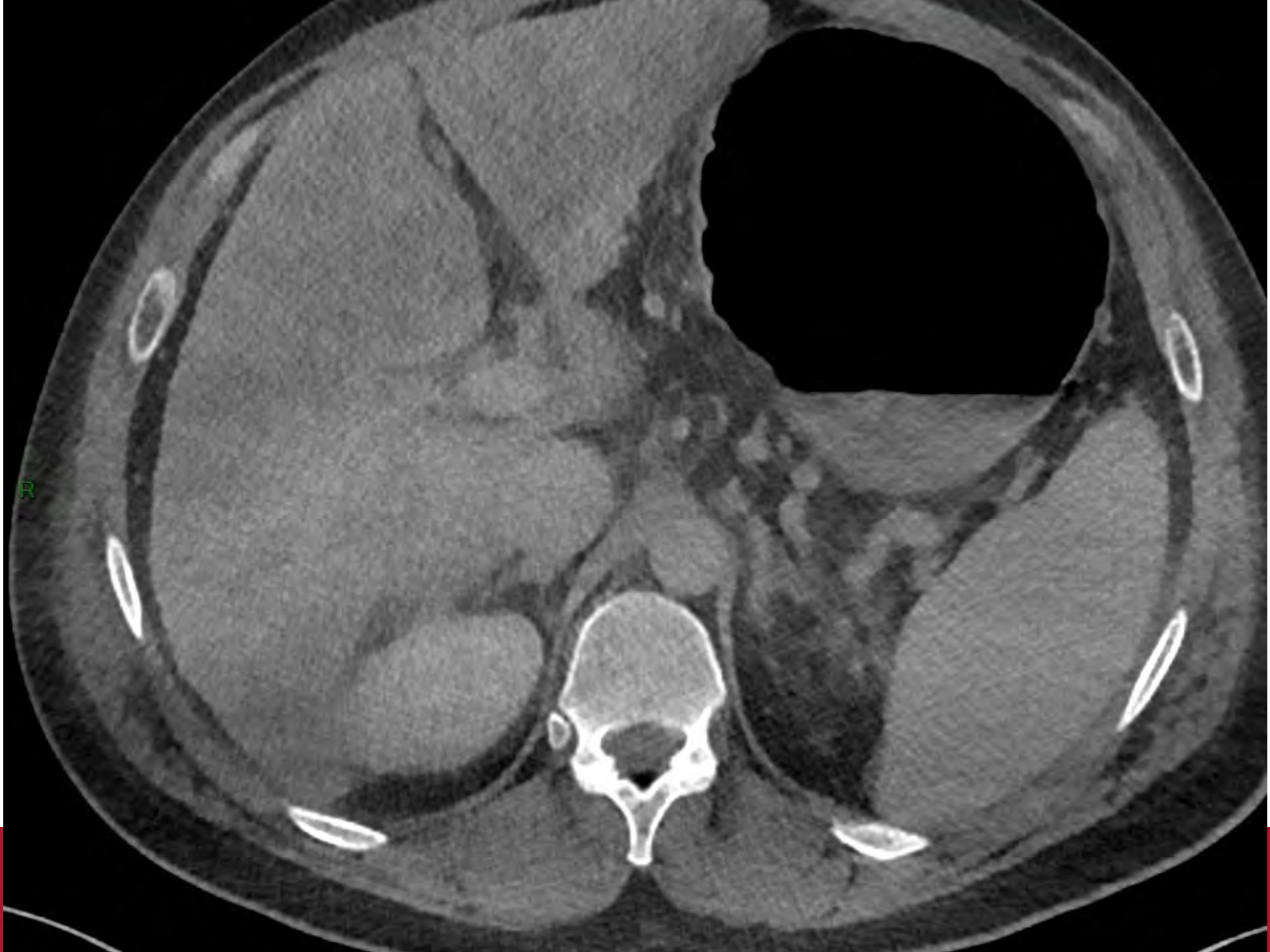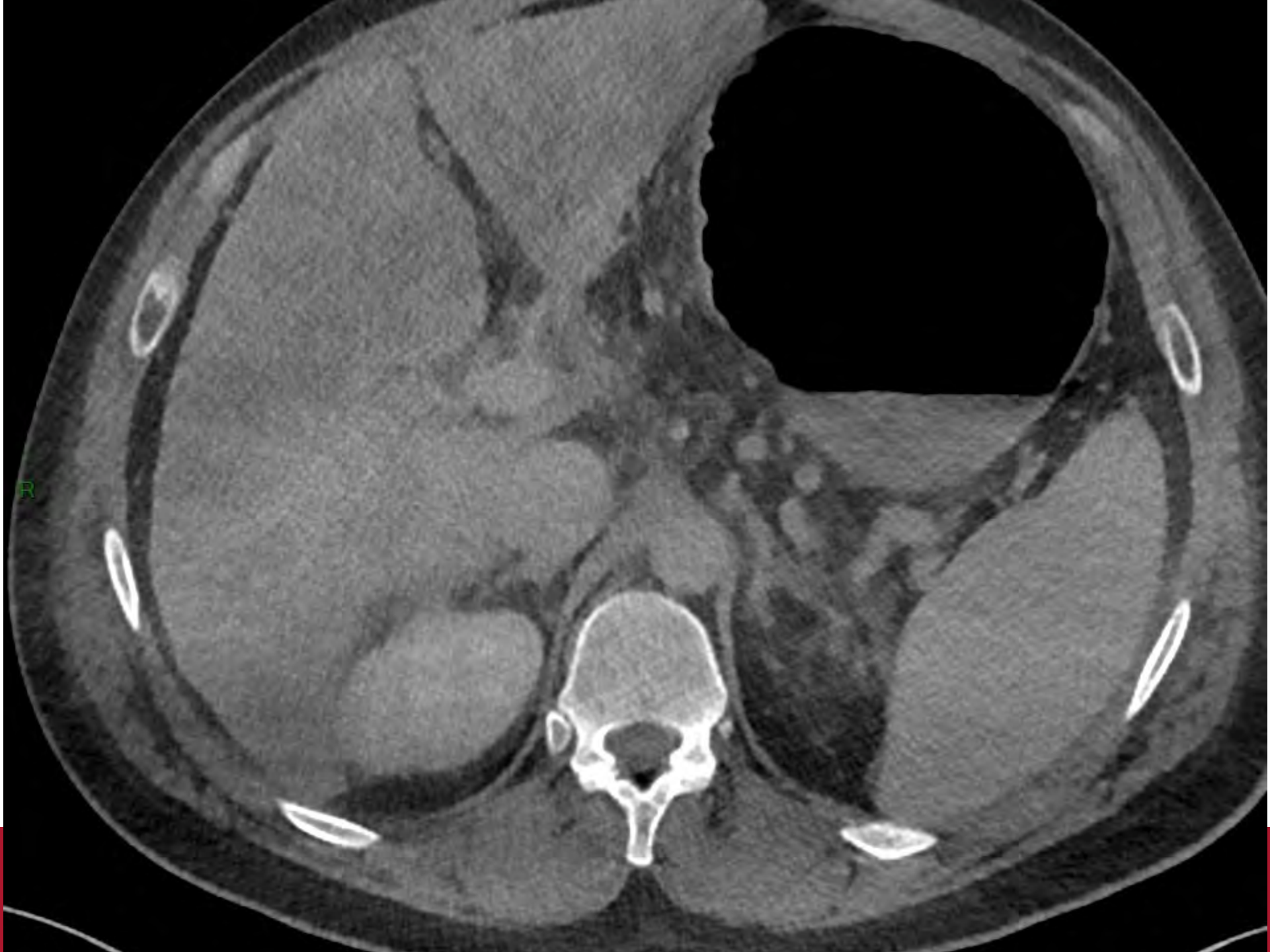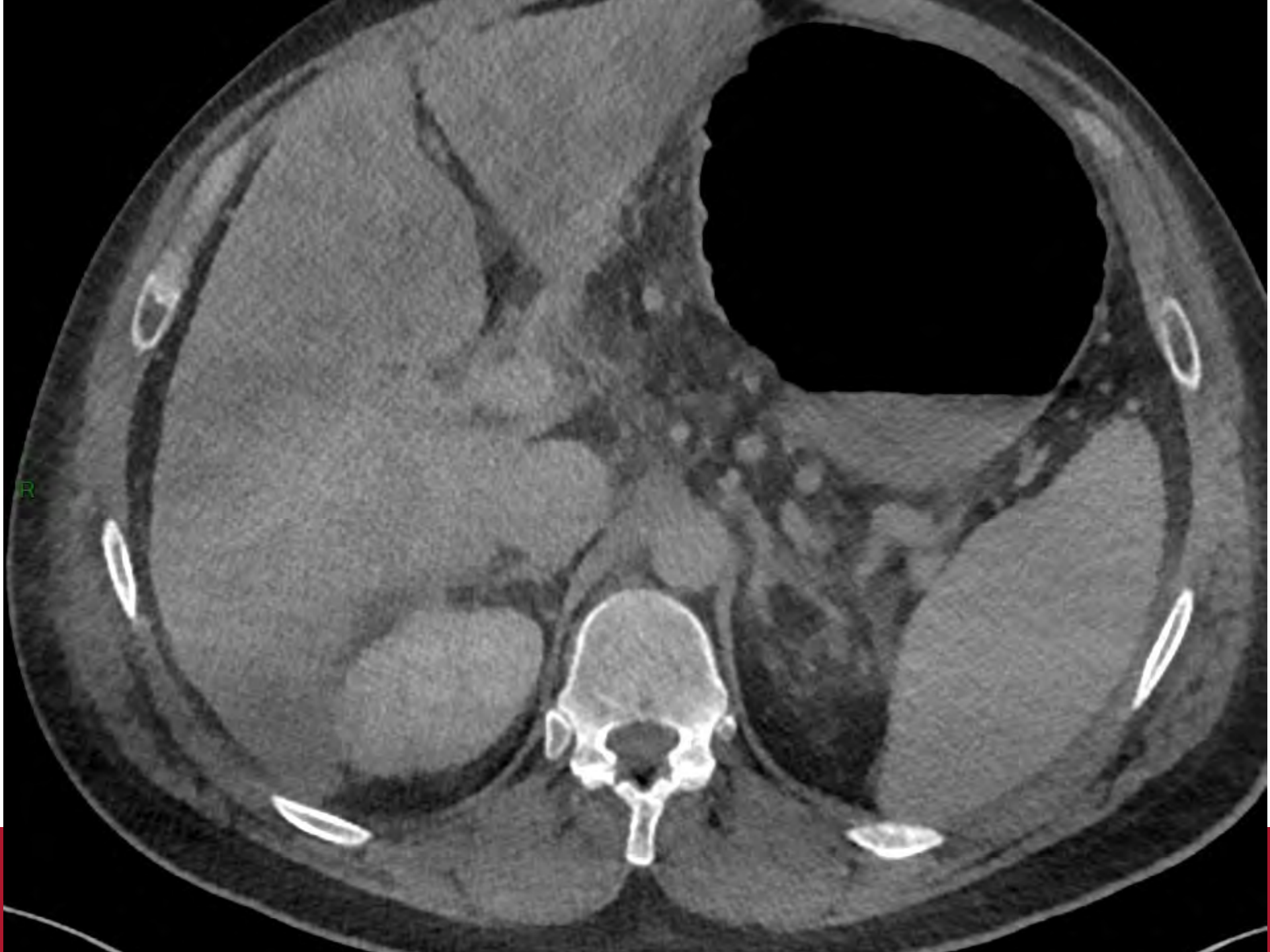




























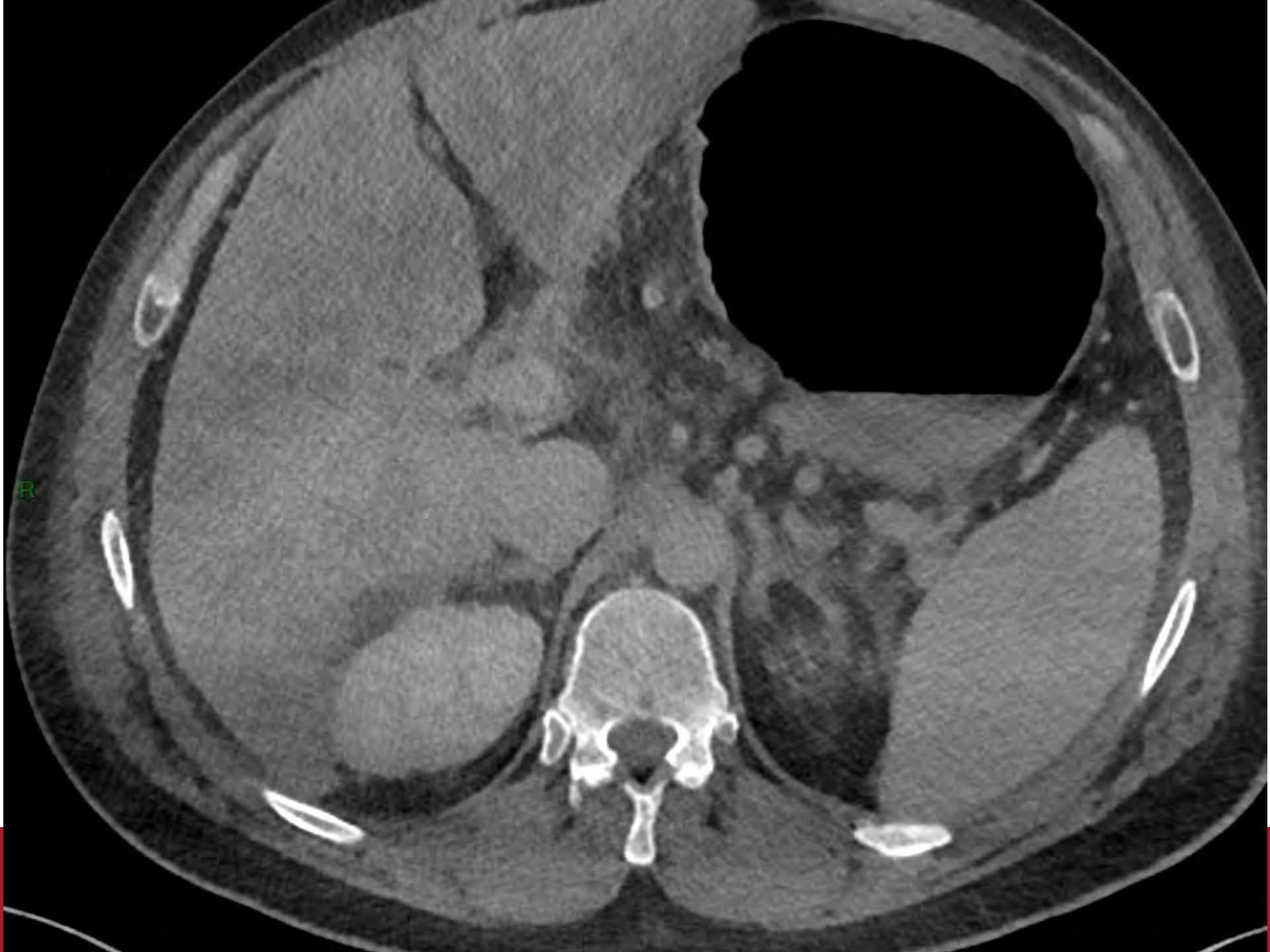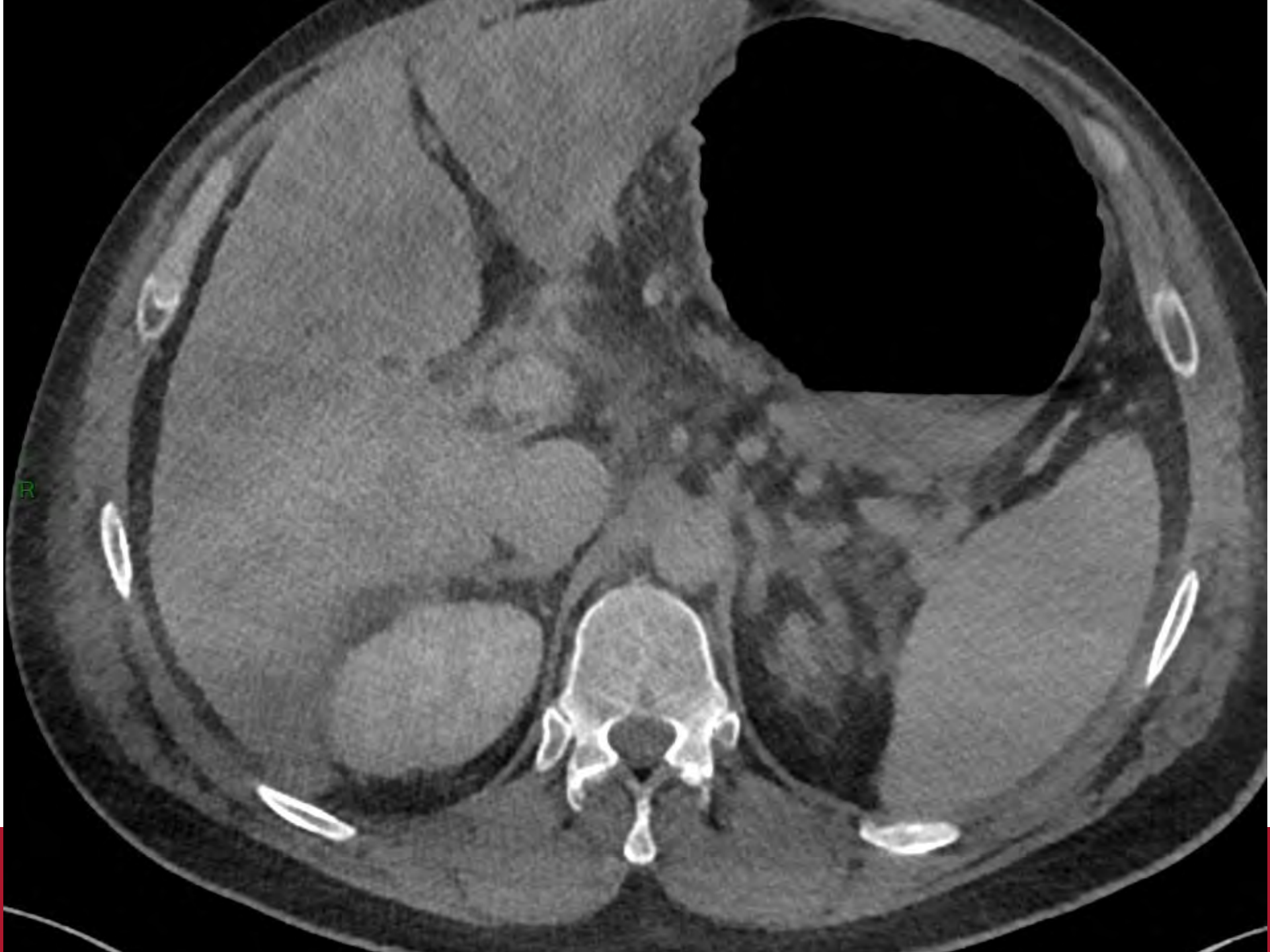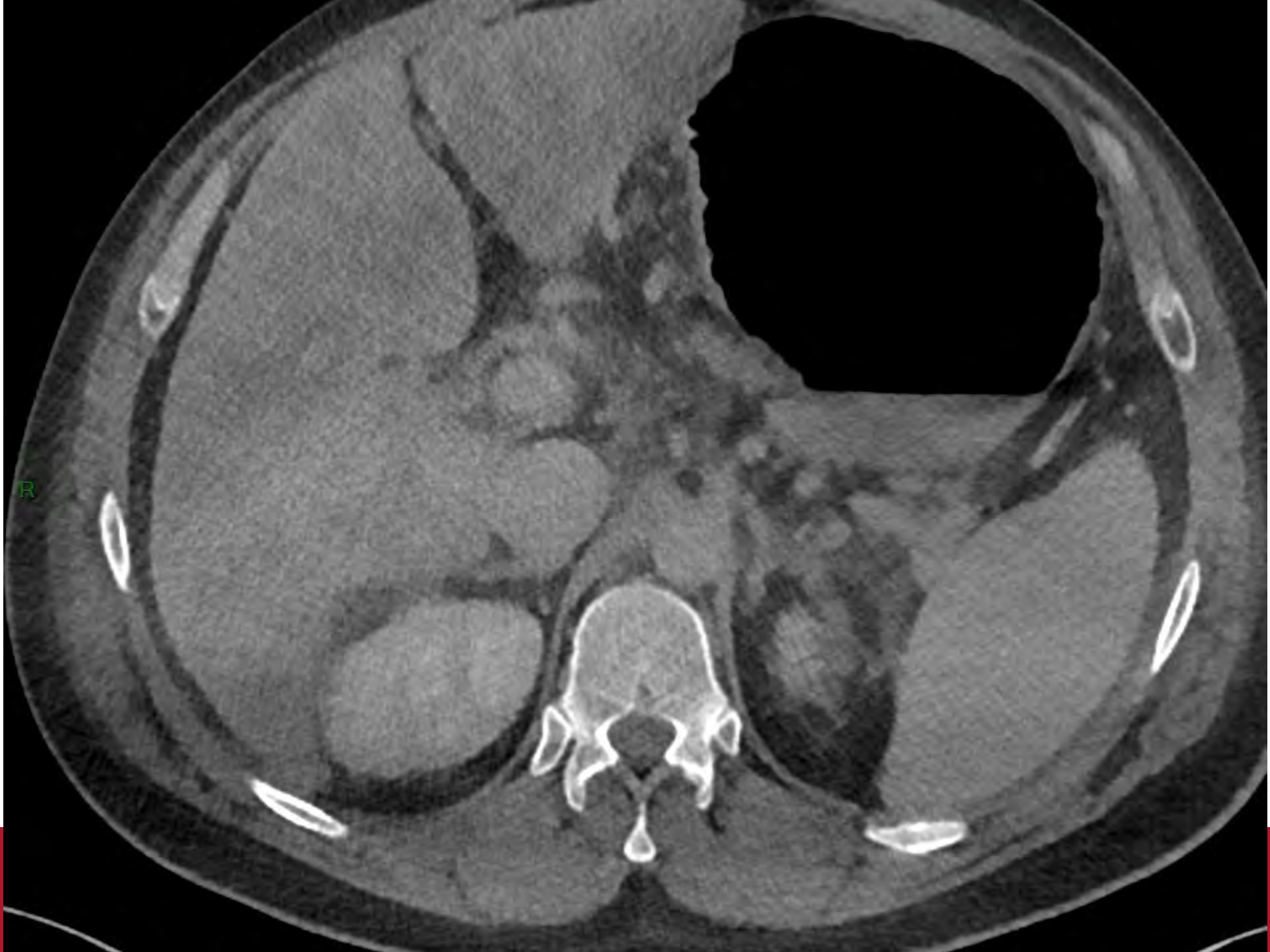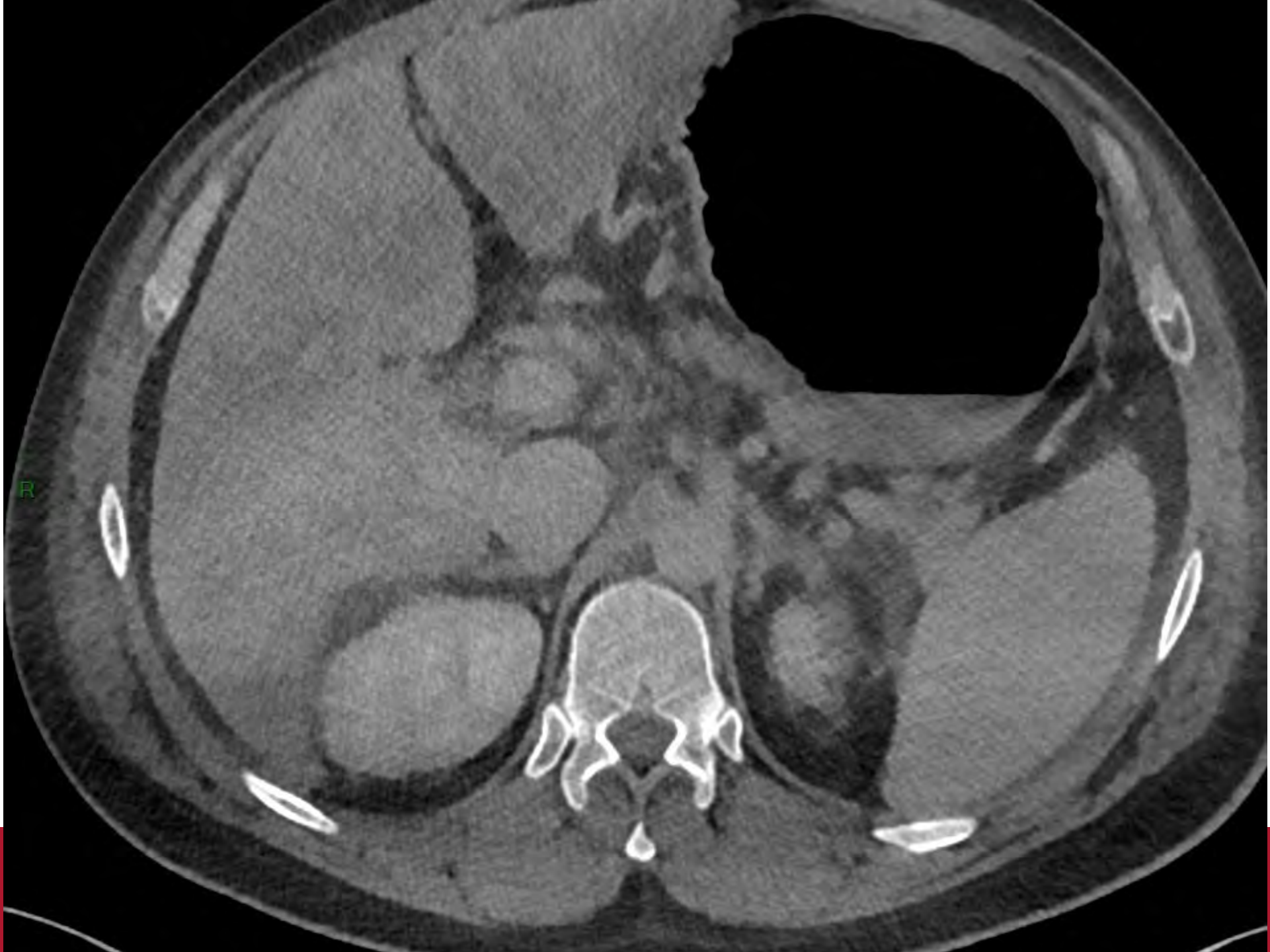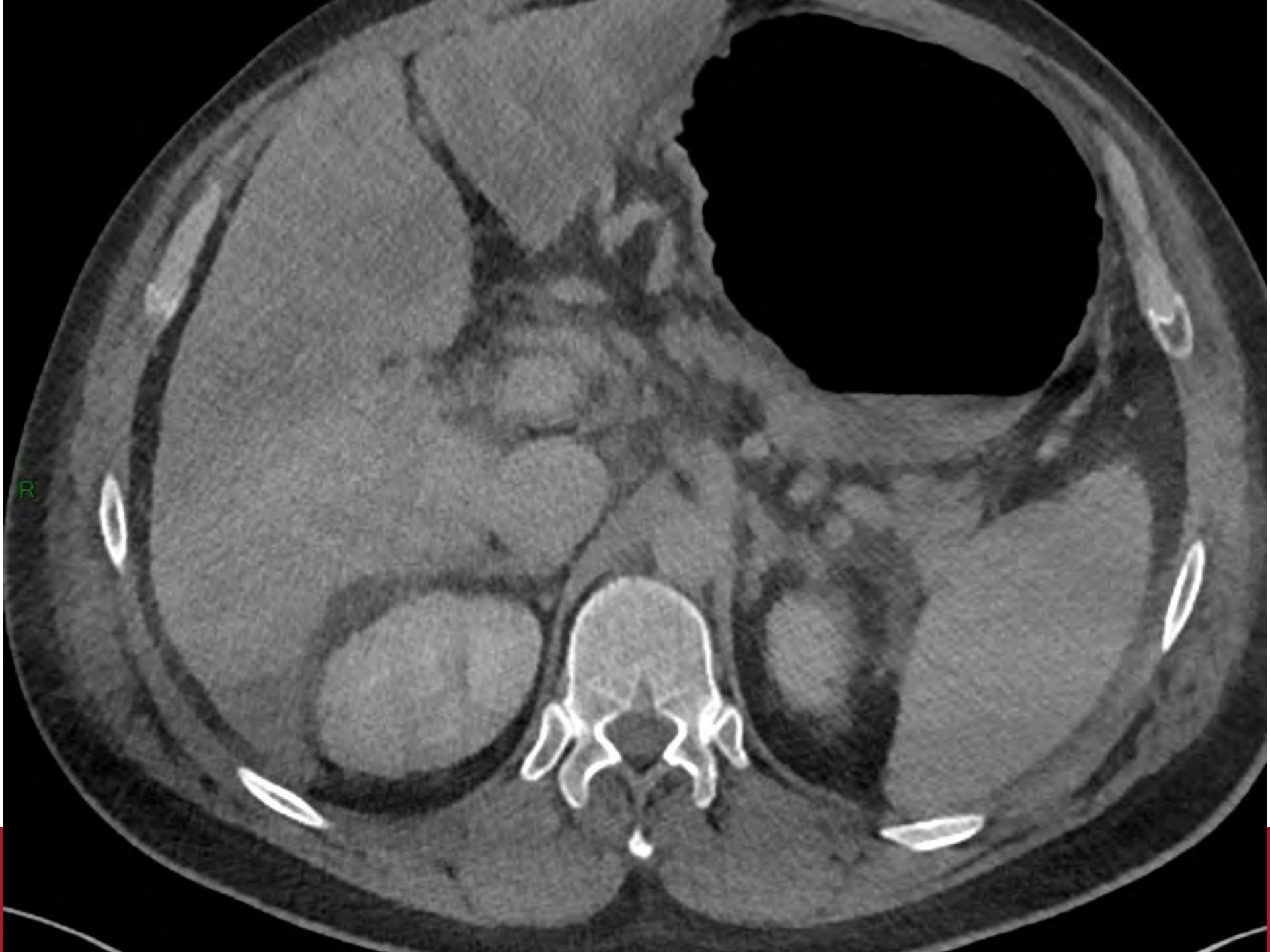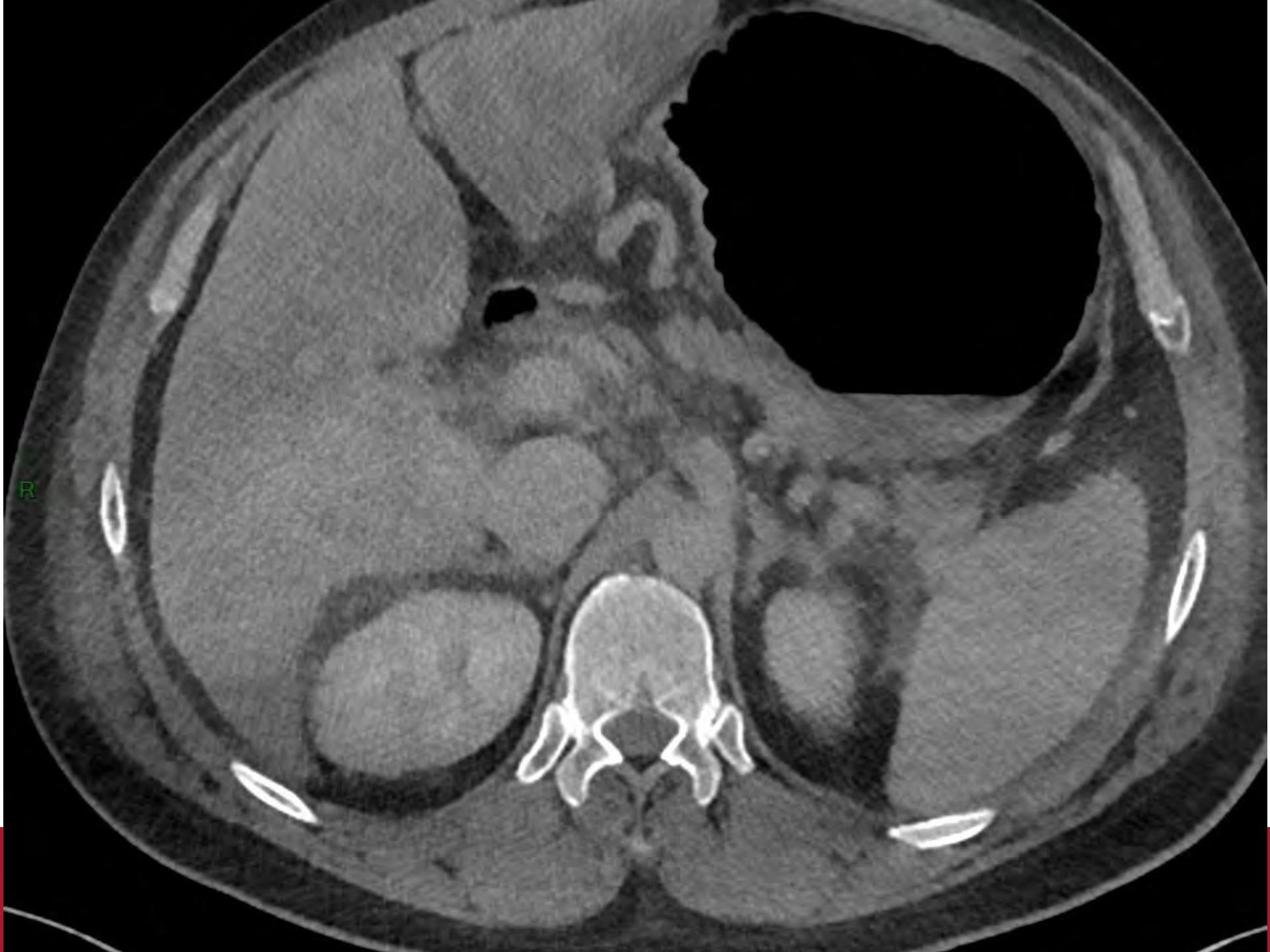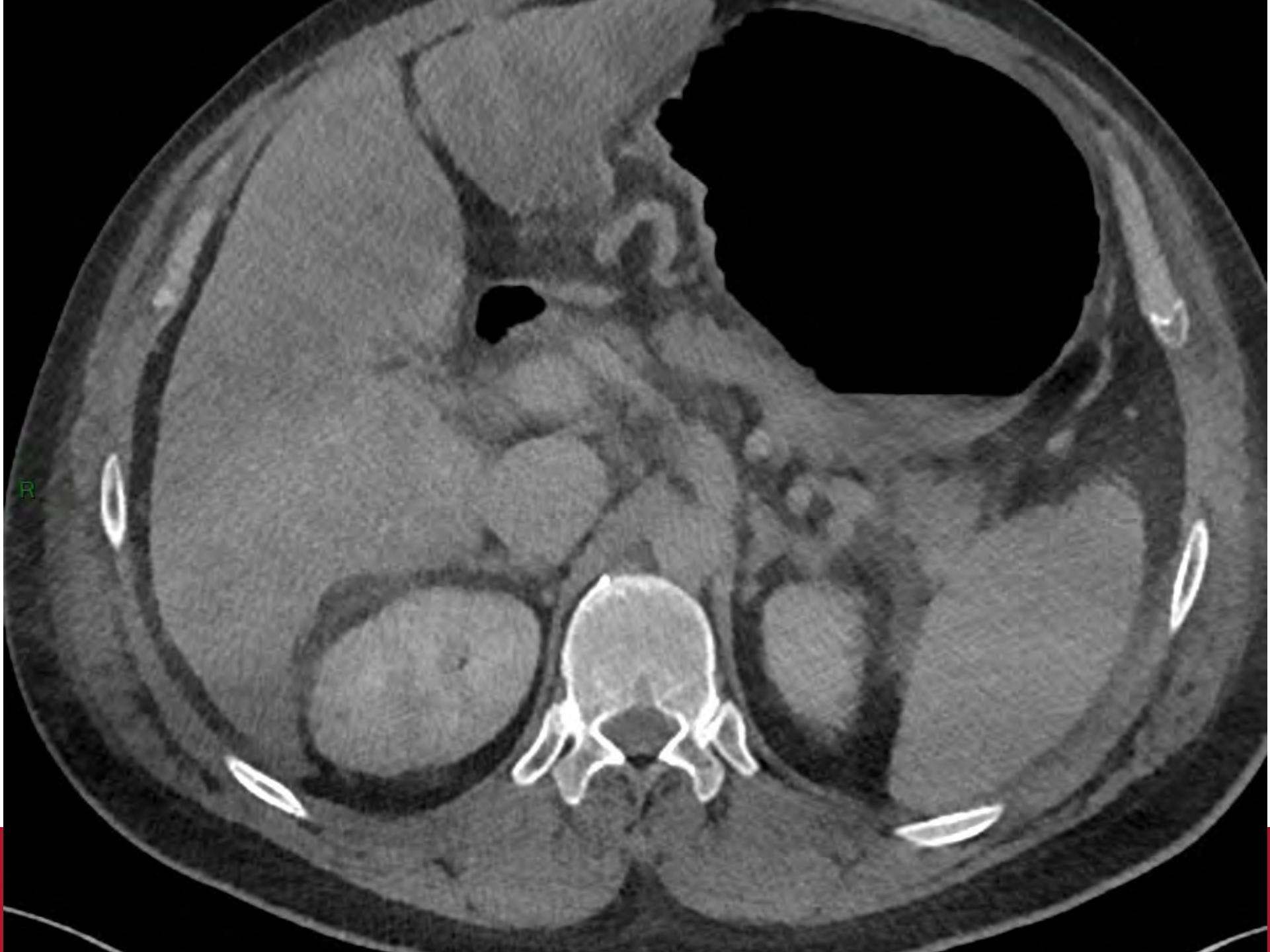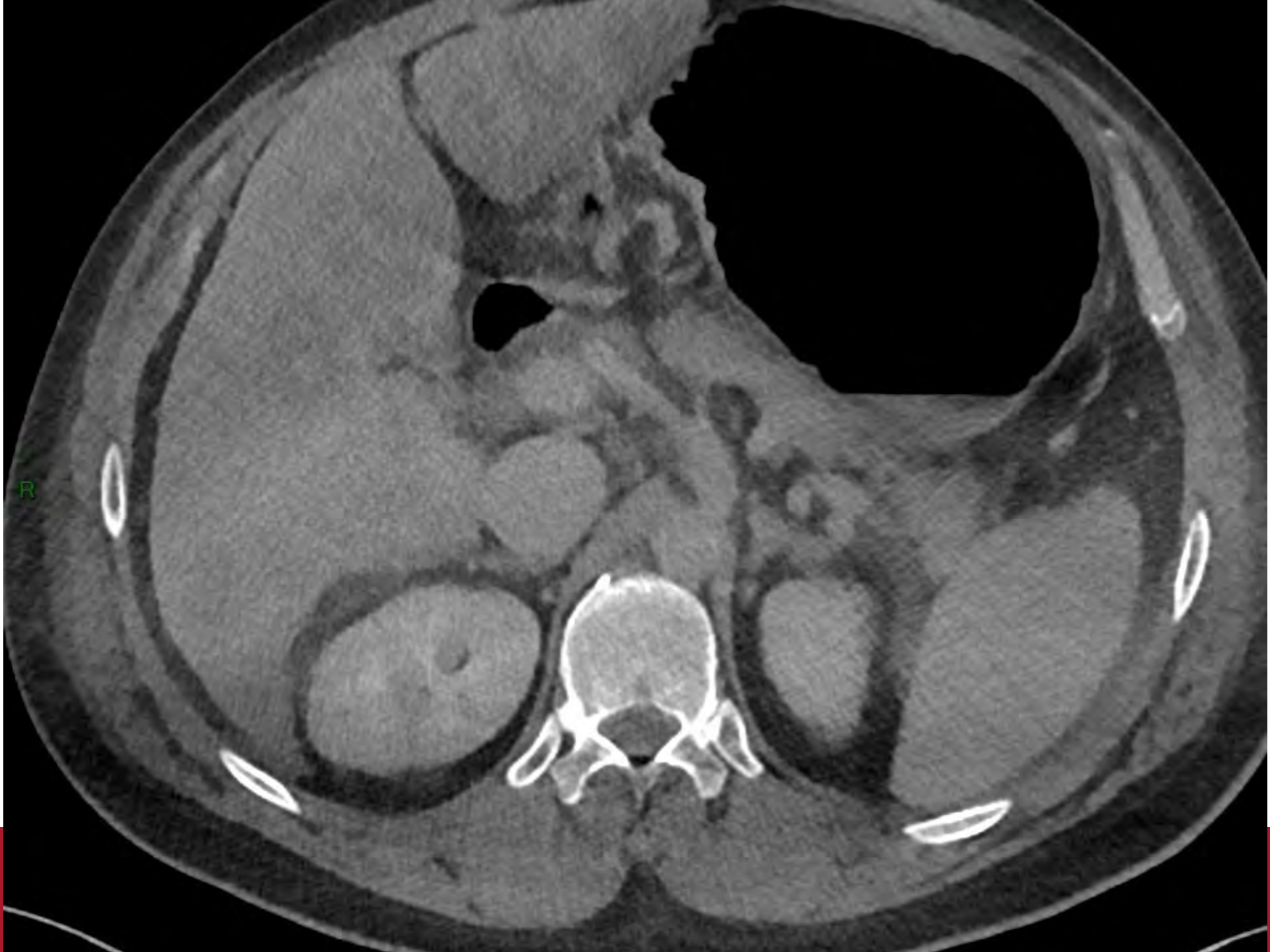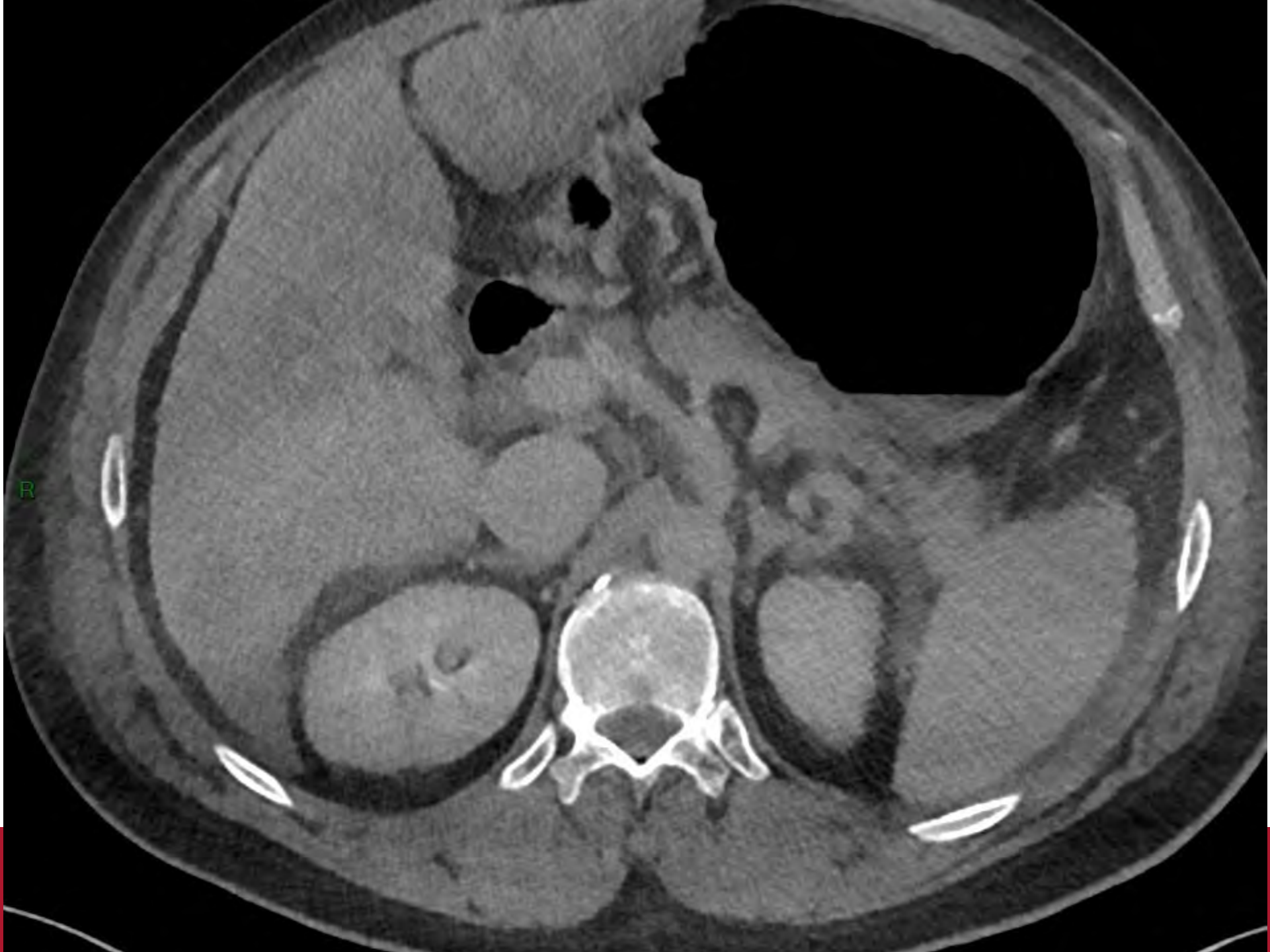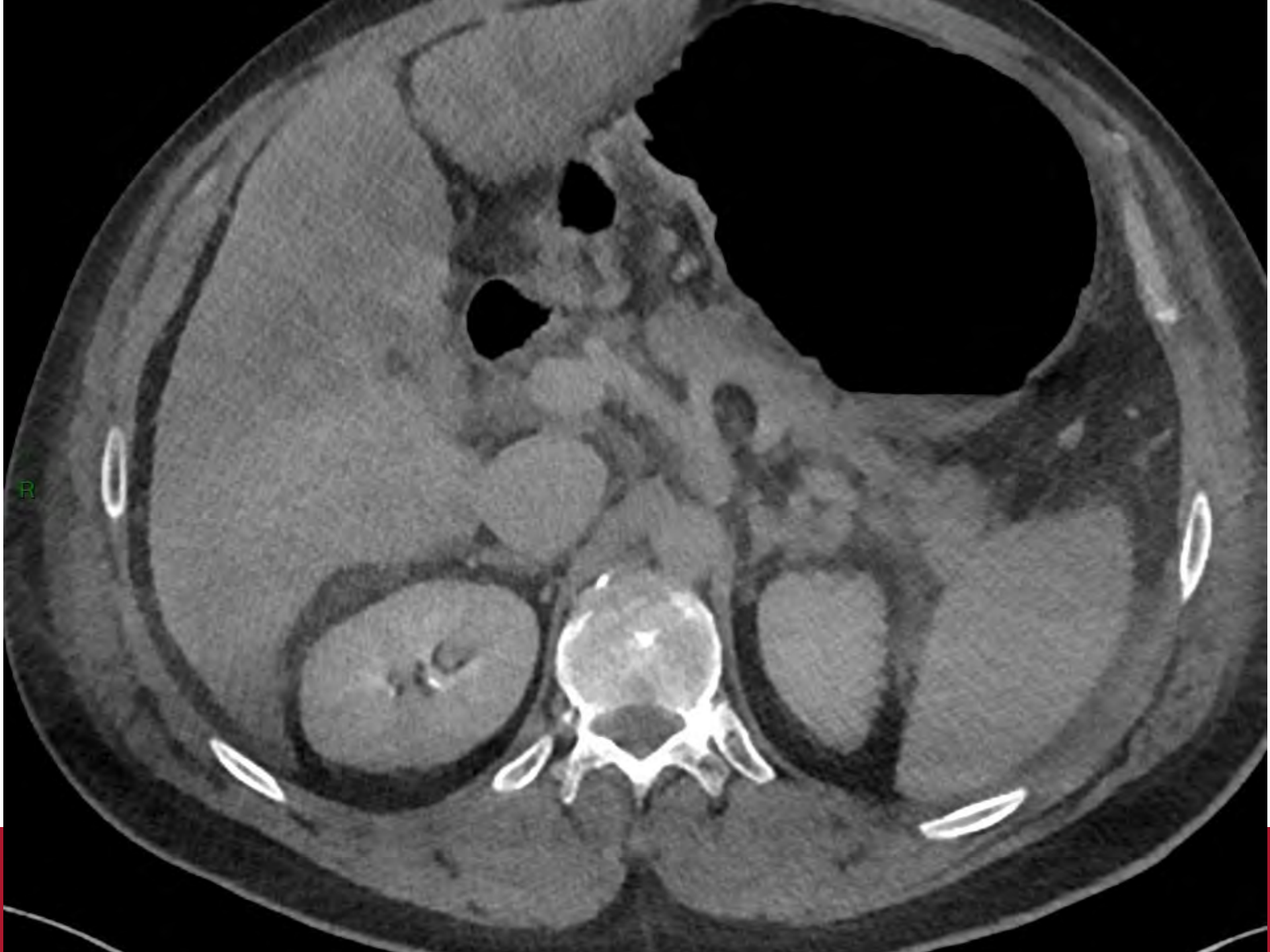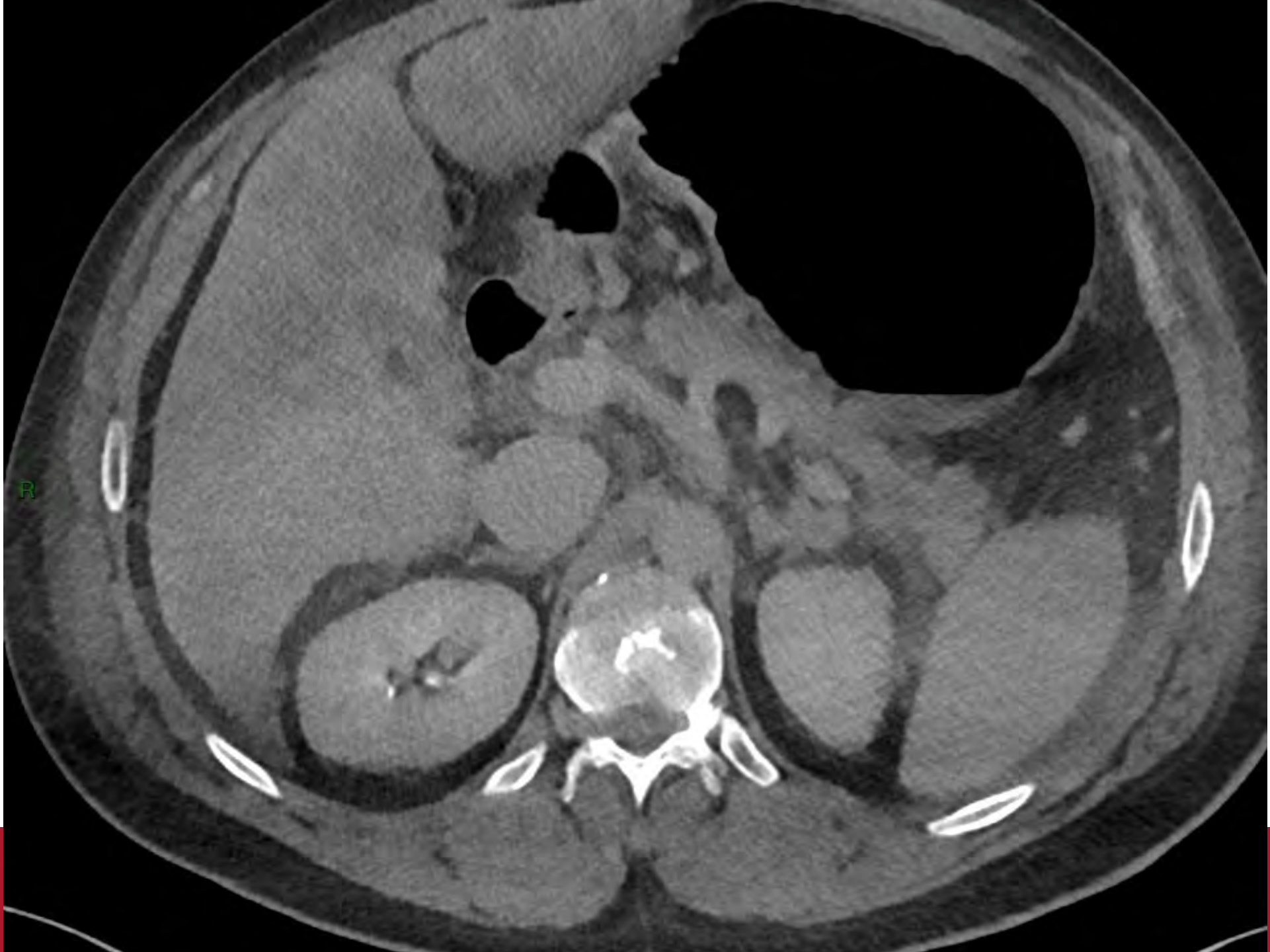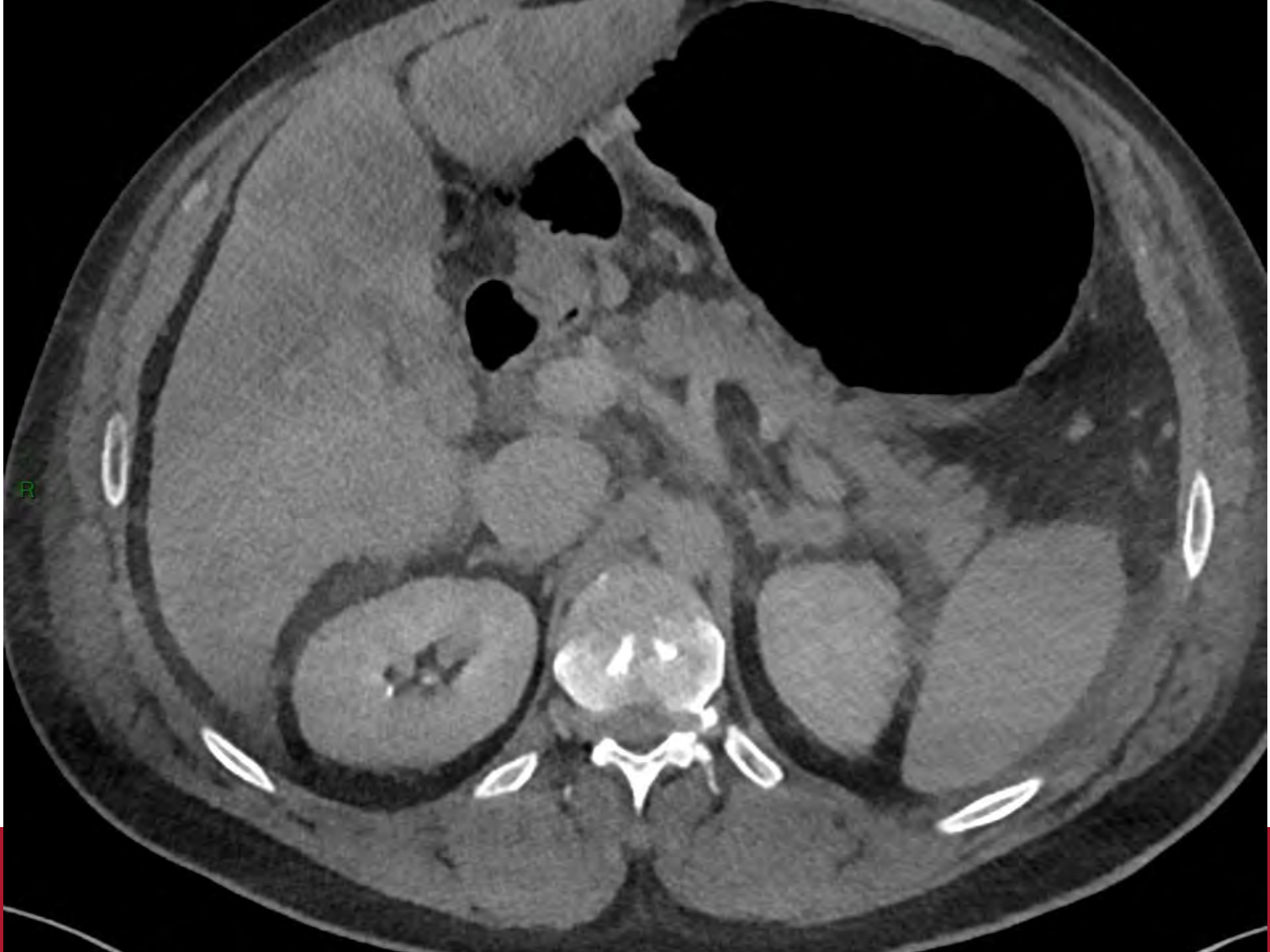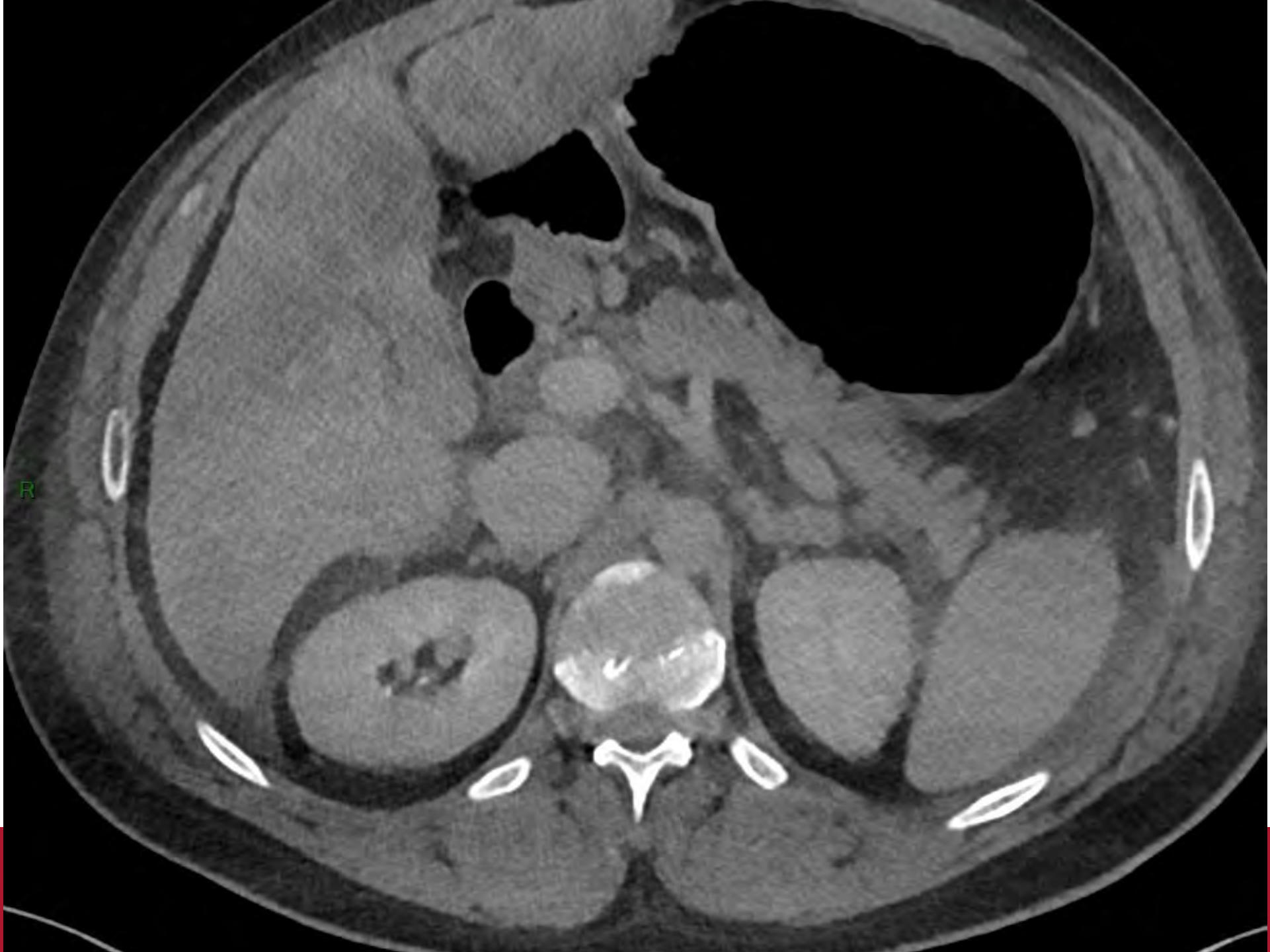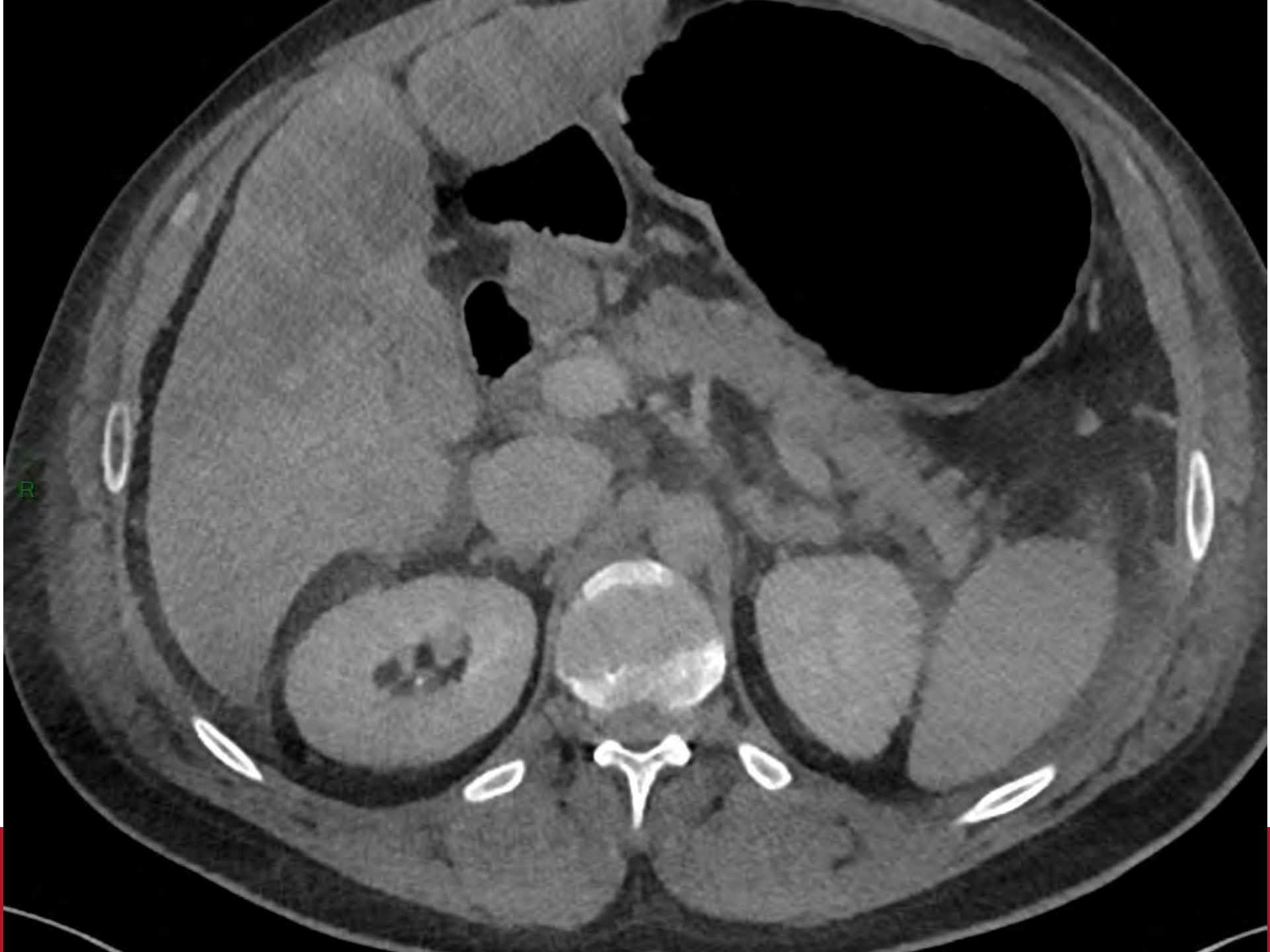


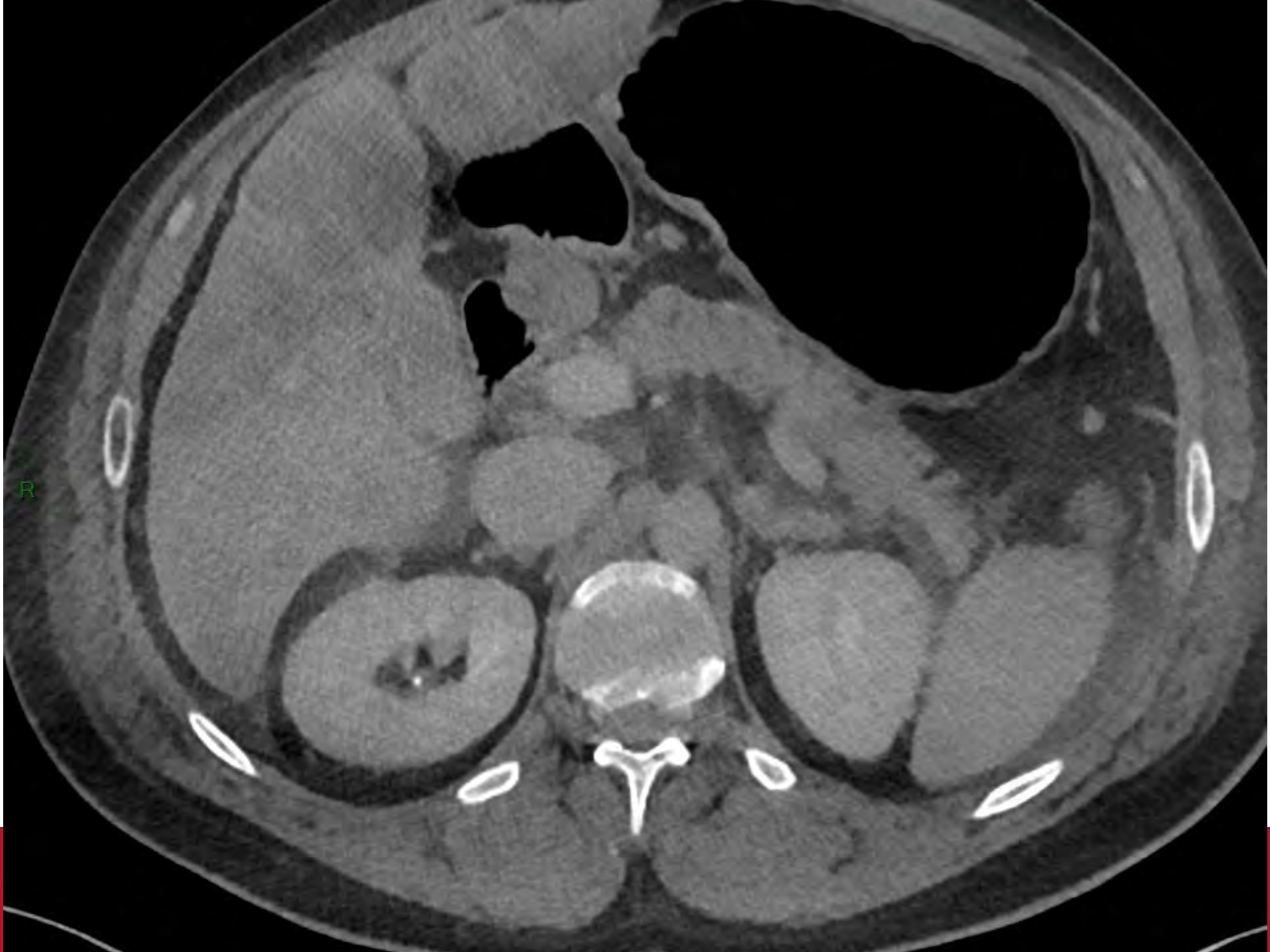


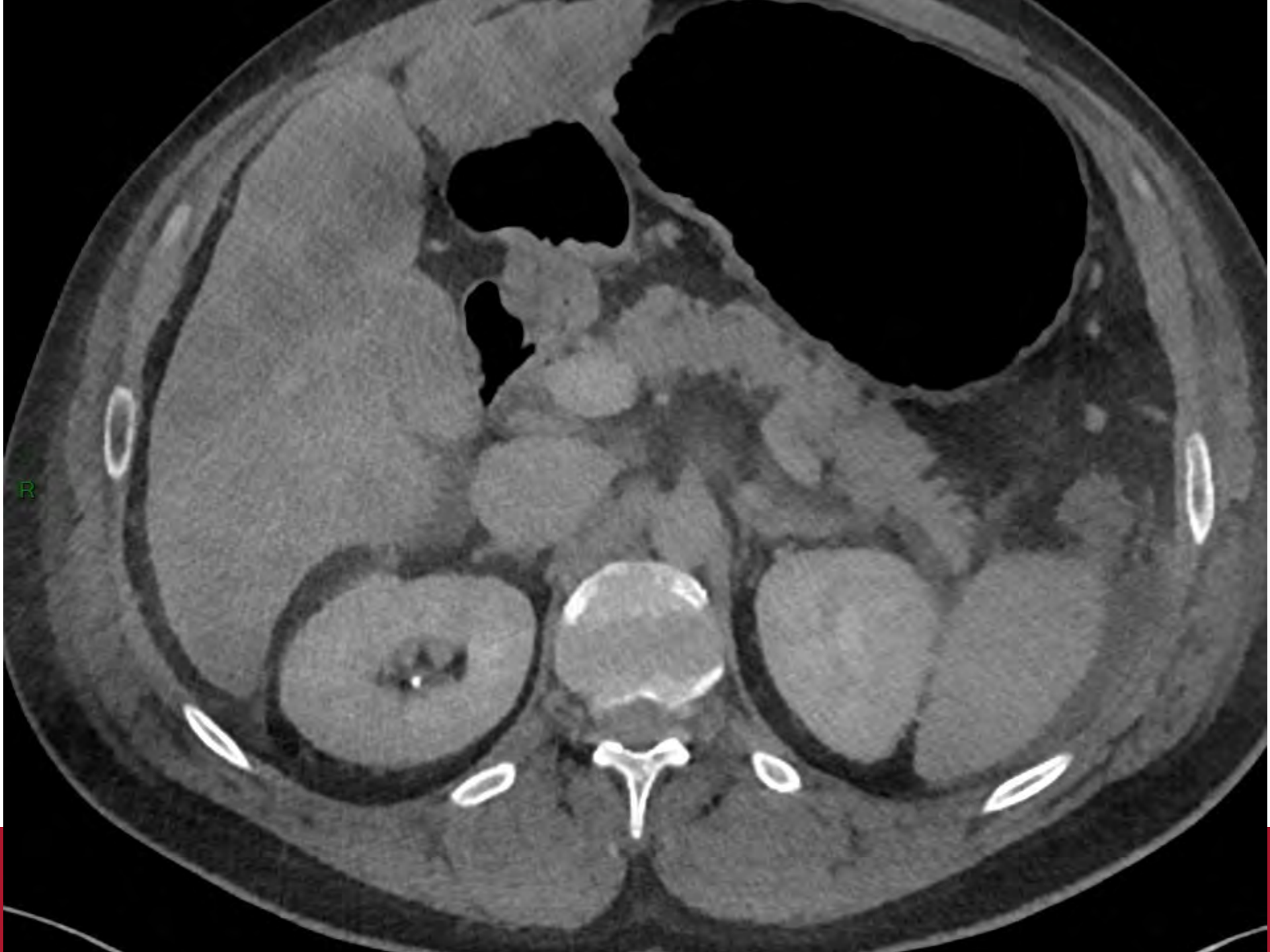












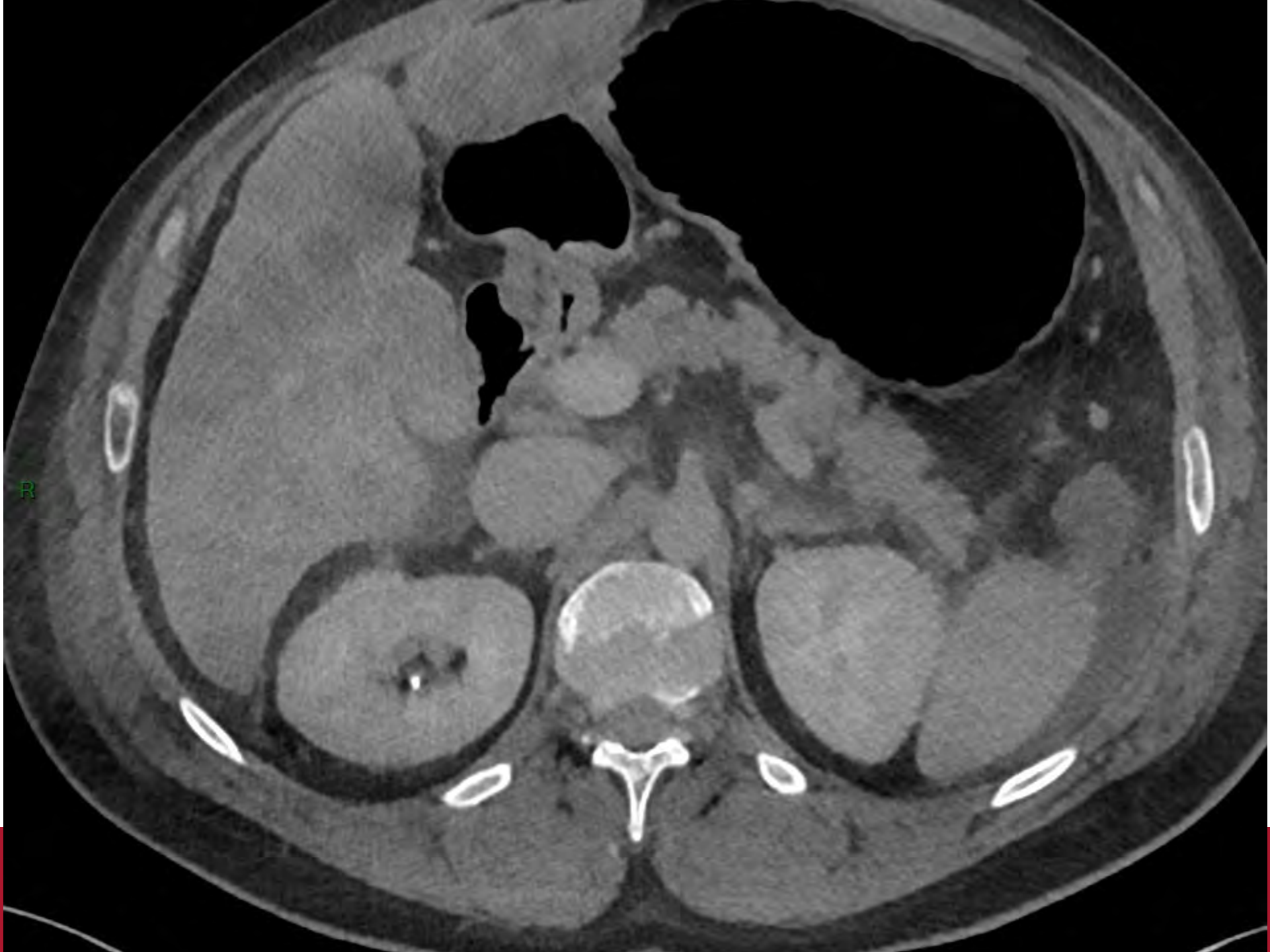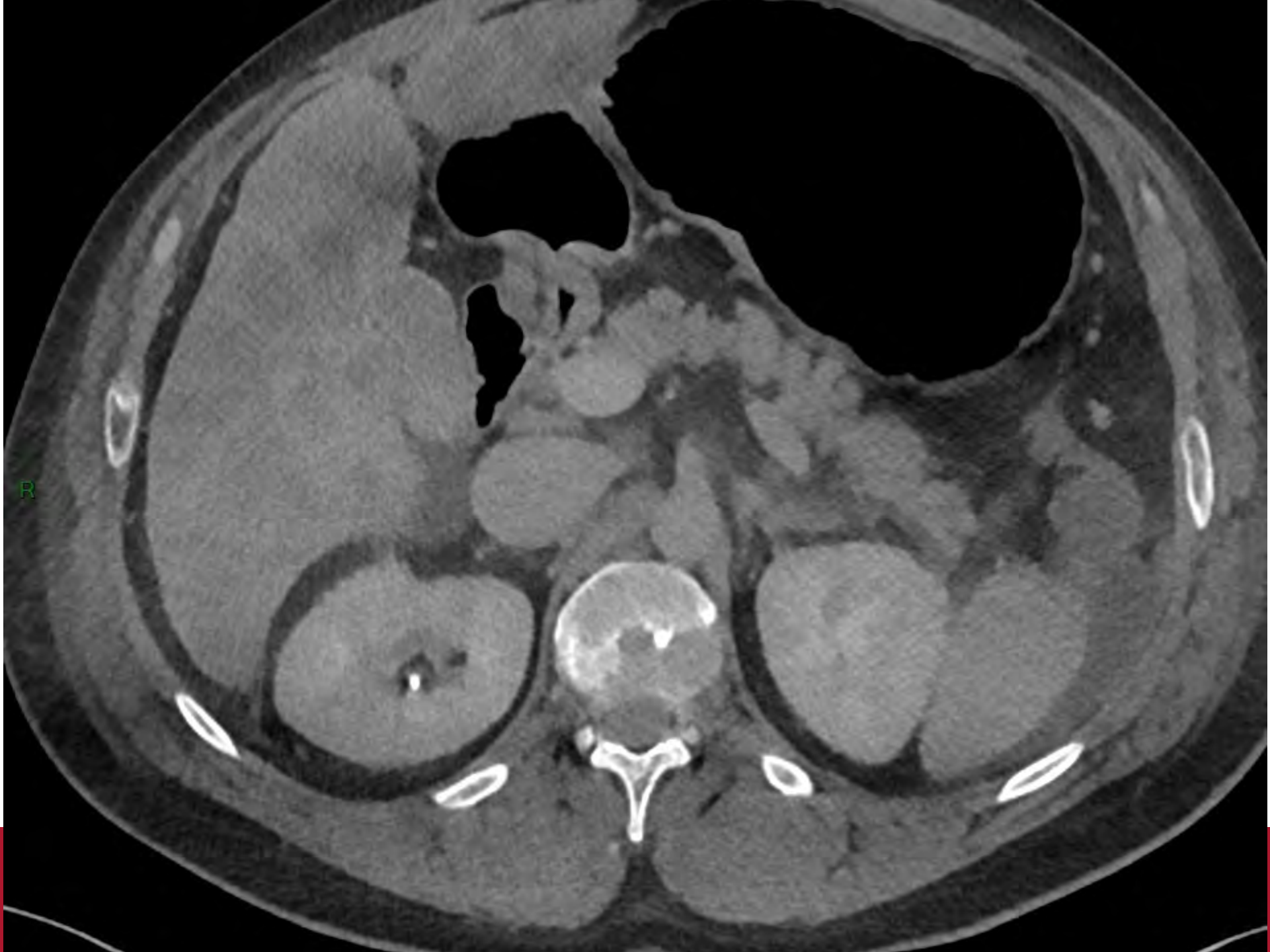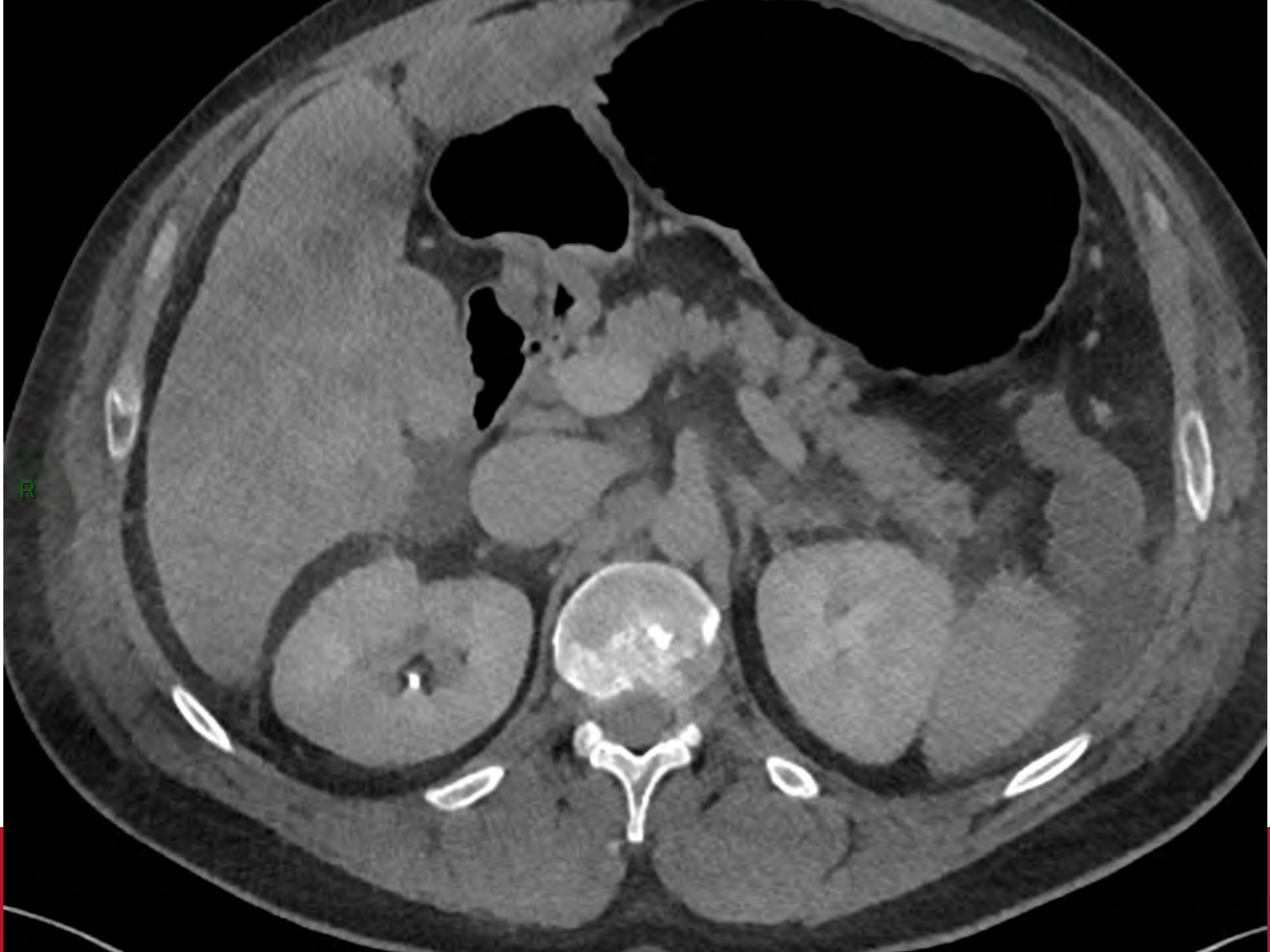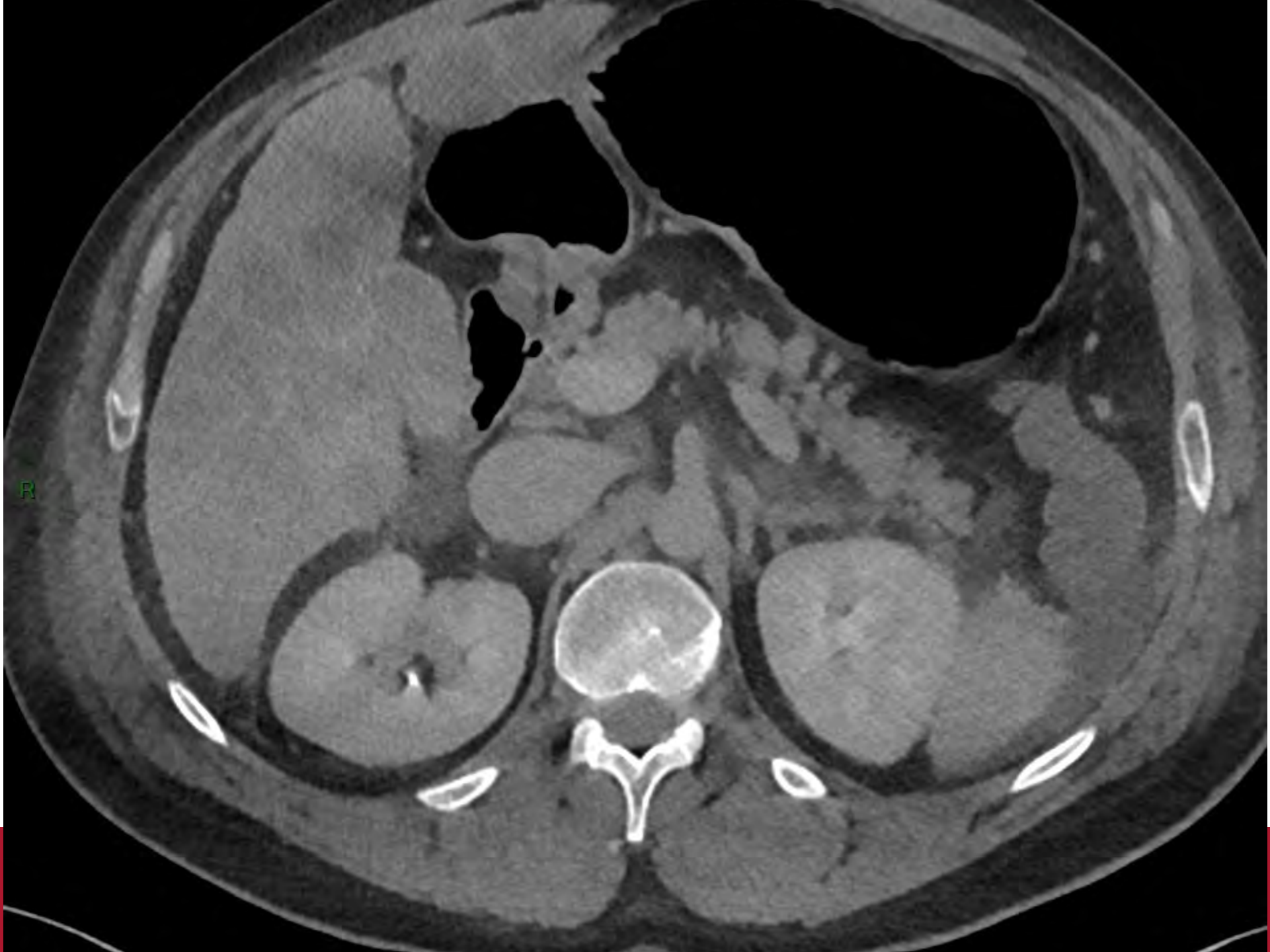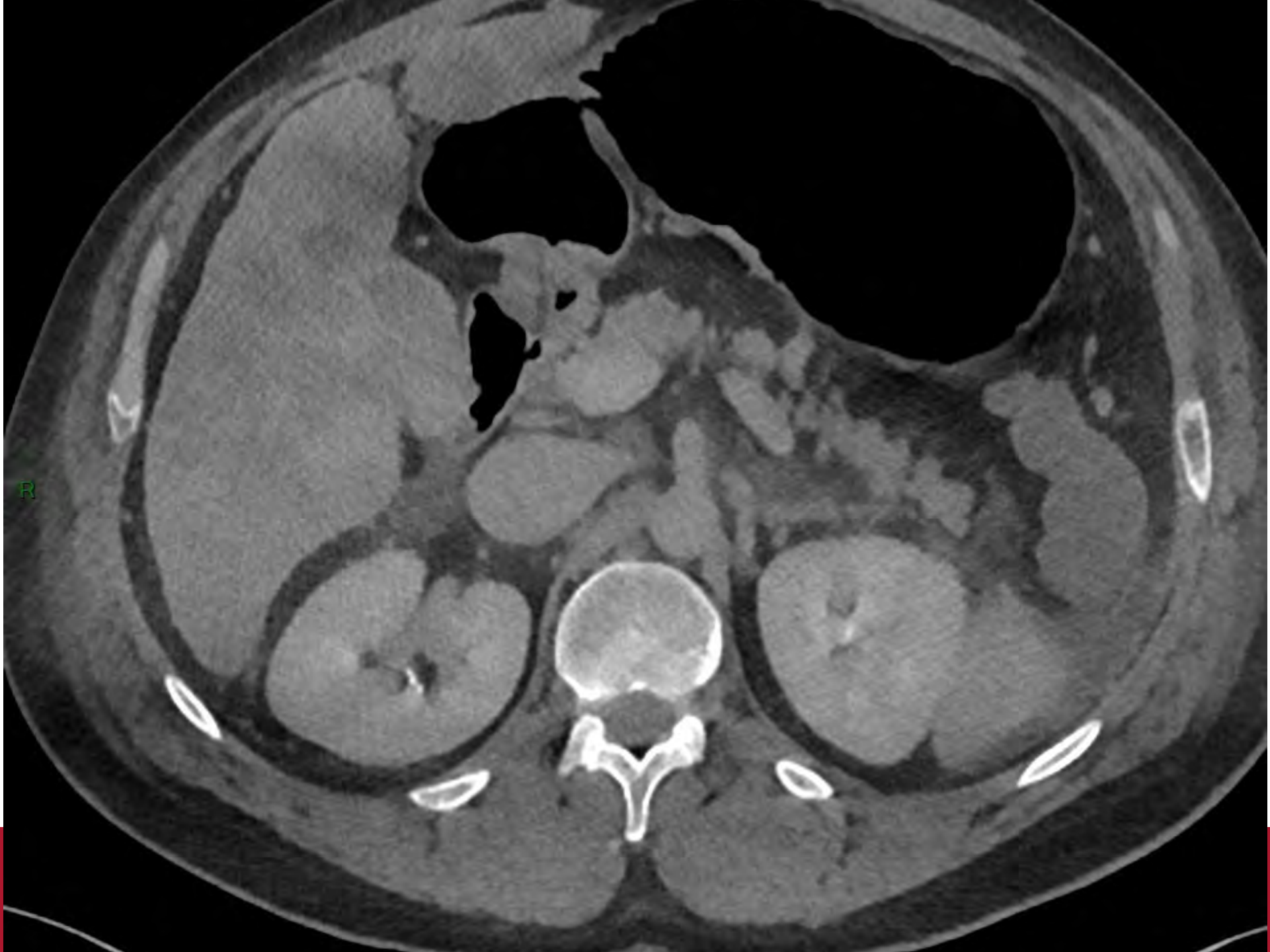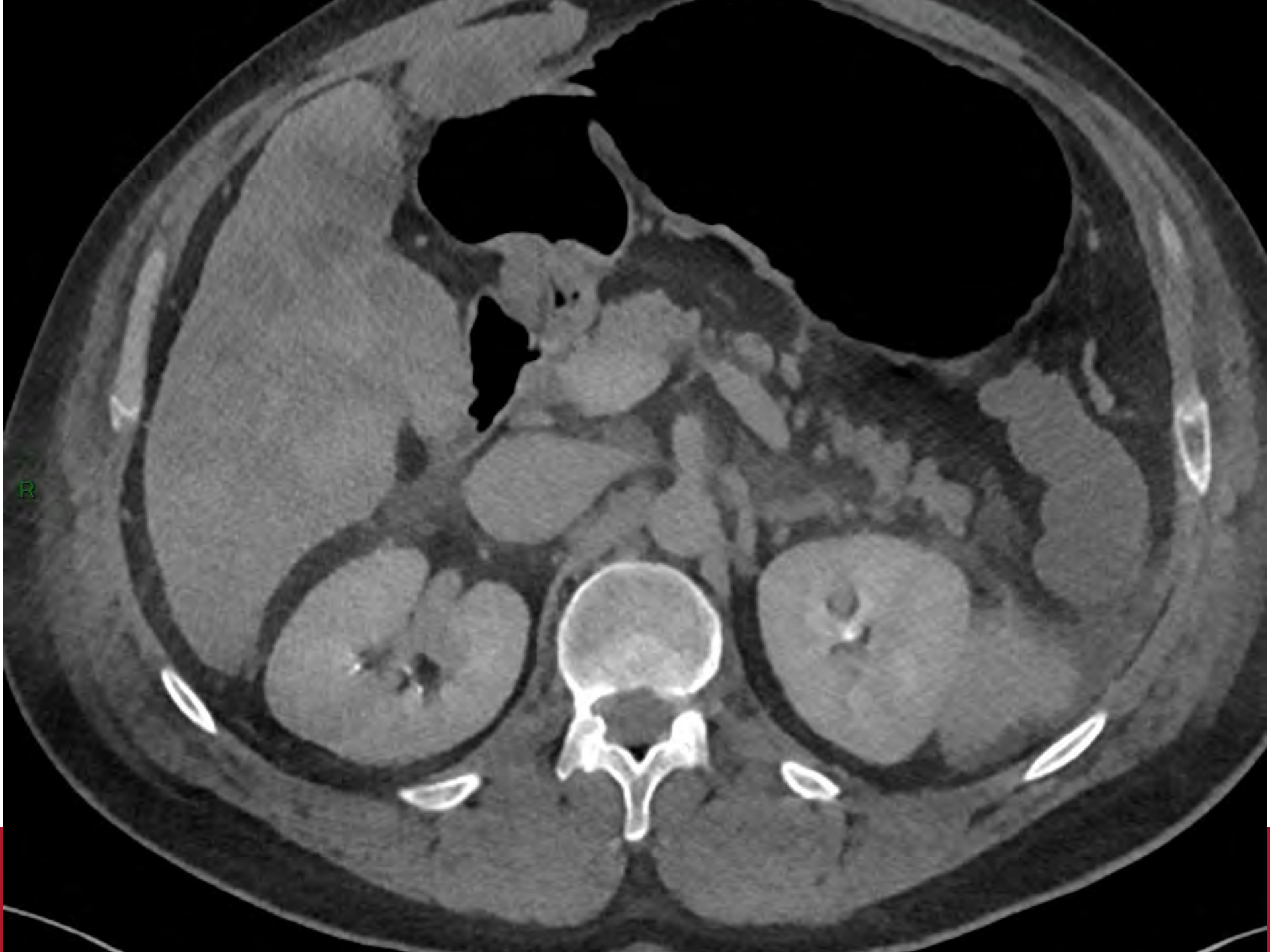


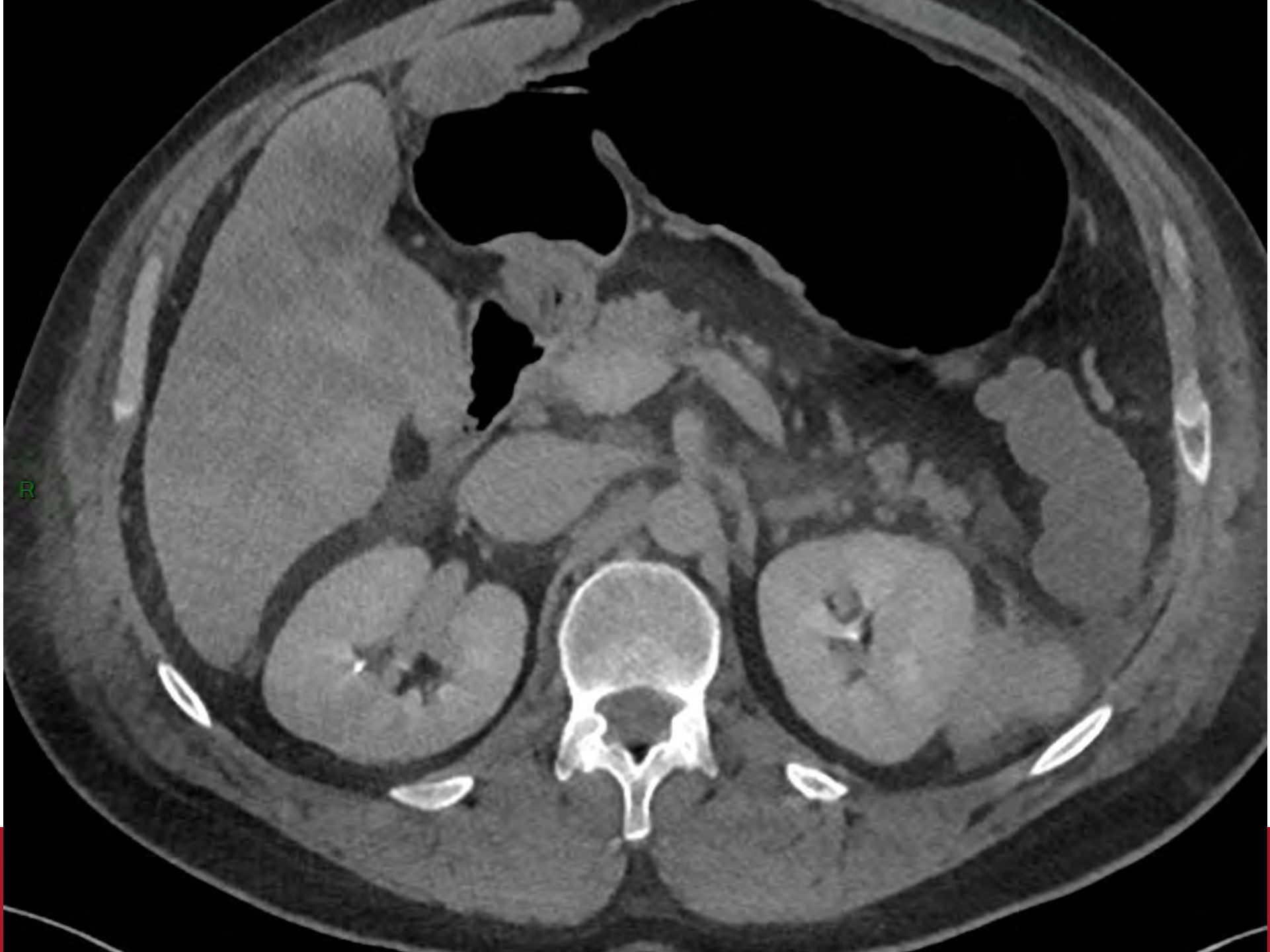


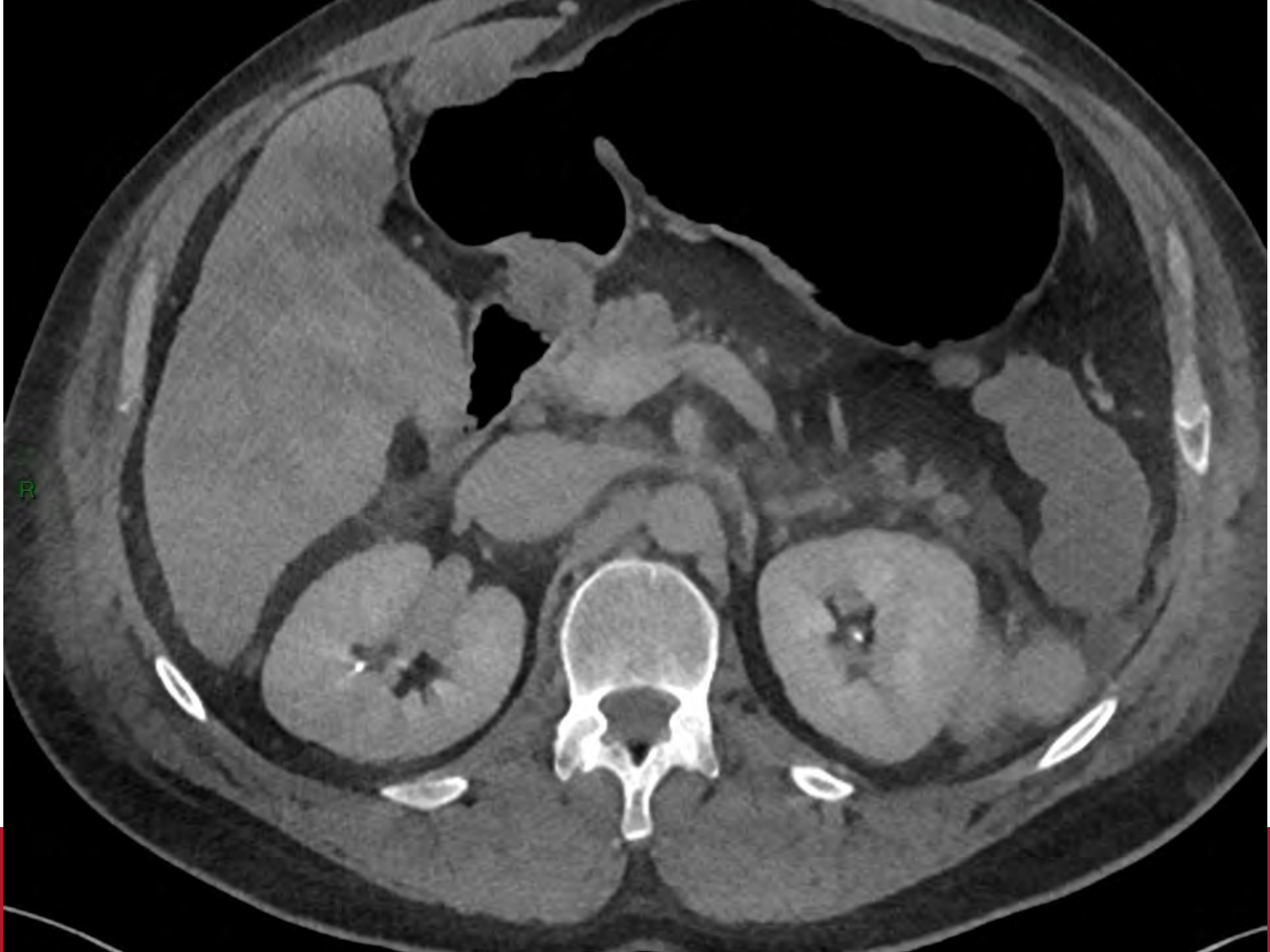


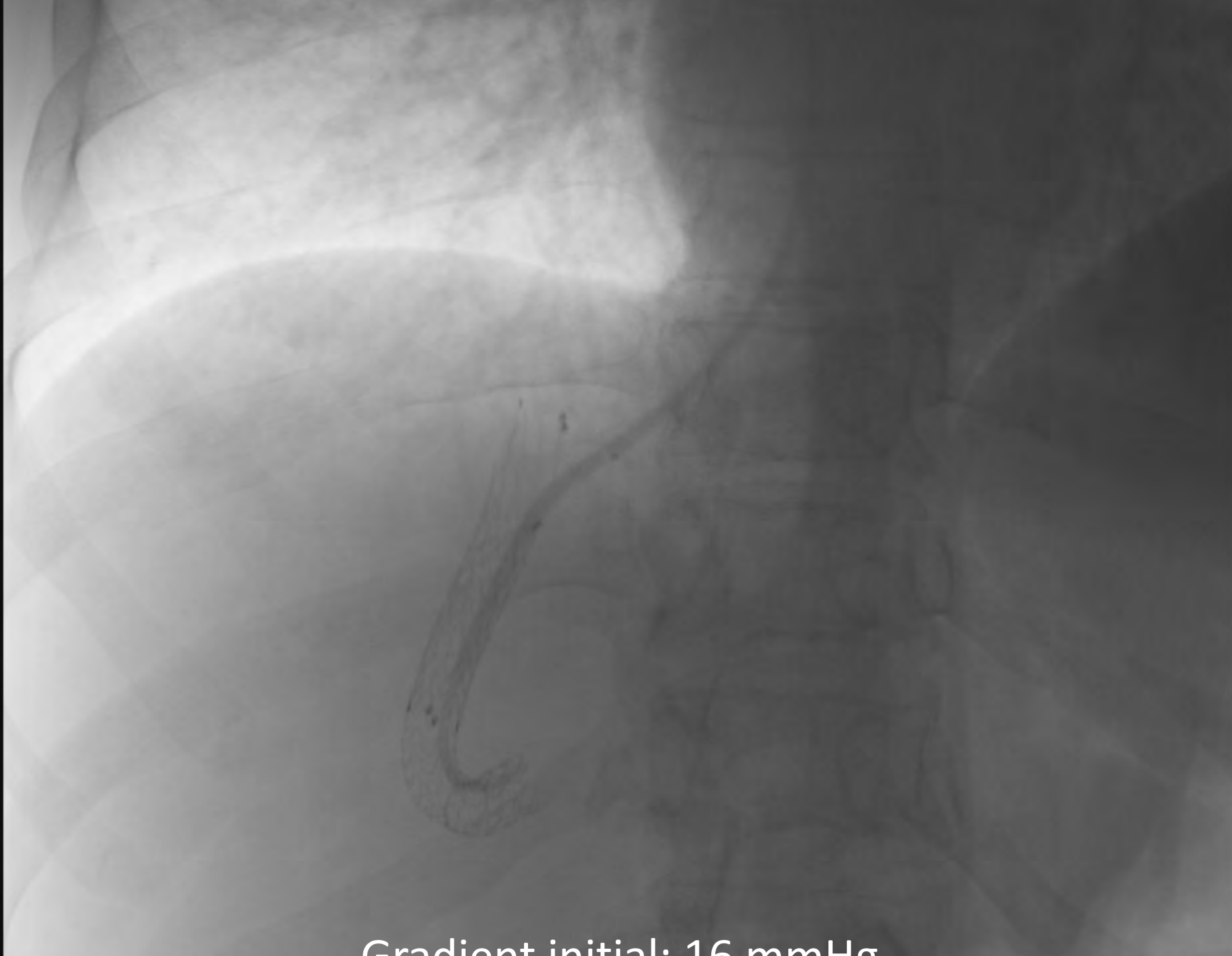












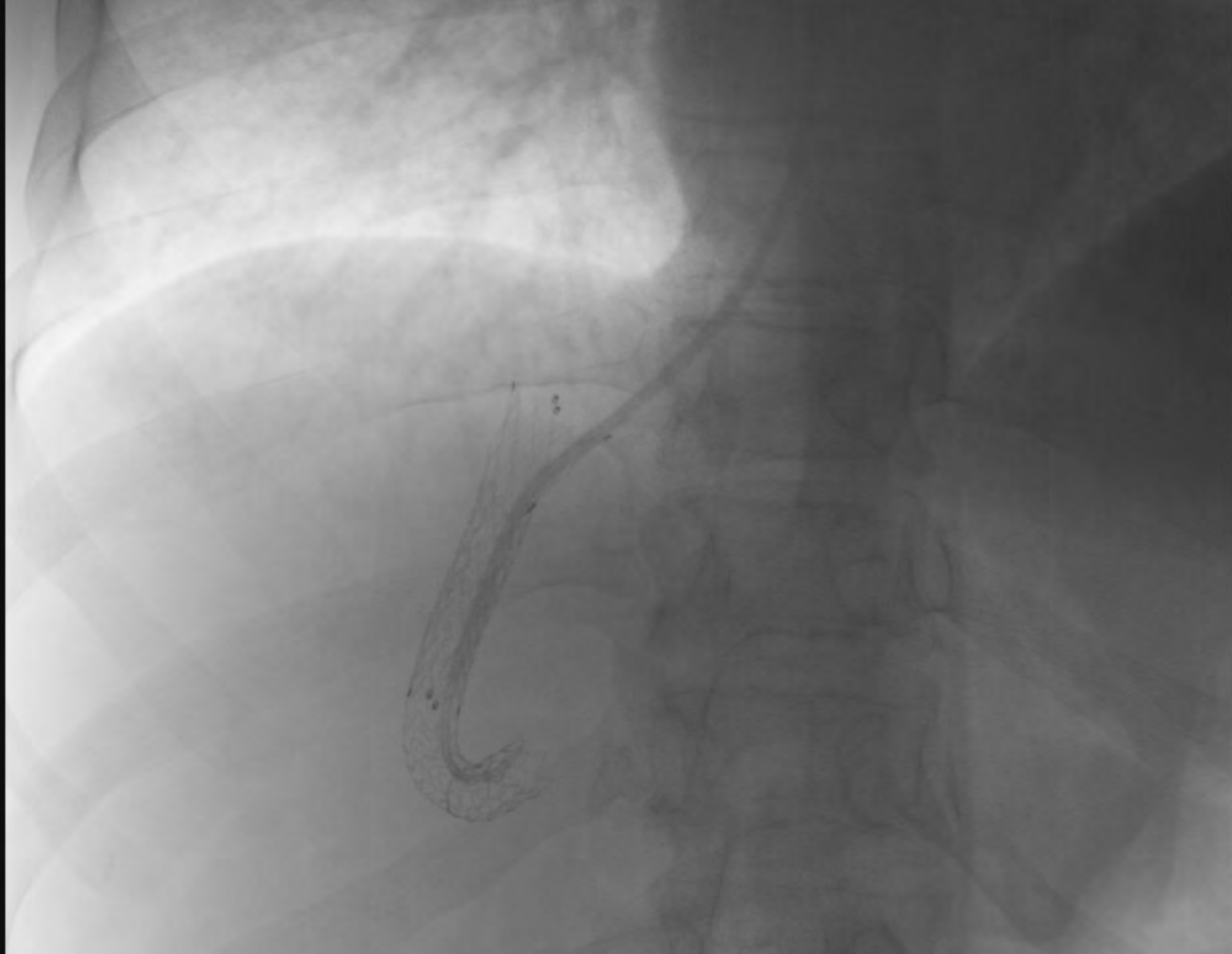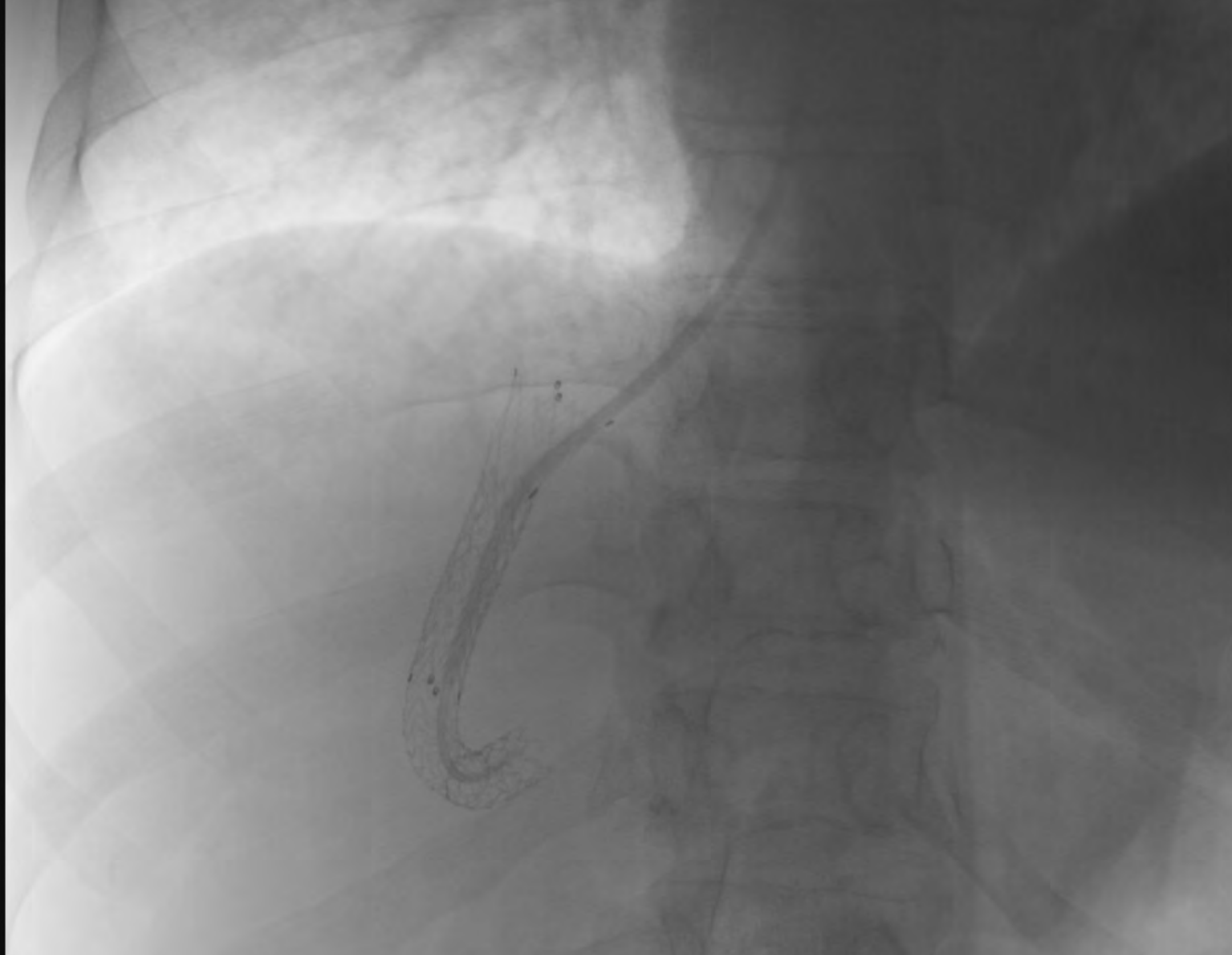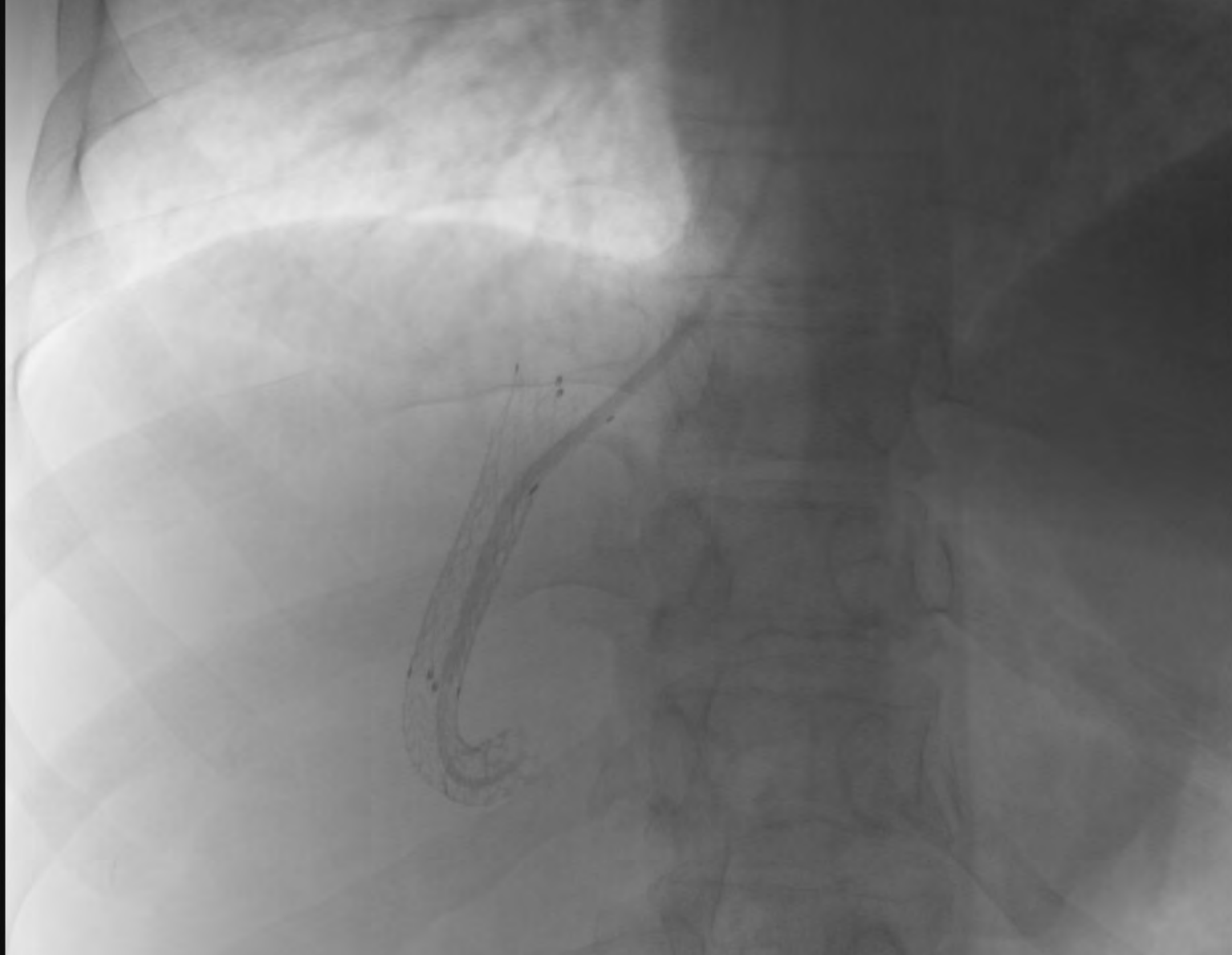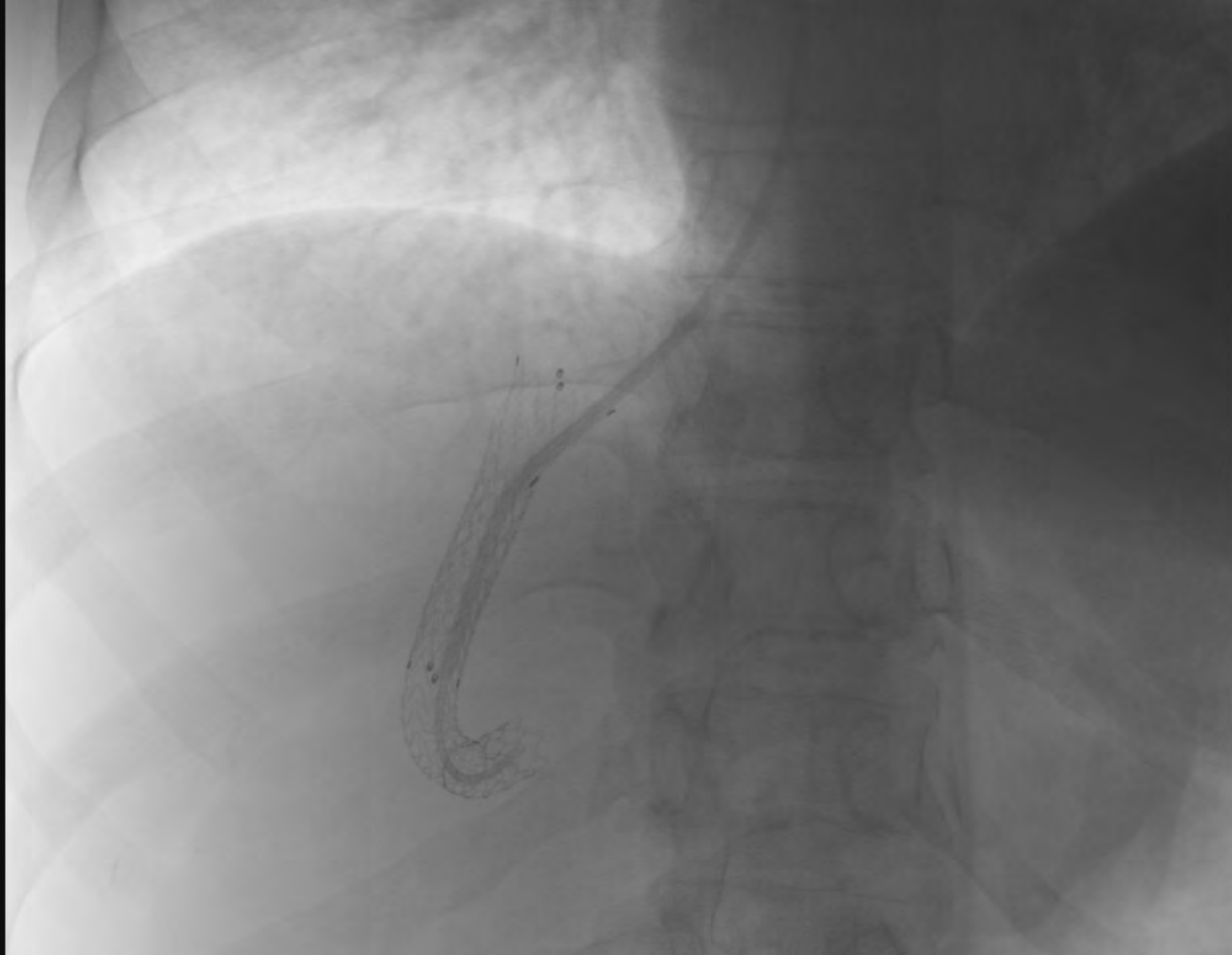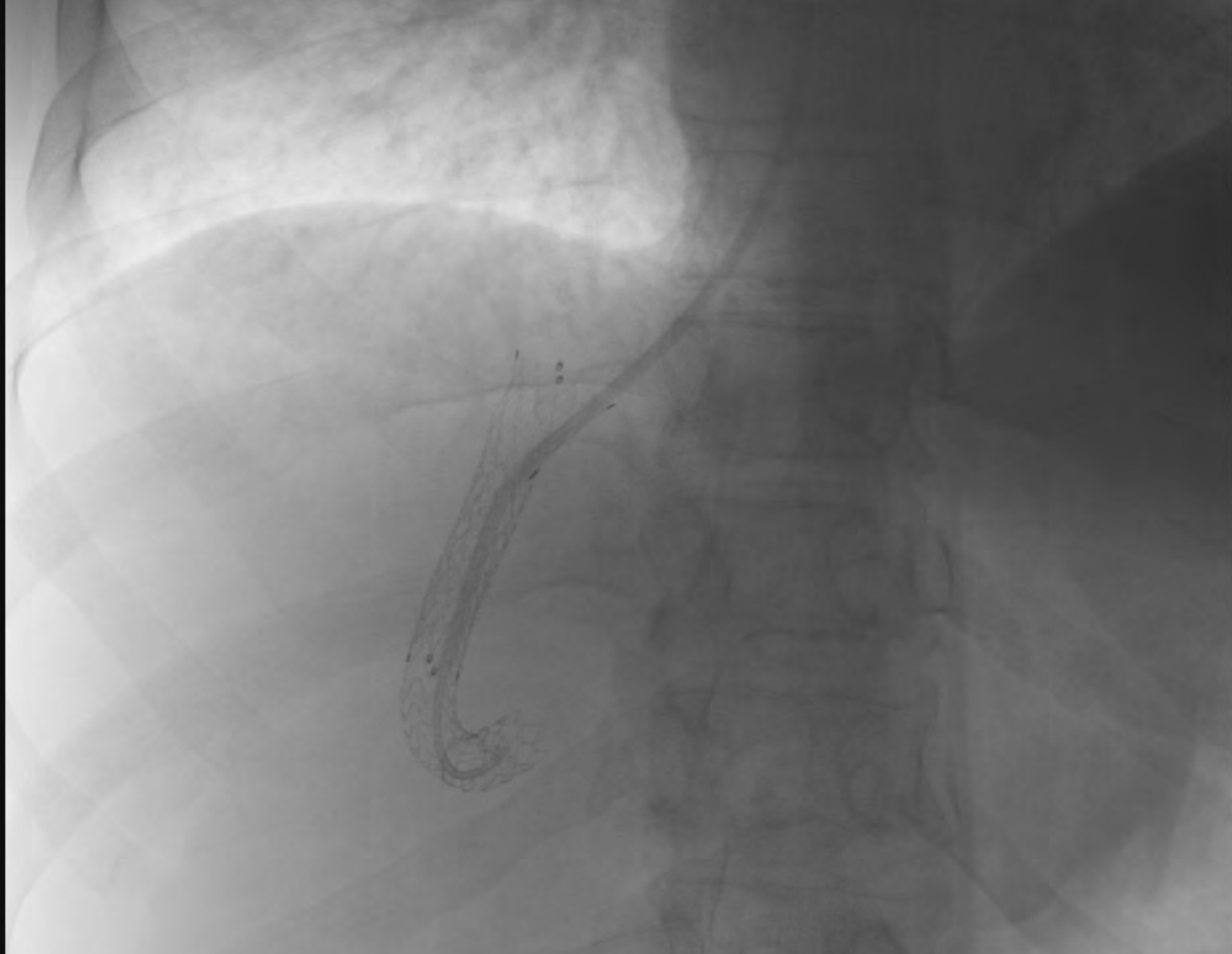Gradient initial: 16 mmHg

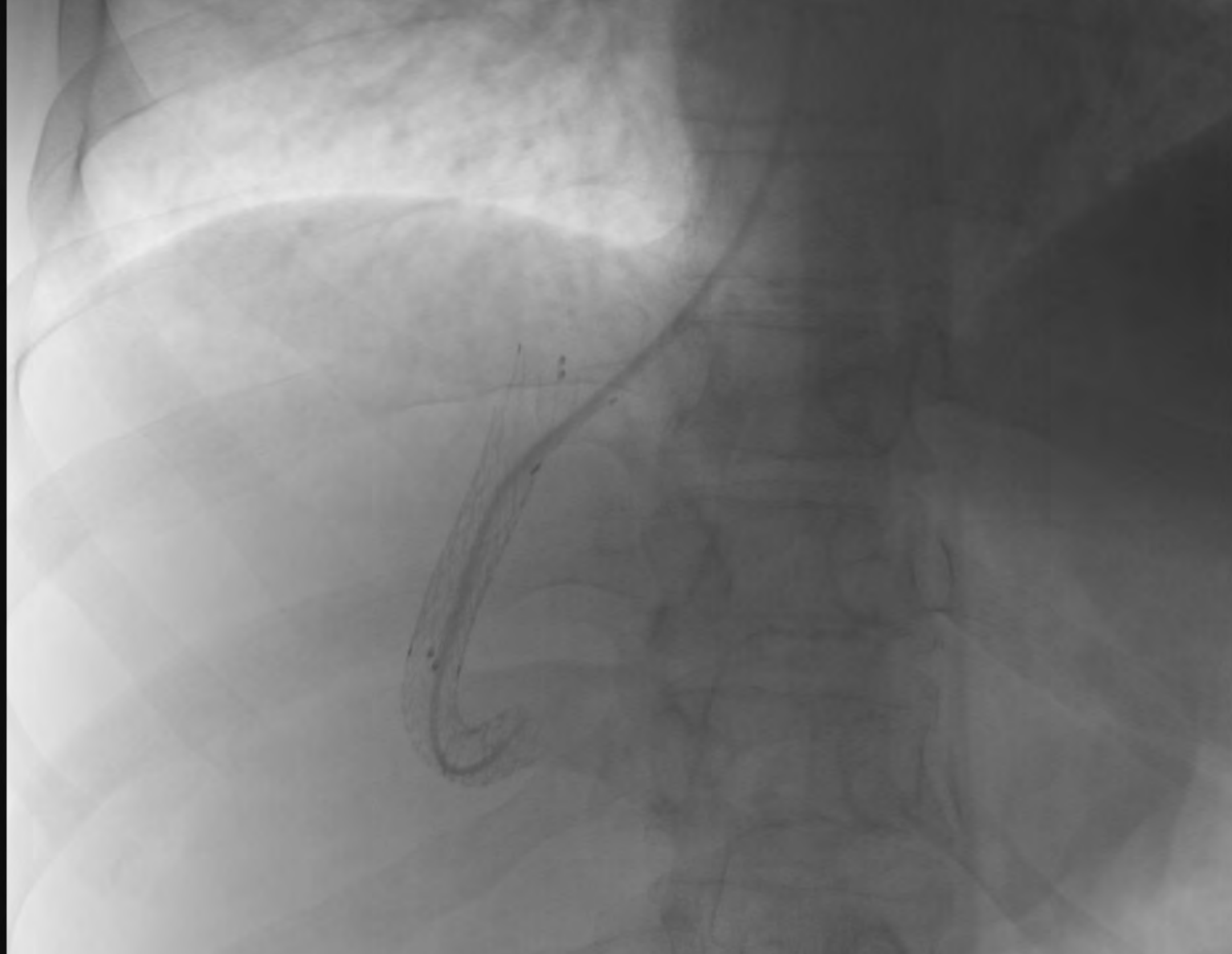

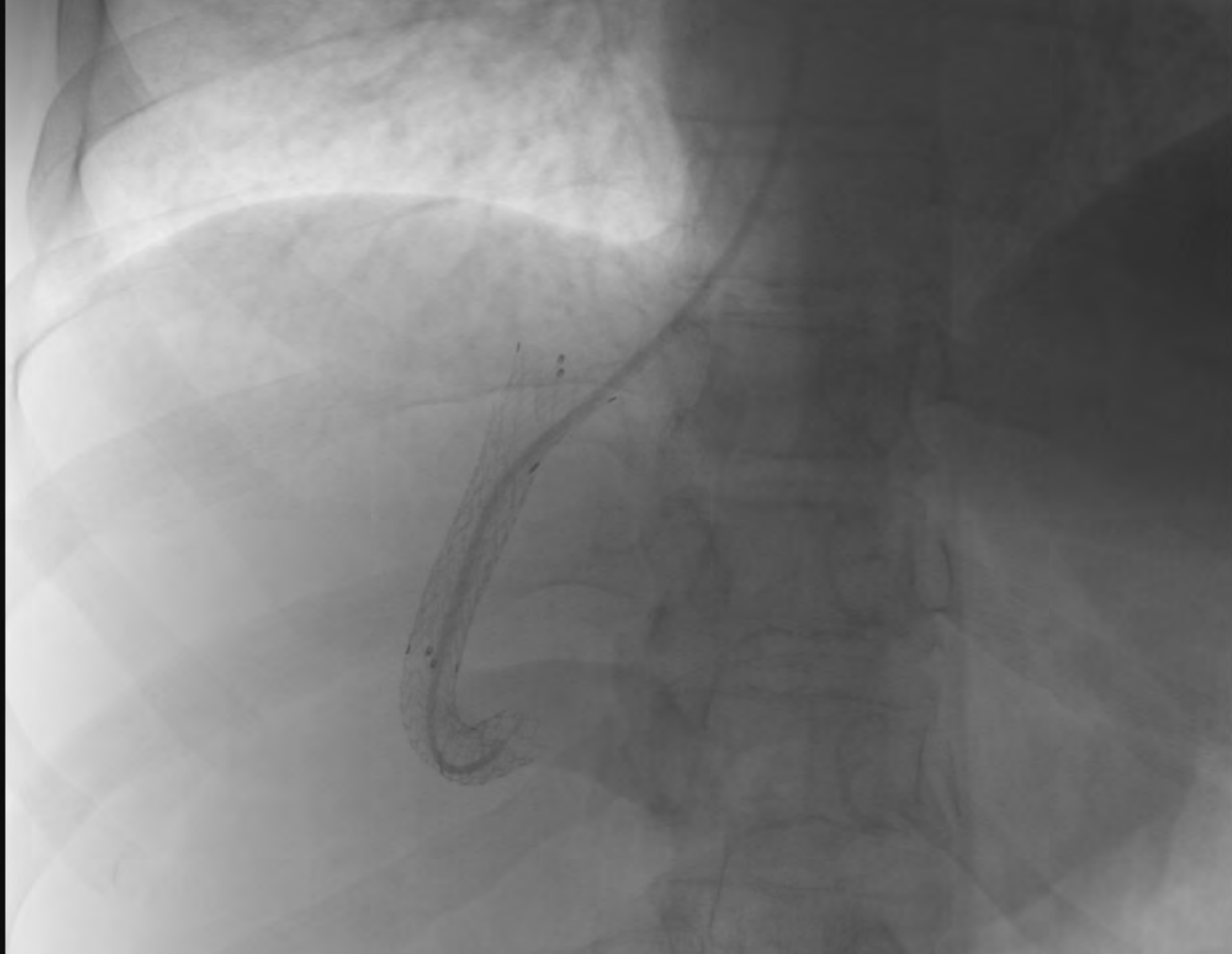



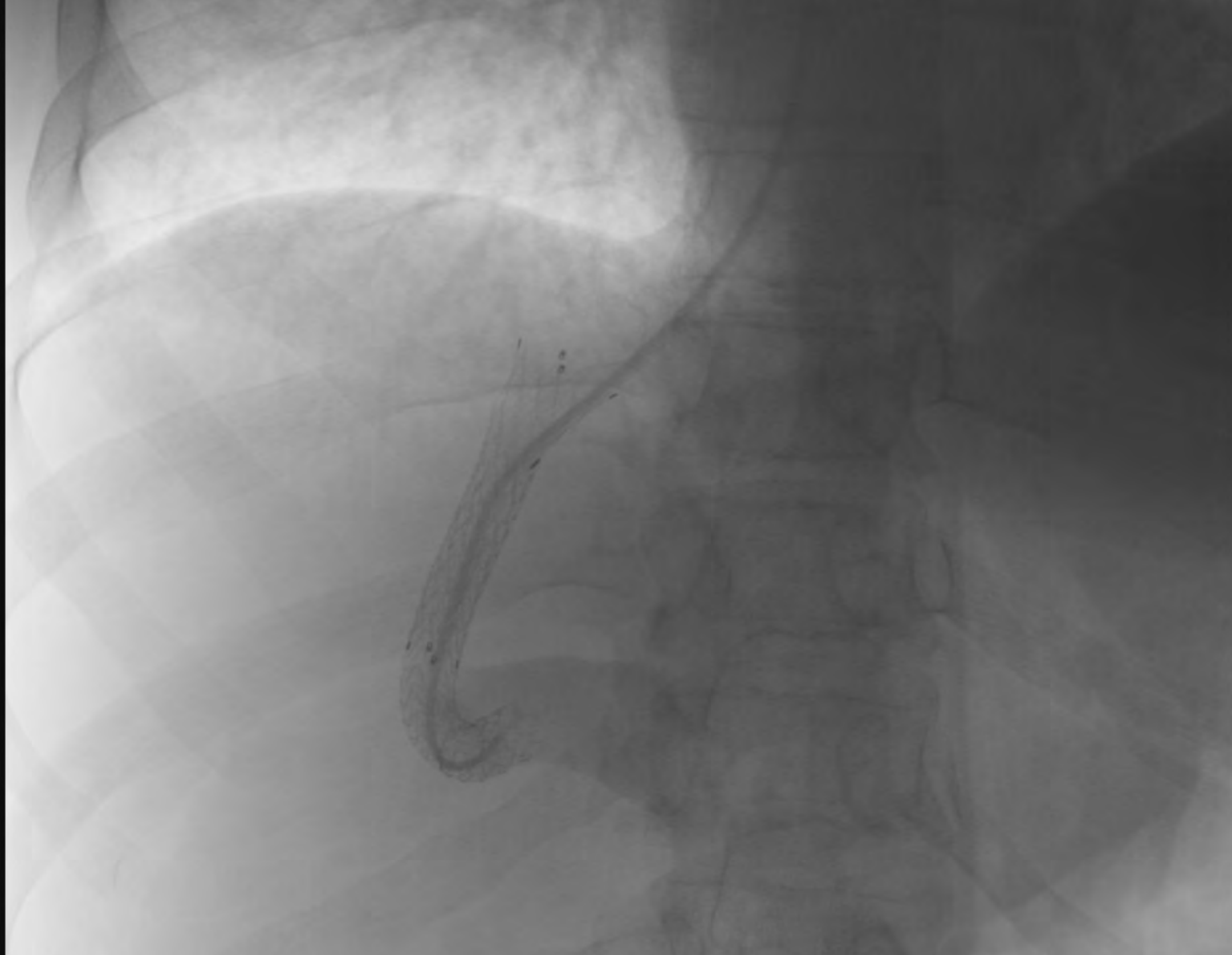


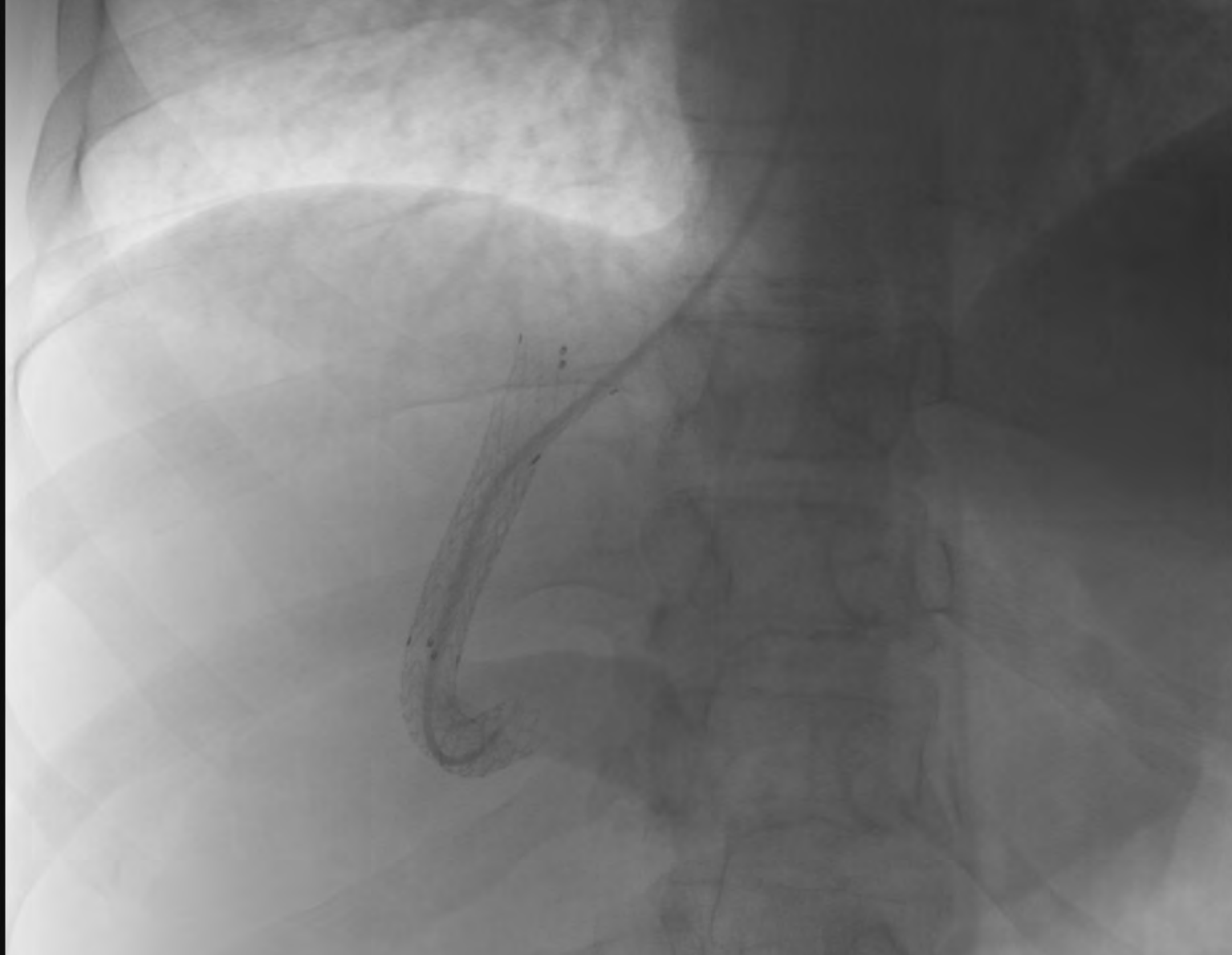


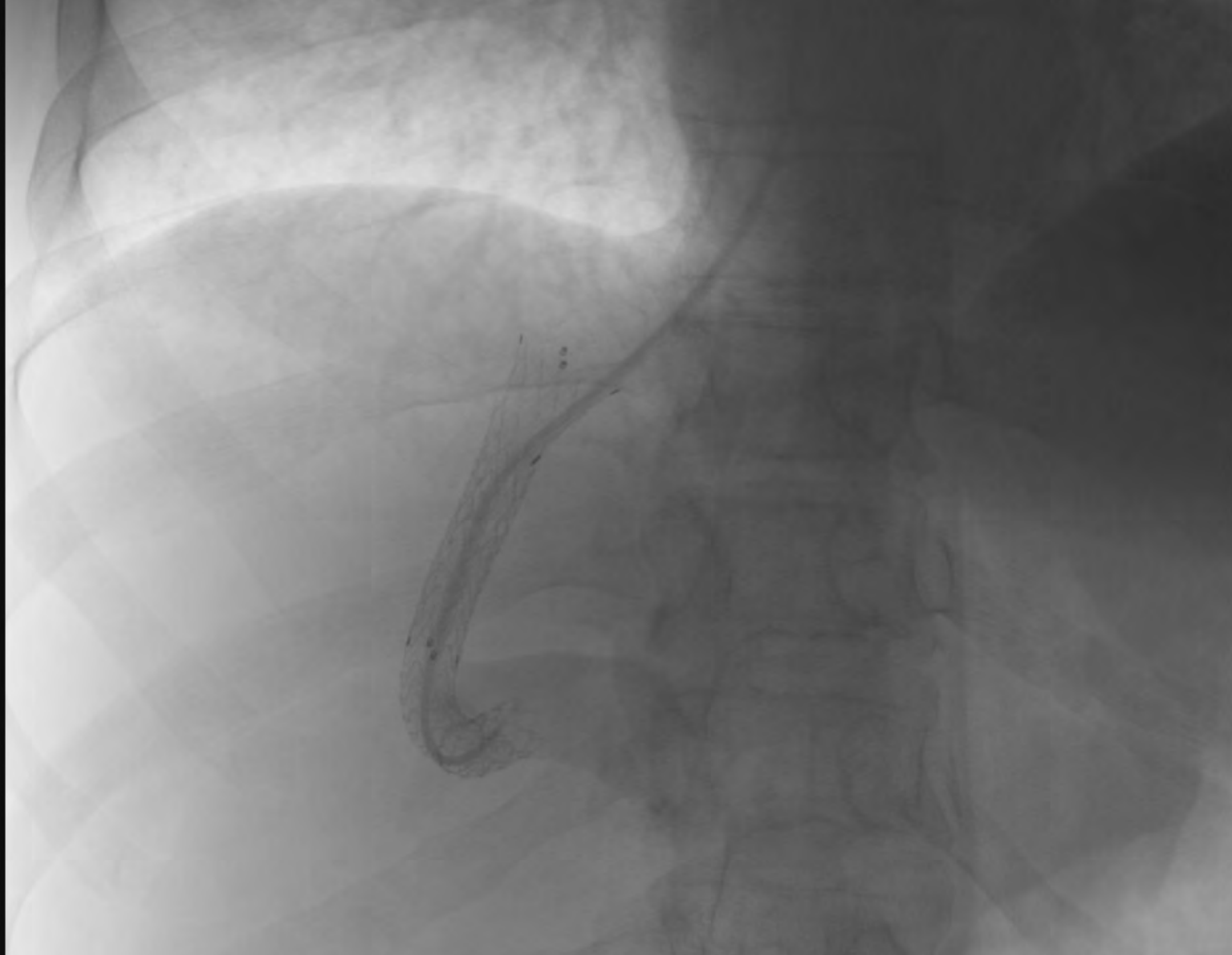


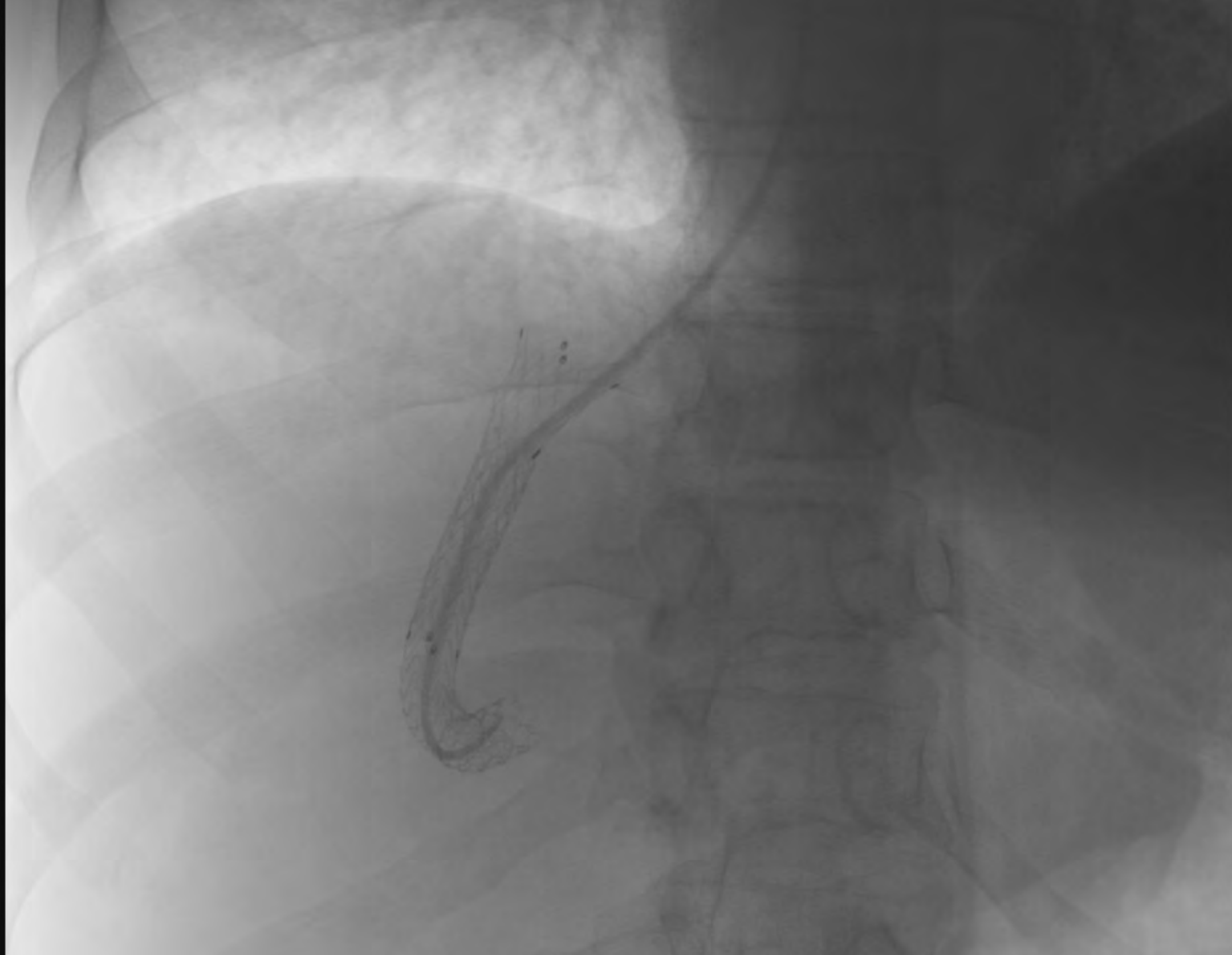


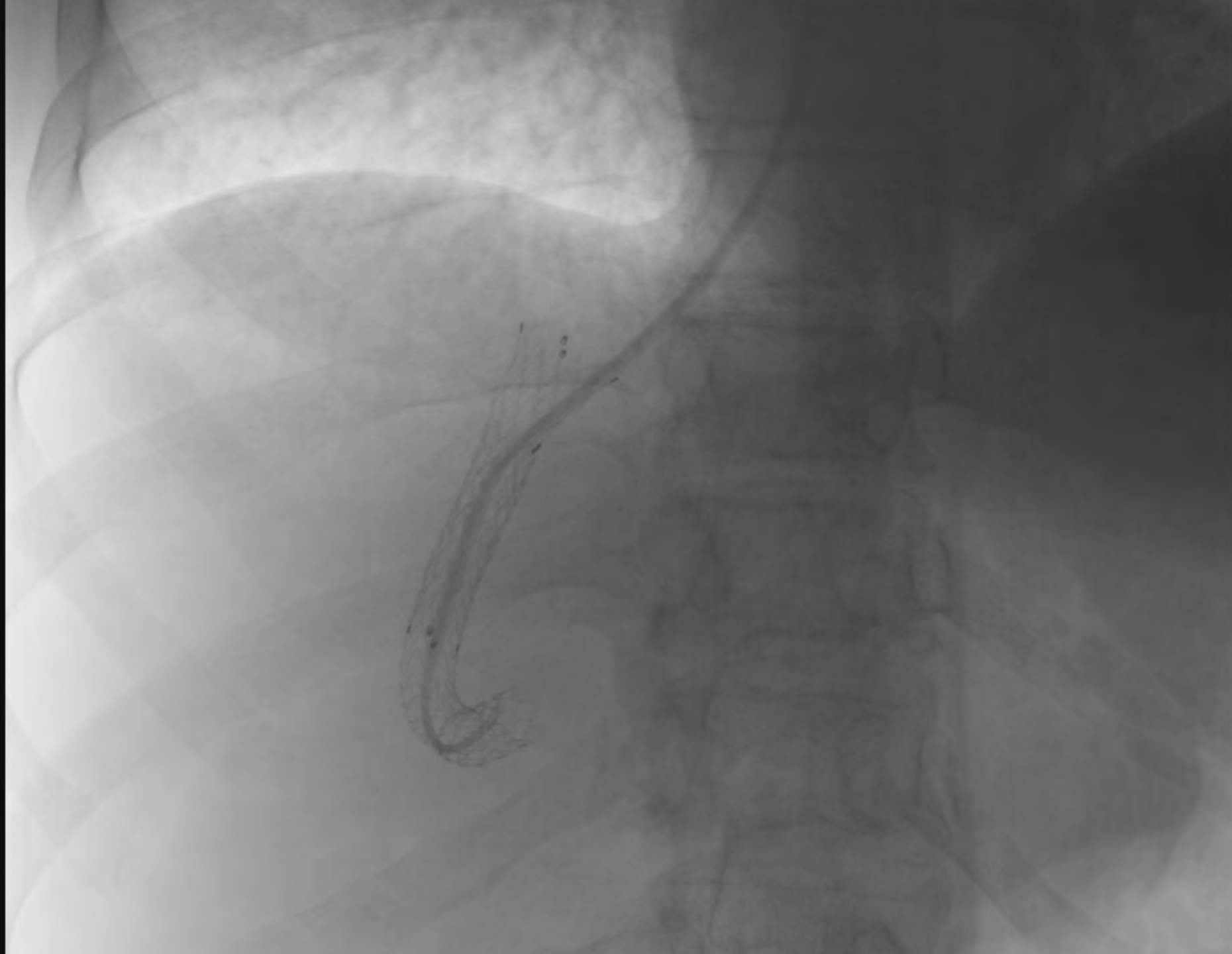


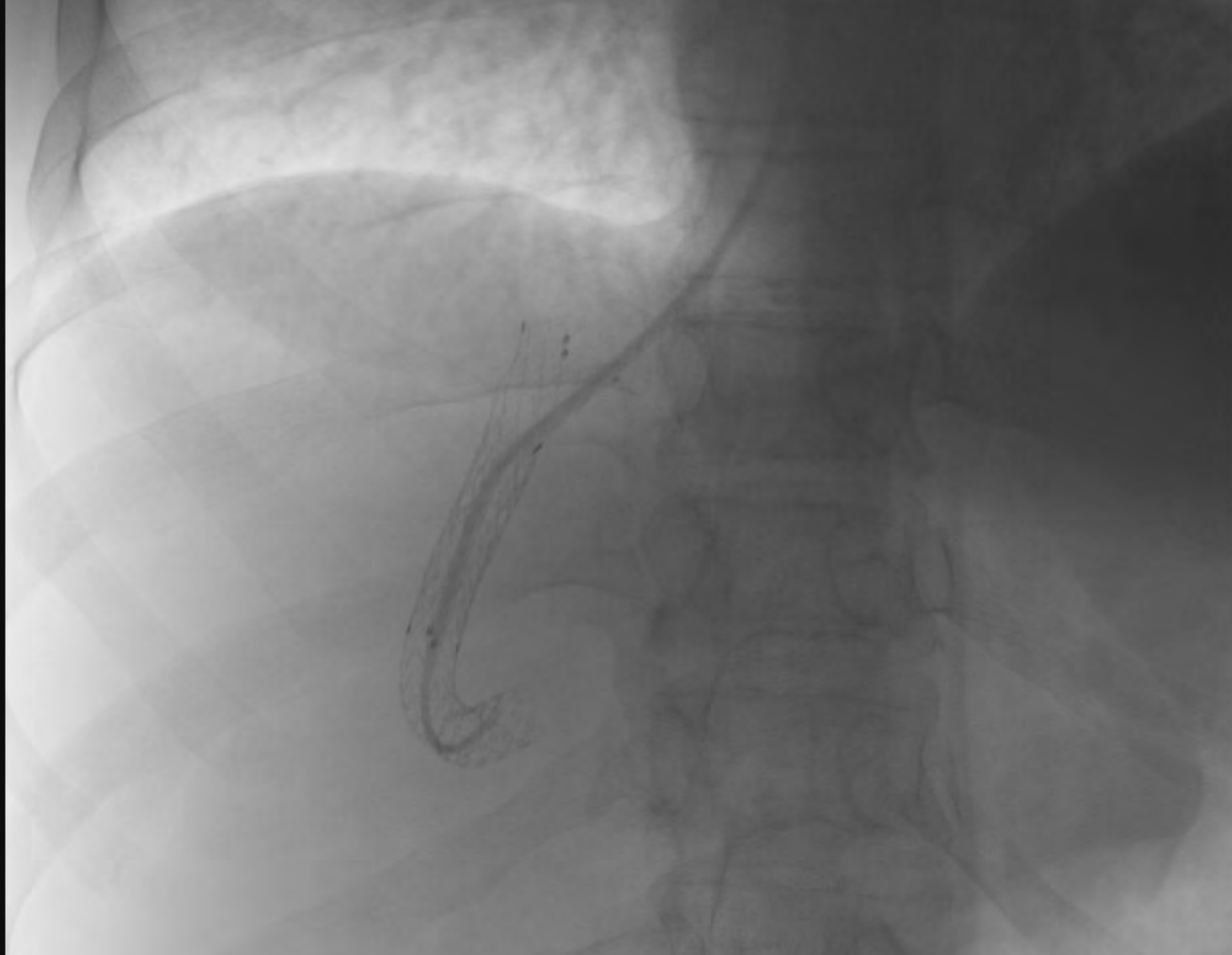


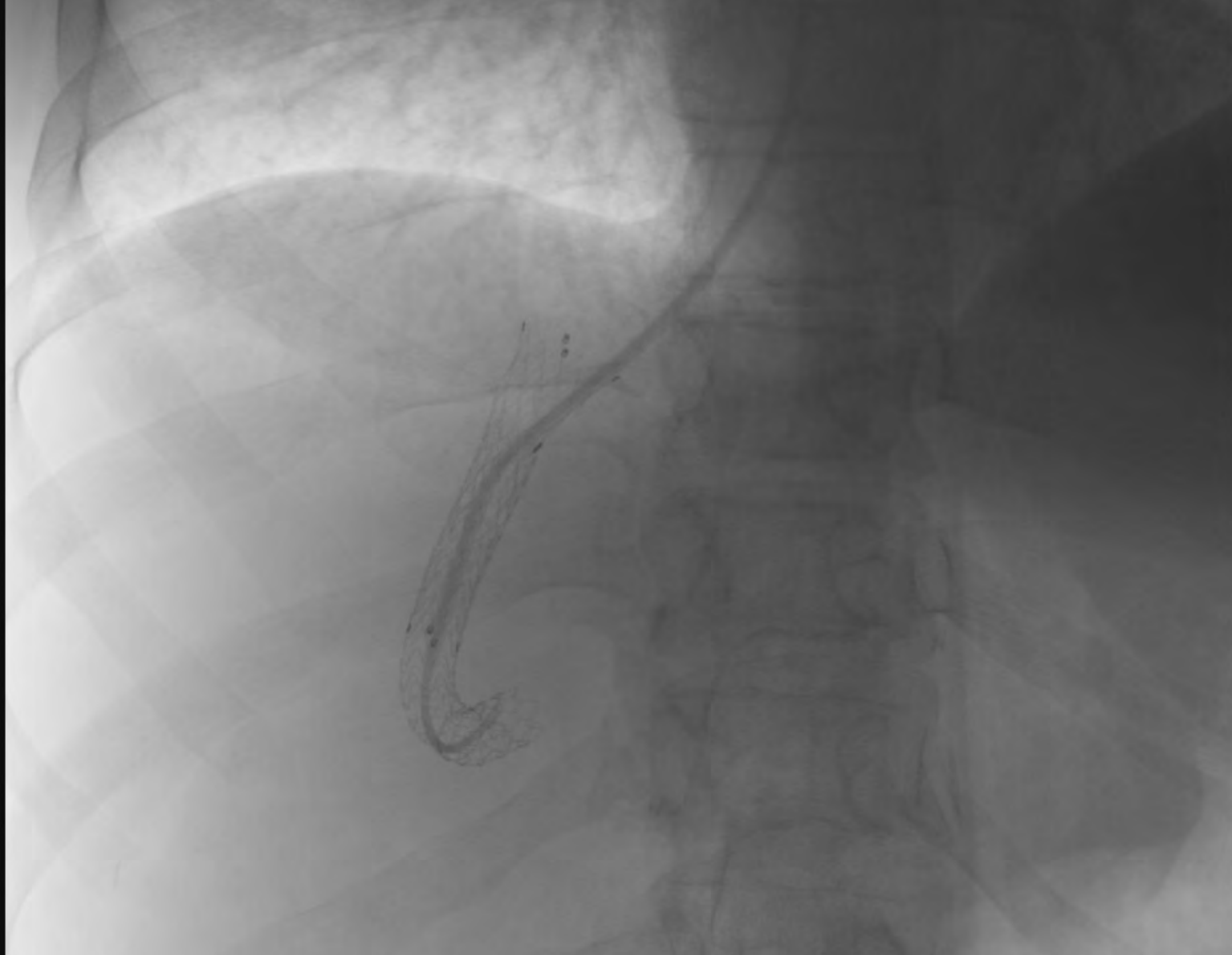


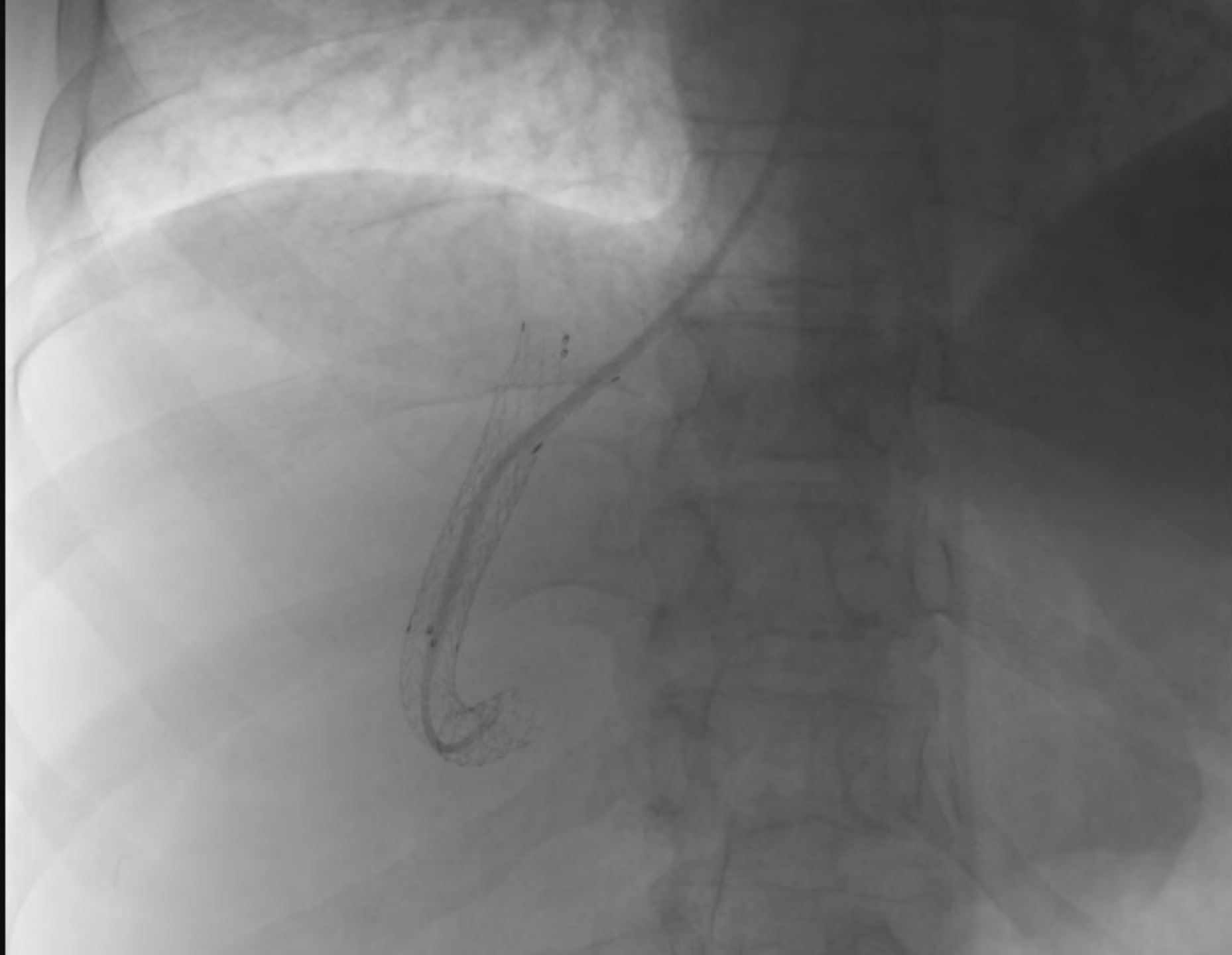


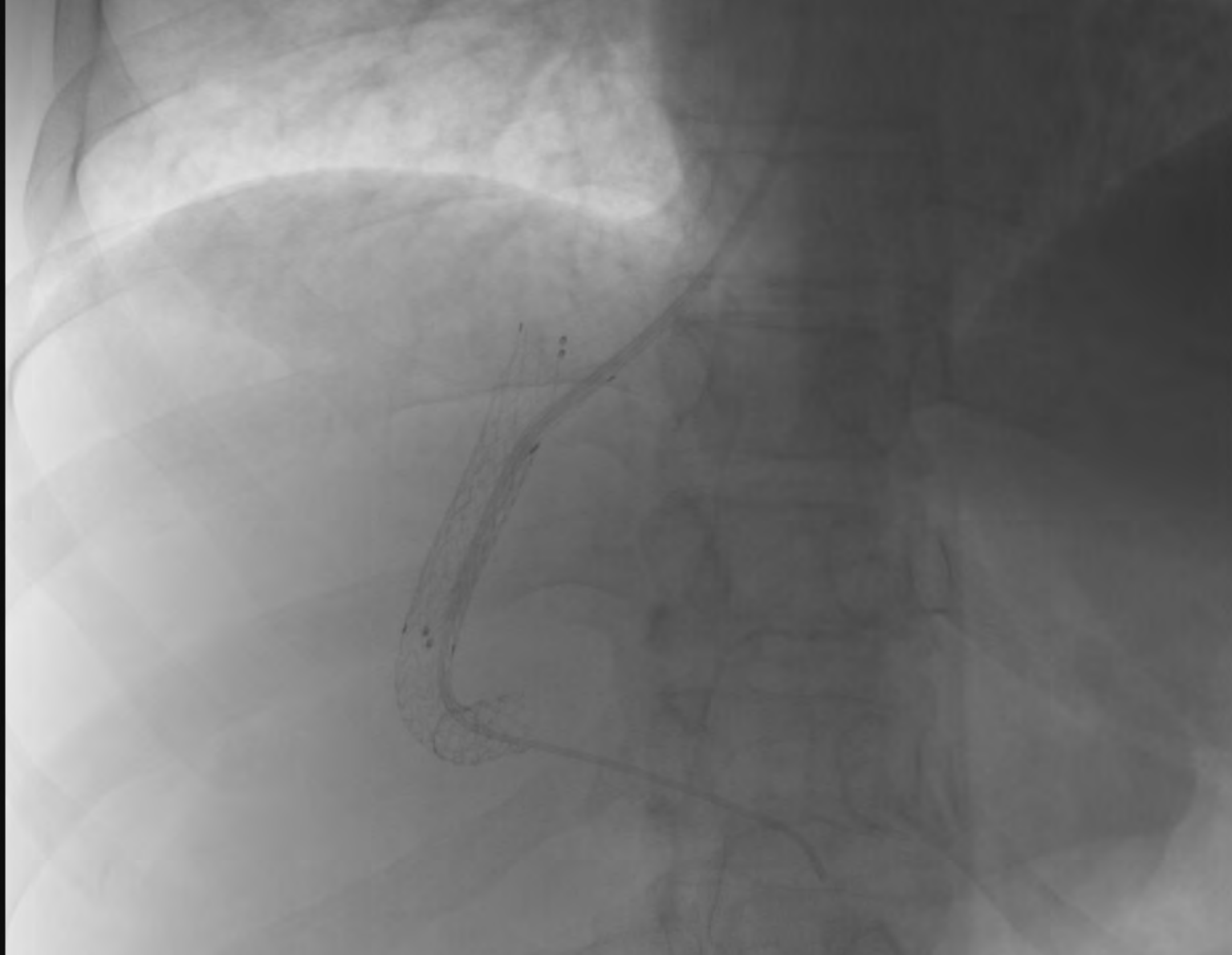


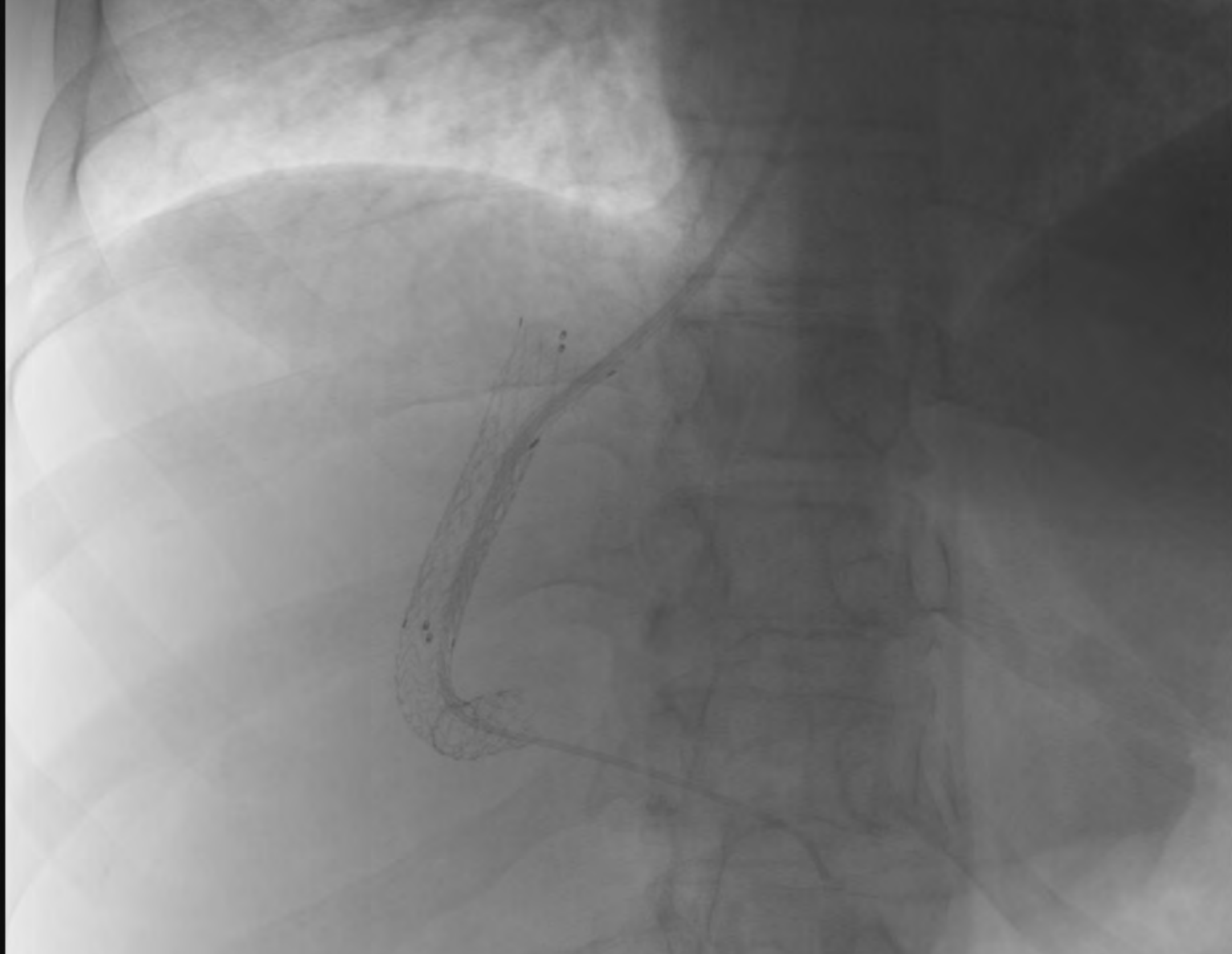


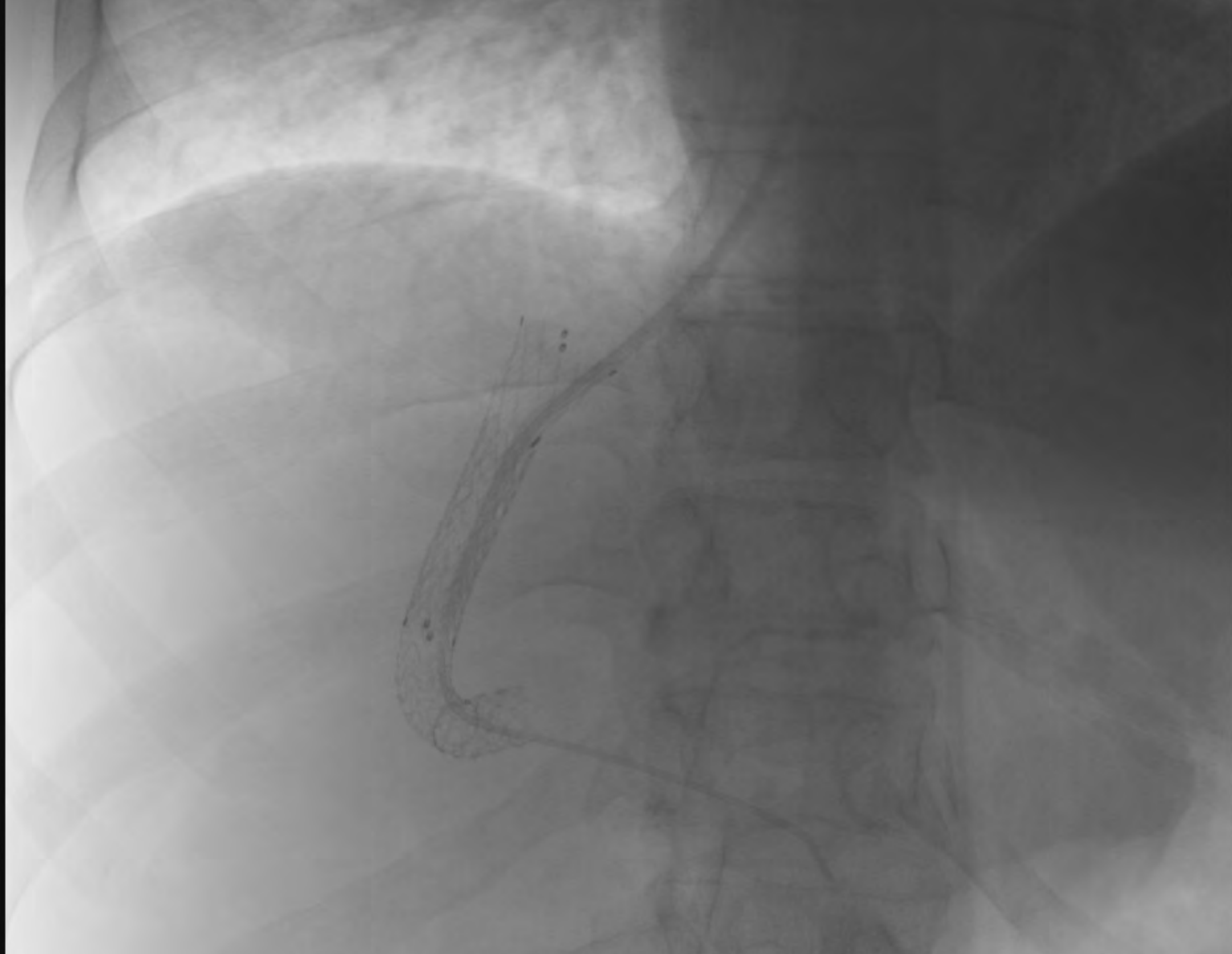


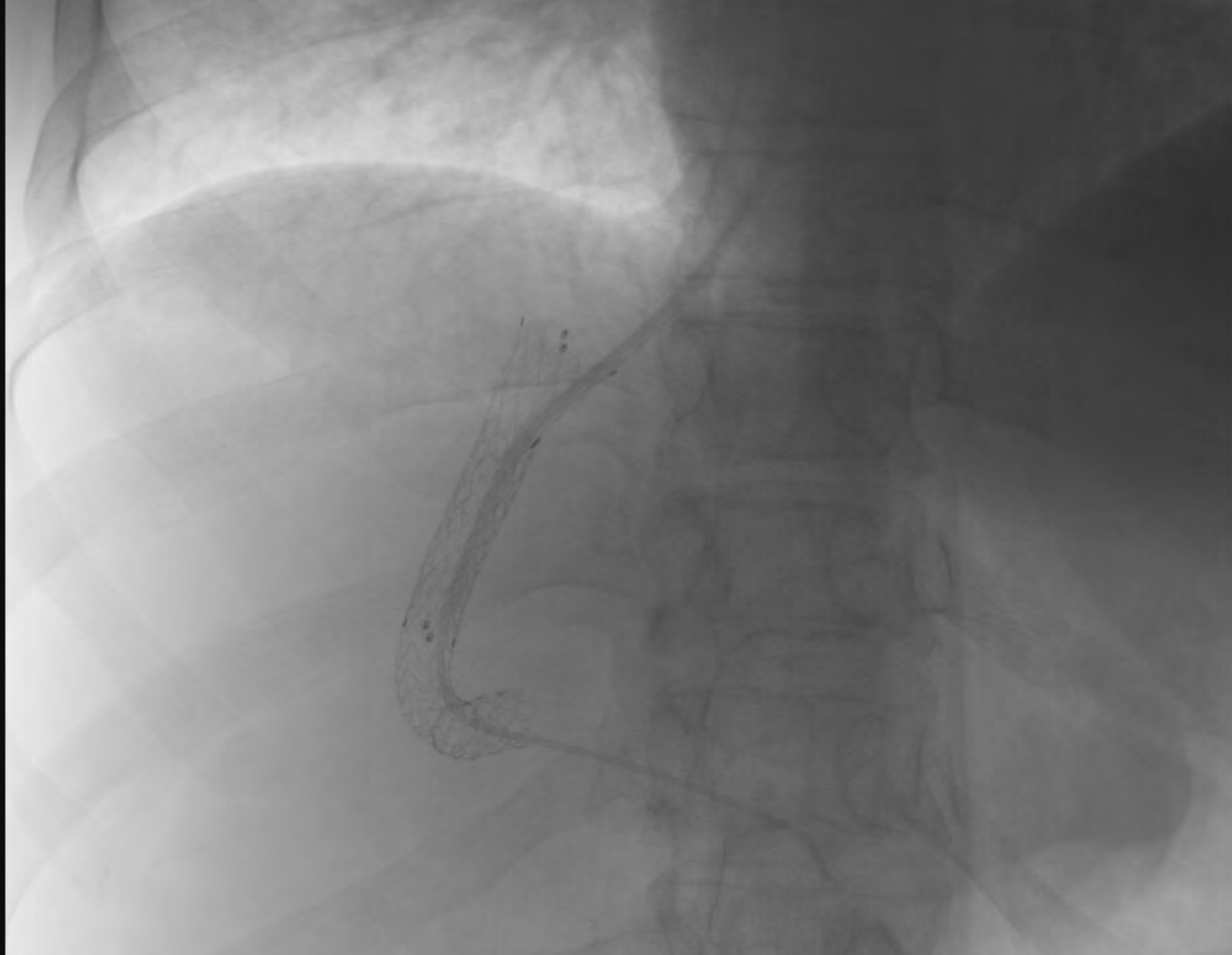


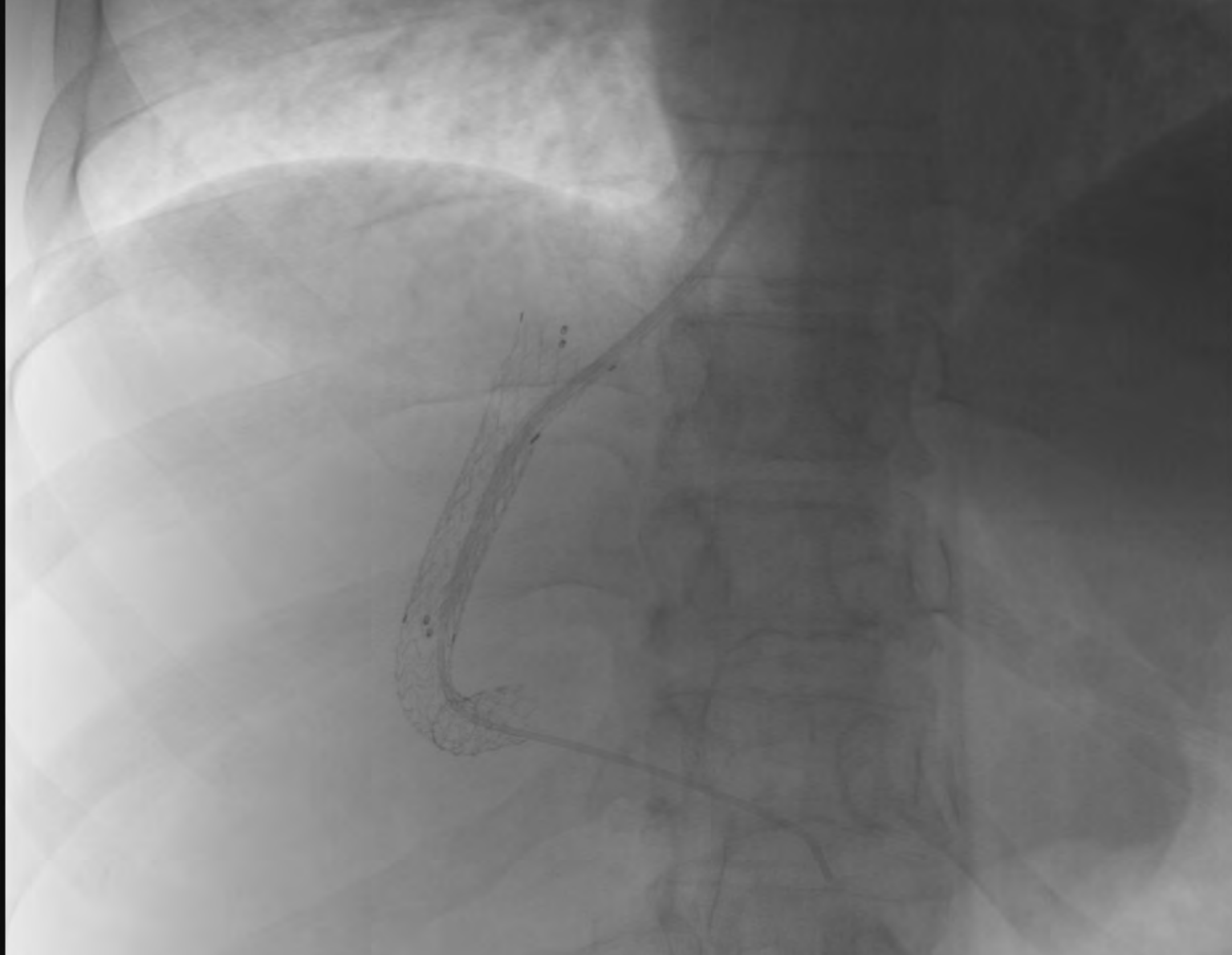


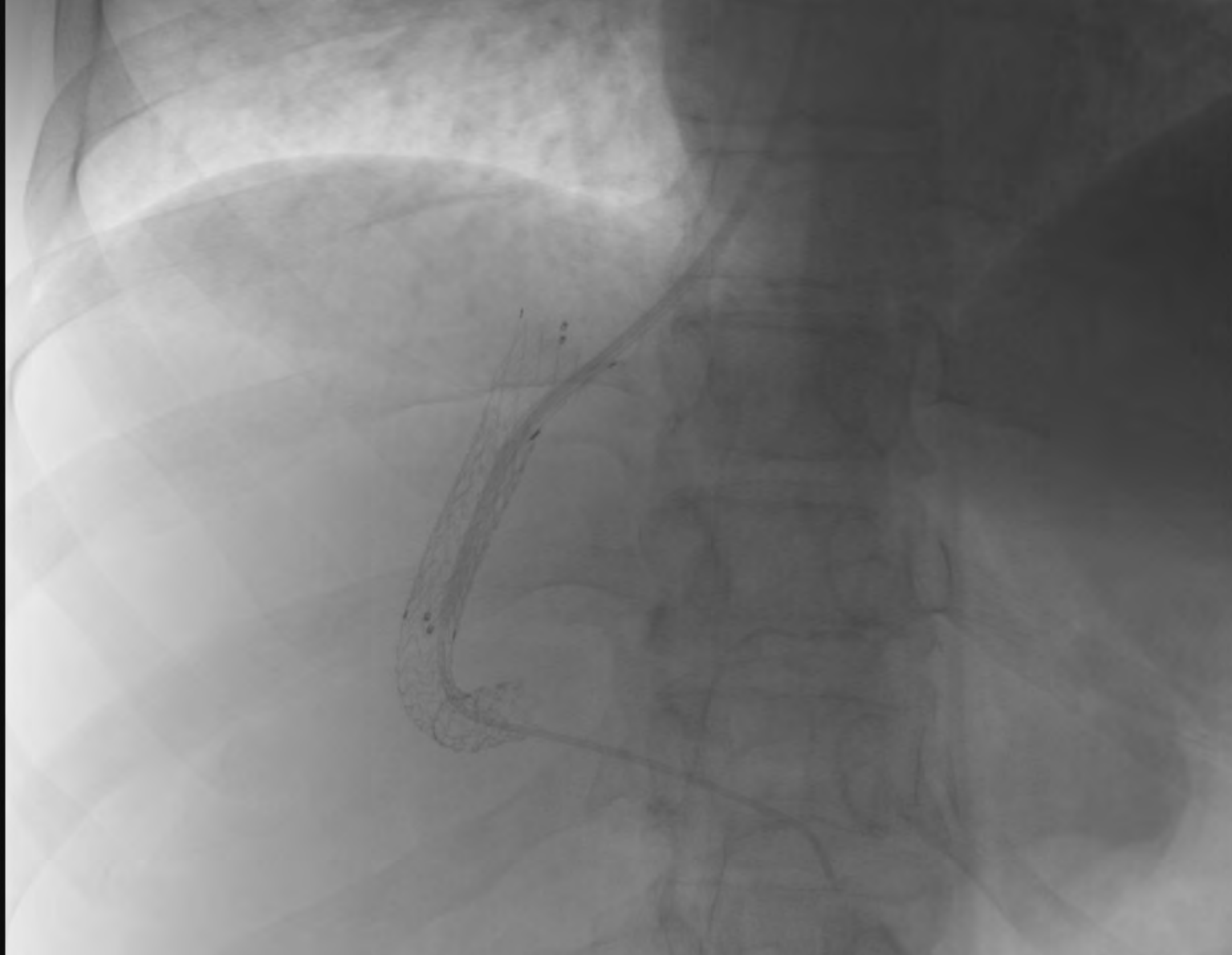

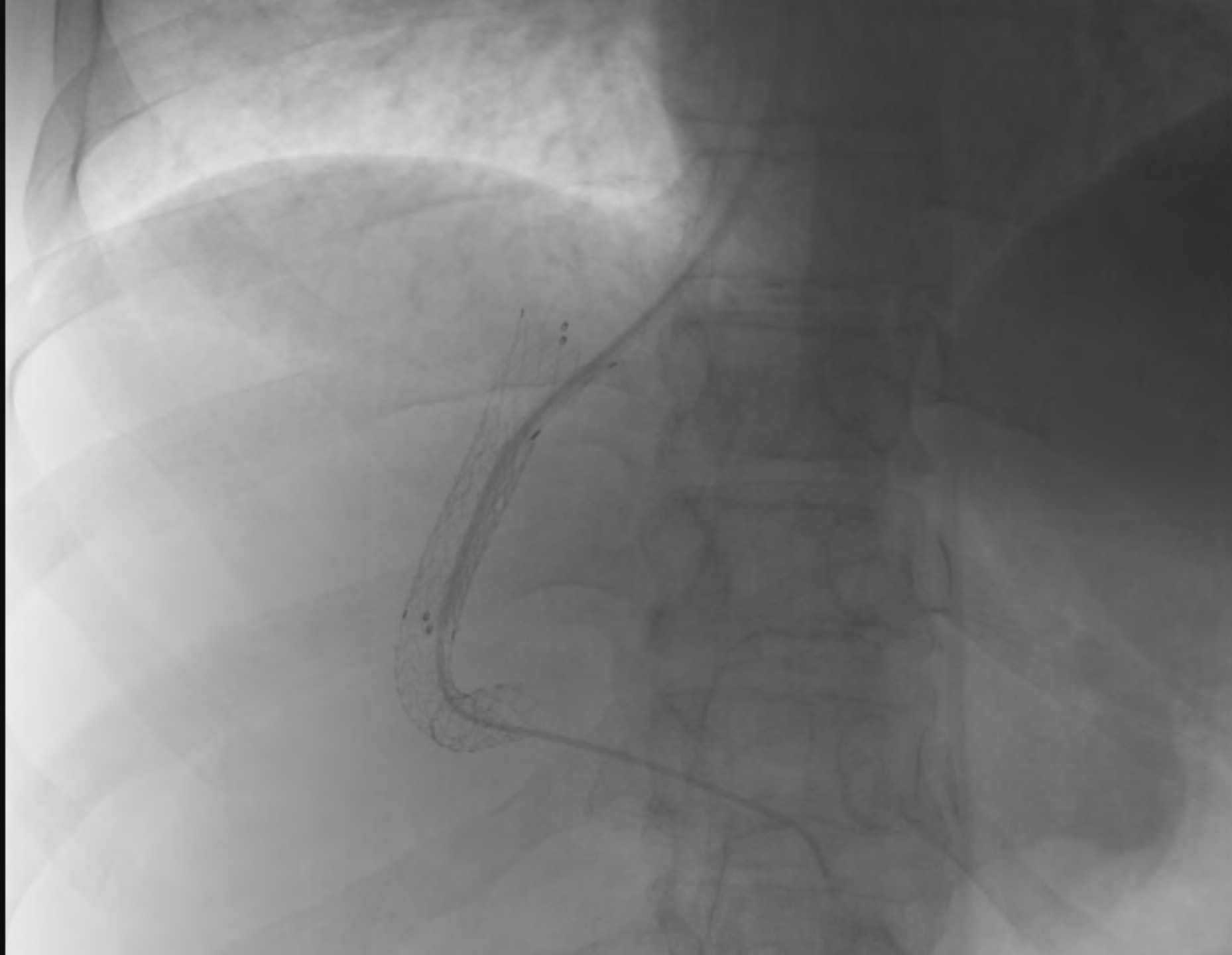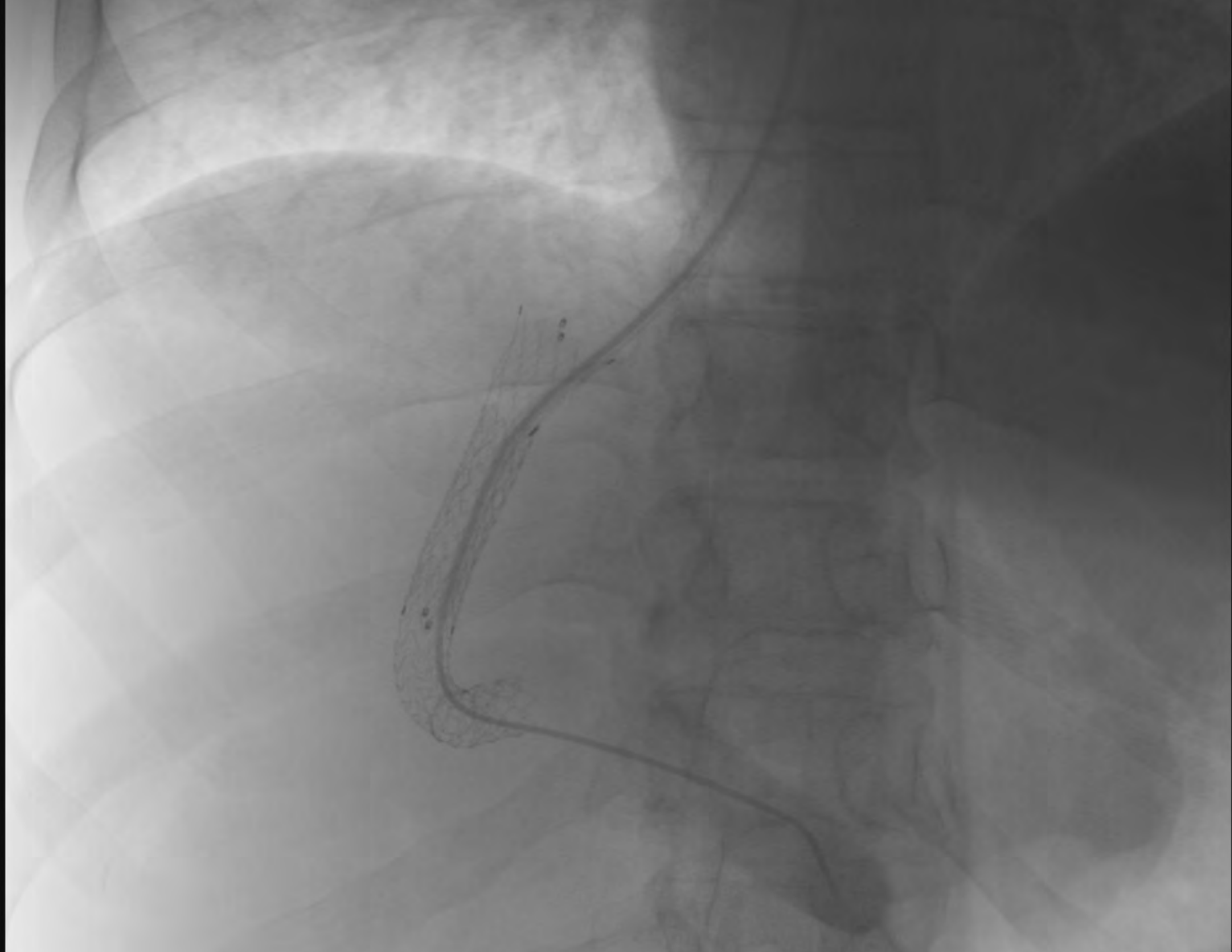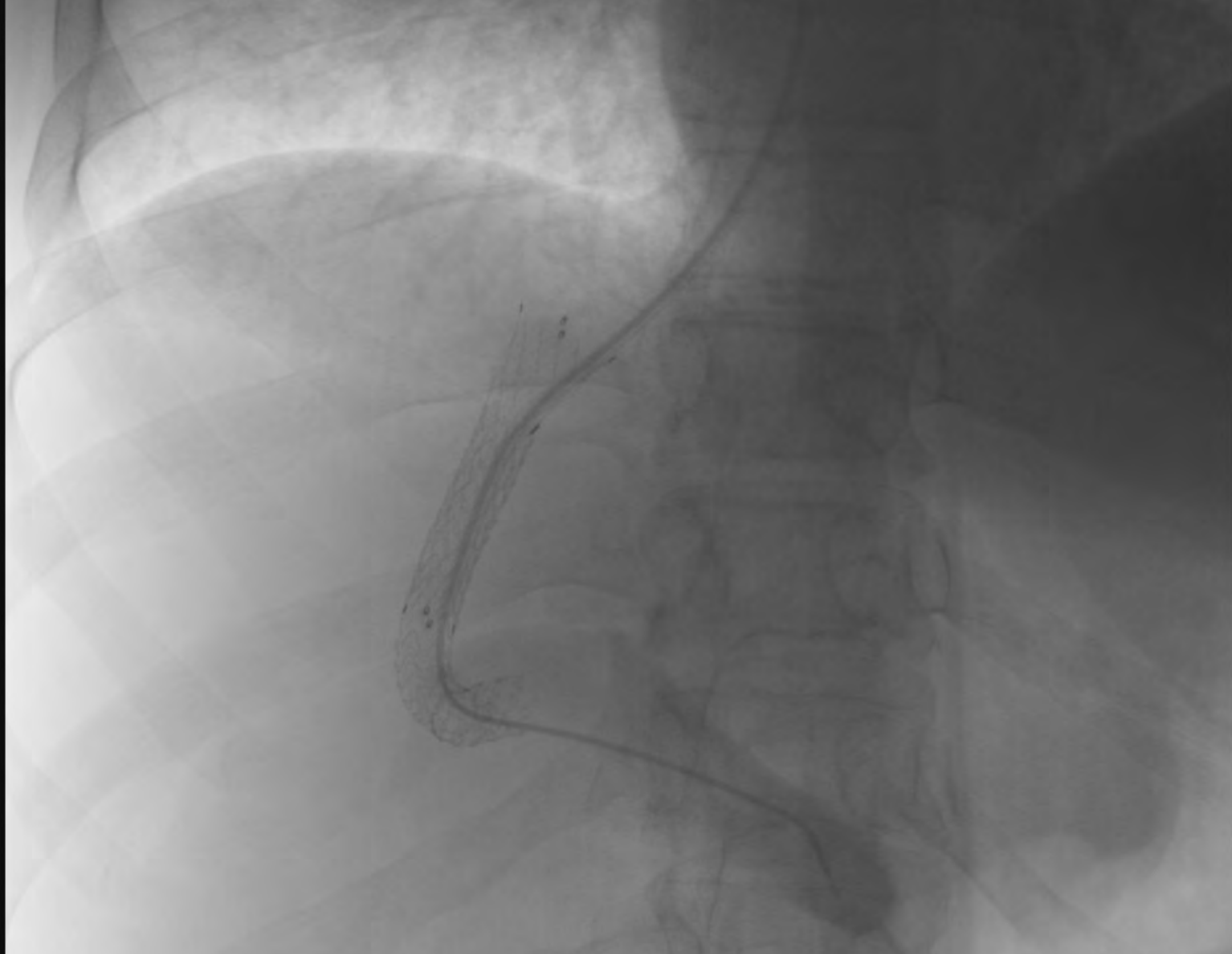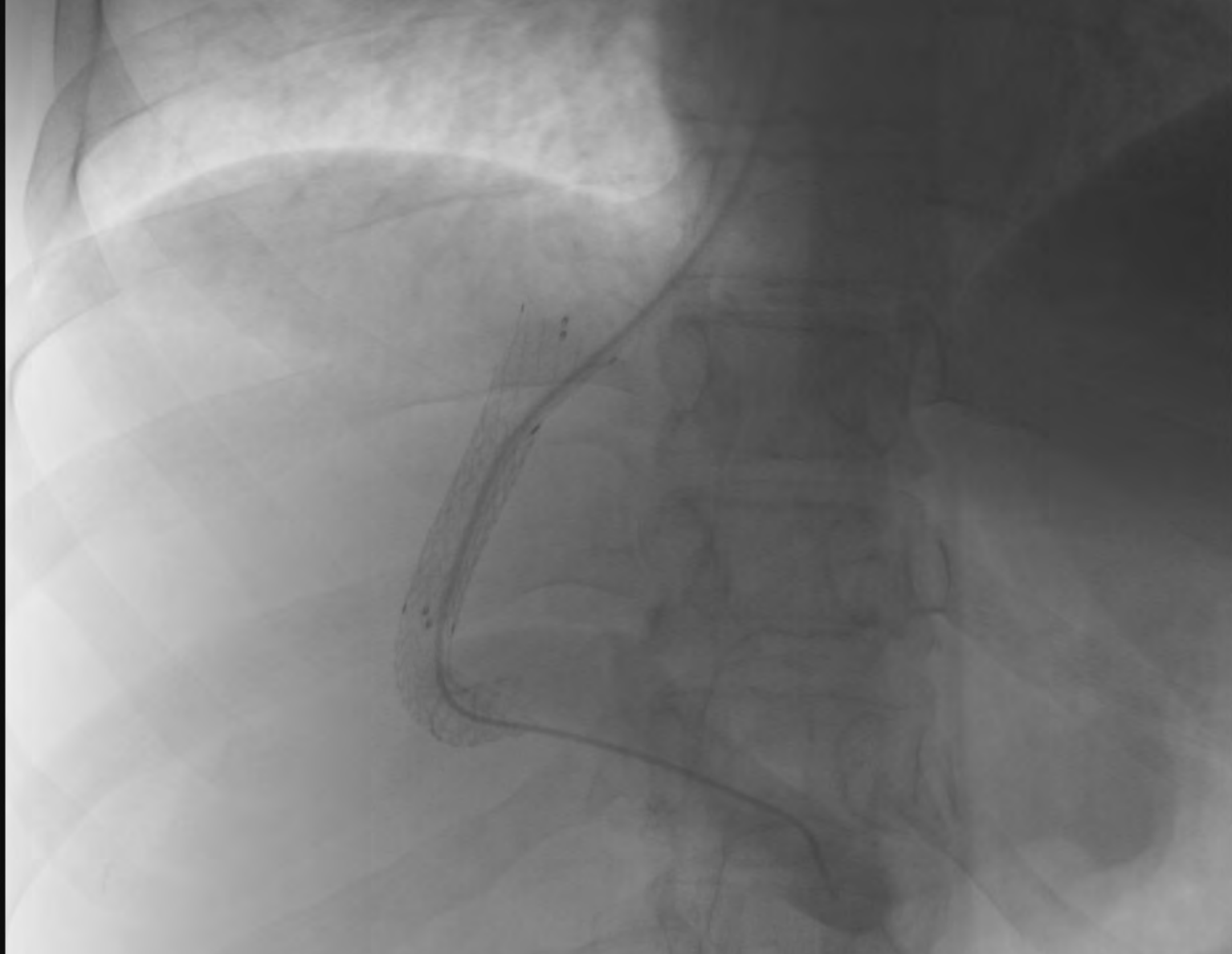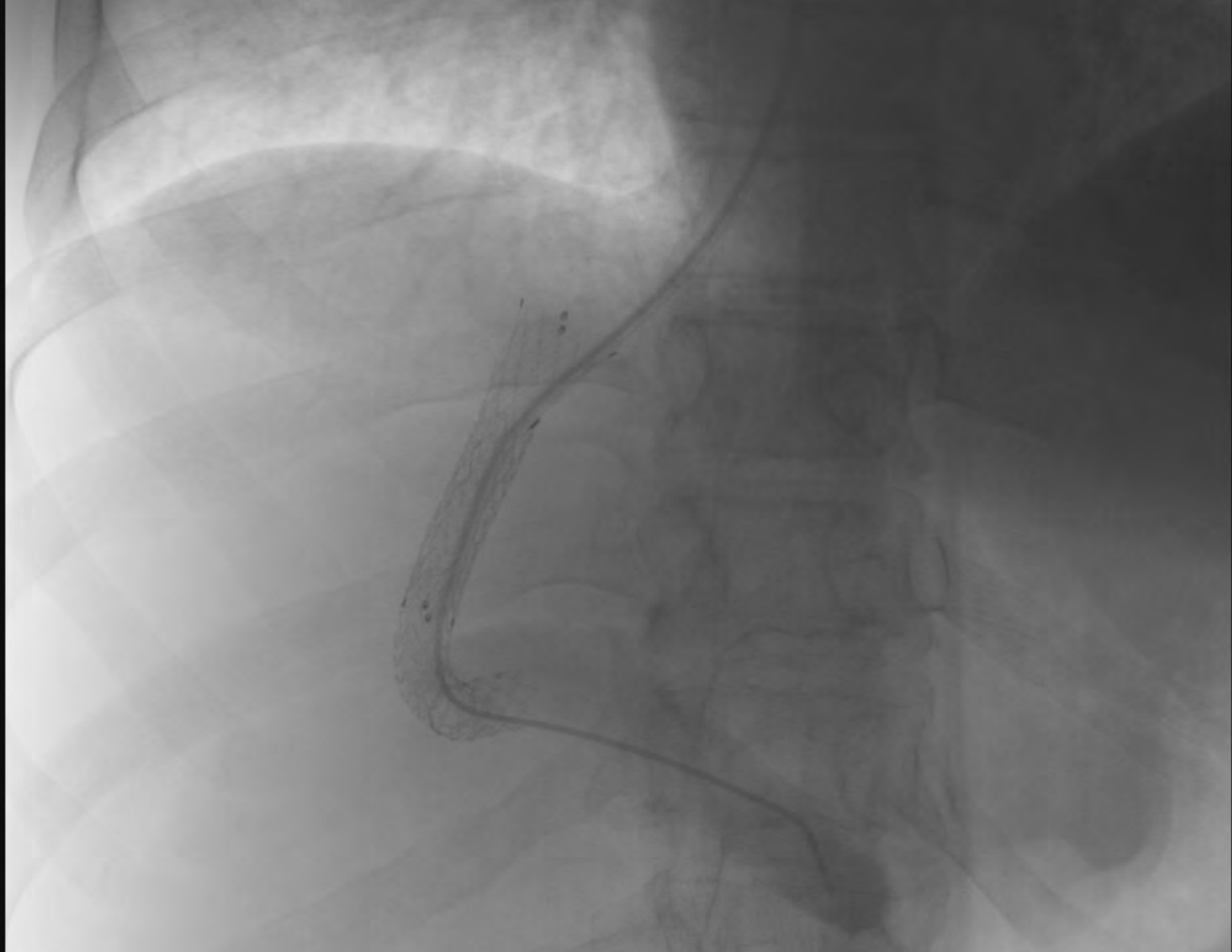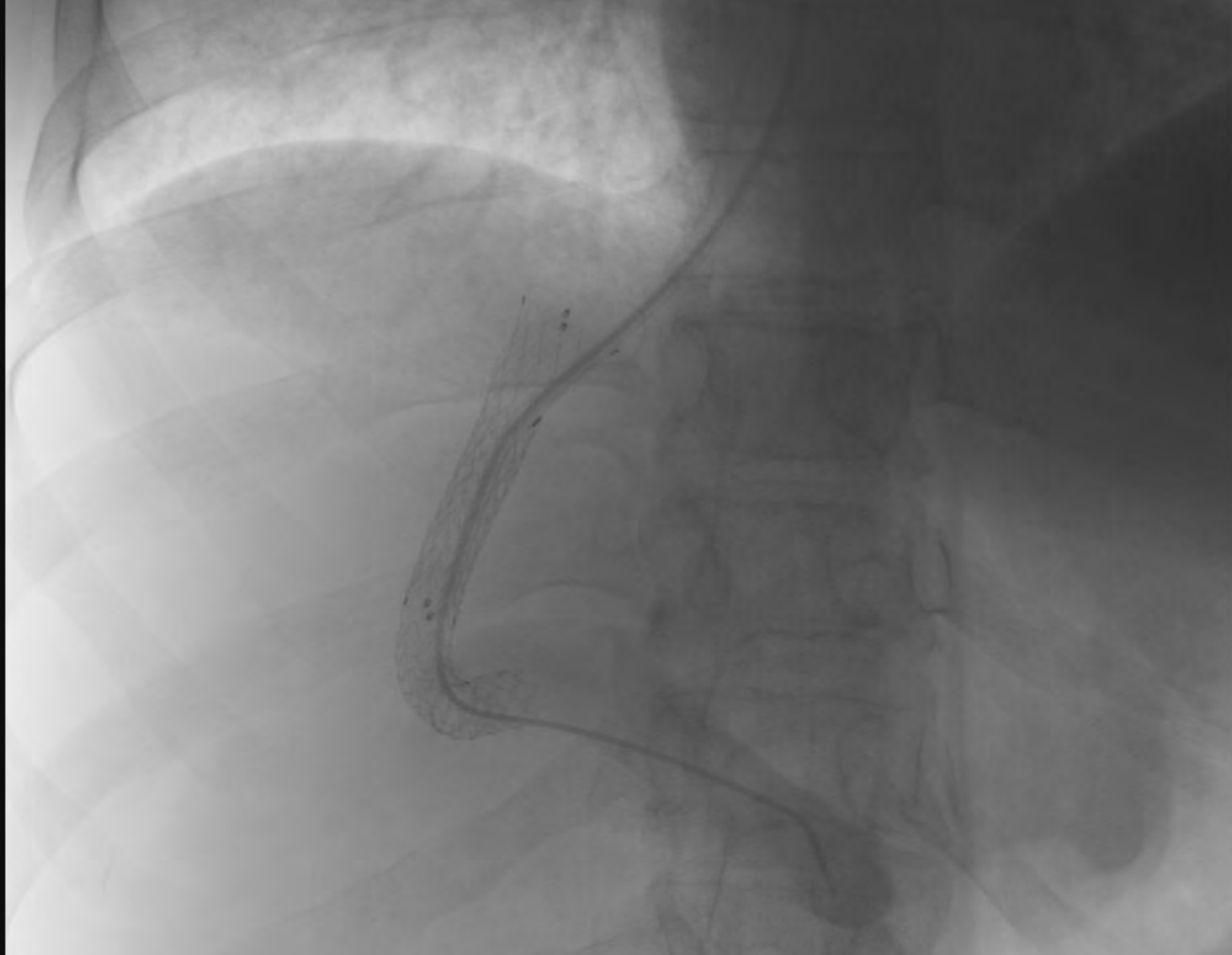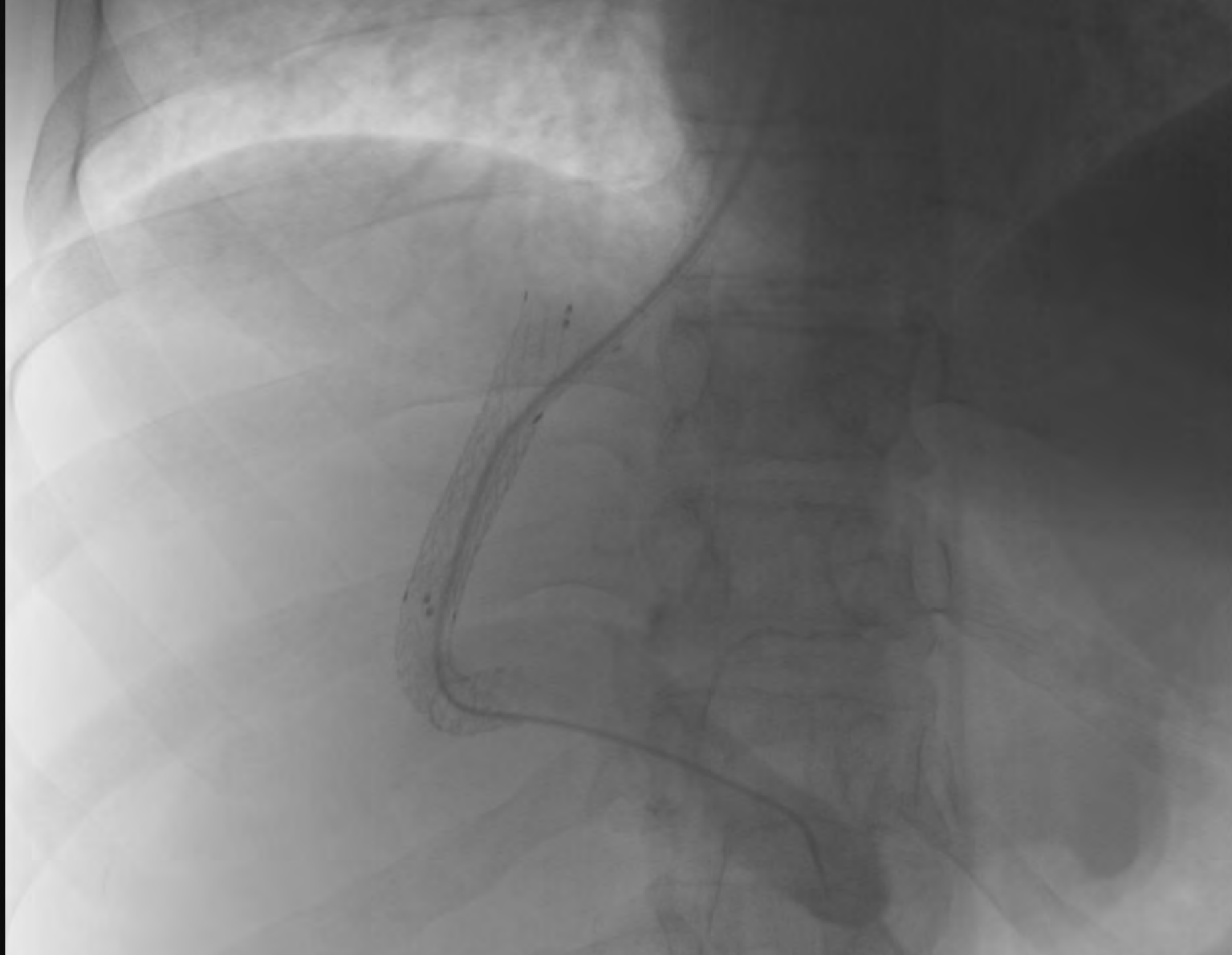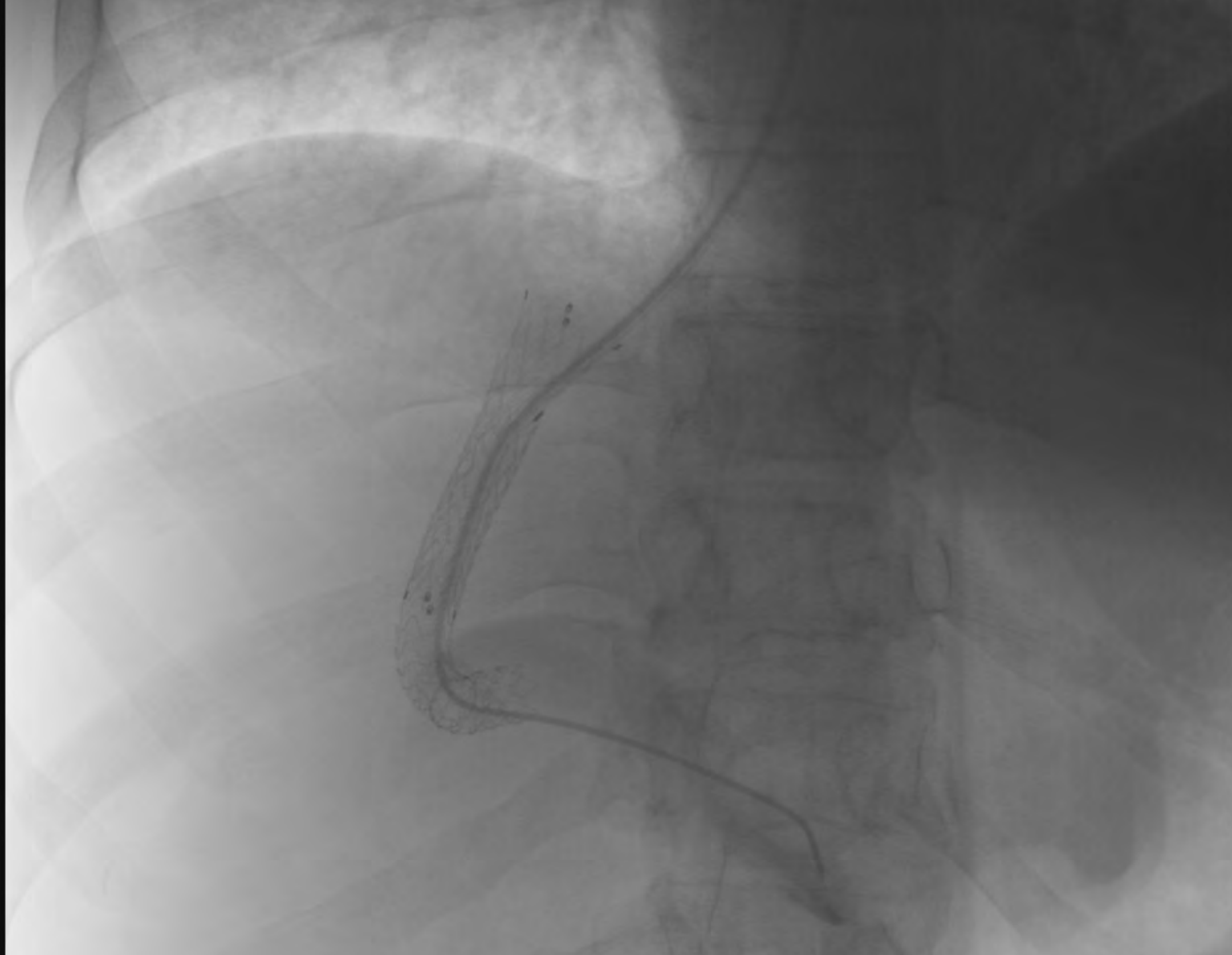


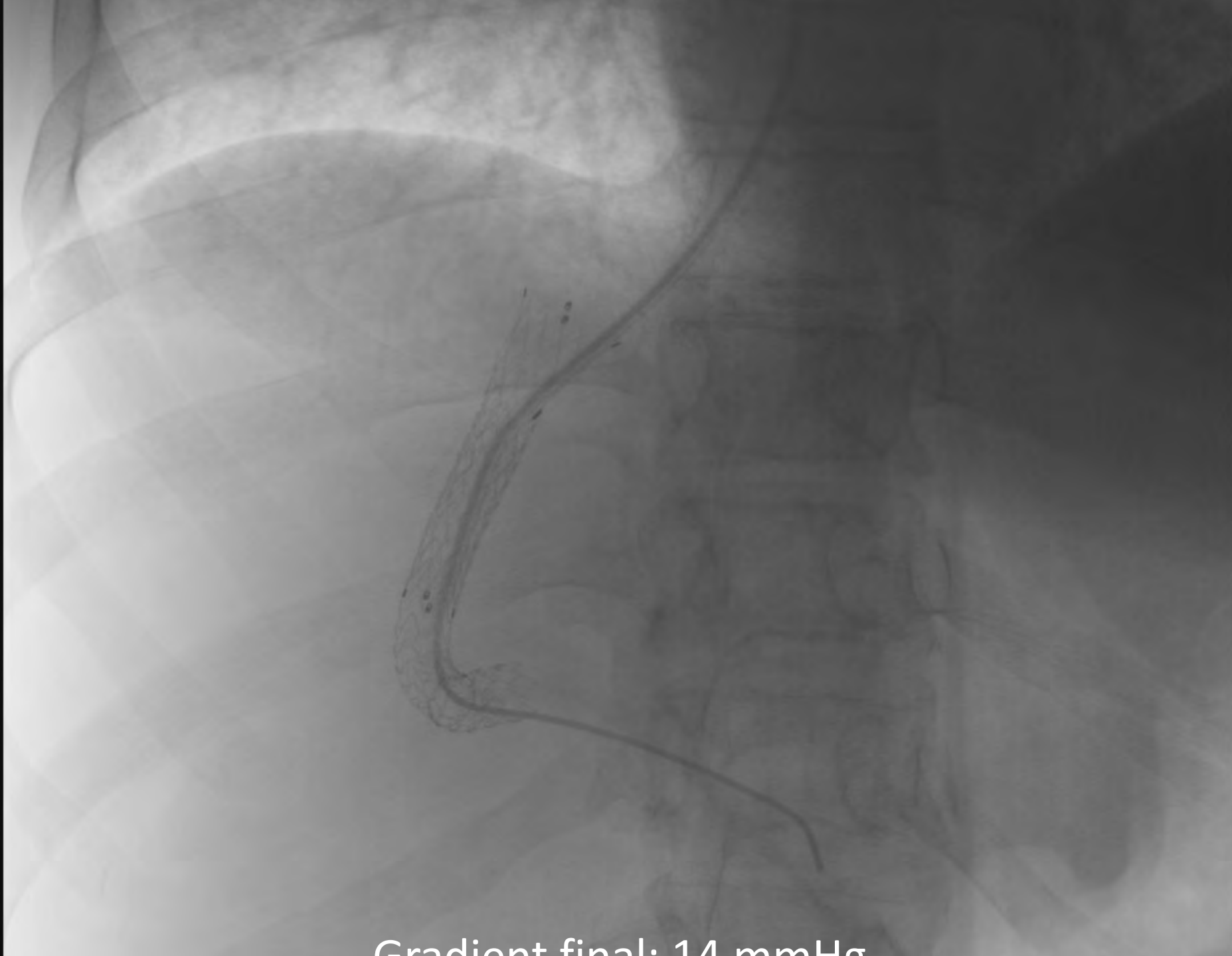












Gradient final: 14 mmHg

Décision RCP TIPS/TH

- Ok bilan pré-TH et inscription
- Mise en CIT car diminution du MELD

MERCI